

## Case 2704

# Bilateral theca lutein cysts associated with hydatidiform mole: MR findings

Bexiga A\*, Cunha TM\*, Penedo JP\*, Oliveira C\*, Tomé V\*\* \*Department of Radiology \*\*Department of Medical Oncology

INSTITUTO PORTUGUÊS DE ONCOLOGIA de Francisco Gentil de LISBOA

**Section:** Genital (Female) Imaging

**Published:** 2005, Oct. 22

**Patient:** 21 year(s), female

## Clinical Summary

A 21-year-old female patient was investigated for a sero-hematic vaginal discharge, a positive pregnancy test and the presence of bilateral adnexal masses.

## Clinical History and Imaging Procedures

The patient had been experiencing dysmenorrhea for the past two months, with hypertension and oliguria. She underwent a pregnancy test which was positive and an abdominal ultrasound that suggested a molar pregnancy. The histological examination of the material obtained by suction curettage revealed complete hydatidiform mole (Fig. 1). She was admitted to our hospital for further diagnostic and treatment evaluation, as she also had a dry cough, dyspnea, palpitations and dizziness. The physical examination revealed polypnea, a prominent abdomen and the presence of a palpable lump located in the hypogastrium and the left iliac fossae. This lump had an elastic consistency and was painless. She also had a sero-hematic vaginal discharge. The laboratory blood tests revealed a Hb level of 7.48 g/dl and a  $\beta$ -HCG >200,000 UI. A chest X-ray showed a diffuse bilateral interstitial infiltrate and a small bilateral pleural effusion (Fig. 2). The chest abnormalities were assumed to represent pulmonary edema, and disappeared after support treatment. An abdomino-pelvic MR scan was performed and the T2W images revealed a small homogeneous hepatic enlargement, mild ascitis; a uterine enlargement (the uterus measured 16 × 7 × 9 cm), a distortion of the normal zonal anatomy without focal changes in the myometrium, the presence of heterogeneous contents in the endometrial cavity, and a marked enlargement of the ovaries, containing multiple theca lutein cysts (Fig. 3a-e). On contrast-enhanced T1-

weighted images, there was a homogeneous enhancement seen in the myometrium and the uterine cervix (Fig. 3f, g). Considering the persistent elevated  $\beta$ -HCG levels, she was submitted to chemotherapy (6 cycles with methotrexate). After this the  $\beta$ -HCG levels returned to normal and there was an improvement in her clinical condition. One year later, she is well and without disease.

## Discussion

---

GTD is a proliferative process that results from an aberrant fertilization. GTD may occur in a benign form (hydatidiform mole) or as a malignancy (invasive mole or choriocarcinoma). GTD is characterized by an abnormal proliferation of pregnancy-associated trophoblastic tissue with malignant potential. Complete moles are associated with the absence of a fetus, whereas partial moles usually occur with an abnormal fetus or may be associated with fetal demise. Pregnancy-induced hypertension can occur before 24 weeks of gestation. In 25%-60% of the cases of hydatidiform mole, the ovaries are seen to contain multiple theca lutein cysts, resulting from ovarian hyperstimulation due to high circulating levels of  $\beta$ -HCG. These cysts are multiloculated, often bilateral, and resolve after treatment of the intrauterine process. Complications such as hyperthyroidism, anemia, and CID can occur. All patients should be screened for coagulopathy. An occurrence of trophoblastic embolism is believed to cause acute respiratory insufficiency. Once the diagnosis has been confirmed, the patient should be evaluated for metastatic disease and the molar pregnancy should be terminated. 15% of women with a complete mole will develop recurrent disease in the form of an invasive mole or choriocarcinoma. The mole, although evacuated, may persist and remain confined to the uterine cavity, penetrate the myometrium, embolize to the vagina or lungs, or transform into a choriocarcinoma. In most patients with complete moles, adequate evacuation is curative and vacuum aspiration is recommended as the initial method to avoid the dangers of perforation. In recent years, an earlier administration of chemotherapy has been found to reduce the incidence of metastases. A transabdominal sonography is of value when gestational trophoblastic disease is a diagnostic consideration. The complete hydatidiform mole has a classic sonographic appearance of a solid collection of echoes with numerous anechoic spaces. The ultrasound technique has not been shown to be useful in staging or in determining the patient's risk of developing persistent disease. Endovaginal sonography reveals the presence of multiple anechoic channels and spaces which are typically seen with trophoblastic disease. A color-Doppler endovaginal imaging procedure showed high-velocity blood flow, with a low-impedance system, through most of these spaces. Importantly, the color-Doppler imaging disclosed the presence of vascular invasion of the myometrium. CT is the imaging procedure of choice to search for metastases (especially for lung metastases). MR imaging should be used when the use of a contrast medium is contraindicated, follow-up studies are needed, or when the uterus is to be evaluated as the site of primary disease. It is also indicated as a technique to search for a local myometrial or pelvic invasion. A hydatidiform mole usually appears as a heterogeneous, markedly hyperintense mass on T2-weighted images, that distends the endometrial cavity. On contrast-enhanced T1-weighted images, characteristic numerous cystic areas are seen in the mass. The normal myometrium remains and surrounds the mass. Intralesional hemorrhage and necrosis

are also typical occurrences, and both would be expected to cause areas of high-intensity signal within the tumor, on MR images. MR imaging is useful in tumor detection when the tumor deeply invades the myometrium but does not extend to the endometrial surface. In this situation, uterine curettage specimens are nondiagnostic. During chemotherapy, imaging studies are requested only when HCG concentrations plateau or rise unexpectedly. The reappearance of uterine zones, a decrease in myometrial and adnexal vascularity, and a development of intralesional hemorrhage and/or necrosis paralleled the decreases in serum  $\beta$ -HCG levels, during favourable therapeutic response.

## Final Diagnosis

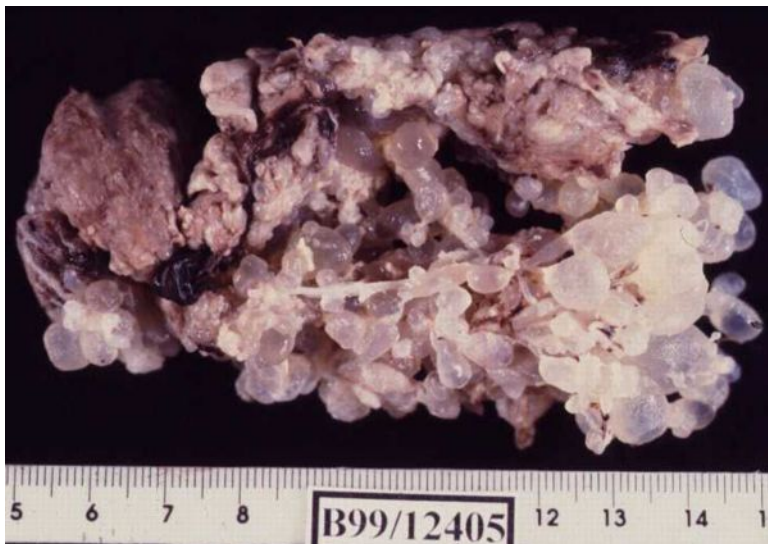---

Complete hydatidiform mole.

## Figures

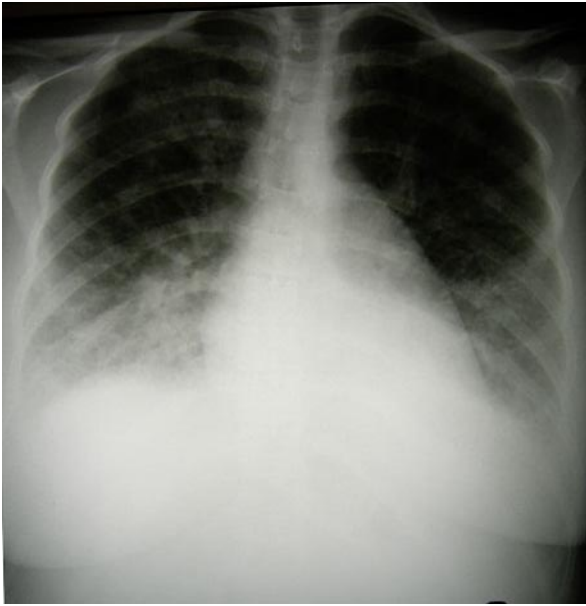
---

Figure 1



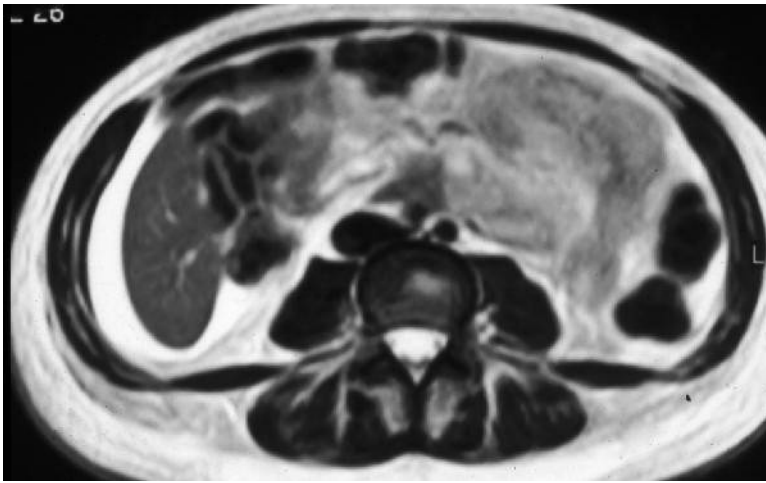
An image showing the gross specimen of a complete hydatidiform mole with the classic "cluster of grapes" appearance.

**Figure 2**

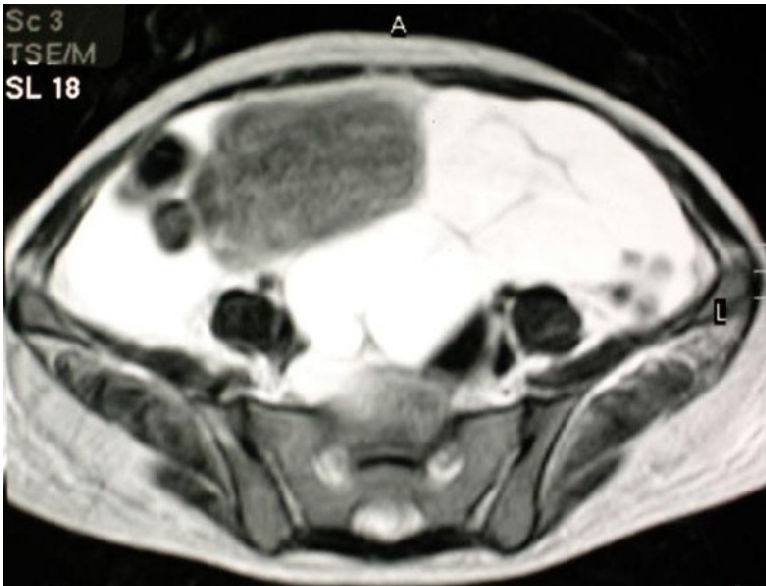


A chest X-ray showing diffuse bilateral interstitial infiltrate and a small bilateral pleural effusion.

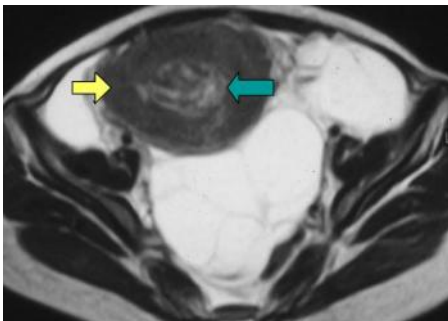
**Figure 3**



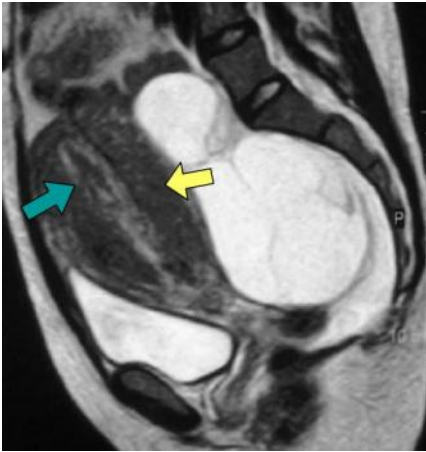An axial T2-weighted image (lower abdomen) showing mild homogeneous hepatic enlargement, peri-hepatic and bilateral parieto-colic ascitis.



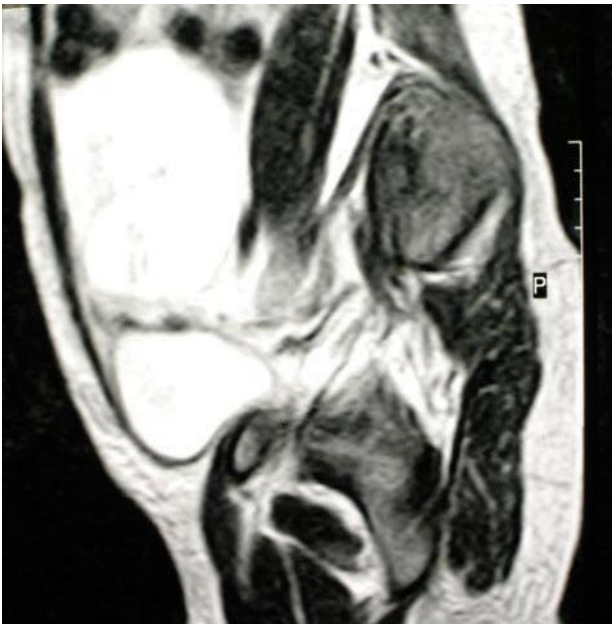An axial T2-weighted image showing uterine enlargement with partial volume of the corpus localized in a right position. There is a marked enlargement of the ovaries, containing multiple theca lutein cysts. The right ovary is in a retro-uterine position. Ascitis is seen in the parieto-colic fossa.



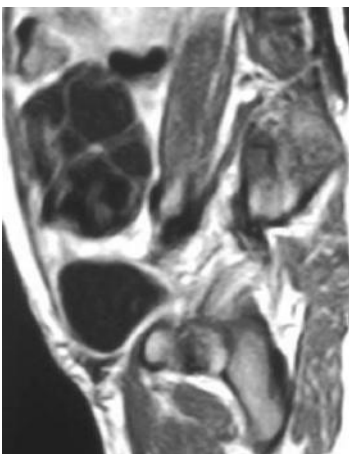
An axial T2-weighted image showing uterine enlargement with the loss of the normal zonal anatomy, without focal changes in the myometrium (yellow arrow), and heterogeneous contents in the endometrial cavity (green arrow). There is a marked enlargement of the ovaries containing multiple theca lutein cysts. The right ovary is in a retro-uterine position. Ascitis in the right iliac fossae and posterior to the right ovary can be seen.



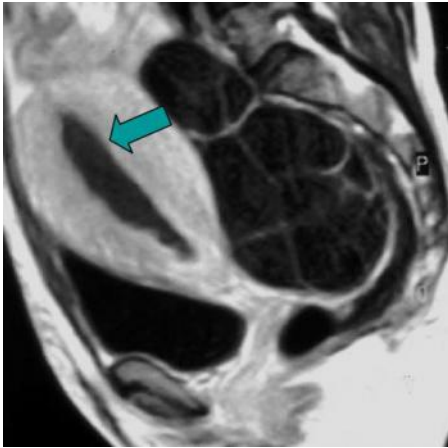A sagittal T2-weighted image showing uterine enlargement with the loss of the normal zonal anatomy, without focal changes in the myometrium (yellow arrow), and heterogeneous contents in the endometrial cavity (green arrow). Multiple theca lutein cysts in the right ovary, and mild ascitis in the cul-de-sac can be seen.



A sagittal T2-weighted image showing multiple theca lutein cysts in the left ovary.



A sagittal contrast-enhanced T1-weighted image showing multiple theca lutein cysts in the left ovary.



A sagittal contrast-enhanced T1-weighted image showing a homogeneous enhancement in the myometrium and uterine cervix. There is presence of fluid in the endometrial cavity (green arrow). Multiple theca lutein cysts in the right ovary in a retro-uterine position, and mild ascitis in the cul-de-sac can be seen.

## MeSH

---

### **Trophoblasts** [A16.759.802]

Cells lining the outside of the BLASTOCYST. After binding to the ENDOMETRIUM, trophoblasts develop into two distinct layers, an inner layer of mononuclear cytotrophoblasts and an outer layer of continuous multinuclear cytoplasm, the syncytiotrophoblasts, which form the early fetal-maternal interface (PLACENTA).

### **Hydatidiform Mole** [C13.703.720.949.416.875]

Trophoblastic hyperplasia associated with normal gestation, or molar pregnancy. It is characterized by the swelling of the CHORIONIC VILLI and elevated human CHORIONIC GONADOTROPIN. Hydatidiform moles or molar pregnancy may be categorized as complete or partial based on their gross morphology, histopathology, and karyotype.

## References

---

- [1] Wagner BJ, Woodward PJ, Dickey GE. From the Archives of the AFIP. Gestational Trophoblastic Disease: Radiologic-Pathologic Correlation. Radiographics. 1996 Jan; 16(1):131-48.
- [2] Green CL, Angtuaco TL, Shah HR, Parmley TH. Gestational Trophoblastic Disease: a spectrum of radiologic diagnosis. Radiographics. 1996 Nov; 16(6):1371-84.
- [3] Nagayama M, Watanabe Y, Okumura A, et al. Fast MR imaging in obstetrics. Radiographics. 2002 May-Jun; 22(3):563-80.
- [4] Desai RK, Desberg AL. Diagnosis of Gestational Trophoblastic Disease: value of endovaginal color flow Doppler sonography. AJR Am J Roentgenol. 1991 Oct; 157(4):787-8.
- [5] Sanders C, Rubin E. Malignant Gestational Trophoblastic Disease: CT findings. AJR Am J Roentgenol. 1987 Jan; 148(1):165-8.

## Citation

---

Bexiga A\*, Cunha TM\*, Penedo JP\*, Oliveira C\*, Tomé V\*\* \*Department of Radiology \*\*Department of Medical Oncology (2005, Oct. 22)

**Bilateral theca lutein cysts associated with hydatidiform mole: MR findings {Online}**

URL: <http://www.eurorad.org/case.php?id=2704>