

*G Chir Vol. 37 - n. 4 - pp. 155-157  
July-August 2016*

original article

## Pancreas divisum: correlation between anatomical abnormalities and bile precipitation in the gallbladder in seven patients

P. IZZO<sup>1</sup>, P. DI CELLO<sup>1</sup>, F. PUGLIESE<sup>1</sup>, S. IZZO<sup>1</sup>, R. GRANDE<sup>1</sup>, F. BIANCUCCI<sup>1</sup>, G. SINAIMERI<sup>1</sup>, F. RAZIONALE<sup>1</sup>, U. COSTI<sup>1</sup>, M. AL MANSOUR<sup>1</sup>, A. MUNEEER<sup>2</sup>, S. VALABREGA<sup>3</sup>, L. IZZO<sup>1</sup>

**SUMMARY: Pancreas divisum: correlation between anatomical abnormalities and bile precipitation in the gallbladder in seven patient.**

P. IZZO, P. DI CELLO, F. PUGLIESE, S. IZZO, R. GRANDE, F. BIANCUCCI, G. SINAIMERI, F. RAZIONALE, U. COSTI, M. AL MANSOUR, A. MUNEEER, S. VALABREGA, L. IZZO

*Pancreas divisum is a genetic defect associated with recurrent acu-*

*te pancreatitis due to insufficient drainage of the accessory pancreatic duct. Seven young patients diagnosed with pancreatic divisum and thickening of the gallbladder bile as shown on magnetic resonance cholangio-pancreatography without pancreatic ductal changes underwent laparoscopic cholecystectomy. During the mean follow-up of 32 months no episode of pancreatitis was reported. There is an association between PD and higher concentration of bile in the gallbladder. Cholecystectomy can be considered curative in patients with PD in the absence of indications for major surgery.*

KEY WORDS: Pancreas divisum - Laparoscopic cholecystectomy - Pancreatitis.

### Introduction

The pancreas divisum (PD) is the most common congenital anatomical anomaly of the pancreas. It is found in 7% of autopsy series (1, 2). PD is characterized by a lack of fusion between the embryological dorsal and ventral ducts of the pancreas. The dorsal pancreatic bud is composed of the head, body and tail and is drained into the duodenum through the papilla minor, the ventral pancreatic bud is composed of part of the head and uncinata process and is drained together with the bile duct through the papilla major. There is often association between PD and recurrent acute and or chronic pancreatitis, which appears to be caused in most cases by inadequate drainage of the dorsal pancreas. Instead, an incomplete PD is characterized by a connection between the two ductal systems, which are present, but are insufficient (4). The diagnosis of PD is based on Endoscopic retrograde cholangiopancreatography (ERCP) and magnetic resonance cholangiopancreatography (MRCP)

imaging with secretin stimulation. PD is asymptomatic in most patients, but in about 5% of cases patients develop symptoms of pancreatitis, potentially as a result of insufficient drainage through the papilla minor (7). Surgical treatment aims to increase the drainage of the dorsal pancreas (8) by ERCP with papillotomy or stent, causing a regression of symptoms in two-thirds of patients (3, 5, 6, 8-10). In cases of persistent symptoms, reinsertion of the papilla, "duodenum-preserving" resection of the head of the pancreas or pancreatic resection according to Whipple can be done (11-13, 19).

### Patients and methods

Seven patients (4 males and 3 females) with a mean age of 34 years (range 28-36), were prospectively observed between 2006 and 2011. All patients were hospitalized for recurrent pancreatitis (at least 2 episodes), with a elevated amylase and lipase blood levels (above what threshold?). The MRCP Imaging demonstrated the presence of complete pancreas divisum (4 patients) in association with mild ectasia of the pancreatic ducts in only 2 patients (Fig. 1) and incomplete pancreas divisum (3 patients) with normal calibre of the pancreatic ducts (Fig. 2). In all patients examined, we observed the presence of thickening of the bile in the gallbladder.

In the absence of clear indications to surgery on the

<sup>1</sup> Department of Surgery "Pietro Valdoni", Policlinico Umberto I, "Sapienza" University of Rome, Rome, Italy

<sup>2</sup> Research Oncology, Division of Cancer Studies, King's College London, SE1 9RT, UK

<sup>3</sup> Department of General Surgery, "Sant'Andrea" Hospital, "Sapienza" University of Rome, Rome, Italy

Corresponding author: Luciano Izzo, e-mail: [luciano.izzo@uniroma1.it](mailto:luciano.izzo@uniroma1.it)

© Copyright 2016, CIC Edizioni Internazionali, Roma

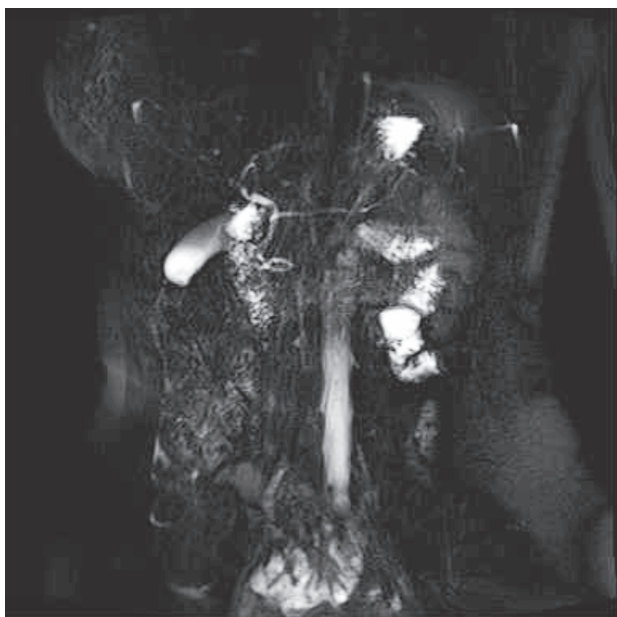


Figure 1 - Complete PD.

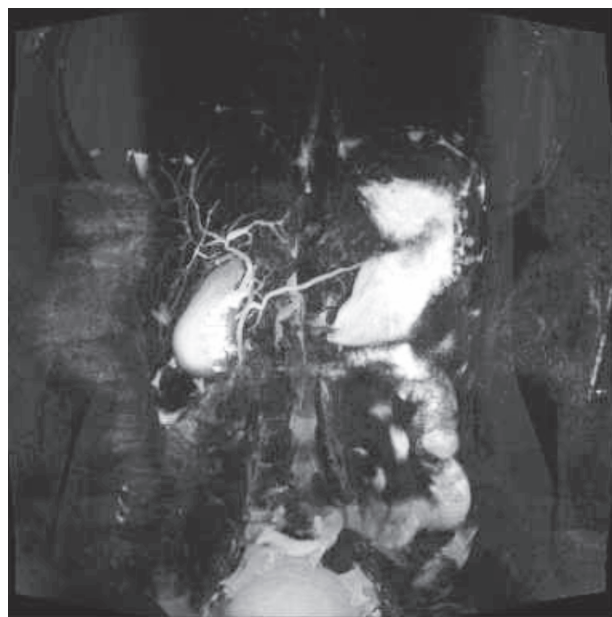


Figure 2 - Incomplete PD.

pancreatic ducts, all patients underwent laparoscopic cholecystectomy in our Department of surgery. The mean follow-up period of 32 months (range 28-36) demonstrated the complete absence of further episodes of postoperative pancreatitis.

## Discussion

Over 95% of patients with PD are asymptomatic, but the remaining 5% develop symptoms of acute pancreatitis. The causative factor for this appears to be an insufficient drainage of pancreatic fluids through the papilla minor. The origin of the symptoms, whether from the sphincter of Oddi dysfunction or structural stenosis of the papilla, is still debated. The reason why only some patients develop symptoms is even less clear (8, 14-17). It should be noted that 22% of patients with clinical symptoms associated with PD have mutations in the “cystic fibrosis trans-membrane conductance regulator gene” (CFTR). The clinical symptoms seem to be the only factor influencing the decision of surgical treatment (18).

In 7 patients treated in our department, the patients had no dilation of the accessory pancreatic duct, but

showed, symptoms of recurrent, acute pancreatitis. In all cases the MRCP Imaging identified thickening of the bile in the gallbladder, which we consider the aetiology of their symptoms.

The patients underwent laparoscopic cholecystectomy with resolution of pain, and absence of further episodes of acute pancreatitis during a mean follow-up period of 32 months. Therefore, it is possible that there is an association between the primitive pancreatic anatomical malformations and increased precipitation and concentration of bile in the gallbladder that causes poor drainage of the accessory pancreatic-duct.

## Conclusions

It is possible that laparoscopic cholecystectomy may be curative in the presence of bile thickening within the gallbladder, associated with PD - in the absence of dilation of the accessory pancreatic duct. It may also be beneficial in patients possessing clinical symptoms, when interventional ERCP contraindicated to avoid duodenal preserving resection of the pancreas carries with its high associated morbidity and mortality (19-23).

## References

1. Vidali M, Doulgerakis G, Condilis N, Karmiri E, Poygouras I, Papaioannoy G, Ioannoy C, Pierrakakis S, Setakis N. Diagnostic and therapeutic approach to pancreatic trauma. *Ann Ital Chir.* 2005 May-Jun;76(3):247-50. Italian.
2. Bruzzone P. Independent organ donor facilities: The future of organ donation? *Ann Ital Chir.* 2014;85:616-7.
3. Dumont F, Yzet T, Vibert E, Poirier J, Bartoli E, Delcenserie R, Manaouil D, Dupas JL, Bounicaud D, Regimbeau JM. Pancreas

- divisum and the dominant dorsal duct syndrome. *Ann Chir.* 2005 Jan;130(1):5-14. Review. French.
4. Smanio T. Proposed nomenclature and classification of the human pancreatic ducts and duodenal papillae. Study based on 200 post mortems. *Int Surg.* 1969;52:125-141.
  5. Lubrano J, Scatton O, Schlessler C, Soubrane O. Aberrant pancreas and duodenal diaphragm: an exceptional association. *Ann Chir.* 2006 May;131(5):334-7. Epub 2005 Nov 7. French.
  6. Stern CD. A historical perspective on the discovery of the accessory duct of the pancreas, the ampulla 'of Vater' and pancreas divisum. *Gut.* 1986;27:203-212.
  7. Satterfield ST, McCarthy JH, Geenen JE, Hogan WJ, Venu RP, Dodds WJ, et al. Clinical experience in 82 patients with pancreas divisum: preliminary results of manometry and endoscopic therapy. *Pancreas.* 1988;3:248-253.
  8. Wolf DC, Sivak MV Jr. Partial pancreas divisum. *Cleve Clin J Med.* 1987;54:33-37.
  9. Manfredi R, Costamagna G, Brizi MG, Spina S, Maresca G, Vecchioli A, et al. Pancreas divisum and "Santorinicele": diagnosis with dynamic MR cholangiopancreatography with secretin stimulation. *Radiology.* 2000;217:403-408.
  10. Matos C, Metens T, Deviere J, Delhay M, Le Moine O, Cremer M. Pancreas divisum: evaluation with secretin-enhanced magnetic resonance cholangiopancreatography. *Gastrointest Endosc.* 2001;53:728-733.
  11. Fogel EL, Toth TG, Lehman GA, DiMagno MJ, DiMagno EP. Does endoscopic therapy favorably affect the outcome of patients who have recurrent acute pancreatitis and pancreas divisum? *Pancreas.* 2007;34:21-45.
  12. Lehman GA, Sherman S. Pancreas divisum. Diagnosis, clinical significance, and management alternatives. *Gastrointest Endosc Clin N Am.* 1995;5:145-170.
  13. Borak GD, Romagnuolo J, Alsolaiman M, Holt EW, Cotton PB. Long-term clinical outcomes after endoscopic minor papilla therapy in symptomatic patients with pancreas divisum. *Pancreas.* 2009;38:903-906.
  14. Lans JJ, Geenen JE, Johanson JF, Hogan WJ. Endoscopic therapy in patients with pancreas divisum and acute pancreatitis: a prospective, randomized, controlled clinical trial. *Gastrointest Endosc.* 1992;38:430-434.
  15. Madura JA, Madura JA II, Sherman S, Lehman GA. Surgical sphincteroplasty in 446 patients. *Arch Surg.* 2005;140:504-511, discussion 511-513.
  16. Schlosser W, Rau BM, Poch B, Beger HG. Surgical treatment of pancreas divisum causing chronic pancreatitis: the outcome benefits of duodenum-preserving pancreatic head resection. *J Gastrointest Surg.* 2005;9:710-715.
  17. Warshaw AL, Simeone JF, Schapiro RH, Flavin-Warshaw B. Evaluation and treatment of the dominant dorsal duct syndrome (pancreas divisum redefined). *Am J Surg.* 1990;159:59-64, discussion 66.
  18. Delhay M, Engelholm L, Cremer M. Pancreas divisum: congenital anatomic variant or anomaly? Contribution of endoscopic retrograde dorsal pancreatography. *Gastroenterology.* 1985;89:951-958.
  19. Kamisawa T. Clinical significance of the minor duodenal papilla and accessory pancreatic duct. *J Gastroenterol.* 2004;39:605-615.
  20. Khalid A, Slivka A. Pancreas divisum. *Curr Treat Options Gastroenterol.* 2001;4:389-399.
  21. Liao Z, Gao R, Wang W, Ye Z, Lai XW, Wang XT, et al. A systematic review on endoscopic detection rate, endotherapy, and surgery for pancreas divisum. *Endoscopy.* 2009;41:439-444.
  22. Choudari CP, Imperiale TF, Sherman S, Fogel E, Lehman GA. Risk of pancreatitis with mutation of the cystic fibrosis gene. *Am J Gastroenterol.* 2004;99:1358-1363.
  23. Schneider L, Muller E, Hinz U, Grenacher L, Buchler MW, Werner J. Pancreas Divisum: A Differentiated Surgical Approach in Symptomatic Patients. *World J Surg.* 2011;35:1360-136.