

# MUSCULOSKELETAL SURGERY

## FLUOROSCOPIC FREE HAND AND ELECTROMAGNETIC-GUIDED TARGETING SYSTEM FOR DISTAL LOCKING SCREWS OF HUMERAL INTRAMEDULLARY NAIL.

--Manuscript Draft--

<b>Manuscript Number:</b>	MUSC-D-16-00063R1
<b>Full Title:</b>	FLUOROSCOPIC FREE HAND AND ELECTROMAGNETIC-GUIDED TARGETING SYSTEM FOR DISTAL LOCKING SCREWS OF HUMERAL INTRAMEDULLARY NAIL.
<b>Article Type:</b>	Original Article
<b>Keywords:</b>	Interlocking screw, Humeral trauma, Radiation free, Radiation exposure, Intramedullary nail, Electromagnetic guided.
<b>Corresponding Author:</b>	pietro persiani, PhD MD Sapienza, University of Rome rome, italy ITALY
<b>Corresponding Author Secondary Information:</b>	
<b>Corresponding Author's Institution:</b>	Sapienza, University of Rome
<b>Corresponding Author's Secondary Institution:</b>	
<b>First Author:</b>	pietro persiani, PhD MD
<b>First Author Secondary Information:</b>	
<b>Order of Authors:</b>	pietro persiani, PhD MD giorgio di Giacomo ciro villani michele dario Gurzi oreste moreschini
<b>Order of Authors Secondary Information:</b>	
<b>Funding Information:</b>	
<b>Abstract:</b>	<p><b>Abstract</b></p> <p><b>Purpose</b> The current techniques used to lock distal screws for the nailing of long bone fractures exposes the surgeons, radiologists and patients to a hearty dose of ionizing radiation. The Sureshot™ Distal Targeting System is a new technique that, with the same results, allows for shorter surgery times and, consequently, less exposure to radiation.</p> <p><b>Materials and Methods</b> The study was performed on 59 patients (34 males and 25 females) with a simple humerus fracture diagnosis, type 1.2.A according to the AO classification, who were divided into 2 groups. Group 1 was treated with ante-grade in-tramedullary nailing with distal locking screws inserted with a free hand technique. Group 2 was treated with the in-tramedullary nail using the Sureshot™ Distal Targeting System. Two intra-operative time parameters were evaluated in both groups: the time needed for the positioning of the distal locking screws and the time of exposure to ionizing radiations during this procedure.</p> <p><b>Results</b> Group 2 showed a lower average distal locking time compared to group 1 (645.48" vs 1023.57"), and also a lower average time of exposure to ionizing radiation than in group 1 (4.35" vs. 28,96").</p> <p><b>Conclusions</b> The Sureshot™ Distal Targeting System has proven to be equally effective when compared to the traditional techniques, with the added benefits of a significant</p>

	reduction of both surgical time and risk factors related to the exposure to ionizing radiation for all the operating room staff and the patient.
<b>Response to Reviewers:</b>	<p>We hope that the review on the text of our work can meet your interest and satisfaction.</p> <p>Thanks in advance.</p> <p>Pietro Persiani Ciro Villani Oreste Moreschini Michele Gurzi Giorgio di Giacomo</p>

PERSIANI PIETRO MD PhD, GURZI MICHELE MD, MORESCHINI ORESTE MD, DI GIACOMO GIORGIO MD, VILLANI CIRO MD

Department of Anatomical Sciences, Histological, Forensic Medicine and Locomotive System  
Sapienza University of Rome Piazzale Aldo Moro n ° 5, Rome, Italy.

## FLUOROSCOPIC FREE HAND AND ELECTROMAGNETIC-GUIDED TARGETING SYSTEM FOR DISTAL LOCKING SCREWS OF HUMERAL INTRAMEDULLARY NAIL.

AUTHOR CORRESPONDENT: PIETRO PERSIANI

Department of Orthopaedics and Traumatology University Sapienza, Piazzale Aldo Moro n ° 5, Rome, Italy.  
ppersiani@me.com

### Abstract

#### Purpose

The current techniques used to lock distal screws for the nailing of long bone fractures exposes the surgeons, radiologists and patients to a hearty dose of ionizing radiation. The Sureshot™ Distal Targeting System is a new technique that, with the same results, allows for shorter surgery times and, consequently, less exposure to radiation.

#### Materials and Methods

The study was performed on 59 patients (34 males and 25 females) with a simple humerus fracture diagnosis, type 1.2.A according to the AO classification, who were divided into 2 groups. Group 1 was treated with ante-grade intramedullary nailing with distal locking screws inserted with a free hand technique. Group 2 was treated with the intramedullary nail using the Sureshot™ Distal Targeting System. Two intra-operative time parameters were evaluated in both groups: the time needed for the positioning of the distal locking screws and the time of exposure to ionizing radiations during this procedure.

#### Results

Group 2 showed a lower average distal locking time compared to group 1 (645.48" vs 1023.57"), and also a lower average time of exposure to ionizing radiation than in group 1 (4.35" vs. 28,96").

#### Conclusions

The Sureshot™ Distal Targeting System has proven to be equally effective when compared to the traditional techniques, with the added benefits of a significant reduction of both surgical time and risk factors related to the exposure to ionizing radiation for all the operating room staff and the patient.

Interlocking screw, Humeral trauma, Radiation free, Radiation exposure, Intramedullary nail, Electromagnetic guided.

PERSIANI PIETRO MD PhD, GURZI MICHELE MD, MORESCHINI ORESTE MD, DI GIACOMO GIORGIO MD, VILLANI CIRO MD

Department of Anatomical Sciences, Histological, Forensic Medicine and Locomotive System  
Sapienza University of Rome Piazzale Aldo Moro n ° 5, Rome, Italy.

FLUOROSCOPIC FREE HAND AND ELECTROMAGNETIC-GUIDED TARGETING SYSTEM FOR DISTAL LOCKING SCREWS OF HUMERAL INTRAMEDULLARY NAIL.

AUTHOR CORRESPONDENT: PIETRO PERSIANI

Department of Orthopaedics and Traumatology University Sapienza, Piazzale Aldo Moro n ° 5, Rome, Italy.  
ppersiani@me.com

#### Abstract

##### Purpose

The current techniques used to lock distal screws for the nailing of long bone fractures exposes the surgeons, radiologists and patients to a hearty dose of ionizing radiation. The Sureshot™ Distal Targeting System is a new technique that, with the same results, allows for shorter surgery times and, consequently, less exposure to radiation.

##### Materials and Methods

The study was performed on 59 patients (34 males and 25 females) with a simple humerus fracture diagnosis, type 1.2.A according to the AO classification, who were divided into 2 groups. Group 1 was treated with ante-grade intramedullary nailing with distal locking screws inserted with a free hand technique. Group 2 was treated with the intramedullary nail using the Sureshot™ Distal Targeting System. Two intra-operative time parameters were evaluated in both groups: the time needed for the positioning of the distal locking screws and the time of exposure to ionizing radiations during this procedure.

##### Results

Group 2 showed a lower average distal locking time compared to group 1 (645.48" vs 1023.57"), and also a lower average time of exposure to ionizing radiation than in group 1 (4.35" vs. 28,96").

##### Conclusions

The Sureshot™ Distal Targeting System has proven to be equally effective when compared to the traditional techniques, with the added benefits of a significant reduction of both surgical time and risk factors related to the exposure to ionizing radiation for all the operating room staff and the patient.

Interlocking screw, Humeral trauma, Radiation free, Radiation exposure, Intramedullary nail, Electromagnetic guided.

#### **Compliance with Ethical Standards:**

**Conflict of Interest: Pietro Persiani declares that he has no conflict of interest. Michele Gurzi declares that he has no conflict of interest. Oreste Moreschini declares that he has no conflict of interest. Giorgio Di Giacomo declares that he has no conflict of interest. Ciro Villani declares that he has no conflict of interest.**

**Ethical approval: All procedures performed in studies involving human participants were in accordance with the ethical standards of the institutional and/or national research committee and with the 1964 Helsinki declaration and its later amendments or comparable ethical standards.**

**Informed consent: This is a retrospective study based on the analysis of the data present in the operating room records, there has been no contact with patients. Informed consent regarding the collection and analysis of data related to the surgery was obtained from all individual participants included in the study.**

## INTRODUCTION

Internal fixation with intramedullary nailing is one of the most used techniques in the treatment of diaphyseal fractures of the humerus and long bones in general; it offers great advantages, including indirect reduction and preservation of soft tissues and the fracture hematoma. The positioning of the distal locking screws remains, however, a procedure that has long surgical times and exposes the surgeon, and the patient, to high doses of ionizing rays [1-16], leading to numerous diseases, including thyroid cancer [4].

The traditional technique consists in the freehand insertion of the screws under fluoroscopic control [17-21]; this technique requires sufficient experience and skill from both the surgeon and the radiographer.

The Sureshot™ Distal Targeting System (Smith & Nephew, Inc., Memphis, TN, USA) is a new centring system for the distal locking of intramedullary nails, which uses computer technology based on electromagnetic fields. The advantages of this feature are: the reduced exposure to ionizing radiation for both patient and surgeon [22-27], the reduced potential of placement errors of the distal screws and the reduced surgical time [28-31].

The aim of our study is to analyze in a retrospective view the results obtained in humeral shaft fracture treated with The Sureshot™ Distal Targeting System compared to the same device but using the more traditional free hand technique for distal screw fixation, to assess the efficiency of this last device to reduce the exposition time to ionizing radiation.

## MATERIALS AND METHODS

Our work is a non-randomized control group study analysed in a retrospective view, based on the study of medical and surgical records. Our study sample is composed of 59 non-consecutive patients (34 males and 25 females, average age 41, age range 34-47) with a simple humerus fracture diagnosis, types 1.2.A.1, 1.2.A.2 and 1.2.A.3 according to the AO classification. All these cases were these patients were treated between February 2013 and February 2016, at the -----.

In all cases included in this study the ante-grade humeral intramedullary nail (Trigen Smith & Nephew, Inc., Memphis, TN, USA) was used. The sample involved in the study, although analysed retrospectively, was homogeneous and treated by two experienced operators (PP, OM) with a long experience in the repair of humeral fractures.

Our sample was divided in two groups according to the used or not of the Sureshot™ Distal Targeting System.

Additional inclusion criteria for our study sample were: absence of pathological fractures; diagnosis of a simple fracture according to the AO classification; absence of neurological deficits; absence of poly-traumas, use of the Sureshot™ Distal Targeting System.

The chosen between freehand technique and distal targeting system was made according to the skill of surgeon with the new system, as result during the first part of the period considered most of the patients were treated with the freehand technique and are non-consecutive, on the opposite the patients treated in the last part of this period were all treated with the Sureshot™ Distal Targeting System.

Thus, the two groups compared in our study were composed as follow (Table 1):

Group 1 was the control group, it include 28 patients treated with a 16 cm intramedullary nail (Trigen™ nails, Smith & Nephew, Inc., Memphis, TN, USA) with distal locking screws inserted with a freehand technique: positioning the image intensifier perpendicularly to the arm supported by the aid, a centred incision is performed on the locking hole and the bone surface is reached in a blunt manner; the first cortex is drilled; the drill is then removed and the antero-posterior positioning of the cutter in correspondence of the locking hole is checked; if the position is correct one can proceed up to the second cortex; the length is measured and is controlled laterally, the nailing screw is then placed and its correct positioning and length are antero-posteriorly checked. The procedure is then repeated for the second screw.

Group 2 was the study group, it include 31 patients treated with a 16 cm ante-grade intramedullary nail (Trigen™ nails, Smith & Nephew, Inc., Memphis, TN, USA) using the Sureshot™ Distal Targeting System for the distal locking. All the locking procedures were done by two of the authors with an already acquired learning curve. When making a comparison with Group 1, there was no change in the arrangement and organization of the operating room.

The targeting system consists of three main parts: a computerized control unit (fig. 1), located within the display screen, a donut-shaped free hand pointer that produces a concentrated electromagnetic field and a sensor probe (fig. 2), inserted in the nail, which transmits the position information to the control unit.

The system then plays back a virtual image of the distal part of the nail in real time. A 12mm drill is positioned at the centre of the pointer. A trajectory line appears on the display in real time, connecting two coloured circles (Figure 2), which represent the tip of the drill and the centre of the pointer: the alignment of the circles provides the ideal direction for drilling and screw insertion. The skin is incised on the indicated site and a calibrated drill is connected through the guiding-sleeve. The correct position of the screws was evaluated intra-operatively with fluoroscopy after insertion.

Two intra-operative temporal parameters were timed in both groups: the time, measured in seconds, for the correct positioning of the distal locking screws (from the time when the nail is positioned to the last antero-posterior check-up

for the evaluation on the correct placement of the screws); the time, measured in seconds, of exposure to ionizing radiation during this procedure (automatically calculated by the Siemens model fluoroscopic image intensifier).

The evaluation of the data was performed by running the Student's t-test for normal continuous data for two independent samples by means of the SPSS 20 statistical software (IBM statistics).

## RESULTS

In group 1 (free hand), the average time for the distal locking was 28.96 seconds (range of 16-39, S.D: 8,401), and the average time of exposure was 1023.57 seconds (range of seconds 510-1400, S.D: 429,317 ).

In group 2, the average time for the distal locking was 4.35 seconds (range of 2-8 S.D: 1,799), and the average time of exposure was 645.48 seconds (range of seconds 310-1110, S.D 210,093).

For both the parameters assessed within the two groups there was a significant statistical difference  $p$ -value  $<0.001$  (Table 2).

There were no immediate complications in the two groups; since our study focuses on the analysis of surgery times and radiation exposure, there is no value, at this stage, in assessing the long-term complications.

## DISCUSSION

Both the *free hand* distal locking and the Targeting System techniques achieved a correct positioning of the implant at the end of the surgery.

In group 2, the exposure to ionizing radiation was significantly lower, reducing the risky and occupational exposure that surgeons are subject to [30-33]. Amongst the orthopedic procedures with fluoroscopy, intramedullary nailing of long bones is considered the one with the highest exposure to radiation [8]. During these surgeries, the distal locking of the intramedullary nail is the phase with the higher percentage of exposure to radiation, reaching as much as 50% [1]. Recent studies have revealed an increased risk of cancer, mostly due to radiation exposure, among orthopedic surgeons [14-15].

Literature data on the Sureshot™ system report an accuracy of between 96% and 100%, with a decrease of the average irradiation time from 36 to 13 seconds and from 49 to 25 seconds for the locking of the tibia and femur, respectively [34].

In a comparative study with the *free hand* technique on a cadaver, the new technique was equally effective (100% vs. 94% for the tibial nail; 96% for both techniques for the femoral nail) and faster (+ 32% for the femoral nail and + 47.5% for the tibial nail) compared to traditional distal locking [34]. The use of the Sureshot™ technique is currently not able to completely eliminate the use of fluoroscopy, however, it does limit its use to the confirmation of the correct final position of the screws or in case of particular difficulty.

There are many works present in literature regarding distal locking in the nailing of femoral and tibial fractures, and they all are based on the *free hand* method; contrarily, there are few studies that compare the distal locking techniques in progress with intramedullary humeral nailing [35-46].

The main disadvantages are the added cost (the probe used is single-use only) and the fact that the pointer is used “free hand” by the surgeon, without the aid of a support, thus making it unstable and prone to little trajectory changes due to involuntary movements of the surgeon. However, the continuous real time display of the procedure allows for immediate corrections and, consequently, an accurate positioning of the screw on the first attempt (whereas the *free hand* technique usually requires 1-6 attempts), therefore reducing also the surgical and operating room occupancy times, in a statistically significant way.

In any case, larger studies are still needed to evaluate the cost (of the device)/benefit (statistically significant reduction of the surgical time and exposure to ionizing rays).

## CONCLUSION

The Sureshot™ Distal Targeting System has proven to be equally effective when compared to the traditional techniques in 1.2.A.1, 1.2.A.2 and 1.2.A.3 distal humeral fractures (AO classification).

Furthermore, it adds with the benefits of a significant reduction of both surgical time and risk factors related to the exposure to ionizing radiation for all the operating room staff and the patient, thus reducing the incidence of related diseases.


## REFERENCES

1. Levin PE, Schoen Jr RW, Browner BD (1987) Radiation exposure to the surgeon during closed interlocking intramedullary nailing. *Journal of Bone and Joint Surgery* 69:761–6
2. Sugarman ID, Adam I, Bunker TD (1988) Radiation dosage during AO locking femoral nailing. *Injury* 19:336–8
3. Sanders R, Koval KJ, DiPasquale T, Schmelling G, Stenzler S, Ross E (1993) Exposure of the orthopaedic surgeon to radiation. *Journal of Bone and Joint Surgery* 75:326–30
4. Muller LP, Suffner J, Wenda K, Mohr W, Rommens PM (1998) Radiation exposure to the hands and the thyroid of the surgeon during intramedullary nailing. *Injury* 29:461–8
5. Madan S, Blakeway C (2002) Radiation exposure to surgeon and patient in intramedullary nailing of the lower limb. *Injury* 33:723–7
6. Blattert TR, Fill UA, Kunz E, Panzer W, Weckbach A, Regulla DF (2004) Skill dependence of radiation exposure for the orthopaedic surgeon during interlocking nailing of long-bone shaft fractures: a clinical study. *Archives of Orthopaedic and Trauma Surgery* 124:659–64
7. Hafez MA, Smith RM, Matthews SJ, Kalap G, Sherman KP (2005) Radiation exposure to the hands of orthopaedic surgeons: are we underestimating the risk? *Archives of Orthopaedic and Trauma Surgery* 125:330–5
8. Oddy MJ, Aldam CH (2006) Ionising radiation exposure to orthopaedic trainees: the effect of sub-specialty training. *Annals of the Royal College of Surgeons of England* 88:297–301
9. Tsalafoutas IA, Tsapaki V, Kaliakmanis A, Pneumaticos S, Tsoronis F, Koulentianos ED, et al (2008) Estimation of radiation doses to patients and surgeons from various fluoroscopically guided orthopaedic surgeries. *Radiation Protection Dosimetry* 128:112–9
10. Kirousis G, Delis H, Megas P, Lambiris E, Panayiotakis G (2009) Dosimetry during intramedullary nailing of the tibia. *Acta Orthopaedica* 80:568–72
11. Agarwal A (2011) Radiation risk in orthopedic surgery: ways to protect yourself and the patient. *Operative Techniques in Sports Medicine* 19:220–3
12. Giordano BD, Grauer JN, Miller CP, Morgan TL, Rehtine 2nd GR (2011) Radiation exposure issues in orthopaedics. *Journal of Bone and Joint Surgery* 93. e69(1–10)
13. Uzoigwe CE, Middleton RG (2012) Occupational radiation exposure and pregnancy in orthopaedics. *Journal of Bone and Joint Surgery British Volume* 94: 23–7
14. Mastrangelo G, Fedeli U, Fadda E, Giovanazzi A, Scoizzato L, Saia B (2005) Increased cancer risk among surgeons in an orthopaedic hospital. *Occupational Medicine (Lond)* 55:498–500
15. Chou LB, Cox CA, Tung JJ, Harris AH, Brooks-Terrell D, Sieh W (2010) Prevalence of cancer in female orthopaedic surgeons in the United States. *Journal of Bone and Joint Surgery* 92:240–4
16. Coetzee JC, van der Merwe EJ (1992) Exposure of surgeons-in-training to radiation during intramedullary fixation of femoral shaft fractures. *South African Medical Journal* 81:312–4
17. Hashemi-Nejad A, Garlick N, Goddard NJ (1994) A simple jig to ease the insertion of distal screws in intramedullary locking nails. *Injury* 25:407–8

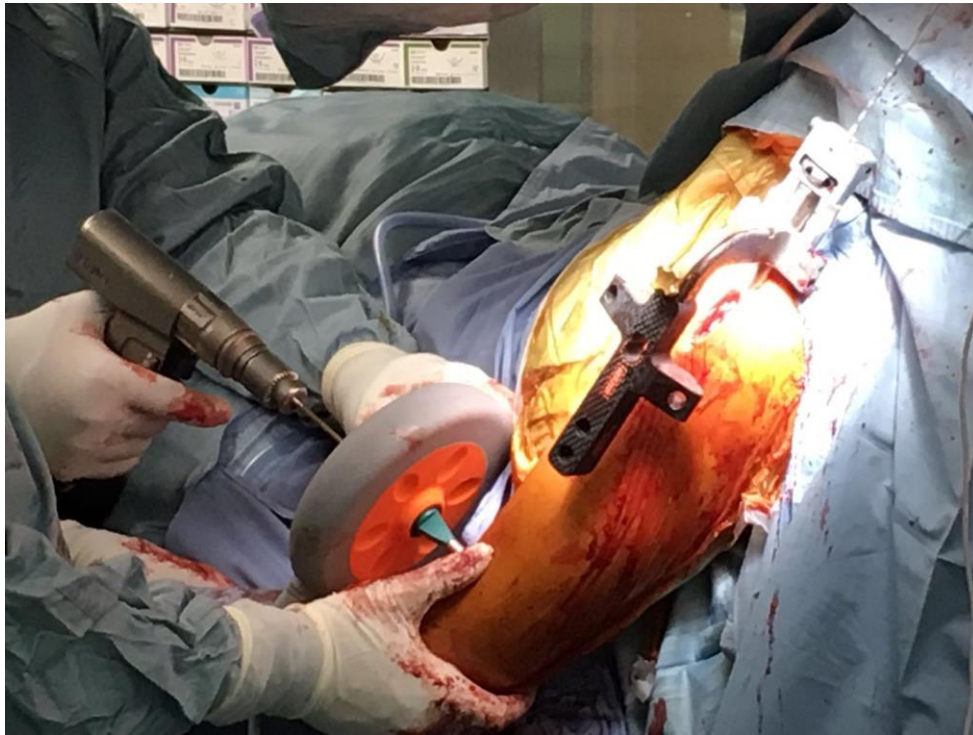
18. Krettek C, Konemann B, Miclau T, Kolbli R, Machreich T, Kromm A, et al (1998) A new mechanical aiming device for the placement of distal interlocking screws in femoral nails. *Archives of Orthopaedic and Trauma Surgery* 117:147–52
19. Goodall JD (1991) An image intensifier laser guidance system for the distal locking of an intramedullary nail. *Injury* 22:339
20. Knudsen CJ, Grobler GP, Close RE (1991) Inserting the distal screws in a locked femoral nail. *Journal of Bone and Joint Surgery British Volume* 73:660–1
21. Gugala Z, Nana A, Lindsey RW (2001) Tibial intramedullary nail distal interlocking screw placement: comparison of the free-hand versus distally-based targeting device techniques. *Injury* 32(Suppl. 4):SD21–5
22. Pardiwala D, Prabhu V, Dudhniwala G, Katre R (2001) The AO distal locking aiming device: an evaluation of efficacy and learning curve. *Injury* 32:713–8
23. Krettek C, Konemann B, Miclau T, Schandelmaier P, Blauth M, Tscherner H (1997) A new technique for the distal locking of solid AO unreamed tibial nails. *Journal of Orthopaedic Trauma* 11:446–51
24. Tyropoulos S, Garnavos C (2001) A new distal targeting device for closed interlocking nailing. *Injury* 32:732–5
25. Arlettaz Y, Akiki A, Chevalley F, Leyvraz PF (2008) Targeting device for intramedullary nails: a new high-stable mechanical guide. *Injury* 39:170–5
26. Karachalios T, Babis G, Tsarouchas J, Sapkas G, Pantazopoulos T (2000) The clinical performance of a small diameter tibial nailing system with a mechanical distal aiming device. *Injury* 31:451–9
27. Slomczykowski MA, Hofstetter R, Sati M, Krettek C, Nolte LP (2001) Novel computer-assisted fluoroscopy system for intraoperative guidance: feasibility study for distal locking of femoral nails. *Journal of Orthopaedic Trauma* 15:122–31
28. Whatling GM, Nokes LD (2006) Literature review of current techniques for the insertion of distal screws into intramedullary locking nails. *Injury* 37:109–19
29. Pennig D, Brug E, Kronholz HL (1988) A new distal aiming device for locking nail fixation. *Orthopedics* 11:1725–7
30. Suhm N, Jacob AL, Nolte LP, Regazzoni P, Messmer P (2000) Surgical navigation based on fluoroscopy – clinical application for computer-assisted distal locking of intramedullary implants. *Computer Aided Surgery* 5:391–400
31. Zhu Y, Chang H, Yu Y, Chen W, Liu S, Zhang Y (2016) Meta-analysis suggests that the electromagnetic technique is better than the free-hand method for the distal locking during intramedullary nailing procedures. *Int Orthop*. 2016 Jun 2. [Epub ahead of print]
32. Stathopoulos I, et al (2012) Radiation-free distal locking of intramedullary nails: Evaluation of a new electromagnetic computer-assisted guidance system. *Injury*, DOI: <http://dx.doi.org/10.1016/j.injury.2012.08.051>
33. Maqungo S, Horn A, Bernstein B, Keel M, Roche S (2014) Distal interlocking screw placement in the femur: free-hand versus electromagnetic assisted technique (sureshot). *J Orthop Trauma*. 2014 Dec;28(12):e281-3. doi: 10.1097/BOT.000000000000125.
34. Tornetta P, Pattel P, Tseng S, Whitten A, Ricci W (2009) Distal locking using an electromagnetic field guided computer based real time system. Presented at Orthopaedic Trauma Association (OTA) Annual Meeting, San Diego, CA



35. Anastopoulos G, Ntagiopoulos PG, Chissas D, Loupasis G, Asimakopoulos A, Athanaselis E, et al (2008) Evaluation of the Stryker S2 IM Nail Distal Targeting Device for reduction of radiation exposure: a case series study. *Injury* 39:1210–5
36. Anastopoulos G, Ntagiopoulos PG, Chissas D, Papaeliou A, Asimakopoulos A (2008) Distal locking of tibial nails: a new device to reduce radiation exposure. *Clinical Orthopaedics and Related Research* 466:216–20
37. Suhm N, Messmer P, Zuna I, Jacob LA, Regazzoni P (2004) Fluoroscopic guidance versus surgical navigation for distal locking of intramedullary implants. A prospective, controlled clinical study. *Injury* 35:567–74
38. Malek S, Phillips R, Mohsen A, Viant W, Bielby M, Sherman K (2005) Computer assisted orthopaedic surgical system for insertion of distal locking screws in intramedullary nails: a valid and reliable navigation system. *International Journal of Medical Robotics* 1:34–44
39. Leloup T, El Kazzi W, Schuind F, Warzee N (2008) A novel technique for distal locking of intramedullary nail based on two non-constrained fluoroscopic images and navigation. *IEEE Transactions on Medical Imaging* 27:1202–12
40. Windolf M, Schroeder J, Fliri L, Dicht B, Liebergall M, Richards G (2012) Reinforcing the role of the conventional C-arm – a novel method for simplified distal interlocking. *BMC Musculoskeletal Disorders* 13:8
41. Yaniv Z, Joskowicz L (2005) Precise robot-assisted guide positioning for distal locking of intramedullary nails. *IEEE Transactions on Medical Imaging* 24:624–35
42. Schandelmaier P, Krettek C, Tscherne H (1996) Biomechanical study of nine different tibia locking nails. *Journal of Orthopaedic Trauma* 10:37–44
43. Krettek C, Konemann B, Miclau T, Schandelmaier P, Blauth M, Tscherne H (1997) In vitro and in vivo radiomorphometric analyses of distal screw hole position of the solid tibial nail following insertion. *Clinical Biomechanics (Bristol Avon)* 12:198–200
44. Krettek C, Mannss J, Konemann B, Miclau T, Schandelmaier P, Tscherne H (1997) The deformation of small diameter solid tibial nails with unreamed intramedullary insertion. *Journal of Biomechanics* 30:391–4
45. Krettek C, Mannss J, Miclau T, Schandelmaier P, Linnemann I, Tscherne H (1998) Deformation of femoral nails with intramedullary insertion. *Journal of Orthopaedic Research* 16:572–5
46. Kanellopoulos AD, Yiannakopoulos CK, Vossinakis I, Badras LS (2003) Distal locking of femoral nails under direct vision through a cortical window. *Journal of Orthopaedic Trauma* 17:574–7



**Fig. 1** Computerized control unit



**Fig. 2** Donut-shaped free hand pointer and sensor probe

Table 1 – Partition of the 2 groups

	Overall x-ray exposure (sec)		Distal screw x-ray exposure (sec)	
	Group1	Group2	Group1	Group2
1	510	310	16	2
2	550	360	16	2
3	550	400	18	2
4	590	440	17	2
5	610	460	18	3
6	650	480	21	3
7	660	480	20	3
8	690	500	22	3
9	700	500	22	3
10	720	510	25	3
11	720	510	26	3
12	730	530	28	3
13	800	550	30	4
14	790	550	30	3
15	910	570	31	4
16	1020	570	36	4
17	1100	600	35	4
18	1110	620	35	4
19	1200	650	34	5
20	1230	700	35	5
21	1340	710	35	5

2 2	1400	740	36	5
2 3	1510	770	36	6
2 4	1550	810	37	6
2 5	1600	840	37	6
2 6	1730	840	38	6
2 7	1790	870	38	6
2 8	1900	920	39	6
2 9	-	1020	16	8
3 0	-	1090	16	8
3 1	-	1110	18	8

Table 2 - Results

<b>Groups</b>		<b>N</b>	<b>Average</b>	<b>Deviation std.</b>	<b>Average errors</b>	<b>std.</b>	<b>Sig. (2- code)</b>
Overall x-ray exposure (sec)	1	28	1023,57	429,317	81,133		,000
	2	31	645,48	210,093	37,734		
Distal screw x-ray exposure (sec)	1	28	28,96	7,946	1,502		,000
	2	31	4,35	1,799	,323		

