

Case
Reports

Open Conversion after Aortic Endograft Infection

Caused by Colistin-Resistant, Carbapenemase-Producing *Klebsiella pneumoniae*

Nunzio Montelione, MD
Danilo Menna, MD
Pasqualino Sirignano, MD
Laura Capoccia, MD
Wassim Mansour, MD
Francesco Speziale, MD

A 62-year-old man presented with fever, abdominal pain, and malaise 13 months after emergency endovascular aortic repair. Computed tomographic angiograms showed a periprosthetic fluid and gas collection, so infection was diagnosed. Open conversion was performed, involving endograft explantation and in situ aortic reconstruction. Cultures and the explanted prosthesis were positive for carbapenemase-producing *Klebsiella pneumoniae*, resistant to colistin. Because of the sparse data on endograft infections caused by this pathogen, we placed the patient on an empiric double-carbapenem regimen for 4 weeks. Symptomatic recovery occurred after 21 days. On the 30th day, we deployed a stent to treat a new pseudoaneurysm. Three years later, the patient had no signs of persistent or recurrent infection. We think that this is the first report of aortic endograft infection caused by colistin-resistant, carbapenemase-producing *K. pneumoniae*. (**Tex Heart Inst J** 2016;43(5):453-7)

Key words: Anti-bacterial agents/therapeutic use; aortic aneurysm, abdominal/surgery; bacterial infections/drug therapy/etiology/microbiology; blood vessel prosthesis implantation/adverse effects; drug therapy, combination; endovascular procedures/adverse effects; *Klebsiella pneumoniae*/drug effects/growth & development; postoperative complications; prosthesis-related infections/diagnosis/drug therapy/microbiology/surgery; treatment outcome

From: Vascular and Endovascular Surgery Division, Department of Surgery, Policlinico Umberto I, Sapienza University of Rome, 00161 Rome, Italy

Address for reprints: Nunzio Montelione, MD, Vascular and Endovascular Surgery Division, Policlinico Umberto I, Sapienza University of Rome, Viale del Policlinico 155, 00161 Rome, Italy

E-mail: nunzio_montelione@hotmail.it

© 2016 by the Texas Heart® Institute, Houston

Endovascular aneurysm repair (EVAR) has become an alternative to aortic surgery and is often the treatment of choice for patients who have favorable anatomy.¹⁻⁴ Results from EVAR can equal or exceed those of open surgery; however, EVAR's higher complication rate necessitates monitoring, in case patients need reintervention.^{5,6} Although one of the least frequent causes of reintervention is infection (incidence, <1% of EVAR cases),⁷⁻⁹ it is associated with high mortality rates for surgically and conservatively treated patients.¹⁰⁻¹⁵ Bloodstream infections caused by carbapenemase-producing *Klebsiella pneumoniae* (CPKP) are typically associated with a mortality rate of 13% to 58%, and few therapeutic options are available.^{16,17}

We present what we think is the first case of aortic endograft infection caused by colistin-resistant CPKP, report the therapeutic regimen and surgical course in a 62-year-old patient, and discuss the relevant medical literature.

Case Report

In September 2011, a 62-year-old man who had arterial hypertension, dyslipidemia, and paroxysmal atrial fibrillation was referred to a vascular center because of sudden-onset lumbar pain and fever. The patient underwent urgent EVAR for an inflammatory abdominal aortic aneurysm. A 31 × 14 × 145-mm GORE® EXCLUDER® endograft (W.L. Gore & Associates, Inc.; Flagstaff, Ariz) was deployed.

After EVAR, the patient's lumbar pain promptly disappeared, but his fever persisted. Blood cultures grew methicillin-resistant *Staphylococcus epidermidis*, and a urine culture contained >100,000 colony-forming units of *Pseudomonas aeruginosa* and *Serratia marcescens*. Examination of the central venous catheter tip used during the EVAR procedure yielded *Candida albicans*. The patient underwent 50 days of specific antibiotic therapy until his fever disappeared, and then he was discharged from the hospital. During his hospitalization, a computed tomographic angiogram (CTA) showed thickening and enhancement of the aortic wall, suggesting a persistent, intense periaortic inflammatory reaction.

In November 2012, the patient was admitted to our hospital with fever (temperature, 38.8 °C), abdominal pain, and malaise. Blood tests revealed mild anemia (hemoglobin, 10.7 g/dL), leukocytosis (white blood cell count, 18.25 ×10⁹/L) with significant neutrophilia (neutrophils, 15.77 ×10³/μL), an elevated serum C-reactive protein level of 27.95 mg/L, and an erythrocyte sedimentation rate of 56 mm/hr.

An emergency CTA showed a perigraft gas collection, consistent with endograft infection (Fig. 1).

Even in the absence of melena, an esophagogastroduodenoscopy was performed, to exclude a secondary aortoenteric fistula. Surgical conversion consisting of endograft explantation and aortic reconstruction was planned.

Surgery was performed through a median xifopubic laparotomy. The juxtarenal aortic wall was substantially inflamed, so suprarenal clamping was necessary. Renal hypothermia was achieved by selective perfusion of the renal arteries (4 °C lactated Ringer solution with 12.5 g/L of mannitol and 125 mg/L of methylprednisolone).¹⁸ The endograft (Fig. 2A) was completely removed, and infrarenal reconstruction was performed in end-to-end fashion with use of a rifampin-soaked, silver-coated Dacron bifurcated graft (Fig. 2B).

During the patient's 9-day postoperative intensive care unit stay, he had fever (temperature, 39 °C) and pneumonia. Blood cultures, bronchoalveolar-lavage fluid samples, and the explanted prosthesis were positive for colistin-resistant CPKP: the minimum inhibitory concentrations of ertapenem, meropenem, and colistin were 128, 256, and ≥ 16 $\mu\text{g/mL}$, respectively. In accordance with the available medical literature,¹⁷ empiric therapy with fosfomycin (3 g, 4 \times /d) and tigecycline (50 mg, 2 \times /d) was started; however, the fever and positive cultures persisted.

An experimental protocol at our hospital enabled the intravenous administration of ertapenem (1 g/d) for 4 weeks and meropenem (2 g, 3 \times /d). The patient's fever completely resolved after 21 days of this regimen. On

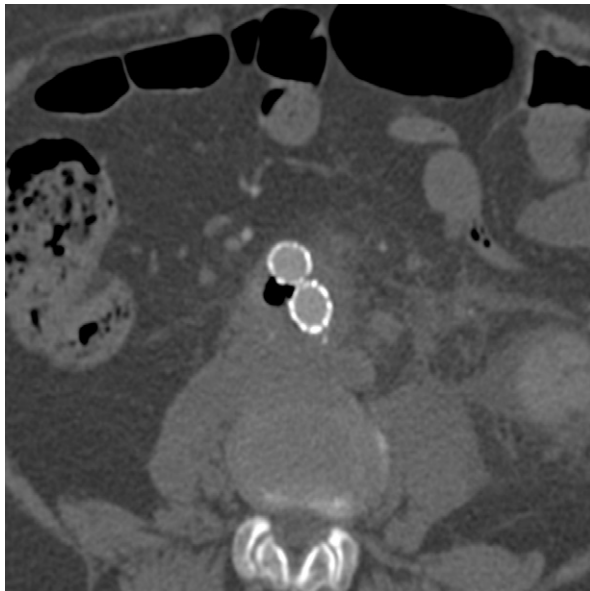


Fig. 1 Preoperative computed tomographic angiogram shows periprosthetic fluid and gas collections associated with inflammation of the aortic wall.

the 30th day, a CTA showed nothing unusual except a distal right anastomotic pseudoaneurysm (maximum diameter, 18 mm). We successfully treated the pseudoaneurysm by means of percutaneous endovascular relining, with use of an 11 \times 90-mm Zenith[®] iliac leg (Cook Medical Inc.; Bloomington, Ind). The patient recovered uneventfully, had normal hematologic test results, and was discharged from the hospital 7 days postprocedurally.

Follow-up clinical examinations and laboratory tests were scheduled at 6 weeks; 3, 6, and 12 months; and annually thereafter. Monitoring with CTA was performed at 6, 12, and 24 months. At the patient's 3-year follow-up evaluation, he was in good clinical condition,

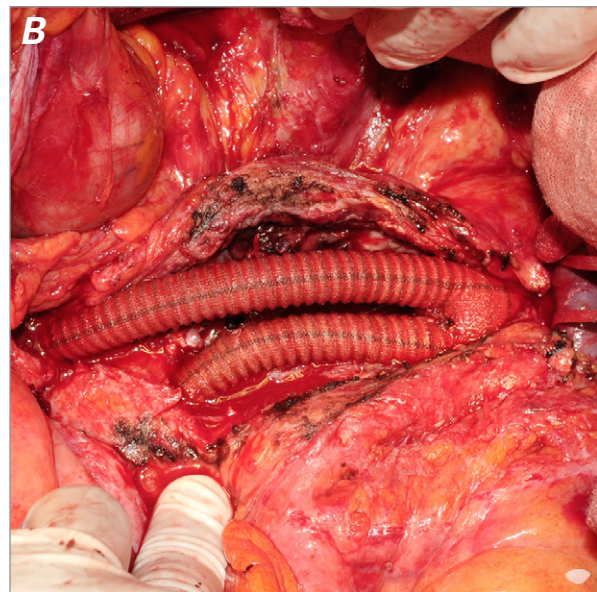
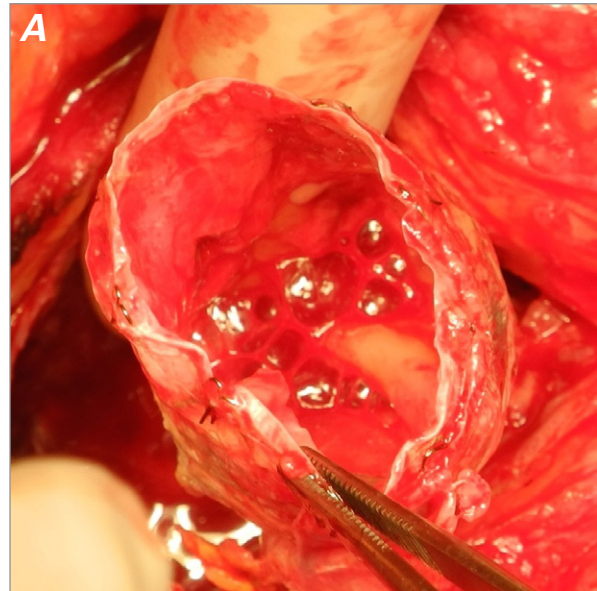


Fig. 2 Intraoperative photographs show **A**) evidence of graft infection and **B**) the completed reconstruction.

with no laboratory or radiologic signs of persistent or recurrent infection (Fig. 3).

Discussion

The incidence of endograft infection after EVAR has been reported in major series as 0.2% to 0.9%,^{7,8,12-15} although the actual rate is difficult to estimate.¹⁹ Those percentages might rise, given the projected increases in numbers of EVAR procedures.

The absence of a standardized follow-up protocol and the heterogeneous, nonspecific symptoms in the early

phase of endograft infection can cause extensive delays in final diagnosis. Accordingly, at the time of treatment, patients often present in poor clinical condition and with a poor prognosis.¹⁹

When open conversion is planned in these patients, high surgical risk is posed by their typically older age and poor clinical condition, by suprarenal or suprarenal aortic clamping, and by the technical challenges of endograft removal, especially in nonelective circumstances.¹² The high mortality rates reported in all series thus far are of great concern. In one report, 16% of patients who underwent extra-anatomic reconstruction died, compared with 5.8% who had in situ reconstruction.⁷ For these reasons, less invasive treatments have been recommended for patients who have severe underlying diseases.⁷⁻¹³ Results in those cases seem somewhat inferior to those in complete excision. Hart and colleagues²⁰ found a 13% rate of recurrent infection in patients who underwent complete graft excision and a 27% rate in those who underwent partial graft salvage. The postoperative mortality rates were 27% and 40% in the 2 treatment groups, respectively. These discouraging results are compounded by the lack of a specific and effective antibiotic therapy. In fact, microbiologic tests are negative in approximately 30% of cases, and a multibacterial cause has been reported in approximately 20% of endograft infections.²¹ Therefore, even after successful surgical endograft removal, concerns exist about proper antibiotic protocols. In accordance with accumulated knowledge about treating aortic-graft infections,²²⁻²⁷ we chose to perform complete endograft excision and in situ aortic reconstruction in our patient.

Microbiologic tests of our patient's explanted endograft revealed a very rare microorganism. Sepsis from CPKP is associated with a high mortality rate (13%–58%).^{16,17} Results are even worse when colistin resistance is detected,²⁸ because colistin is the core component of several therapeutic combinations.²⁹ Patients who had sepsis caused by colistin-resistant CPKP had a significantly higher mortality rate than did patients who had colistin-susceptible CPKP infections (40.6% vs 20.3%; $P=0.04$).²⁸

Some authors have reported successful results from a double-carbapenem regimen (ertapenem and either meropenem or doripenem).³⁰⁻³³ Ertapenem activity is greatly affected by carbapenemases, so it might act as a suicide substrate. After the carbapenemase receptors have been bound by ertapenem, the second carbapenem (meropenem or doripenem) can then exert its antimicrobial activity.^{31,34}

Because of the sparse data on endograft infections caused by colistin-resistant CPKP, we treated our patient with ertapenem and meropenem. The double-carbapenem regimen induced a clinical response (initial defervescence), and a microbiologic response (no growth in blood cultures) 48 hours after antibiotic therapy was

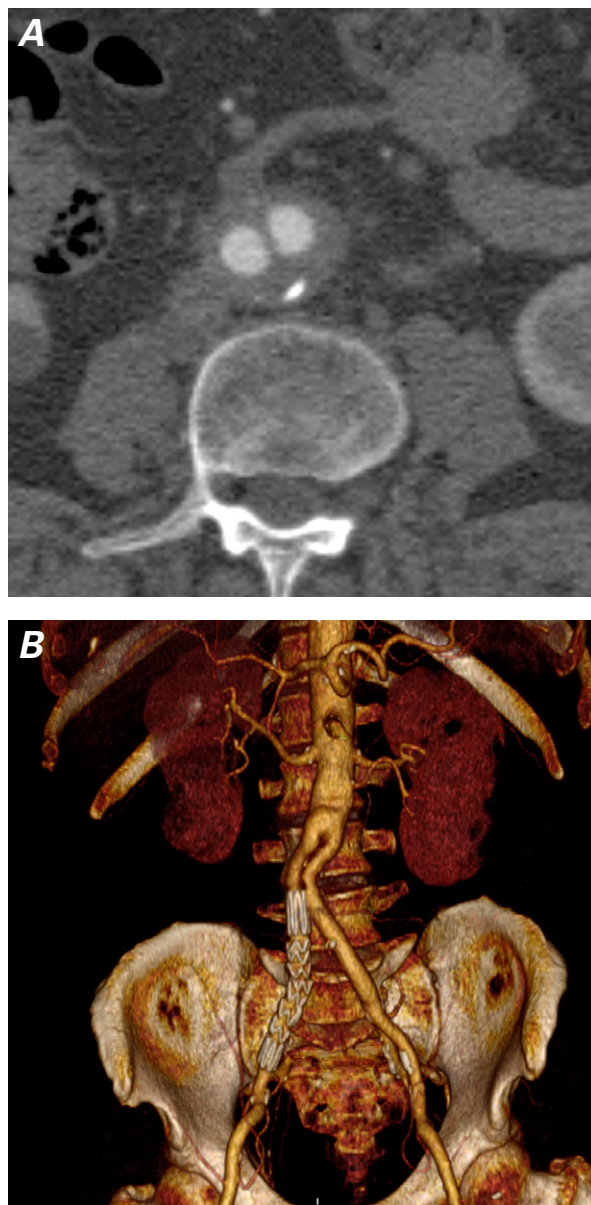


Fig. 3 At the 3-year follow-up evaluation, computed tomographic angiograms show **A**) no evidence of recurrent infection (axial view), and **B**) good graft patency and correct positioning of the right iliac stent-graft (volume-rendered 3-dimensional reconstruction).

started. Complete regression of symptoms occurred in 21 days. The distal anastomotic pseudoaneurysm was detected during the scheduled 30-day CTA and was treated by deploying another endograft. Placing another graft in a recently infected anatomic field could have been hazardous, but we proceeded because the patient was judged to be clinically well and free from infection. The combined surgical removal of the endograft and the new pharmacologic treatment protocol provided a satisfactory result in our patient.

References

- Greenhalgh RM, Brown LC, Kwong GP, Powell JT, Thompson SG; EVAR trial participants. Comparison of endovascular aneurysm repair with open repair in patients with abdominal aortic aneurysm (EVAR trial 1), 30-day operative mortality results: randomised controlled trial. *Lancet* 2004;364(9437):843-8.
- Prinssen M, Verhoeven EL, Buth J, Cuypers PW, van Sambeek MR, Balm R, et al. A randomized trial comparing conventional and endovascular repair of abdominal aortic aneurysms. *N Engl J Med* 2004;351(16):1607-18.
- Lederle FA, Freischlag JA, Kyriakides TC, Padberg FT Jr, Matsumura JS, Kohler TR, et al. Outcomes following endovascular vs open repair of abdominal aortic aneurysm: a randomized trial. *JAMA* 2009;302(14):1535-42.
- Chaikof EL, Brewster DC, Dalman RL, Makaroun MS, Illig KA, Sicard GA, et al. The care of patients with an abdominal aortic aneurysm: the Society for Vascular Surgery practice guidelines. *J Vasc Surg* 2009;50(4 Suppl):S2-49.
- Sampram ES, Karafa MT, Mascha EJ, Clair DG, Greenberg RK, Lyden SP, et al. Nature, frequency, and predictors of secondary procedures after endovascular repair of abdominal aortic aneurysm. *J Vasc Surg* 2003;37(5):930-7.
- Hobo R, Buth J; EUROSTAR collaborators. Secondary interventions following endovascular abdominal aortic aneurysm repair using current endografts. A EUROSTAR report. *J Vasc Surg* 2006;43(5):896-902.
- Ducasse E, Calisti A, Speziale F, Rizzo L, Misuraca M, Fiorani P. Aortoiliac stent graft infection: current problems and management. *Ann Vasc Surg* 2004;18(5):521-6.
- Sharif MA, Lee B, Lau LL, Ellis PK, Collins AJ, Blair PH, Soong CV. Prosthetic stent graft infection after endovascular abdominal aortic aneurysm repair. *J Vasc Surg* 2007;46(3):442-8.
- Hobbs SD, Kumar S, Gilling-Smith GL. Epidemiology and diagnosis of endograft infection. *J Cardiovasc Surg (Torino)* 2010;51(1):5-14.
- Fiorani P, Speziale F, Calisti A, Misuraca M, Zaccagnini D, Rizzo L, Giannoni MF. Endovascular graft infection: preliminary results of an international enquiry. *J Endovasc Ther* 2003;10(5):919-27.
- Brinster CJ, Fairman RM, Woo EY, Wang GJ, Carpenter JP, Jackson BM. Late open conversion and explantation of abdominal aortic stent grafts. *J Vasc Surg* 2011;54(1):42-6.
- Kelso RL, Lyden SP, Butler B, Greenberg RK, Eagleton MJ, Clair DG. Late conversion of aortic stent grafts. *J Vasc Surg* 2009;49(3):589-95.
- Laser A, Baker N, Rectenwald J, Eliason JL, Criado-Pallares E, Upchurch GR Jr. Graft infection after endovascular abdominal aortic aneurysm repair. *J Vasc Surg* 2011;54(1):58-63.
- Heyer KS, Modi P, Morasch MD, Matsumura JS, Kibbe MR, Pearce WH, et al. Secondary infections of thoracic and abdominal aortic endografts. *J Vasc Interv Radiol* 2009;20(2):173-9.
- Phade SV, Keldahl ML, Morasch MD, Rodriguez HE, Pearce WH, Kibbe MR, Eskandari MK. Late abdominal aortic endograft explants: indications and outcomes. *Surgery* 2011;150(4):788-95.
- Munoz-Price LS, Poirel L, Bonomo RA, Schwaber MJ, Dzikos GL, Cormican M, et al. Clinical epidemiology of the global expansion of *Klebsiella pneumoniae* carbapenemases. *Lancet Infect Dis* 2013;13(9):785-96.
- Tumbarello M, Viale P, Viscoli C, Treccarichi EM, Tumietto F, Marchese A, et al. Predictors of mortality in bloodstream infections caused by *Klebsiella pneumoniae* carbapenemase-producing *K. pneumoniae*: importance of combination therapy. *Clin Infect Dis* 2012;55(7):943-50.
- Lemaire SA, Jones MM, Conklin LD, Carter SA, Criddell MD, Wang XL, et al. Randomized comparison of cold blood and cold crystalloid renal perfusion for renal protection during thoracoabdominal aortic aneurysm repair. *J Vasc Surg* 2009;49(1):11-9.
- Capoccia L, Mestres G, Riambau V. Current technology for the treatment of infection following abdominal aortic aneurysm (AAA) fixation by endovascular repair (EVAR). *J Cardiovasc Surg (Torino)* 2014;55(3):381-9.
- Hart JP, Eginton MT, Brown KR, Seabrook GR, Lewis BD, Edmiston CE Jr, et al. Operative strategies in aortic graft infections: is complete graft excision always necessary? *Ann Vasc Surg* 2005;19(2):154-60.
- Cernohorsky P, Reijnen MM, Tielliu IF, van Sterkenburg SM, van den Dungen JJ, Zeebregts CJ. The relevance of aortic endograft prosthetic infection. *J Vasc Surg* 2011;54(2):327-33.
- Menna D, Capoccia L, Sirignano P, Esposito A, Rossi M, Speziale F. Infective etiology affects outcomes of late open conversion after failed endovascular aneurysm repair. *J Endovasc Ther* 2015;22(1):110-5.
- Liberatore M, Misuraca M, Calandri E, Rizzo L, Speziale F, Iurilli AP, Anagnostou C. White blood cell scintigraphy in the diagnosis of infection of endovascular prostheses within the first month after implantation. *Med Sci Monit* 2006;12(3):MT5-9.
- Speziale F, Rizzo L, Fadda GF, Fiorani P, Alfani D, Rossi M. Surgical approach for the treatment of secondary aortoenteric fistulae. *Eur J Vasc Endovasc Surg* 1998;16(6):530-4.
- Fiorani P, Speziale F, Rizzo L, Taurino M, Giannoni MF, Lauri D. Long-term follow-up after in situ graft replacement in patients with aortofemoral graft infections. *Eur J Vasc Endovasc Surg* 1997;14 Suppl A:111-4.
- Speziale F, Rizzo L, Sbarigia E, Giannoni MF, Massucci M, Maraglino C, et al. Bacterial and clinical criteria relating to the outcome of patients undergoing in situ replacement of infected abdominal aortic grafts. *Eur J Vasc Endovasc Surg* 1997;13(2):127-33.
- Santini C, Baiocchi P, Venditti M, Brandimarte C, Tarasi A, Rizzo L, et al. Aorto-femoral graft infections: a clinical and microbiological analysis. *J Infect* 1993;27(1):17-26.
- Capone A, Giannella M, Fortini D, Giordano A, Meledandri M, Ballardini M, et al. High rate of colistin resistance among patients with carbapenem-resistant *Klebsiella pneumoniae* infection accounts for an excess of mortality. *Clin Microbiol Infect* 2013;19(1):E23-30.
- Kontopoulou K, Protonotariou E, Vasilakos K, Kriti M, Koteli A, Antoniadou E, Sofianou D. Hospital outbreak caused by *Klebsiella pneumoniae* producing KPC-2 beta-lactamase resistant to colistin. *J Hosp Infect* 2010;76(1):70-3.

30. Bulik CC, Nicolau DP. Double-carbapenem therapy for carbapenemase-producing *Klebsiella pneumoniae*. *Antimicrob Agents Chemother* 2011;55(6):3002-4.
31. Giamarellou H, Galani L, Baziaka F, Karaiskos I. Effectiveness of a double-carbapenem regimen for infections in humans due to carbapenemase-producing pandrug-resistant *Klebsiella pneumoniae*. *Antimicrob Agents Chemother* 2013; 57(5):2388-90.
32. Daikos GL, Markogiannakis A. Carbapenemase-producing *Klebsiella pneumoniae*: (when) might we still consider treating with carbapenems? *Clin Microbiol Infect* 2011;17(8):1135-41.
33. Qureshi ZA, Paterson DL, Potoski BA, Kilayko MC, Sandovsky G, Sordillo E, et al. Treatment outcome of bacteremia due to KPC-producing *Klebsiella pneumoniae*: superiority of combination antimicrobial regimens. *Antimicrob Agents Chemother* 2012;56(4):2108-13.
34. Thomson KS. Double-carbapenem therapy not proven to be more active than carbapenem monotherapy against KPC-positive *Klebsiella pneumoniae*. *Antimicrob Agents Chemother* 2012;56(7):4037-8.