

Case report

Clin Ter 2016; 167 (2):40-42. doi: 10.7417/CT.2016.1920

Successful endovascular treatment of a 13 cm abdominal aortic aneurysm. Case report

A. Santagata¹, A.M. Giribono¹, D. Ferrara¹, E. Viviani¹, D. Narese², F. Midiri², D. Albano², A. Padricelli¹, L. del Guercio¹

¹Department of Vascular and Endovascular Surgery, University Federico II of Naples, Naples; ²Department of Radiology, DIBIMEF, University of Palermo, Palermo, Italy

Abstract

There is increasing evidence in the literature that endovascular aneurysm repair is the first-line approach for most of abdominal aortic aneurysms (AAAs). Furthermore aortouniiliac stent graft placement is, in high risk patients or during emergency setting, a safe procedure over the mid- and long-term period and compares well with the results of bifurcated stent grafts.

We present a case of a 66 -year-old gentleman, with pneumothorax after therapeutic thoracentesis and a giant AAA, successfully treated with an aortomonoiliac stent grafting and femoro-femoral crossover bypass. *Clin Ter* 2016; 167(2):40-42. doi: 10.7417/CT.2016.1920

Key words: abdominal aortic aneurysm, aortomonoiliac stent-graft, endovascular surgery

Case report

A 66 -year-old heavy smoker man with a week history of dyspnea and pleural effusion was referred to the emergency department of another hospital for therapeutic thoracentesis. His medical history was also remarkable for hypertension and COPD, hip replacement one year earlier.

After thoracentesis, he developed pneumothorax to the left and subcutaneous emphysema of chest and neck. Contrast-enhanced computed tomographic (CT) showed an infrarenal abdominal aortic aneurysm (AAA) with a diameter of 13 cm x 7.5 cm, right common iliac aneurysm with a maximum diameter of 6.5 cm and left common iliac aneurysm of 4 cm (Fig. 1 A). The patient was then transferred to our institution for AAA management. The serious pulmonary disease excluded the option for an open surgery, thus an urgent endovascular procedure was performed under epidural anesthesia. Multiplanar reconstructions (MPR) were created on a OsiriX Workstation in order to select proper stentgraft. The proximal neck had a 60 degrees angulation, a regular shaped lumen, 19 mm in length and 29 mm in diameter. Severe calcification and thrombus deposition within the neck were not present. The lowest renal artery was the

left. The diameter of the aortic bifurcation was 33 mm. We decided to implant an aortomonoiliac Endurant II stent graft with right iliac limb extender (Endurant ENUF3614102, ENLW1616199 ®; Medtronic, Minneapolis, MN, USA) since this device is available at our institution for urgent procedures. Moreover, an aortomonoiliac configuration was preferred to a bifurcated one aiming to shorten the procedure by avoiding potential delay in catheterization of the contralateral gate. Both groins and the abdomen were disinfected with the patient in supine position. An inguinal exposure of common femoral artery and his branches was obtained bilaterally. A 7 Fr introducer sheath was inserted in the common femoral artery bilaterally and standard guidewires were advanced under fluoroscopic guidance across the abdominal aneurysm. A 20 Fr introducer sheath over an extrastiff guidewire was placed on the right side. On the contralateral side, a 6 Fr pigtail catheter was introduced over the standard guidewire to perform an angiogram of the abdominal aorta and the iliac arteries. This angiography confirmed the presence of huge AAA with implication of right common iliac artery.

After marking the renal arteries, the main body of an aortomonoiliac Endurant II stent graft and a right iliac limb extender were deployed to cover the entire length between the lowest renal artery and the right internal iliac artery (Fig. 1 B). The stent-grafts were subsequently ballooned with a Reliant balloon catheter and an occluder stent graft (Talent OCL24US Medtronic, Minneapolis, MN, USA) was placed in the left common iliac artery. A final angiography revealed good placement of stent-grafts, the patency of both renal arteries, right internal iliac artery and absence of any endoleak. The sheaths were removed and a suprapubic femoro-femoral crossover bypass was performed with an 8 mm ePTFE graft. The patient was discharged on postoperative day 3. One month CT postprocedural scan was performed, showing complete exclusion of the AAA, no endoleak, patency of the crossover bypass, shrinkage of the residual aneurysmal diameter sac to 10 cm. (Fig. 1 C). After 6 months from surgery the patient did not present any complication both at physical examination and at duplex scan.

Correspondence: Annamaria Santagata, Department of Vascular and Endovascular Surgery, University Federico II of Naples Via S. Pansini, 5 80131-Naples, Italy. Tel +390817462629, Fax +390817463698. E-mail: annamariasantagata@hotmail.it

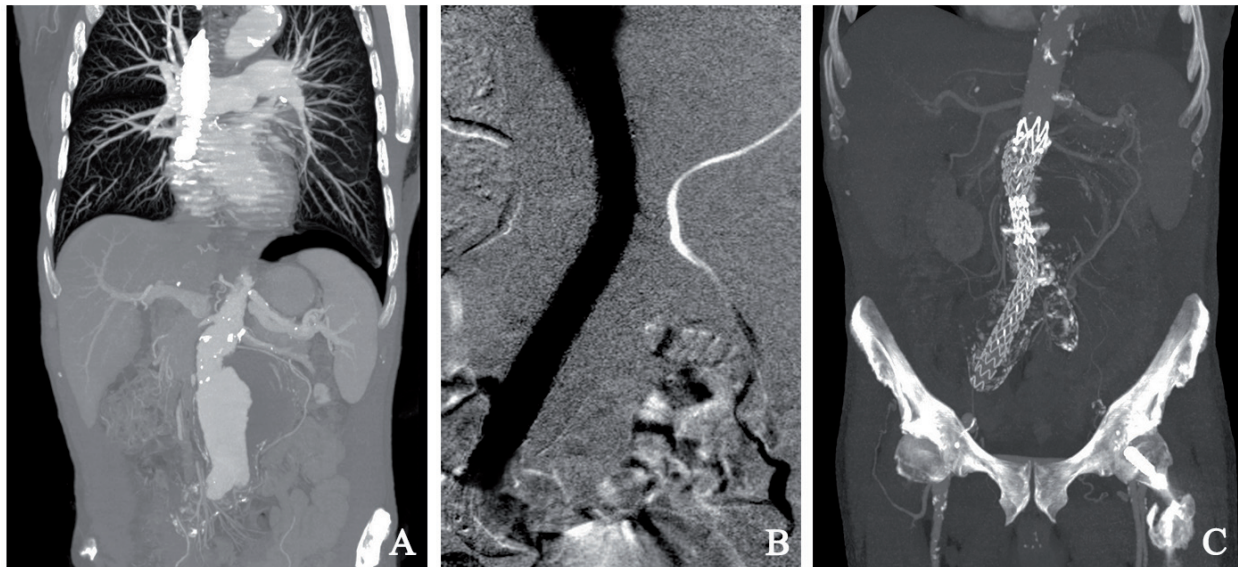


Fig. 1. A Multi-planar reconstruction (MPR) computed tomography (CT) showing longitudinal section of contrast filled abdominal aortic aneurysm with bilateral mural thrombus and left pneumothorax with the air layer between the base of the lung and the pleura; B Intraoperative angiogram showing good placement of stent-grafts and absence of any endoleak.; C Postprocedural MPR-CT scan showing complete exclusion of the AAA, no endoleak and patency of the crossover bypass.

Discussion

The additional information provided by a CT scan may lead to more accurate diagnosis, with more incidental findings, defining as findings that appear unrelated to the original purpose of the scan.

There are many clinical, social and economical advantages associated to the diagnosis of incidentalomas: in our case, the early detection of significant disease, lead to a timely treatment and a likely improvement of the prognosis. (1,2,3)

Our patient presented with a huge AAA, incidentally diagnosed on CT scan, measuring 13 cm as a maximum diameter, with an imminent risk of rupture.

Aortic rupture is, in fact, the most common and life-threatening complication of an AAA with a mortality rate as high as 75% for the infrarenal tract. Brown PM et al (4), showed that the average risk of rupture in male patients with AAA greater than 6 cm is 14.1% per year. Noronen K. et al (5) showed that in 154 cases excluded from the surgical repair of AAA due to severe co-morbidities in the patients, 43% died because of rupture.

Endovascular approaches for repairing various arterial pathologies have become increasingly popular. With low morbidity and mortality, endovascular stent-grafts for AAA exclusion provides an alternative to open repair, especially in patients with concomitant disease (6,7). Moreover, in emergency conditions, the implantation of aortomonoiliac stent-graft with a femoro-femoral crossover bypass provides a good therapeutic option (8,9,10). Tang et al (11) reported among 1172 patients with intact infrarenal AAAs treated as part of the Endurant Stent Graft Natural Selection Global Post-market Registry (ENGAGE) there are not many differences between patients treated with a bifurcated device and an Endurant AUI with femoro-femoral by-pass; the number

of endoleaks was greater in the AUI group at the end of procedure but was similar at 30-day follow-up. Furthermore, the ENGAGE data were analyzed by Broos et al to demonstrate that Endurant stent graft is safe and effective also in patients with challenging aortic neck anatomy (12).

References

1. Van Walraven C, Wong J, Morant K, et al. Incidence, follow-up, and outcomes of incidental abdominal aortic aneurysms. *J Vasc Surg* 2010; 52(2):282-9.e1-2
2. Hara AK, Johnson CD, MacCarty RL, et al. Incidental extracolonic findings at CT colonography. *Radiology* 2000; 215(2):353-7
3. Khashram M, Jones GT, Roake JA. Prevalence of abdominal aortic aneurysm (AAA) in a population undergoing computed tomography colonography in Canterbury, New Zealand. *Eur J Vasc Endovasc Surg* 2015; 50(2):199-205
4. Brown PM, Zelt DT, Sobolev B. The risk of rupture in untreated aneurysms: the impact of size, gender, and expansion rate. *J Vasc Surg* 2003; 37(2):280-4
5. Noronen K, Laukontaus S, Kantonen I, et al. The natural course of abdominal aortic aneurysms that meet the treatment criteria but not the operative requirements. *Eur J Vasc Endovasc Surg* 2013; 45:326-31
6. Qin C, Chen L, Xiao YB. Emergent endovascular vs. open surgery repair for ruptured abdominal aortic aneurysms: a meta-analysis. *PLoS One*. 2014 Jan 31; 9(1):e87465
7. Porcellini M, Nastro P, Bracale U, et al. Endovascular versus open surgical repair of abdominal aortic aneurysm with concomitant malignancy. *J Vasc Surg* 2007; 46(1):16-23
8. Peppelenbosch N, Geelkerken RH, Soong C, et al. Endograft treatment of ruptured abdominal aortic aneurysms using the Talent aortouniiliac system: an international multicenter study. *J Vasc Surg* 2006; 43(6):1111-23

9. Porcellini M, Mainenti P, Bracale U. Endograft repair of spontaneous infrarenal abdominal aortic dissection. *J Vasc Surg* 2005; 41(1):155
10. Dortch JD, Oldenburg WA, Farres H, et al. Long-term results of aortouniiliac stent grafts for the endovascular repair of abdominal aortic aneurysms. *Ann Vasc Surg* 2014; 28(5):1258-65
11. Tang T, Sadat U, Walsh S, et al. ENGAGE Investigators. Comparison of the endurant bifurcated endograft vs. aortouniiliac stent-grafting in patients with abdominal aortic aneurysms: experience from the ENGAGE registry. *J Endovasc Ther* 2013; 20(2):172-81
12. Broos PP, Stokmans RA, van Sterkenburg SM, et al. Performance of the Endurant stent graft in challenging anatomy. *J Vasc Surg* 2015; 62(2):312-8