

The archaeological contribution of forensic craniofacial reconstruction to a portrait drawing of a Korean historical figure

Won Joon Lee ^a, A. Young Yoon ^b, Mi Kyung Song ^c, Caroline M. Wilkinson ^d,
Dong Hoon Shin ^a,

^a Department of Anatomy, Seoul National University College of Medicine, Seoul, South Korea

^b Visual Communication Design, Sungkyunkwan University, Seoul, South Korea

^c Department of Clothing Science, Seoul Women's University, Seoul, South Korea

^d Centre for Anatomy and Human Identification, University of Dundee, Dundee, UK

Keywords:

Archaeology
Craniofacial reconstruction Approximation
Mummy Accuracy Quantitative
3D computerized graphic Portrait

Abstract

Craniofacial reconstruction (CFR) is a technique used to rebuild the living facial appearance onto a skull in order to recognise or identify an individual. This technique is primarily employed in forensic investigation, but also utilised in archaeological research to recreate the faces of paleontological and archaeological humans. In this study, the face of a 17th century historical figure from Korea was reconstructed utilising computerized tomography from the mummified remains. A geographic surface comparison programme was employed to evaluate the accuracy of the CFR produced using a three-dimensional computerized modelling system. Analysis of the facial tissue depth discrepancies demonstrated that the CFR may have acceptable resemblance to the living face of the historical individual. Using computerised graphic technology, the CFR outcome, along with the archaeological information about the hair style, ornaments, and dress discovered in the tomb, a portrait-styled in the typical drawing trend from the era was created. The research suggests that current CFR techniques can provide an accurate portrait drawing of historical figures in Korea.

Introduction

Our fascination with the facial features of our ancestors or historically important figures is no surprise. Portraits and statues have been used as an effective way of remembering ancestors for many years, and many such portraits have been passed down from generation to generation. In developed countries, the portraits of historical figures have often been carefully preserved in specially designed museums or galleries, such as the National Portrait Gallery in the UK or the Smithsonian National Portrait Gallery in the USA. These portraits still provide us with invaluable information about the appearance of historical figures during their life time and suggest a great deal of physical and anthropological data, depicting history and culture across eras.

In the past, Korea has also had a strong cultural tradition for drawing the faces of contemporary celebrities. The facial appearances of high officials, generals or scholars were drawn by contemporary painters; and the facial portraits were used for ancestral worship ceremonies of the Joseon period (1392e1897 CE). At present, these portraits are one of the most popular attractions for the museum exhibitions of Korea (Supplementary data 1).

However, there are many historical figures in Korea for which there are not existing portraits or sculptures, even though their reputations were no less prominent than the known-face figures. The descendants or historical organizations associated with the unknown-face historical figures desire

a memorial way to attract the general public. Facial depictions of unknown-face historical figures however, are often difficult due to the lack of information available for the current artists. Under such circumstances, the artists inevitably rely on imagination or ambiguous references from biological descendants of the decedent. As the demand for portraits of historical figures increases, the artistic license of painters causes some problems, and the public may be confused when various versions present inconsistencies. To resolve this problem, the most likely portrait could be chosen or a new portrait might be recreated from all existing portraits. Whatever the method, it is obvious that the portrait should be depicted or determined on the basis of scientific evidence. As a part of government efforts to resolve such problem, the Ministry of Culture, Sports and Tourism of South Korea (MCST) passed the instruction for national standard portraits of historical figures (Ministry of Culture, Sports and Tourism, 1973). The government's instruction decrees that the appearance of historical figures' faces must be standardized, in order to cause less confusion, and craniofacial reconstruction (CFR) may be a possible application. CFR has primarily been applied in forensic investigations where other approaches are not possible or few clues are available to aid the identification of human remains. It is a technique used to rebuild a face onto a skull to recreate the ante-mortem appearance of the individual in order to recognise and identify the decedent (Wilkinson, 2004).

Along with forensic cases, CFR is also utilised in archaeological research to recreate the faces of paleontological and archaeological humans, particularly where there is little facial information available (Wilkinson, 2011). Scientifically, it is widely accepted that the first CFR was attempted by the Swiss-born German anatomist Wilhelm His who rebuilt the face of the composer Johann Sebastian Bach (His, 1895). Thereafter, the demand for CFR in archaeological research has increased and interdisciplinary studies have been performed world-wide to rebuild interesting faces from the past (Cesarani et al., 2004; Gregersen et al., 2006; Wilkinson, 2008; Papagrigrakis et al., 2011; Hayes et al., 2013). The CFR of King Richard III has been one of the most leading international projects highlighted by academia (National Geographic, 2013). It is noticeable that archaeological excavations regarding historical figures have also been performed in South Korea for several decades (Supplementary data 2). Like many other countries, the majority of the tombs of famous historical figures in Korea have been investigated and recovered by archaeologists for various reasons (for example, the need to relocate or to rescue the remains due to construction work). In those cases, anatomists might be able to inspect the human remains with the permission of descendants and the authorities.

The human remains employed in this study were recovered through re-interment and the ancestor had been buried at the site approximately 400 years previously with the tombstone recording his identity. The ancestor was found in a mummified state with a partially recognisable face. The excited decedents immediately realised the academic value of the mummified body and requested an examination of the remains by a mummy research team in South Korea.

The current study is based on the idea that the face would be recreated from the mummified head using advanced medical imaging and a computerised CFR system. In addition, the reconstructed face could be used as a reliable reference for the depiction of an historical figure. In addition, the reconstructed face will be utilised to depict the face in a stylised drawing following the Joseon tradition.

Materials and methods

The mummy case

For the scientific study of the Joseon mummy, the permit of Institutional Review Board (IRB) was certified to the Bio- anthropology and Paleopathology Lab, Institute of Forensic Science, Seoul National University College of Medicine (H-1108-049-120). On November 2007, a male mummy, named Gyeongsun Choi, was discovered in the Joseon tomb located in Gangneung, the coastal city

on East Sea of Korean peninsula. The mummy was recovered during a reburial process into a newly constructed family cemetery. He was discovered fully wrapped in the clothes of Joseon period (Fig. 1).

The personal history was already recorded by the descendants before investigation. Briefly, he was born in 1561 and died in 1622 (aged 61 years) and he was a member of a renowned local family. Although not qualified as a classics licentiate, he was honoured as the deputy general of Military Commands, a kind of an honorary post for an important member of the locality. In fact, he was likely to have spent his life as a prominent gentleman. When he died, the Royal Court conferred posthumous honours of Commander (jeolchung janggun) on him. He was survived by three sons and three daughters.

A magnetic resonance imaging (MRI) study suggested that it is possible that the mummified Joseon individual might have suffered from spinal stenosis caused by diffuse disc bulging (Shin et al., 2010). In dissection, it was found that faeces still remained in the sigmoid colon or rectum and a paleoparasitological study on the faeces showed that he was infected by *Trichuris trichiura*, the most common parasite species in pre-modern Korean population (Lee et al., 2009). Computed tomography (CT) and post-factum dissection studies by Lee et al. (2009) investigated the cause of death. A pathological change on the left side of the mandible was observed and it was concluded that the lesion might be caused by a fracture, which eventually led to his death. The CFR however was produced with the assumption that the lesion would not have influenced the general facial appearance during his life time. The CT data utilised was employed for the CFR.

Preparation of skull model for CFR

A three-dimensional (3D) head model was obtained from the original CT scan data of the mummy and the CFR was carried out by an independent practitioner (WJL). Facial photographic images of the mummy were not revealed to the CFR practitioner until the project was completed.

The hard tissue images of the head were separated from the CT scan data of the mummy and the skeleton images formatted as Digital Imaging and Communications in Medicine (DICOM) data were converted into stereolithography (STL) images using 3D visualization analysis software (Amira™ version 5.2.2 from VSG, USA). The CFR was completed using a computerized 3D modelling system (FreeForm Modelling™ software from 3D Systems Inc., USA) and the 3D model. This system involves Phantom Desktop™ Haptic Device enabling the engagement of tactile senses to shape and manipulate the digitized 3D models in a non-invasive manner (Wilkinson, 2003a).

CFR

The virtual skull models were imported into FreeForm Modelling as STL files followed by transforming the STL format into Clay (CLY) files to be visualised in the software. Two different types of skull models were prepared for the study: the skull with open jaw; the skull with closed jaw. The sex and age at death of the mummified individual were assessed again from the reconstructed skull model.

Three CFRs were produced from the two skull models according to the combination method of Wilkinson (2004):

- CFR 1 presenting facial appearance before death with open eyelids and closed jaw
- CFR 2 presenting facial appearance before death with closed eyelids and open jaw (intermediate between CFR 1 and CFR 3)
- CFR 3 presenting the mummified face after death with closed eyelids and open jaw.

For CFR 1 and 2, average data of facial soft tissue depth from living Korean adults (Lebedinskaya et

al., 1993) was utilised. Each major facial muscle was rebuilt as accurately as possible following anatomical guidelines. A databank of pre-modelled facial muscles created by Wilkinson (2003a) was utilised at the muscle stage. A number of guidelines were employed to predict facial components such as eyes, nose, mouth and ears. The description in detail was published in a previous study of the accuracy of Korean CFRs (Lee et al., 2012). For the final stage, a skin layer was added over the muscle and skull structure referring to the facial anatomy, musculature and tissue depth guides by utilising transparency tools in the FreeForm software.

Accuracy test

CFR 3 presenting the mummified face after death with closed eyelids and open jaw was used to assess the consistency to the mummified remains. In order to show dehydration-related, mummified changes in CFR 3, the skin depths including facial components were reduced across the skin layer surface of CFR 2. A previous paper describing the dimensional changes associated with mummification was used as a reference during the procedure (Wilkinson, 2008).

For any accuracy test, the living facial appearance of the individual is required, but for this case there were no existing portraits or statues. Therefore, the mummified face on the CT scan was used to assess consistency with CFR 3. The discrepancy between the two facial skin layers of CFR 3 and the mummified face was analysed quantitatively by using 3D geometric surface comparison (reverse modelling) software. CFR 3 and the mummified face were aligned manually in Freeform modelling system, by referring to the embedded common 3D skull models in the CFR 3 and the mummy head. Because the two skull models were oriented identically in dimension and position, the most reliable 3D geometric surface discrepancy between CFR 3 and the mummy head could be obtained.

Illustration and portrait drawing

In the last phase of the study, CFR 1 was illustrated to visualise and reconstruct the complete appearance of the individual, using 3D computer graphic technology to create skin texture, hair style and clothing. The 3D illustration was performed by an illustrator (AYS) employing Maya® (Autodesk®, USA) and ZBrush® (Pixo-logic™, USA). The completed CFR 1 was converted into STL file format; and it was provided to the illustrator with other information relating to skin texture, hair style and clothing.

Photographs of the mummy face were useful for reconstructing the appearance at the age of death and photographs of the mummy hair were also utilised as hair style reference. Textile specialists provided information relating to the dress and ornaments worn by the individual found in the tomb. This included a headband made of horsehair (Manggon), other clothes and a common Korean cap or hat, such as those worn by males of the Joseon period at home.

The illustrated bust was converted into drawing using computer graphic tool (Photoshop®, Adobe®, USA) following the traditional Joseon period painting style (Cultural Heritage Administration, 2007).

Results

The virtual skull model was in good condition (Fig. 2A), with an open mandible. The deviated mandible was repositioned to the maxilla for CFR 1 to create a normal occlusion (Fig. 2B). The skull suggested typical male traits: robust, relatively large size with a good level of symmetry, massive mastoid processes, developed gonial angles, prominent occipital protuberance and temporal lines (Brothwell, 1981; White and Folkens, 2005). The traits showing a round sagittal cranium contour, wide facial shape, flat cheek bones, lesser prominent nasal root and moderate nasal width suggested that the skull was from Mongoloid-type ancestry (Brothwell, 1981; White and Folkens, 2005). The missing mandibular posterior teeth, resorption on the alveolar bone and

the advanced degree of dental attrition suggested a middle-aged man (Brothwell, 1981; Lovejoy, 1985). The overall visual assessment of the skull demonstrated consistencies with the recorded profile of the individual in the Lineage Book of the Clan (Lee et al., 2009).

The tissue depth pegs were placed onto the surface of the skull at the corresponding anatomical landmarks using the Freeform software (Fig. 2C). Each pre-modelled facial muscle was imported and positioned onto the skull, according to the analysis of those origins and insertions. The dimension and detailed shape of the muscles were altered to customize them to the skull utilising 3D deformation tools (Fig. 2D). The facial components were rebuilt onto the skull as predicted from the guidelines (Lee et al., 2012) (Fig. 2E). CFR 1 was completed by addition of a skin layer over the muscle layer (Fig. 2F).

CFR 2 was then attempted. This presents the facial appearance before death with closed eyelids and open jaw. Since only the mandible position was different to CFR1 the skin layer was still applicable and this was adjusted to the open mandible to depict morphological changes in the soft tissue around the open mouth. The eye fissures were presented as closed (Fig. 2G). Finally CFR 3 (mummified face after death with closed eyelids and open jaw) was then reconstructed (Fig. 2H). The mummified face is shown in Fig. 2I.

The completed CFR 3 was compared to the face of the mummy on the CT model in order to assess the accuracy of the CFR. The mummified face (Fig. 3A) and CFR 3 (Fig. 3B) were aligned in Freeform by referring to the embedded common 3D skull models (Fig. 3C). The aligned models were imported as STL file format to the reverse modelling software (Geomagic® Control™ Version 10, 3D Systems Inc., USA).

The Geomagic Control software created shell-to-shell deviation maps between the mummified face and CFR 3 with numerical discrepancies between the two skin layers (Fig. 4). The percentage distributions for the deviations are presented in Table 1. The deviations between the two shells (the errors) were computed as the minimum limit of discrepancy error was ranged within ± 2.5 mm. The average on the discrepancy between the facial surface of CFR 3

And the mummy was 0.43 mm. The standard deviation between the two facial surfaces was 2.04 mm.

The deviation map revealed that 80% of the overall surface of CFR 3 deviated within ± 2.5 mm error to the mummy face (Table 1) and this increased to 95% when the error deviation was broadened to within ± 5.0 mm. The most accurate areas (errors between ± 1.0 mm; green-coloured areas, occupied by 39% of the overall surface of CFR 3) were found across the overall facial surface: majority of the forehead, around the orbits and nose (except the nasal tip and nostrils) the cheeks, the left mouth corner and below the lower lip. Partial forehead, supra and lateral orbits, parts of the nose, the lips and majority of the cheeks and chin were between ± 1.0 and ± 2.5 mm of error (yellow-coloured areas; more prominent than the mummy face). The lower orbits, the left lower forehead, the right upper lip and both central cheeks were between

-1.0 and -2.5 mm of error (light blue-coloured areas; less prominent than the mummy face). The largest areas of error (± 2.5 to ± 4 mm and ± 4 to ± 5 mm) occurred at the tip and nostrils of the nose, the right side of the lips and the lower chin (red-coloured areas; more prominent than the mummy face).

Based on CFR 1, the appearance of the individual was illustrated (Fig. 5). The facial skin texture was created for a man in his 60s, and more facial creases were added in the illustration in order to provide a more realistic age depiction. The clothing, cap and headband were also depicted (Fig. 6). The illustrated bust was converted into portrait-styled drawing. The final result is shown in Fig. 7.

Discussion

Techniques of CFR have been employed in human identification investigations world-wide, particularly when other forensic techniques are not available for identification of unknown

remains (Taylor, 2001; Wilkinson, 2004). In addition to forensic purposes, the CFR techniques have frequently contributed to archaeological research into historical figures or ancient humans (Prag and Neave, 1997).

The faces of our ancestors can be rebuilt from two main materials: the dry skull or the mummified (including embalmed and bog bodies) head. Amongst recent studies on CFR in archaeological contexts, Wilkinson (2003b; 2008; 2011) produced the faces of ancient Egyptians, and attempted to evaluate the accuracy of the CFRs. Cesarani et al. (2004) rebuilt the face of a wrapped Egyptian mummy using Multi-detector Computed Tomography (MDCT) which enabled non-destructive study into the mummy. A research team in Italy and Austria also reconstructed the face of Ferrante Gonzaga (1507e1557 CE), the Italian nobleman of the Renaissance period, using CT scanned data and virtual anthropological analysis from the embalmed body (Benazzi et al., 2010).

Hayes et al. (2012) produced three CFRs using the skulls excavated from Wairau Bar burial site where the earliest colonists were buried in New Zealand. They also carried out a CFR on the skull of *Homo floresiensis* excavated from Liang Bua in Indonesia (Hayes et al., 2013). The face of Dante Alighieri (1265e1321 CE), the major Italian poet of the Middle Ages renowned for his *Divine Comedy*, was recreated from the skull (Benazzi et al., 2009). Papagrigorakis et al. (2011) reconstructed the face of a female child using the skull dated from 430 BCE Athens.

The accuracy of CFR has always been controversial (Wilkinson, 2004). A number of previous empirical studies have therefore employed qualitative and quantitative accuracy tests (Stephan and Cicolini, 2008; Claes et al., 2010; Fernandes et al., 2012; Lee et al., 2012) and successful forensic cases (South Wales Police Museum, 2005; Algemeen, 2009; BBC, 2013) also demonstrate that CFR techniques can provide enough resemblance to the real faces to enable recognition.

The accuracy of CFRs in archaeological cases has usually employed portraits (Wilkinson, 2003b; Kustar, 2004), statues (Gregersen et al., 2006) or texts recording facial features of the individuals (Benazzi et al., 2009). In these cases it has been indirectly concluded that the CFRs may have a reasonable resemblance to the real faces.

In contrast to this international utilisation, CFR has not been applied to forensic or archaeological purposes in South Korea with the same frequency. Recently, CFR techniques have been considered as a significant tool in archaeological research for anatomists in Korea. Government-level projects are currently being pursued to assign standard portraits for historically important figures when contemporary portraits are unavailable. However it is always problematic for artists to depict a face where there is very limited information and these efforts have been criticised for their ambiguous reliability (Ministry of Culture, Sports and Tourism, 2013).

In these cases where the skeletal material exists a facial depiction could be successfully recreated using CFR techniques, and could be used as an ideal reference for the artist. In South Korea, many archaeological excavations have been performed to investigate the tombs of historical figures and the examination of these skeletal remains could provide an opportunity to attain the forensic anthropological information needed for CFR-based portraiture.

The human remains discovered in Joseon tombs have special meaning as the Joseon Kingdom in Korean history prospered for about 500 years (1392e1910 CE). During this period, many historic figures were buried after death in a specific type of the tomb with a lime-soil mixture barrier (LSMB) (Supplementary data 3) and the human remains from such tombs have been preserved in excellent condition. In some exceptional cases, the human remains have been discovered in mummified states (Lee et al., 2009; Shin et al., 2010). The mummified face may enable the assessment of the resemblance of the CFR to the face of the individual, especially where there is no available information about the facial appearance other than the mummy. Furthermore, with the accumulation of other studies, it might be possible to depict the facial appearance as closely as possible to the actual face using CFR techniques. This study was a pioneering attempt to investigate whether a reliable portrait could be recreated from CFR through comparison to the mummified face.

The computer generated CFR system has been evaluated previously. Wilkinson et al. (2006) produced CFRs from two CT scanned skulls employing 3D computerized modelling system. When two face pools were subject to a matching task, the result demonstrated that the combined hit rate was 70%. The accuracy of the two CFRs was also assessed quantitatively utilising a geometric surface comparison programme which was exactly the same methodology used in this study. The results presented that when comparing with the target faces, the majority of the surfaces of the CFRs showed less than 2.5 mm error (60% for the male face and 51.8% for the female face), and 90% of the male face and 75% of the female face presented less than 5.0 mm error. This pioneering study successfully proved that the accuracy assessed by quantitative geometric surface comparison may correlate with the accuracy level from face pool comparison tests that is also considered as the most reliable method to evaluate the accuracy of CFR (Wilkinson and Whittaker, 2002; Stephan and Cicolini, 2008).

Geometric surface comparison was further utilised to study the CFR of skulls from a Korean population using CT data from living subjects (Lee et al., 2012). The study demonstrated that 54%, 65% and 77% of the three CFR surfaces showed less than 2.5 mm error when compared to the corresponding face. Comparing to the previous study of Wilkinson et al. (2006), the study (Lee et al., 2012) established that the CFRs from living Korean subjects showed acceptable accuracy and further demonstrated that geometric surface comparison could be useful for evaluating the accuracy of CFRs generated from computerized systems.

The facial appearance of an individual mummy changes during mummification due to hydration-related contractions or distortions (Wilkinson, 2008) and comparison with the CFRs presenting a living appearance was considered inadequate. Instead, a CFR was produced depicting the changes after mummification, and this was compared with the mummified face. In fact, this methodology is the reverse of Wilkinson's study (2008) where the face in life was produced by rehydrating mummified remains. In other words, the reliability of CFR in this study was estimated indirectly from the quantitative geometric surface comparison between mummified state predicted by CFR 3 and the actual mummified face. If CFR 3 demonstrated an acceptable level of consistency to the mummy head, it could infer that CFR 1 might present close resemblance to the face of individual in life.

On this assumption, it is significant that the results of this study -80% of the overall surface of CFR 3 deviated within an error ± 2.5 mm in the alignment with the mummy face is comparable to the two previous studies using living faces (Wilkinson et al., 2006; Lee et al., 2012). Each highest percentage occupied by within ± 2.5 mm error deviation of the skin surface was 60% and 77% respectively in those two studies. Considering that the result from this study was as high as the previous two studies (Wilkinson et al., 2006; Lee et al., 2012), we can assume that CFR 3 demonstrated acceptable resemblance to the mummy head.

Although the results should be considered with caution due to the limitations of a single case and the indirect comparison method, this research demonstrates that CFR based on anatomical guidelines can be used to create a reliable portrait or statue (Fig. 8). By this project, the portrait images of historical figures in Korea could be deemed more authentic and associated with scientific evidence. This in turn could increase the public confidence in any resulting portraiture.

Conclusion

In Korea, there is a government-led project for the creation of portraits of historical figures when there is a paucity of information on their appearances in historical documents or materials. Since there has been a lot of criticism of artistic depictions, any scientific evidence relating to the facial appearance is desperately needed. In this respect, CFR could be an ideal technique for providing information useful for these portraits or statues. The Korean mummy discovered in a 17th century Joseon tomb provides an opportunity to test the accuracy of CFR using quantitative geometric surface comparison. The accuracy analysis suggested that CFR may produce enough resemblance

to enable recognition. If further studies are carried out on similar cases in Korea, it will enable the production of reliable portraits or statues of historical figures.

References

- Algemeen, 2009. Vader Maasmeisje overleden in gevangenis. Available at: <http://www.nu.nl/algemeen/1962980/vader-maasmeisje-overleden-in-gevangenis.html>.
- BBC, 2013. Corstorphine Hill Murder. Available at: <http://www.bbc.co.uk/news/uk-scotland-edinburgh-east-fife-23240433>.
- Benazzi, S., Bertelli, P., Lippi, B., Bedini, E., Caudana, R., Gruppioni, G., Mallegni, F., 2010. Virtual anthropology and forensic arts: the facial reconstruction of Ferrante Gonzaga. *J. Archaeol. Sci.* 37, 1572e1578.
- Benazzi, S., Fantini, M., De Crescenzo, F., Mallegni, G., Mallegni, F., Persiani, F., Gruppioni, G., 2009. The face of the poet Dante Alighieri reconstructed by virtual modelling and forensic anthropology techniques. *J. Archaeol. Sci.* 36, 278e283.
- Brothwell, D.R., 1981. *Digging Up Bones*. Natural History Museum Publications, London.
- Cesarani, F., Martina, M.C., Grilletto, R., Boano, R., Roveri, A.M.D., Capussotto, V., Giuliano, A., Celia, M., Gandini, G., 2004. Facial reconstruction of a wrapped Egyptian mummy using MDCT. *Am. J. Roentgenol.* 183, 755e758.
- Claes, P., Vandermeulen, D., De Greef, S., Willems, G., Clement, J.G., Suetens, P., 2010. Bayesian estimation of optimal craniofacial reconstructions. *Forensic Sci. Int.* 201, 146e152.
- Cultural Heritage Administration, 2007. *Korean Portrait Paintings*. Nulwa, Seoul.
- Fernandes, C.M.S., da Costa Serra, M., da Silva, J.V.L., Yoshito Noritomi, P., de Sena Pereira, F.D.A., Melani, R.F.H., 2012. Tests of one Brazilian facial reconstruction method using three soft tissue depth sets and familiar assessors. *Forensic Sci. Int.* 214, 211.e1e211.e7.
- Gregersen, M., Boldsen, J., Bjørn, H., Boel, L.W., Fromholt, P., 2006. Examination and identification of a Danish 17th-century nobleman, Laurids Ebbesen: a multi-disciplinary study. *Forensic Sci. Med. Pathol.* 2, 51e58.
- Hayes, S., Buckley, H., Bradley, R., Milne, N., Dennison, J., 2012. Approximating the face of 'Aunty': a Question of Likeness. *J. Archaeol. Method Theory* 19, 306e321. Hayes, S., Sutikna, T., Morwood, M., 2013. Faces of Homo floresiensis (LB1). *J. Archaeol. Sci.* 40, 4400e4410.
- His, W., 1895. Johann Sebastian Bach. *Forshungen uber dessen Brabstatte, Bebeine und Antlitz*. Bericht an den Rath der Stadt Leipzig. FCW Vogel, Leipzig.
- Kustar, A., 2004. The facial restoration of Antal Simon, a Hungarian priest-teacher of the 19th c. *HOMO* 55, 77e90.
- Lebedinskaya, G.V., Balueva, T.S., Veselovskaya, E.V., 1993. Principles of facial reconstruction. In: I_s, can, M.Y., Helmer, R.P. (Eds.), *Forensic Analysis of the Skull*.
- *Craniofacial Analysis, Reconstruction and Identification*. Wiley, New York, pp. 183e198.
- Lee, I.S., Lee, E.J., Park, J.B., Baek, S.H., Oh, C.S., Lee, S.D., Kim, Y.S., Bok, G.D.,
- Hong, J.W., Lim, D.S., Shin, M.H., Seo, M., Shin, D.H., 2009. Acute traumatic death of a 17th century general based on examination of mummified remains found in Korea. *Ann. Anat.* 191, 309e320.
- Lee, W.-J., Wilkinson, C.M., Hwang, H.-S., 2012. An accuracy assessment of forensic computerized facial reconstruction employing cone-beam computed tomography from live subjects. *J. Forensic Sci.* 57, 318e327.
- Lovejoy, C.O., 1985. Dental wear in the Libben population: its functional pattern and role in the

determination of adult skeletal age at death. *Am. J. Phys. Anthropol.* 68, 47e56.

- Ministry of Culture, Sports and Tourism, 2013. What are the Standard Portraits? Available at: <http://nationalculture.mcst.go.kr/portrait/intro/portrait.jsp>.
- Ministry of Culture, Sports and Tourism, 1973. Revised in 2012. Act for Consideration of Portraits and Statues. Available at: <http://nationalculture.mcst.go.kr/portrait/consider/rule.jsp>
- National Geographic, 2013. The Real Richard III. Available at: <http://news.nationalgeographic.com/news/2013/13/130205-richardiii-english-king-3d-reconstruction-science-archaeology/>
- Papagrigorakis, M.J., Synodinos, P.N., Antoniadis, A., Maravelakis, E., Toulas, P., Nilsson, O., Baziotopoulou-Valavani, E., 2011. Facial reconstruction of an 11-year-old female resident of 430 BC Athens. *Angle Orthod.* 81, 171e179.
- Prag, J., Neave, R.A.H., 1997. *Making Faces*. British Museum Press, London.
- Shin, D.H., Lee, I.S., Kim, M.J., Oh, C.S., Park, J.B., Bok, G.D., Yoo, D.S., 2010. Magnetic resonance imaging performed on a hydrated mummy of medieval Korea. *J. Anat.* 216, 329e334.
- Stephan, C.N., Cicolini, J., 2008. Measuring the accuracy of facial approximations: a comparative study of resemblance rating and face array methods. *J. Forensic Sci.* 53, 58e64.
- South Wales Police Museum, 2005. A Chronology of 50 Years of Policing Cardiff's Capital. Available at: http://www.southwalespolicemuseum.org.uk/en/content/cms/visit_the_archives/50_years_of_policing/50_years_of_policing.aspx
- Taylor, K.T., 2001. *Forensic Art and Illustration*. CRC Press, Boca Raton, FL.
- White, T.D., Folkens, P.A., 2005. *The Human Bone Manual*. Elsevier Academic Press, Burlington, MA, USA.
- Wilkinson, C.M., 2003a. Virtual sculpture as a method of computerized facial reconstruction. In: *Proceedings of the 1st. International Conference on Reconstruction of Soft Facial Parts*. Germany, Potsdam, pp. 59e63.
- Wilkinson, C.M., 2003b. The Facial Reconstruction of the Marina El-Alamein Mummy. *Polish Archaeology in the Mediterranean XIV Reports 2002*. Warsaw University, pp. 66e71.
- Wilkinson, C.M., 2004. *Forensic Facial Reconstruction*. Cambridge University Press, Cambridge.
- Wilkinson, C.M., 2008. The Facial reconstruction of ancient Egyptians. *Cpt* 11. In: David, R. (Ed.), *Egyptian Mummies and Modern Science*. Cambridge University Press, pp. 162e180.
- Wilkinson, C.M., 2011. Facial Analysis of Preserved Bodies. In: *Yearbook of Mummy Studies*, vol. 1, pp. 171e180.
- Wilkinson, C., Rynn, C., Peters, H., Taister, M., Kau, C.H., Richmond, S., 2006. A blind accuracy assessment of computer-modeled forensic facial reconstruction using computed tomography data from live subjects. *Forensic Sci. Med. Pathol.* 2, 179e188.
- Wilkinson, C.M., Whittaker, D.K., 2002. Juvenile forensic facial reconstruction: a detailed accuracy study. In: *Proceedings of the 10th Conference of the International Association of Craniofacial Identification*, 11e14 September 2002; Bari, Italy.

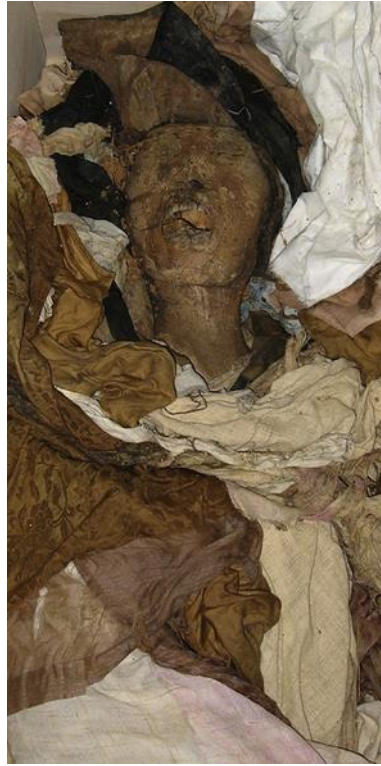

Fig. 1. The male mummy of Gyeongsun Choi used in this study whose body was fully wrapped by the clothes.

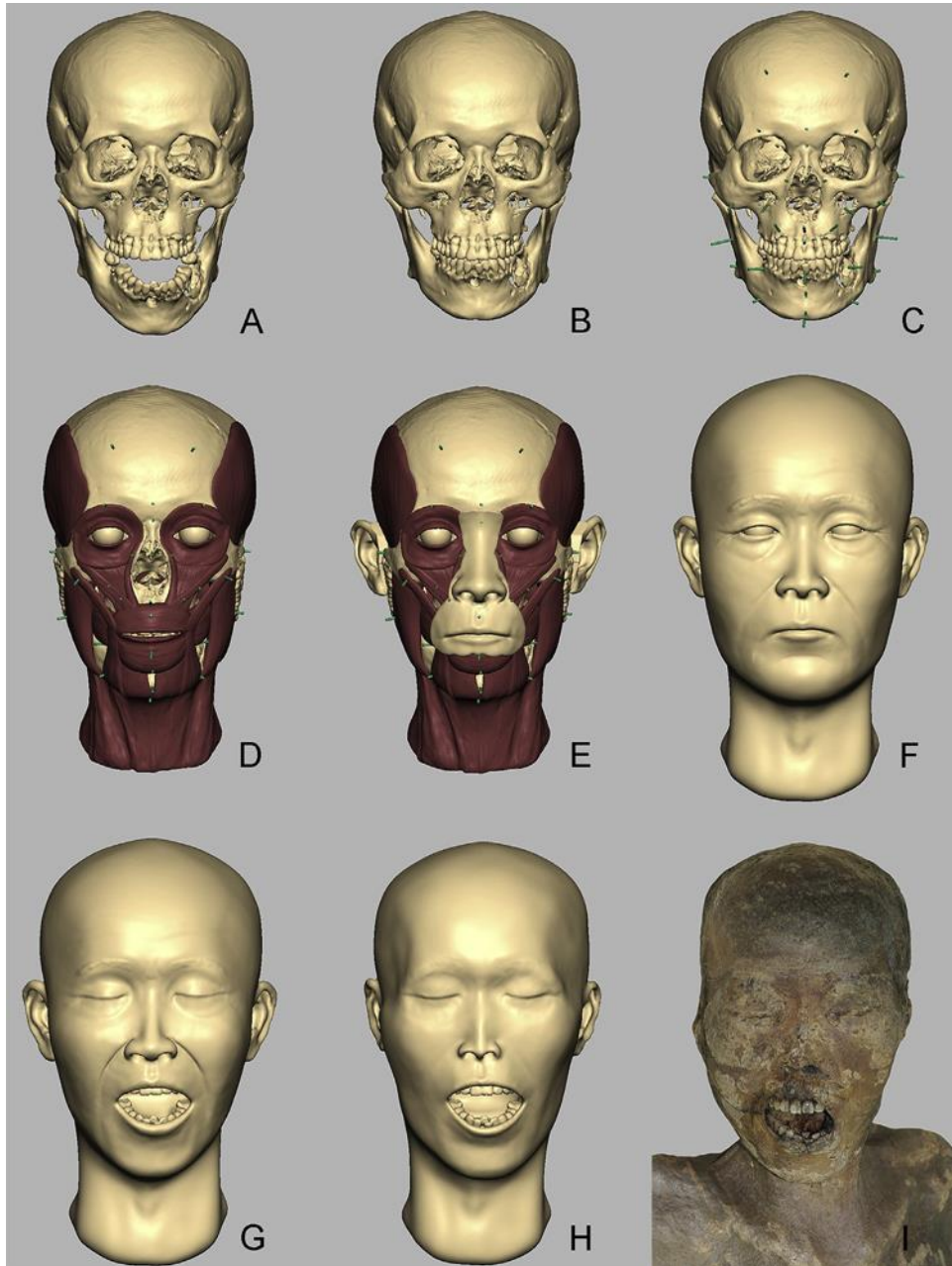


Fig. 2. The procedure of making CFRs using Freeform® Modelling System. (A) The skull image from original head of the mummy with open jaw; (B) The skull image after the replacement of lower jaw to normal occlusion; (C) The skull image after tissue depth pegs being placed to corresponding landmarks; (D) Completion of facial musculature; (E) Completion of modelling facial components; (F) CFR 1, facial appearance before death with open eyelids and closed jaw; (G) CFR 2, facial appearance before death with closed eyelids and open jaw; (H) CFR 3, the mummified face after death with closed eyelids and open jaw; (I) Photographic image of the actual mummy face.

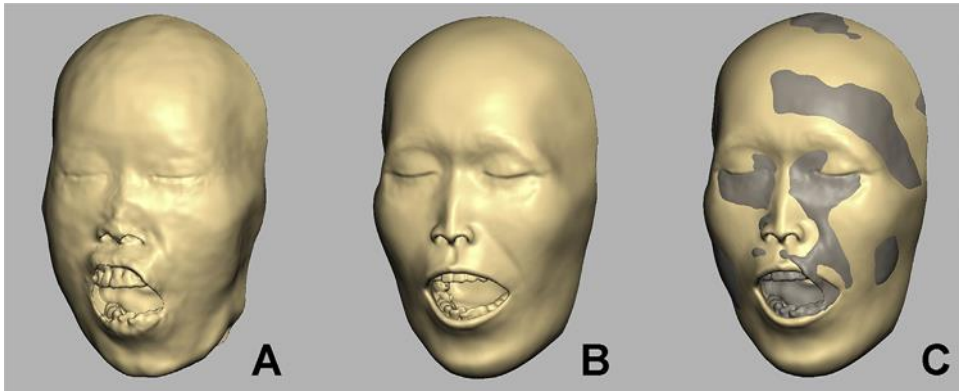


Fig. 3. Alignment of 3D CT scanned mummy face and CFR 3. (A) 3D image of the CT scanned mummy face; (B) CFR 3 cropped the rest of the head for the comparison; (C) Aligned the mummy face and CFR 3 in Freeform® Modelling System.




Fig. 4. Deviation map for the surface comparison between the mummy head and CFR 3 in Geomagic® Control™ software. The colours on the spectrum bars and the face of the mummy indicate the distribution of the discrepancies comparing to CFR 3: 'green' representing the deviation of within ± 1.0 mm; 'yellow to red' representing from above ± 1.0 to ± 12 mm; 'darkening blue' representing from below -1.0 mm to -12 mm. The '+' (the areas of the yellow to red) implies that the skin surface of CFR 3 is more prominent than the subject's face, and the '-' (the areas of the bluish colour) implies that the skin surface of CFR 3 is less prominent than the subject's face. (For interpretation of the references to colour in this figure legend, the reader is referred to the web version of this article.)

Table 1

Distribution (%) of the deviation error between the surfaces of CFR 3 and the face of the mummy within each defined range (minimum range within ± 2.5 mm).

Deviation (X: mm, minimum range within ± 2.5 mm)	$X < -5.0$	$-5.0 \leq X < -2.5$	$-2.5 \leq X \leq 2.5$	$2.5 < X \leq 5.0$	$5.0 < X$	Total (%)
Occupied surface (%)	1.1	2.7 94.5	79.9	11.9	4.4	100




Fig. 5. Illustration of CFR 1 wearing coat and headband discovered in the same coffin.




Fig. 6. The actual coat (jangot)(A) and headband (manggon)(B) discovered in the coffin; (C) The headband depicted in the illustration.



Fig. 7. The illustrated bust converted into the portrait-styled drawing in Joseon period.

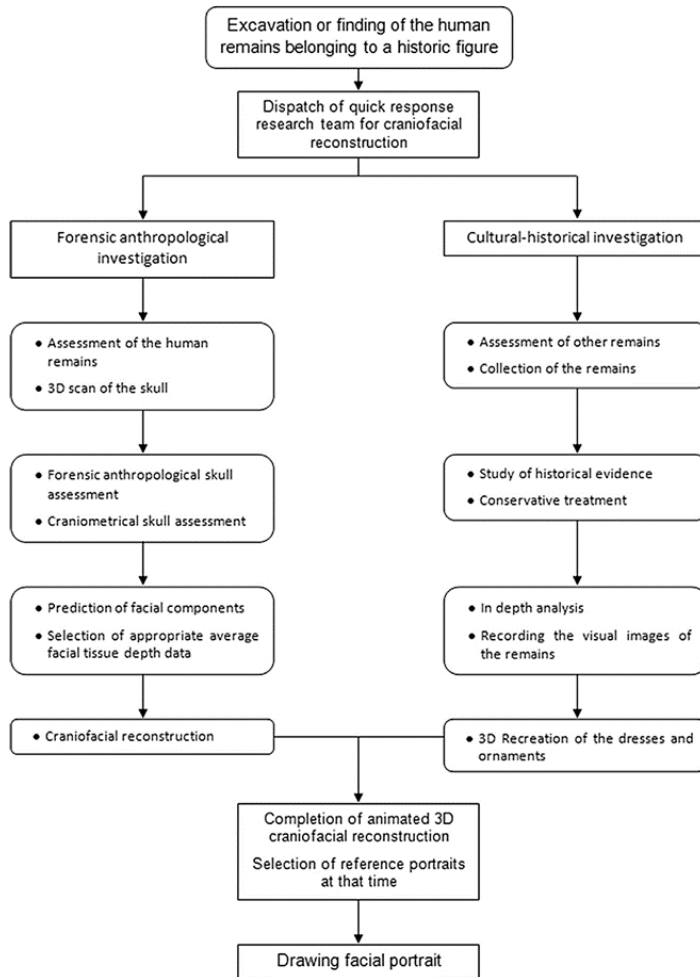


Fig. 8. Flow chart showing how CFR and CFR-based portrait (or statue) could be made by examination of historical figures' tombs and relevant data.