

Northumbria Research Link

Citation: Evison, Martin (2016) Forensic facial reconstruction and its contribution to identification in missing person cases. In: Handbook of Missing Persons. Springer, New York, pp. 427-441. ISBN 978-3-319-10197-3

Published by: Springer

URL: http://link.springer.com/chapter/10.1007/978-3-319-40199-7_28
<http://link.springer.com/chapter/10.1007/978-3-319-40199-7_28>

This version was downloaded from Northumbria Research Link:
<http://nrl.northumbria.ac.uk/29016/>

Northumbria University has developed Northumbria Research Link (NRL) to enable users to access the University's research output. Copyright © and moral rights for items on NRL are retained by the individual author(s) and/or other copyright owners. Single copies of full items can be reproduced, displayed or performed, and given to third parties in any format or medium for personal research or study, educational, or not-for-profit purposes without prior permission or charge, provided the authors, title and full bibliographic details are given, as well as a hyperlink and/or URL to the original metadata page. The content must not be changed in any way. Full items must not be sold commercially in any format or medium without formal permission of the copyright holder. The full policy is available online: <http://nrl.northumbria.ac.uk/policies.html>

This document may differ from the final, published version of the research and has been made available online in accordance with publisher policies. To read and/or cite from the published version of the research, please visit the publisher's website (a subscription may be required.)

www.northumbria.ac.uk/nrl



Evison, M.P., Iwamura, E. S. M. and Guimarães, M.A.G. (2016). Forensic facial reconstruction and its contribution to identification in missing person cases. In Morewitz, S.J. and Sturdy Colls, C. (eds.), *Handbook of Missing Persons*, New York: Springer, p. 427-41. ISBN 978-3-319-10197-3 (print), 978-3-319-40199-7 (online) doi:10.1007/978-3-319-40199-7_28

Evison, M.P., Iwamura, E. S. M. and Guimarães, M.A.G. (2016). Forensic facial reconstruction and its contribution to identification in missing person cases. In Morewitz, S.J. and Sturdy Colls, C. (eds.), *Handbook of Missing Persons*, New York: Springer, p. 427-41. **ISBN** 978-3-319-10197-3 (print), 978-3-319-40199-7 (online) **doi**:10.1007/978-3-319-40199-7_28

This text is the **Accepted Manuscript**. The final volume can be found [here](#).

FORENSIC FACIAL RECONSTRUCTION AND ITS CONTRIBUTION TO IDENTIFICATION IN MISSING PERSON CASES

MARTIN PAUL EVISON, EDNA SADAYO MIAZATO IWAMURA, MARCO AURÉLIO GUIMARÃES AND
DAMIAN SCHOFIELD

Martin Paul Evison, Northumbria University Centre for Forensic Science, Northumbria University, Newcastle Upon Tyne, England NE1 8ST, martin.evison@northumbria.ac.uk

Edna Sadayo Miazato Iwamura, Department of Pathology, Paulista Medical School - Federal University of São Paulo, Rua Botucatu, 740 – Edifício Lemos Torres, São Paulo, SP, 04023-900 Brazil

Marco Aurélio Guimarães, CEMEL, Departamento de Patologia – FMRP-USP, Rua Tenente Catão Roxo, 2418, Ribeirão Preto, SP, 140051-140 Brazil

Damian Schofield, Department of Computer Science, State University of New York at Oswego, 7060 Route 104, Oswego NY, 12126-3599 USA

ABSTRACT

Forensic facial reconstruction is a means for producing a facial surface from the skull. There are several technical approaches that can be applied, which include computerised and plastic sculptural methods. Whether the reconstruction is attempted in virtual or actual reality, the facial surface is projected by one of two principal means: by reconstruction of the craniofacial anatomy or by mathematical extrapolation of the face surface from that of the skull. More recently, it has been possible via a combination of the two. In this chapter, the history of facial reconstruction from the skull will be briefly introduced and the principal methods described. Both plastic and computational approaches will be summarised. The utility of forensic facial reconstruction will be discussed with reference to the investigation of cases of missing persons, and to current controversies in research and practice, relating to the precision and efficacy of the technique.

Keywords: Facial reconstruction, facial approximation, forensic science, identification, missing persons, forensic anthropology

28.1. INTRODUCTION

The earliest attempts to reconstitute the face from the skull so far recognised appear to arise from the Pre-Pottery Neolithic B (PPNB) culture of circa 11,000 – 8,000 BP (Settegast 1990) centred on Jericho and adjacent regions of Jordan and the West Bank (Figure 1). Archaeologists interpret these objects as having played a role in funerary, ancestor-worship, or similar such rites. These reconstructions were completed by modelling a facial surface in plaster. The eyes and eyelids were often replaced with cowry shells, and the skin complexion and facial features—including moustaches—were painted onto the plaster surface. The reconstructions are described as ‘typized and conventional’ and are not believed to represent reconstructions of ante-mortem appearance, beyond ‘some features determined by the bony framework’ (Strouhal 1973, p. 231). Nine millennia were to pass before the first scientific attempts to reconstruct ante-mortem appearance were to arise.

As empirical science grew in significance during the 18th and 19th centuries, efforts were made to collect measurements that could be applied to the hard-tissue surface of the skull in order to project the location of the soft-tissue surface. These tissue-depth measurements were collected from cadavers at specific locations on the face surface; referred to as landmarks. These measurements were then applied to roughly corresponding landmarks on the skull which is the subject of a facial reconstruction (Kollman and Buchly 1898). Early attempts at facial reconstruction were applied to sculptural portraits of Johann Sebastian Bach (His 1895) and Friedrich Schiller (Welcker 1883).

In the early part of the twentieth century, facial reconstruction was adopted for use in investigations into the identification of human remains. One of the most celebrated—but not necessarily the earliest—practitioners of the era was Mikhail Gerasimov of Leningrad (now St Petersburg) and Moscow. In *The Face Finder*, Gerasimov (1971) acknowledges earlier attempts to reconstruct the face from prehistoric archaeological finds—such as those of Hermann Schaafhausen who, with Carl Fuhlrott, is credited with the discovery of Neanderthal Man—and the scientific efforts of Kohlmann and Buchly (see above). Gerasimov then recounts the development of his own approach and its application in a variety of forensic and archaeological contexts—among which the reconstructions of Valentina Kosova (Figure 2) and Ivan IV Vasilyevich (Ivan the Terrible—Figure 3) are prominent.

The latter part of the twentieth century saw a consolidation of methods into ones predominantly based on the reconstitution of the features of soft tissue anatomy (Tyrell et al. 1997) —frequently supported by some use of measurements—and ones solely based on the use of measurements, where the face surface is extrapolated from that of the skull (Wilkinson 2008, Prag and Neave 1997). It also saw the adoption of computerisation, which permitted 3D digitization of the skull and reconstruction in virtual reality (VR) (Vanezis et al. 1989).

In this chapter, the term reconstruction is used to refer to both the process of restitution of a facial surface from that of the skull, as well as to the finished article. Reconstruction, however, is an ambiguous term. It should not be taken to imply that the result is an exact likeness of the ante-mortem face. This outcome is probably impossible to achieve. Reconstructions are in reality approximations—an alternative term frequently used in the literature—that offer widely ranging degrees of resemblance to the individual during life. In this chapter, the principle methods of facial reconstruction will be reviewed, including computerisation, and the value of facial reconstruction in missing person cases will be considered with reference to current controversies in the field.




Figure 1. Faces constructed on skulls using plaster from Tell Aswad, Syria, 7,000-6,000 BC. Source: www.diplomatie.gouv.fr



Figure 2. Gerasimov's reconstruction of Valentina Kosova (Gerasimov 1971)

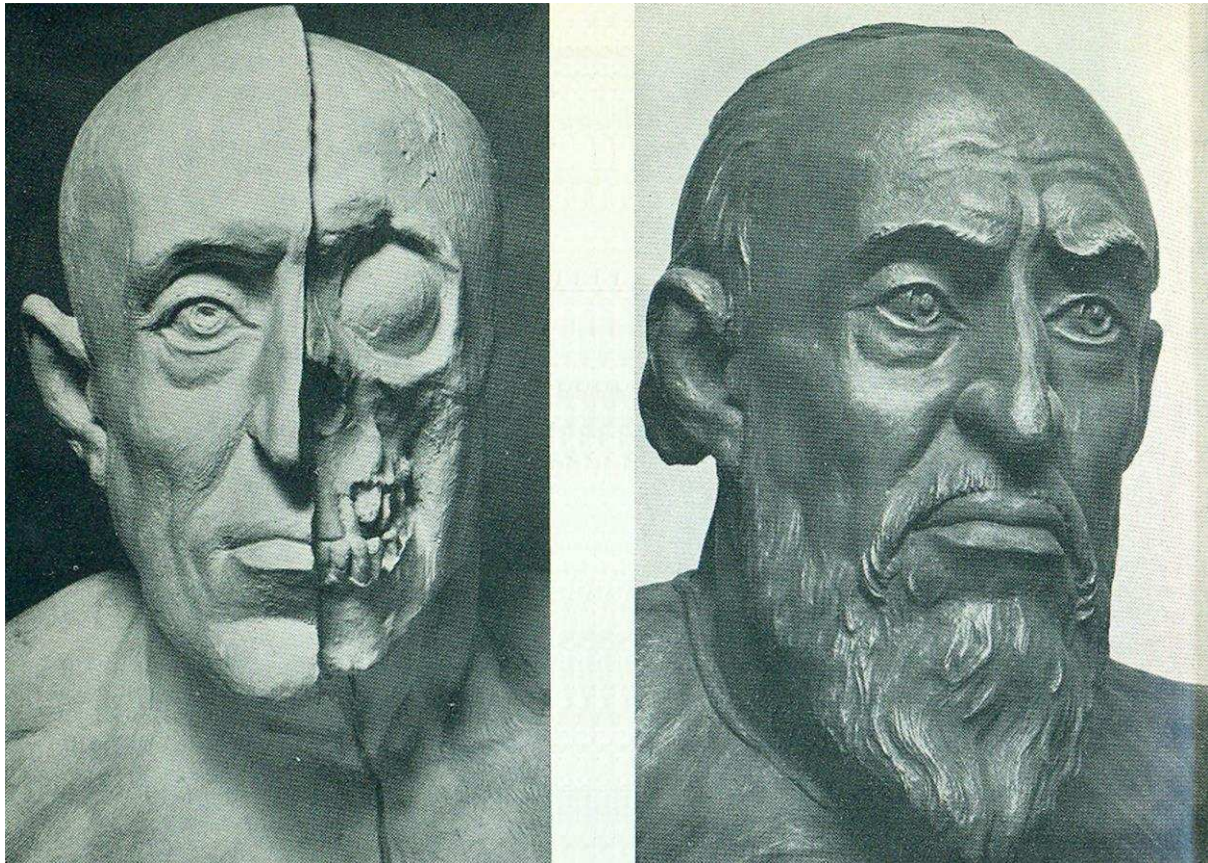


Figure 3. Gerasimov's reconstruction of Ivan IV Vasilyevich—The Terrible (Gerasimov 1971).

28.2 TECHNICAL APPROACHES TO FACIAL RECONSTRUCTION

The anatomy-based method of facial reconstruction—sometimes called the Russian method in deference to Gerasimov—relies on the reconstitution of the soft tissue anatomy (Figure 4). Measurement-based methods—coined, in contrast, the American method (see below)—rely on the hard tissue surface as a template for the soft tissue surface. In the case of both the Russian and American methods, geometric methods derived from research studies and from the canons of sculpture are used to estimate the basic dimensions of the eyelids, nose and lips. In the case of both the Russian and American methods, however, it is important to note substantial regions of the face are not simply a projection of the underlying bone structure. Much of the soft part of the nose, eyes and eyelids correspond to voids in the skull. The lips overlay the dentition, but the underlying hard tissue does not precisely determine the shape of the lips. In the case of the eyeballs and eyelids, the nose, and the lips, the general dimensions can be estimated from the hard tissues but cannot be precisely determined (Reichs and Craig 1997; George 1993).

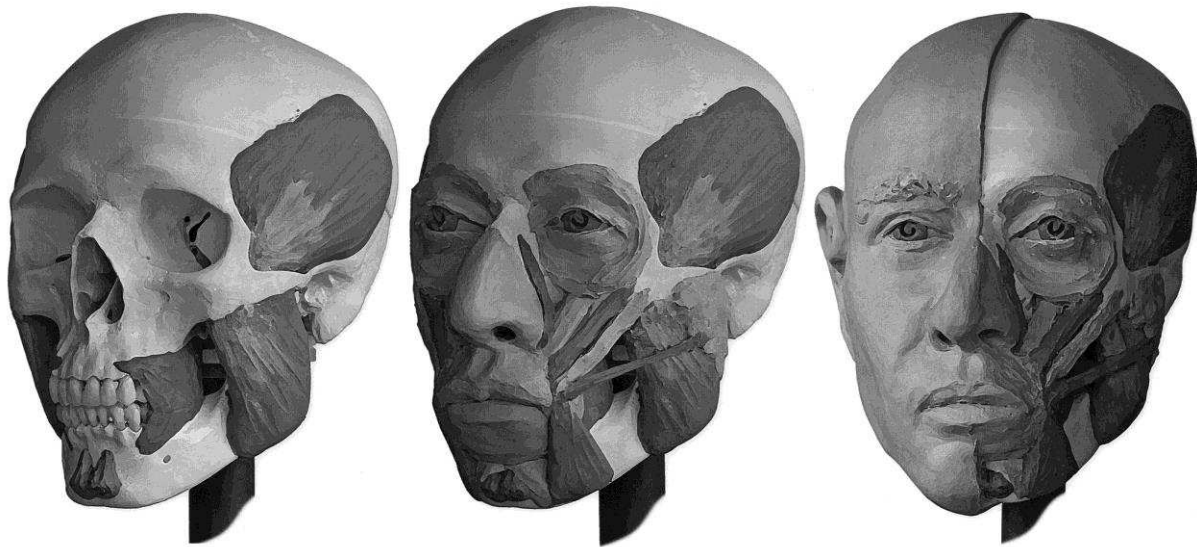


Figure 4. Russian Method (Copyright: Susan Hayes, University of Woollongong, with kind permission of the author).

28.2.1 The American Method

Figure 5 illustrates a reconstruction performed directly on to the surface of a skull using the American method. This reconstruction was undertaken in the 1990's: current practice would be to perform the reconstruction on a cast taken from the skull. This introduces a source of potential error, but is seen to be more sensitive to current expectations regarding the ethical treatment of human remains.

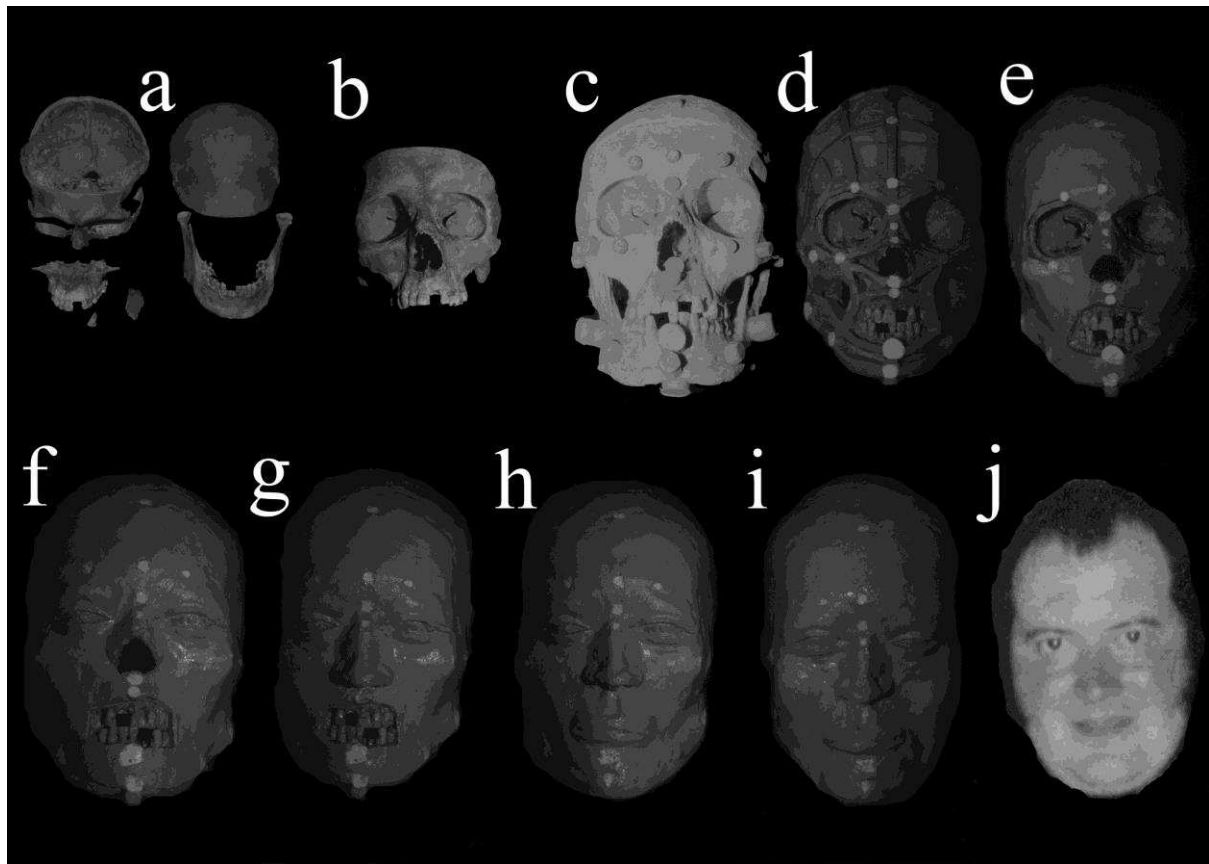


Figure 5. Reconstruction onto the skull using the American method with accompanying ante mortem photograph of the 'missing person' following identification (Reconstruction by Martin Evison); a) disassembled skull following autopsy, b) reassembled maxilla, c) soft tissue depth markers in situ, d) tissue depth interpolated between markers, e) soft tissue depth interpolated into interstices, f) eyeball and eyelids modelled, g) nasal tip modelled, h) lips modelled, i) fullness of face increased, j) ante mortem photograph of subject (© Martin Evison).

The reconstruction was performed following the removal of the soft tissues. This was achieved by treatment of the remains in hot water (~90°C) in the presence of the papain facilitating the digestion of proteins and of detergent facilitating the dispersion of fats. This treatment may last several days, depending on the rapidity with which the defleshing process takes place. Following removal of the soft tissues the clean skeletal material is washed with methylated spirit to remove residual fats and odour. In this case, defleshing was performed following autopsy and odontological examination, during which the calvarium and maxilla had been separated (Figure 5a). The skull was carefully reassembled from the parts, taking care to adjust for skeletal material lost during the post-mortem separation (Figure 5b).

The American method relies on average measurements collected in research at about thirty landmark sites on the skull used as guides to soft tissue depth. Figure 5c illustrates the placement of average soft tissue depth markers at landmark sites on the skull. The significance of these markers and variation in their measurement values are considered in further detail below. As Figure 5c illustrates, however, these are distributed widely over the skull surface, but certain areas of the face—most notably the orbits, nasal cavity and dentition—are not represented. In this example, clay was used to model the soft tissue depths. Wooden or plastic pegs may be used as an alternative, which requires holes to be drilled into the surface—a practice therefore likely to be restricted to a cast facsimile and not to the skull surface itself for ethical reasons.

Figure 5d illustrates the modelling of a lattice by interpolation between tissue depth markers using a ‘plastic’ or clay-based approach. Figure 5e illustrates the modelling in clay of the interstitial spaces in the lattice. The voids associated with the orbits, nasal cavity and dentition are particularly clear at this stage. The eyeballs and eyelids, nasal wings and tip, and the lips are reconstructed following established guidelines in the literature (Fedosyutkin and Nainys 1993, George 1993, Prag and Neave 1997).

Figure 5f illustrates the reconstructed eyeball and eyelids. The conventional approach is to model the eyeballs in clay, ensuring a tight fit into the eye socket. The eyelids are then modelled over the eyeball surface using guidelines associating the commissures of the inner and outer canthi with bony features on the margins of the orbits. The nasal tip (Figure 5g) is modelled by projecting the tip as a point triangulated by imaginary lines from the base of the nasal cavity and the nasal bridge, and by modelling the width of the alar wings beyond the actual margin of the bony nasal cavity. Similar contentions are also followed for modelling the width and height of the lips (Figure 5h).

Whilst the gross dimensions rely on conventions in the literature, there is a good deal of latitude available in the modelling of the facial features in particular. This is important in taking account of the age, sex and ancestry estimated from the skeletal remains—in this case a White male of greater than 45 years-of-age (Figure 5j). Similarly, while average soft tissue depths are typically used, the reconstructed model may take into account a degree of obesity associated with middle age—as attempted in this example (Figure 5i).

28.2.2 The Russian Method

The Russian method relies on the reconstitution of the soft tissue anatomy. It is possible to locate the origin and insertion sites of a number of craniofacial muscles, which offer some guidance to the location, and general size and shape of the muscles concerned—the temporalis, masseter, and buccinators, for example (Figure 4). Placement of the muscles is inevitably subjective, as their precise depth along any point in their cross-section is unknown.

Figure 6 illustrates the Russian method as applied in the reconstruction of a White male youth. In this instance, tissue-depth markers are also followed as a guide. This is a widely-used method of facial reconstruction, popularised by Wilkinson (2008) and co-workers. In Figure 6a the tissue-depth markers are inserted into a plaster cast of the skull. Figure 6b illustrates modelling of the temporalis, buccinators, masseter and levator anguli oris muscles, Figure 6c modelling of the orbicularis oris and placement of the eyeball and Figure 6d the frontalis, levator labii superioris, depressor anguli oris and mentalis muscles, and modelling of the height and width of the lips. In Figure 6e the orbicularis oculis is modelled, taking into account the position of the commissures of the inner and outer canthi of the eye, and the position of the nasal tip is projected. Figure 6f illustrates the completed model of the face surface reconstructed to reveal underlying anatomy.

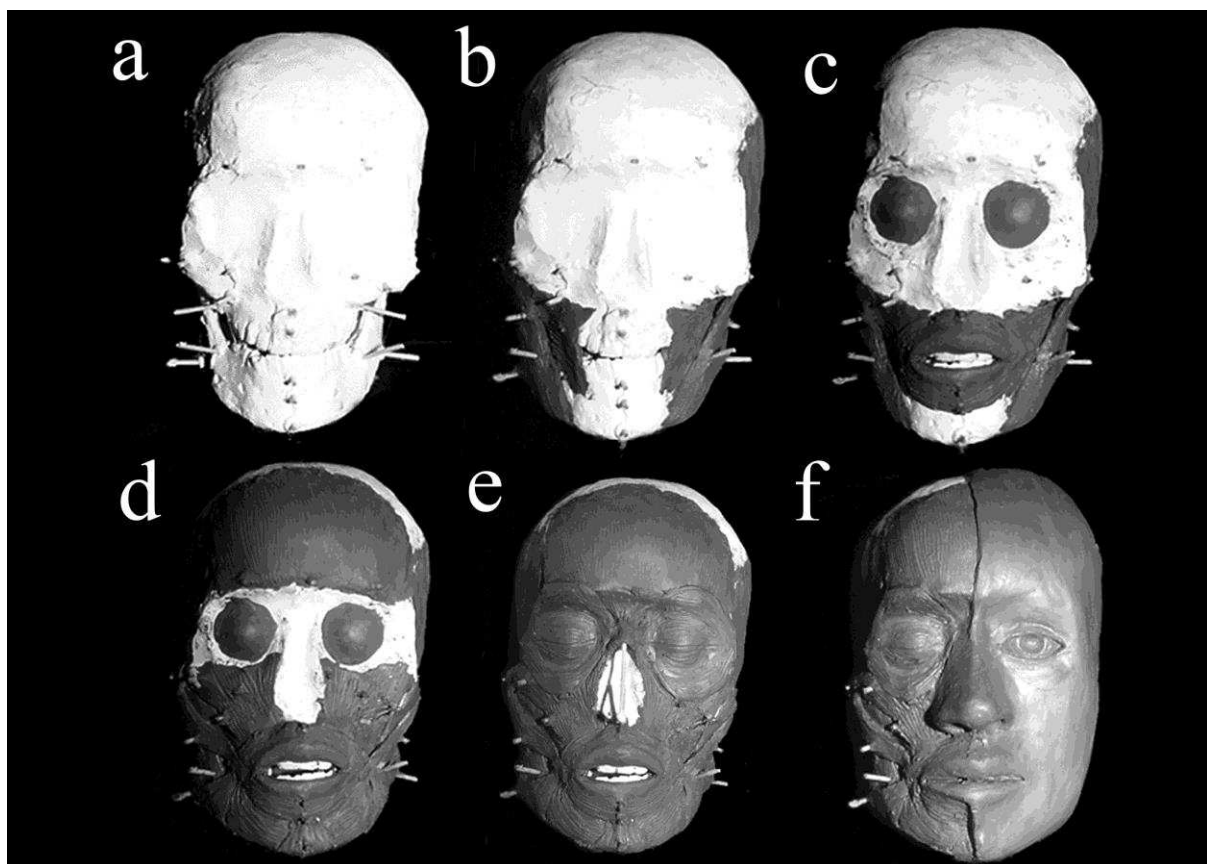


Figure 6. Reconstruction onto a plaster cast of the skull using the Russian method with accompanying use of tissue depth markers (Reconstruction by Nikki Taylor); a) soft tissue depth markers in situ, b) modelling of the temporalis, buccinators, masseter and levator anguli oris muscles, c) modelling of the orbicularis oris and placement of the eyeball, d) modelling of the frontalis, levator labii superioris, depressor anguli oris and mentalis muscles, and modelling of the height and width of the lips, e) modelling of the orbicularis oculis muscles, taking into account the position of the commissures of the inner and outer canthi of the eye—the position of the nasal tip is also projected, f) completed face surface revealing underlying anatomy (© Martin Evison).

28.3 COMPUTERISED APPROACHES

Computerised approaches to facial reconstruction from the skull tend to be analogous to the plastic methods, undertaken in ‘virtual reality’ (VR). Following pioneering forensic work by Vanezis et al. (1989), Tyrell et al. (1997) reviewed research in the field and described the process of 3D data capture and post-capture processing—which permits reconstruction of the skull from bone fragments, for example (Figure 7).

A 3D VR facsimile of the skull is amenable to facial reconstruction using a variety of approaches. One common approach is based upon collection of a ‘volume’ tissue depth dataset from a living individual using computed tomography (CT) of the head and neck. CT is based on x-ray radiology, which yields a strong signal from the underlying hard tissue of the subject’s face. Attardi et al. (1991), for example, used a volume tissue-depth dataset derived from CT which they deformed over the surface of a skull of an Egyptian mummy obtained by x-ray radiography. The reconstruction is finished by rendering or ‘texture mapping’ the photographic image of the face of a living Egyptian individual over the surface of the reconstruction, yielding a life-like appearance.

VR modelling can be used to generate a facial surface using approaches analogous to the American and Russian plastic methods. In Figures 8 and 9, the reconstruction of the faces of Egyptian mummies is again shown, this time employing methods that simulate the traditional techniques. Figure 8 shows reconstruction of the face surface using tissue depths—similar to the American method. Figure 8a shows the ‘lofting’ or projection of a primitive 3D surface of the skull from 2D x-ray radiographs of the mummy. Figure 8b shows an intermediate stage where the mandible was rearticulated in VR as it appeared to have been dislocated in the ancient remains. Figure 8c shows the completed superimposition of markers representing the soft tissue depths at traditional

landmark sites, as well as a series of mathematically interpolated pseudo-landmarks spaced at regular intervals between them. Figure 8d shows a simple face texture modelled on the face surface without texture mapping the photograph of a living individual.

Figure 9 shows the facial reconstruction in VR of a mummy believed by some experts to be that of Queen Nefertiti (ca. 1370 – ca. 1330 BC; Fletcher 2005). Whilst Figure 9a shows the 2D digital x-ray radiographs collected *in situ* marked up for lofting, Figure 9b shows the 3D surface projected from the 2D radiographs and the facial musculature modelled in VR following the Russian method. Figure 9c shows a simple face texture modelled on the face surface, again without texture mapping the photograph of a living individual. Figure 9d shows an alternative version of the finished reconstruction with the face surface texture mapped using the photograph of a living individual.

The advent of computerisation has opened up possibilities for facial reconstructions that are rapid, automated, easily disseminated, and flexible or adjustable according to a range of parameters that can be selected to reflect uncertainties arising from osteological or investigative evidence. Figure 10 illustrates, for example, VR modelling of a range of variation in age, obesity and biogeographic ancestry that can be presented on the Internet (Green and Evison 1999; Evison and Green 1999). These early models allow the shape and colour of finished VR models to vary within the range of uncertainty implied from forensic osteological and odontological analysis, or from other investigative findings. Figure 7 shows the reassembly in VR of the components of the skull that had to be reassembled manually in the plastic reconstruction demonstrated in Figure 5.

Computational models continue to suffer from a paradox in that purely virtual reconstructions tend to have an artificial and sometimes ‘mannequin-like’ appearance, whereas those finished by texture mapping a photograph tend to resemble the individual depicted in the photograph. Interpolating between facial surface textures may offer one solution to this problem (Green and Evison 1999). Alternatively, using averaged photographs overcomes the resemblance of the reconstruction to a particular individual, and it is axiomatic that an average face surface texture is likely to be closer in appearance to the real individual than a distinctive face surface texture—unless there is a good reason for including it. Distinctive features—such as in the dentition or other empirically determined features—are factors that should be emphasised. As caricature frequently demonstrates, these can aid recognition (McIntyre et al. 2013). Furthermore, research in face perception suggests that rendering an average face surface texture where the real face surface texture is unknown may increase the prospects of identification as it may enhance the distinctiveness of other—and known—

aspects of facial appearance, such as those determined by the shape of the underlying hard tissues (Little et al. 2012). Computerisation offers considerable potential in facial reconstruction. However, the long-standing promise of an affordable, powerful, and easy-to-use online application remains unfulfilled.

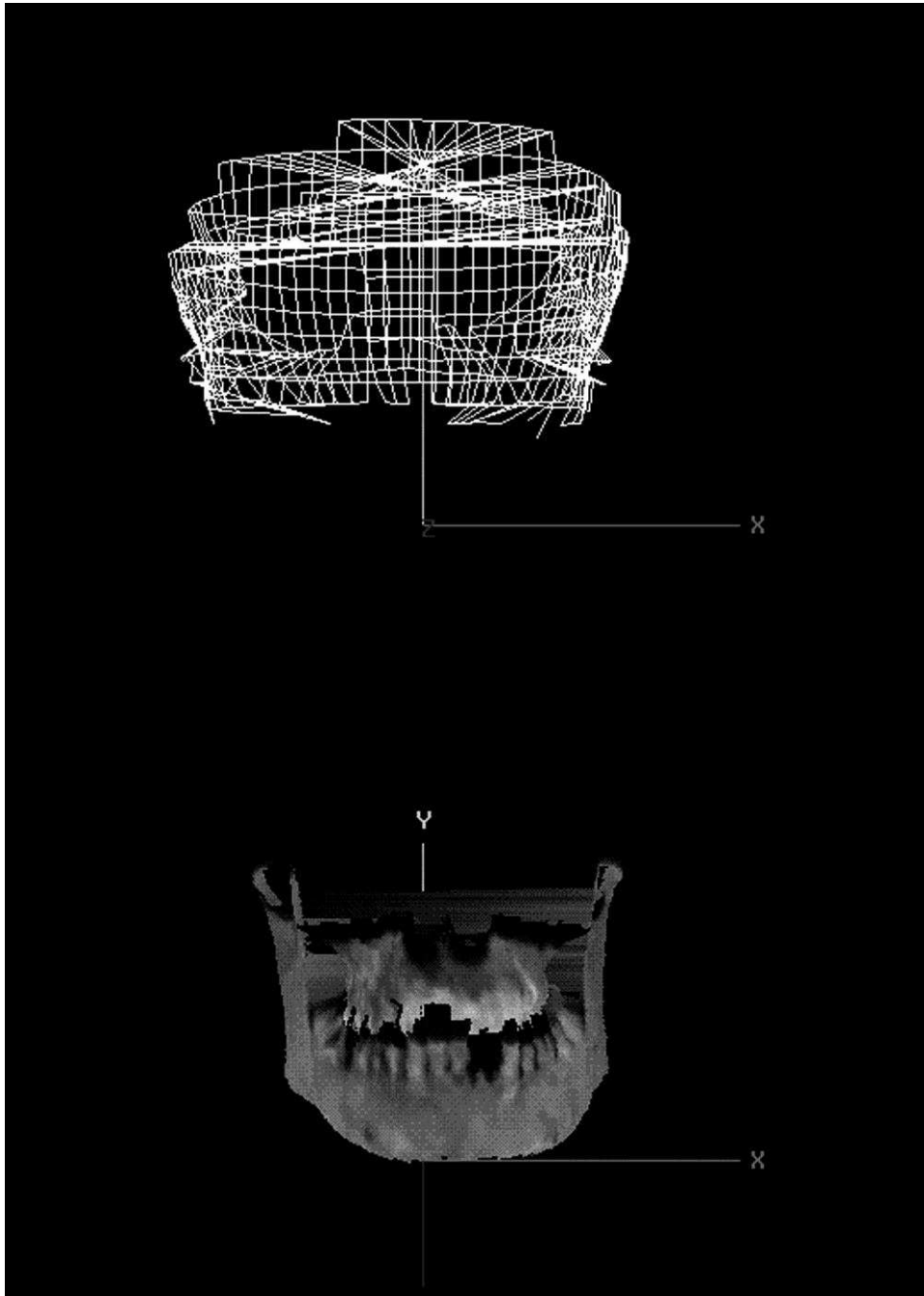


Figure 7. Reconstruction of skull in virtual reality from separately scanned components. The mandible, maxilla and part of cranium shown are the 3D digitally captured skull elements shown in Figure 5a. (© Martin Evison).

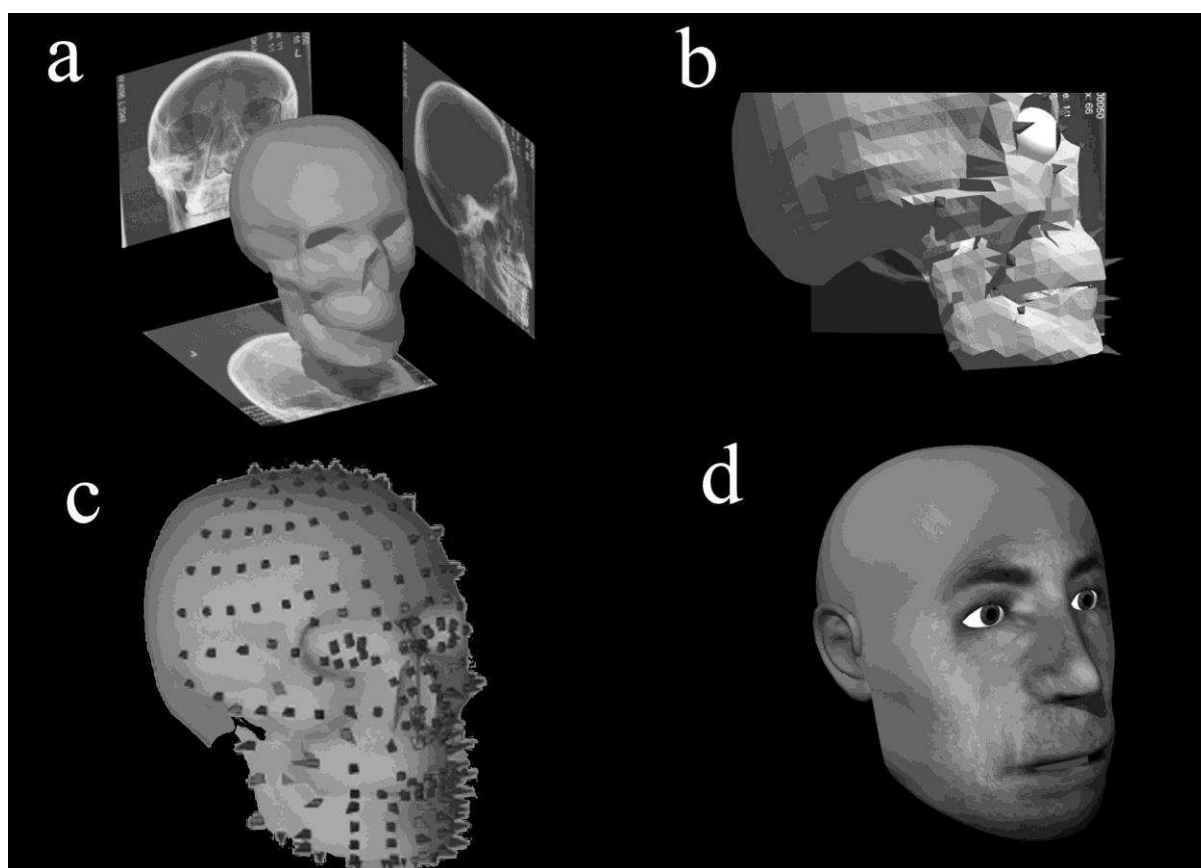


Figure 8. Stages in the reconstruction in virtual reality of an Egyptian mummy using the American method (reconstruction by Martin Evison and Damian Schofield, State University of New York Oswego); a) lofting of primitive 3D surface from 2D digital x-ray radiographs, b) adjustment in VR of displaced mandible, c) placement of soft tissue depth landmarks (dark grey) and interpolated pseudo-landmarks (light grey), d) face surface texture modelled in VR (© Damian Schofield and Martin Evison).

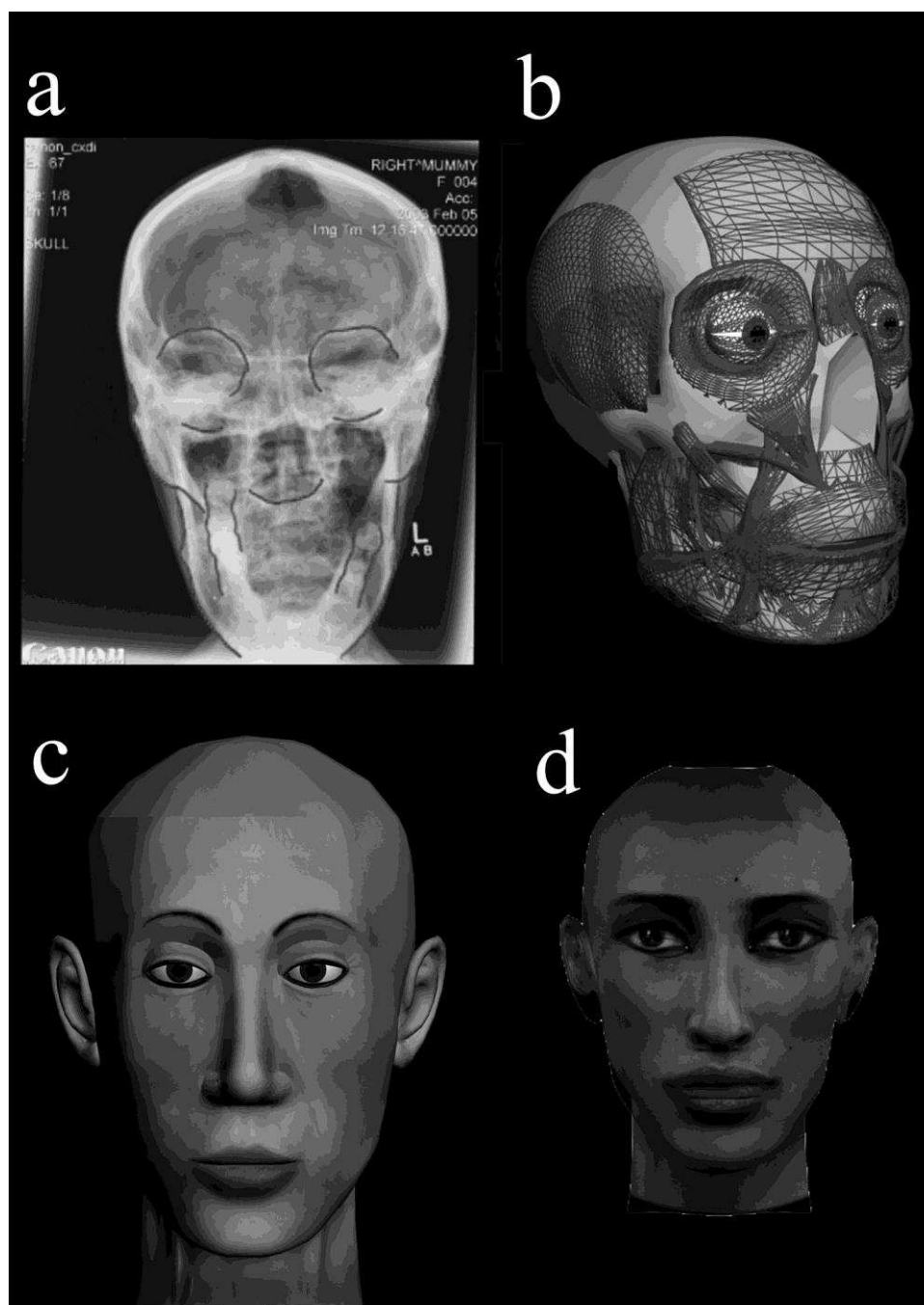


Figure 9. Stages in the reconstruction in virtual reality of an Egyptian mummy using the American method (reconstruction by Martin Evison and Damian Schofield, State University of New York Oswego); a) 2D digital x-ray radiograph marked for lofting (see Figure 8a), b) craniofacial musculature reconstructed in VR, c) face surface texture modelled in VR (© Damian Schofield and Martin Evison), d) face surface rendered using the photograph of a living individual (© Atlantic Productions).

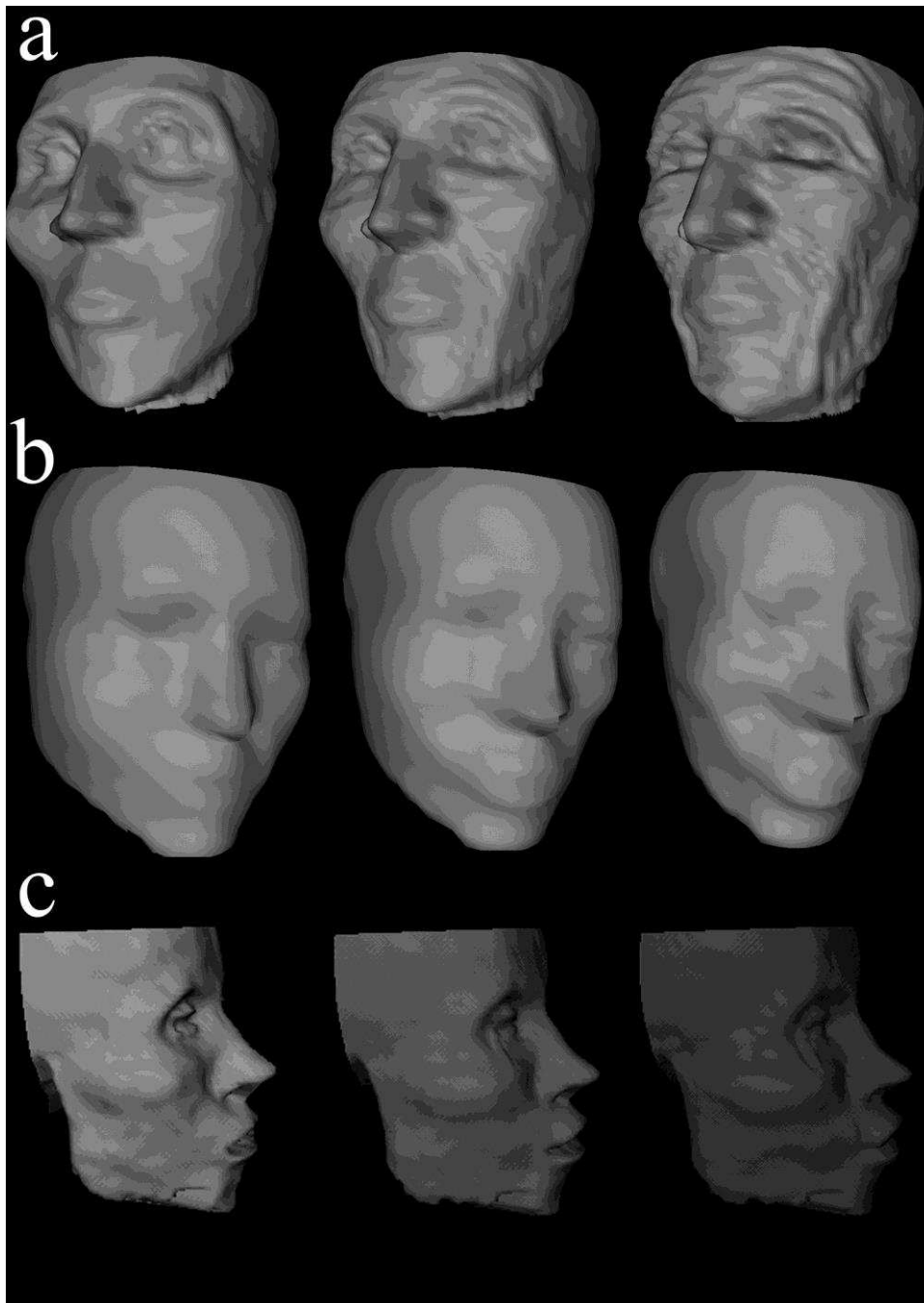


Figure 10. Models demonstrating 3D animated VR on the Internet (Evison and Green 1999) and the modelling of a) ageing, b) obesity and c) ancestry (Green and Evison 1999)

28.4. THE VALUE OF FORENSIC FACIAL RECONSTRUCTION IN MISSING PERSONS CASES

The precise role of facial reconstruction in investigation is contentious. It might be assumed that a reconstruction of high artistic quality, with a life-like facial appearance, of the correct age, sex and ethnic group, and bearing a strong resemblance to the individual during life is essential to secure

identification. In reality, case examples testify to the observation that identifications can be obtained from reconstructions that are of poor—or mannequin-like—sculptural quality, of limited resemblance and of the wrong race (Prag and Neave 1997).

Figure 11 shows a set of reconstructions produced during the long investigation of human remains found dumped in a suburban hedgerow. Not unusually, there was some uncertainty regarding the biogeographic ancestry of this individual: the remains were found in a region of England with a high level of immigration from South Asia, and both White and South Asian reconstructions were produced. There was also some initial uncertainty regarding the age and sex of the individual, and at least one androgynous reconstruction was produced. Slightly different age estimations were offered by the forensic anthropologists and odontologists consulted, placing the individual in their teens or twenties. Ultimately, the individual was identified as a known missing person by DNA analysis—a White female of 18 years-of-age—allowing the reconstructions to be compared with ante-mortem photographs.

Figure 12 shows an unsolved case where a similar miscommunication led to the modelling of male and female reconstructions based on the same remains, believed to be those of a South East Asian. The case illustrated in Figure 5 concerned a middle-aged White male whose remains were initially unidentified because investigative information from the subject's mother had led the police to believe he was 6" shorter than he really was. A key found in the subject's clothing allowed the misunderstanding to be resolved and the missing person enquiry to proceed.

These cases illustrate the somewhat subjective nature of assessing resemblance in facial reconstruction cases and of the uncertain role of precision in investigation and artistic quality in yielding recognition. In order to investigate some these issues, Stephan and Henneberg (2001) measured recognition rates using 16 facial reconstructions accompanied by photographs of the living individual and found that 403 incorrect identifications were made from 592 comparisons. Using a similar approach in a further study, Stephan (2002a) found that the accuracy of a facial reconstruction is not related to whether it is subjectively assessed resemblance. This observation tends to complement a commonly-held belief amongst some practitioners that successful recognition in facial reconstruction cases is not related to artistic quality. In fact—as the case of a reconstruction completed following a misunderstanding of the deceased's race illustrates (Prag and Neave 1997)—resemblance may be entirely secondary to the publicity surrounding the publication of a reconstruction in the print and broadcast media.

Assessment of biogeographic ancestry is not precise, particularly beyond the major continental groups—African, Indo-European, Oriental—and presents problems in cases where group differences are subtle, but individual differences may be wide. In another case (Figure 13), investigators suspected the deceased may have been Arab, although the demography of the locality where the remains were found was predominantly White. Age estimation again varied according to the osteological or odontological method used, giving a range of 45-60 years. As no distinction could be made on the basis of empirical evidence, two reconstructions were produced intended to have Arab and White appearance. Subtle differences in the generosity of the nasal tip and lips were modelled to make the distinction, within the usual published conventions for White subjects. In this instance, sufficient soft tissue survived post-mortem to assist in the estimation of the shape of the facial features, including the ears—which otherwise can be placed following sculptural canons - and the hair, including a moustache—which otherwise are guesswork. The dentition was also distinctive and helpful in soliciting identification, suggesting that modelling a subtly open mouth is desirable. Following publicity centred on the reconstruction on national television, the remains were identified by DNA analysis as those of a known missing Arab male of 73 years-of-age and ante-mortem photographs could again be compared with the two reconstructions (Figure 13).

Forensic anthropologists often rely on published guidelines based on reference samples in their analyses. The representativeness of these reference samples to the particular case under investigation is a key controversy in the field. This is particularly relevant to those regions where reference samples are not available and even more so to those regions where historic admixture has complicated the simple assignment of skeletal remains to relatively well characterised groups. This scenario applies noticeably in Brazilian forensic anthropology (Francisco 2015), where historic immigration and intermarriage has led to admixture between groups of Native South American, African, European and—more recently—Arab and Japanese ancestry. Figure 14 illustrates a reconstruction of a Brazilian individual of mixed ancestry, successfully leading to identification of a missing person.

The scientific precision of facial reconstruction remains questionable, however. As well as summarising a range of pertinent issues, Stephan et al. (2003a) have reevaluated existing conventions regarding the estimation of the mouth width (Stephan 2003b), and projection of the eyeball (Stephan 2002b) and nose (Stephan et al. 2003). They also questioned the value of using tissue-

depth data derived from different ancestry groups and even different sexes. Stephan and Simpson (2008) offer a generic set of tissue depth averages for use in reconstructions.

The question might reasonably be asked “why not just use DNA?” The value of forensic facial reconstruction in missing person cases is highlighted by this very question. It is of fundamental value where no candidate identifications are available with which post-mortem – ante-mortem comparisons can be made. In these instances, publicising a forensic facial reconstruction and any accompanying physical or other circumstantial information may be critical to a putative identification being put forward, which can subsequently be corroborated by more reliable scientific means. In contemporary forensic science, corroboration will be achieved by DNA analysis in comparison with a reference sample from family or an intimate sample from personal possessions or clothing (Chapters 22-24) . Forensic odontological comparison with ante-mortem dental records is also commonly used to confirm identity. An unusual medical history involving trauma or surgery affecting the skeleton may offer a potential alternative if neither DNA profiling nor dental comparison can be undertaken (Chapter 27). It is important to note that identification of the victim is a signal attrition point during homicide investigations. Identification of the victim is a key contribution that forensic anthropology and facial reconstruction can make to case conversion and progress (Evison et al. 2013).



Figure 11. Facial reconstructions generated by a variety of practitioners using different techniques during a lengthy missing person investigation solved by DNA analysis—two ante mortem photographs of the subject are also shown (© Martin Evison).



Figure 12. Facial reconstructions from the same skull of a South East Asian individual varied to appear male and female, respectively (© Martin Evison).




Figure 13. Reconstructions produced to accommodate Arab (centre) and White (right) appearance, compared with ante mortem photographs of the subject. The left-hand image is of the reconstruction intended to appear White. The complications of accommodating subtle variation between groups which vary widely within themselves is discussed in the text (© Martin Evison).

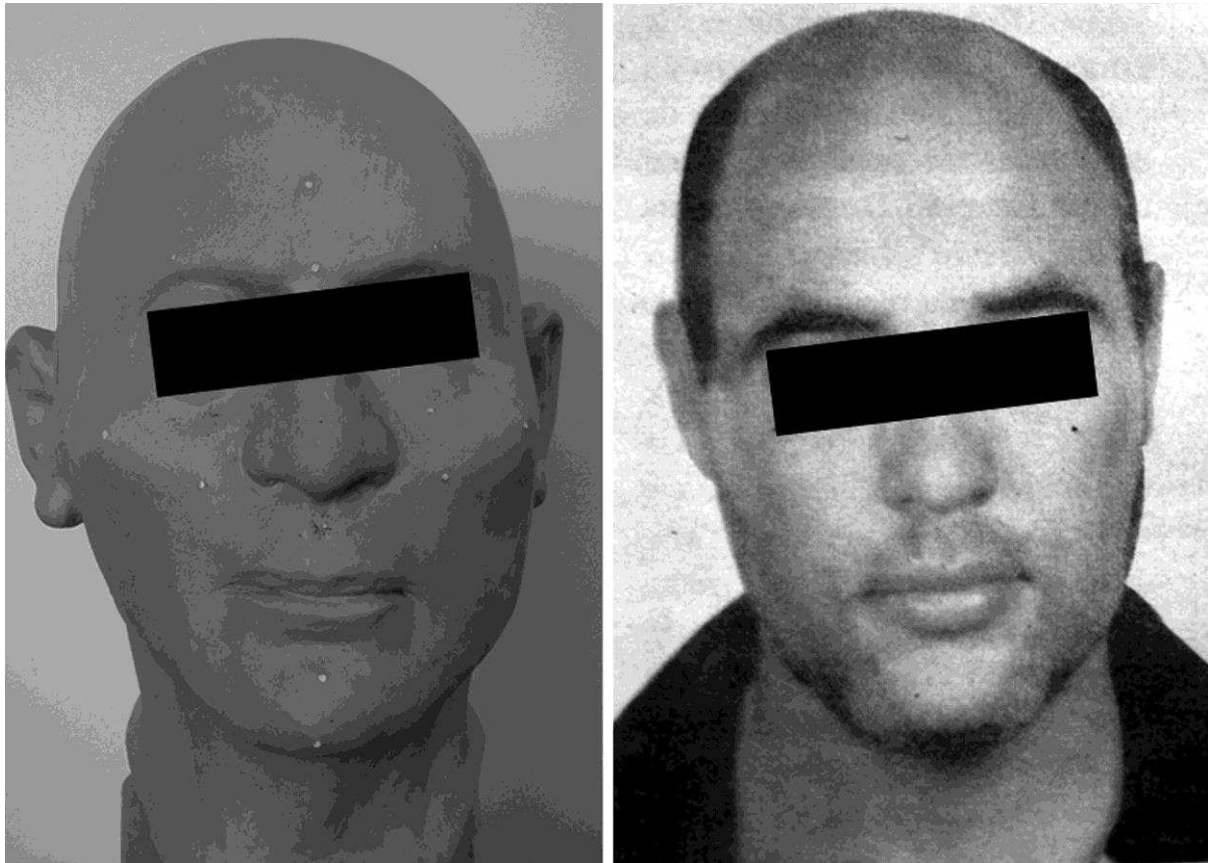


Figure 14. Further case illustration undertaken using the American method with ante mortem photograph (Copyright: Harold Capitanini, University of São Paulo Ribeirão Preto Medical School).

26.5 CONCLUSIONS

Given the overall subjectivity involved in forensic facial reconstruction, a resemblance to the individual during life is the best that can usually be expected. In the absence of strong evidence for reliable recognition of a facial reconstruction, in many instances it is arguable that it is the interest arising from the publicity surrounding the case upon which the reconstruction centres, rather than the reconstruction itself, which leads to identification. Furthermore, public interest generally leads to a number of potential paths of inquiry where individual names are sequentially excluded by a process of elimination. Should one individual remain who cannot be excluded, further investigation is essential to confirm or exclude them as the “missing person”.

Osteological, odontological or wider investigative information that can be used to improve the accuracy of the reconstruction may prove invaluable. Experience suggests such information should nevertheless be regarded with some circumspection. In those cases where no candidate identification is available that may offer a route to comparison of DNA or odontological evidence from the remains

with those of ante-mortem reference samples, the technique is—in the absence of other means—invaluable in generating media attention that may ultimately lead to an identification, whether or not that is achieved by actual recognition of the facial image itself.

26.6 REFERENCES

Attardi, G., Betro, M., Forte, M., Gori, R., Guidazzoli, A., Imboden, S., & Mallegni, F. (1991). 3D Facial Re-construction and Visualization of Ancient Egyptian Mummies using spiral CT Data, *SIGGRAPH99 Abstracts and Applications*, 223-239.

Evison, M. P. & Green, M. A. (1999). Presenting three-dimensional forensic facial simulations on the Internet using VRML. *Journal of Forensic Sciences* 44, 1216–1220.

Evison, M. P., Francisco, R. A. and Guimarães, M. A. (2012). Approaching Utility in Forensic Anthropology. *Forensic Science Policy and Management: An International Journal* 3(2), 85-104

Fedosyutkin, B. A. & Nainys, J. V. (1993). The Relationship of Skull Morphology to Facial Features. In M. Y. İşcan & R. P. Helmer (Eds.), *Forensic Analysis of the Skull: Craniofacial Analysis, Reconstruction, and Identification*. New York: Wiley-Liss, 199-214.

Fletcher, J. (2005). *The Search for Nefertiti*. London: Hodder.

Francisco, R. A. (2015). *Analysis of skeletons exhumed with a known bioanthropological profile for establishing the best anthropological parameters to be applied to the Brazilian population in forensic anthropological examinations*. University of São Paulo [Unpublished PhD Thesis].

George, R. M. (1993). Anatomical and Artistic Guidelines for Forensic Facial Reconstruction. In M. Y. İşcan & R. P. Helmer (Eds.), *Forensic Analysis of the Skull: Craniofacial Analysis, Reconstruction, and Identification*. New York: Wiley-Liss, 215-218.

Gerasimov, M. M. (1971). *The Face Finder*. London: Hutchinson.

Green, M. A. & Evison, M. P. (1999). Interpolating between computerized three-dimensional forensic facial simulations. *Journal of Forensic Sciences* 44, 1221–1225.

Hayes, S. (2012). *3D Facial Approximation: An Introductory Lab Manual AME 1.0*. Perth, WA: UNIPrint.

His, W. (1895). Johann Sebastian Bach's gebeine and anlitz nebst bemerkungen uber dessen bilder. *Abhandlung durch Mathematik und Physik* 22: 380-420.

Kollman J. & Buchly, W. (1898). Die Persistenz der Rassen und die Reconstruction der Physiognomie prahistorischer Schadel. *Archiv für Anthropologie* 25: 329-359.

Little, A. C., Hancock, P. J. B., DeBruine, L. M. & Jones, B. C. (2012). Adaptation to antifaçes and the perception of correct famous identity in an average face. *Frontiers in Psychology* 3(19).
<http://dx.doi.org/10.3389/fpsyg.2012.00019> Accessed 20th January 2016.

McIntyre, A. H., Hancock, P. J. B., Kittler, J. & Langton, S. (2013). Improving discrimination and face matching with caricature. *Applied Cognitive Psychology* 27(6), 725-734.

Prag, J. & Neave, R. (1997). *Making Faces: Using Forensic and Archaeological Evidence*. London: British Museum Press.

Reichs, K. J. & Craig, E. (1997). Facial Approximation: Procedures and Pitfalls. In K. J. Reichs & W. M. Bass (Eds.), *Forensic Osteology: Advances in the Identification of Human Remains*. Springfield, IL: Charles C. Thomas, 491-513.

Settegast, M. (1990). *Plato Prehistorian: 10,000 to 5,000 B.C. Myth, Religion, Archaeology*. Hudson, NY: Lindisfarne Press.

Stephan, C. N. (2002a). Do resemblance ratings measure the accuracy of facial approximations? *Journal of Forensic Science* 47(2), 239-243.

Stephan, C. N. (2002b). Facial Approximation: Globe Projection Guideline Falsified by Exophthalmometry Literature. *Journal of Forensic Science* 47(4), 1-6.

Stephan, C. N. (2003a). Anthropological facial "reconstruction" - Recognizing the fallacies, "unembracing" the error, and realizing method limits. *Science and Justice* 43, 193-199.

Stephan, C. N. (2003b). Facial Approximation: An Evaluation of Mouth-Width Determination. *American Journal of Physical Anthropology* 121, 48-57.

Stephan, C. N. & Henneberg, M. (2001). Building faces from dry skulls: Are they recognized above chance rates? *Journal of Forensic Sciences* 46, 432-440.

Stephan, C. N. & Henneberg, M. (2006). Recognition by facial approximation: case specific examples and empirical tests. *Forensic Science International* 156, 182-191.

Stephan, C. N. & Sampson, E. K. (2008). Facial Soft Tissue Depths in Craniofacial Identification (Part I): An Analytical Review of the Published Adult Data. *Journal of Forensic Sciences* 53(6), 1257-1272.

Stephan, C. N., Henneberg, M. & Sampson, W. (2003). Predicting Nose Projection and Pronasale Position in Facial Approximation: A Test of Published Methods and Proposal of New Guidelines. *American Journal of Physical Anthropology* 122, 240-250.

Strouhal, E. (1973). Five Plastered Skulls from Pre-Pottery Neolithic B Jericho: Anthropological Study. *Paléorient* 1(2), 213-247.

Tyrrell, A. J., Evison, M. P., Chamberlain, A. T., & Green, M. A. (1997). Forensic three-dimensional facial reconstruction: historical review and contemporary developments. *Journal of Forensic Sciences* 42(4), 653-661.

Welcker, H. (1883). *Schiller's Schadel und Todtenmaske, nebst Mittheilungen uber Schadel und Todtenmaske Kant's*. Braunschweig, Germany: Viehweg, F. and son.

Vanezis, P., Blowes, R. W., Linney, A. D., Tan, A. C., Richards, R., & Neave, R. (1989). Application of 3-D computer graphics for facial reconstruction and comparison with sculpting techniques. *Forensic Science International* 42(1-2), 69-84.

Wilkinson, C. (2008). *Forensic Facial Reconstruction*. Cambridge: Cambridge University Press.