



# University of HUDDERSFIELD

## University of Huddersfield Repository

Ousey, Karen and Atkin, Leanne

Wound bed preparation: A novel approach using HydroTherapy

### Original Citation

Ousey, Karen and Atkin, Leanne (2016) Wound bed preparation: A novel approach using HydroTherapy. *British Journal of Community Nursing*. ISSN 1462-4753 (In Press)

This version is available at <http://eprints.hud.ac.uk/30033/>

The University Repository is a digital collection of the research output of the University, available on Open Access. Copyright and Moral Rights for the items on this site are retained by the individual author and/or other copyright owners. Users may access full items free of charge; copies of full text items generally can be reproduced, displayed or performed and given to third parties in any format or medium for personal research or study, educational or not-for-profit purposes without prior permission or charge, provided:

- The authors, title and full bibliographic details is credited in any copy;
- A hyperlink and/or URL is included for the original metadata page; and
- The content is not changed in any way.

For more information, including our policy and submission procedure, please contact the Repository Team at: [E.mailbox@hud.ac.uk](mailto:E.mailbox@hud.ac.uk).

<http://eprints.hud.ac.uk/>

## **Wound bed preparation: A novel approach using HydroTherapy**

<sup>1</sup> Karen Ousey PhD., Professor of skin integrity. <sup>1</sup>Leanne Atkin, Lecturer Practitioner/Vascular Nurse Specialist

1. School of Human and Health Sciences, Institute of Skin Integrity and Infection Prevention. University of Huddersfield. Queensgate Huddersfield

This article was supported by an educational grant from Hartmann

### **Abstract**

Wounds that fail to heal quickly are often encountered by community nursing staff. An important step in assisting these chronic or stalled wounds progress through healing is debridement to remove devitalised tissue, including slough and eschar, that can prevent the wound from healing. A unique wound treatment called HydroTherapy aims to provide an optimal healing environment. The first step of HydroTherapy involves HydroClean plus™, this dressing enables removal of devitalised tissue through autolytic debridement and absorption of wound fluid. Irrigation and cleansing provided by Ringer's solution from the dressing further removes any necrotic tissue or eschar. Once effective wound bed preparation has been achieved a second dressing, HydroTac™, provides an ongoing hydrated wound environment that enables re-epithelialisation to occur in an unrestricted fashion. This paper presents 3 case studies of slow healing wounds treated with HydroClean plus™ which demonstrates effective wound debridement.

**Key Words:** wound bed preparation, devitalised tissue, debridement, de-sloughing, hydration.

### **Key points**

- Debridement is often an important step in preparing the wound bed so chronic or stalled wounds can progress through healing.
- HydroClean plus™ is the first dressing used in HydroTherapy, a unique wound treatment that aims to debride the wound and provide an optimal healing environment.
- HydroClean plus™ successfully prepares the wound bed for healing progression by removing devitalised tissue.

## **Introduction**

Community nurses often encounter chronic wounds, which continue to place significant burden on health care systems' resources and are disabling for patients, (Posnett and Franks, 2008). The concept of wound bed preparation is not new, but remains as relevant today as when it was first introduced. Wound bed preparation is a holistic approach to wound diagnosis and treatment, it ensures patient focused outcomes and treatments, relating to the cause of the wound and the optimisation of the wound bed to promote healing (Snyder et al., 2016).

There is debate surrounding when a wound becomes classed as chronic (Sibbald et al., 2013) suggest any wound present for more than 6 weeks is considered to be chronic in nature, and as the population grows both acute and chronic wounds are becoming more frequent (Sibbald et al., 2013). Additionally, wounds can be classed as recalcitrant (non-healing) if they do not follow the expected trajectory of wound healing. Normal trajectory estimates that there should be a 30% reduction of wound surface area after only 4 weeks, if this is achieved it is projected that the wound will close within a period of 12 weeks (Margolis et al., 2004, Sibbald et al., 2013).

When healing has stalled it is vital that the community nurse has the appropriate knowledge and skills to assesses the whole patient and does not simply concentrate on the wound bed (Atkin, 2014). To

ensure effective patient treatment the assessment should: determine the cause of the wound, identify any co-morbidities/complications that may contribute to the wound or delay wound healing, assess the status of the wound and support the development of management plans (World Union of Wound Healing Societies (WUWHS, 2008).

#### Devitalised tissue

In many chronic wounds there is a build-up of devitalised tissue (Nunan et al., 2014) that interferes with and delays wound healing (Snyder et al., 2016). Both slough and eschar are types of devitalised tissue that may be present in chronic wounds. The former – slough appears as moist, loose, yellow stringy dead tissue. Eschar, on the other hand has the appearance of blackish dry, thick tissue which may be leathery in consistency (Milne, 2015).

Dead tissue, slough and debris in a wound can:

- Prevent or delay a wound's normal healing process (Weir, 2007)
- Mimic or hide infection, attract bacteria to the wound, increasing the risk of infection (O'Brien, 2002)
- Prevent practitioners from assessing the extent and size of the wound, which is particularly problematic when staging pressure ulcer damage (Weir, 2007)
- Increase odour and exudate (Vowden and Vowden, 2011)

Devitalised tissue is known to provide an environment in which microorganisms can attach and form biofilms, which as a consequence results in wound infection (Percival and Suleman, 2015). Ultimately this may lead to a more serious deep tissue infection that can be life threatening (Leaper et al., 2015). In light of this, a basic tenant on the treatment of chronic (or acute) wounds is that any or all devitalised tissue must be removed allowing the wound to be prepared for healing. Therefore, removal of devitalised tissue using a debridement technique is imperative in the first steps to healing

wounds and is the basis of a number of specific guidelines developed to aid the clinician to do this (Pilcher, 2016). This guidance includes the TIME management process (see Table 1), which is the acronym given to Tissue management involving wound bed preparation; Control of Infection and Inflammation; Moisture imbalance; Advancement of the epithelial Edge of the wound as shown in Table 1 (Dowsett, 2008).

### Wound debridement

There are several “standard” methods by which the clinician can remove devitalised tissue including mechanical, autolytic, chemical, enzymatic and biological (larvae) debridement techniques (Mat Saad et al, 2013). Advances in technology have allowed nurses and other healthcare professionals access to newer debridement methods ranging from pulsed lavage debridement (hydro-surgery, water-jet) to ultrasound-assisted wound treatment (Doerler et al, 2012). However, choice of debridement technique depends on the type, amount of devitalized tissue in the wound bed, size and depth of the wound, underlying disease, possible co-morbidity, and the patient’s general condition. Combined methods of debridement may also be used to achieve better results. It is not within the scope of this article to review and critique the different methods of devitalised tissue removal, but to understand why and how this needs to be done.

### HydroTherapy

This article highlights a unique wound treatment regimen “HydroTherapy” that consists primarily of two Hydro-Responsive Wound Dressings (HRWDs), the first of which enables removal of devitalised tissue, which subsequently supports wound bed preparation. This is achieved by both providing autolytic debridement and absorption of wound fluid, which aids in the removal of any deleterious components in the fluid that may delay healing. This is combined with an irrigation and cleansing mechanism (with Ringer’s solution from the dressing HydroClean plus™) that further removes any necrotic tissue or eschar. Subsequent use of the second HRWD wound dressing HydroTac™ provides

an ongoing hydrated wound environment that enables re-epithelialisation to occur in an unrestricted fashion.

#### Case study 1

A 58-year-old male with a diabetic foot ulcer. The ulcer had undergone surgical debridement two weeks previously to his presentation at the clinic, but had shown no obvious improvement (Figure 1). The wound was static extending in depth with increasing slough and necrotic edges, it had dry wound edges that were retracting and the skin flap had not adhered. Six days after HydroClean plus™ treatment was commenced the wound was moist, its depth was reducing and the skin flap was starting to adhere (Figure 2). At 13 days, the wound was fully debrided and the skin flap had fully adhered (Figure 3). HydroClean plus™ was stopped at this point because the wound bed had been successfully prepared for healing. The skin surrounding the wound, the peri-wound skin, showed some hyper-hydration but was not macerated.

Fig 1

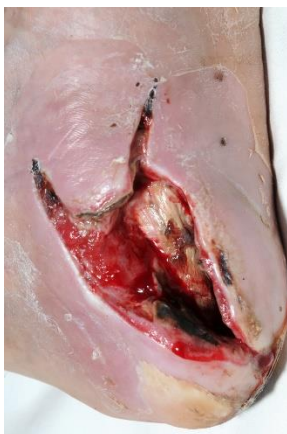

Fig 2

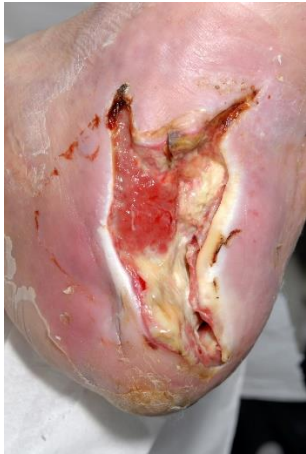
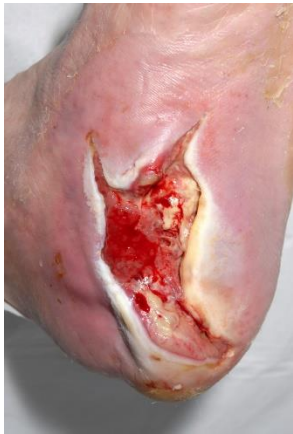
Fig 3



#### Case study 2

The second case was a 72-year-old man with peripheral arterial disease who developed gangrene of his toes and underwent revascularisation and amputation of the 4<sup>th</sup> and 5<sup>th</sup> toes. Initially the wound progressed well but around week 4 it had started to stall, and there was evidence of increasing sloughy tissue (Figure 4). The patient was reassessed and his arterial supply remained adequate. HydroClean plus™ was commenced to allow rapid debridement and optimisation of the wound bed to facilitate granulation growth. After only 1 week there was evidence of debridement and the wound bed was shallower with healthy granulation visible (Figure 5).

Fig 4

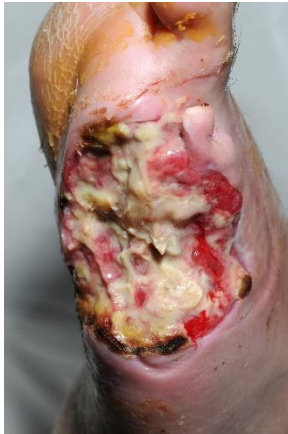
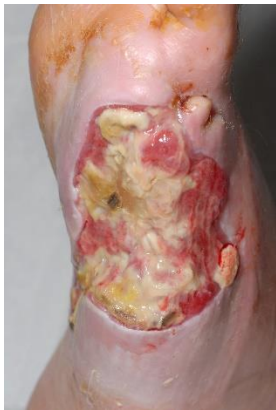
Fig 5



### Case study 3

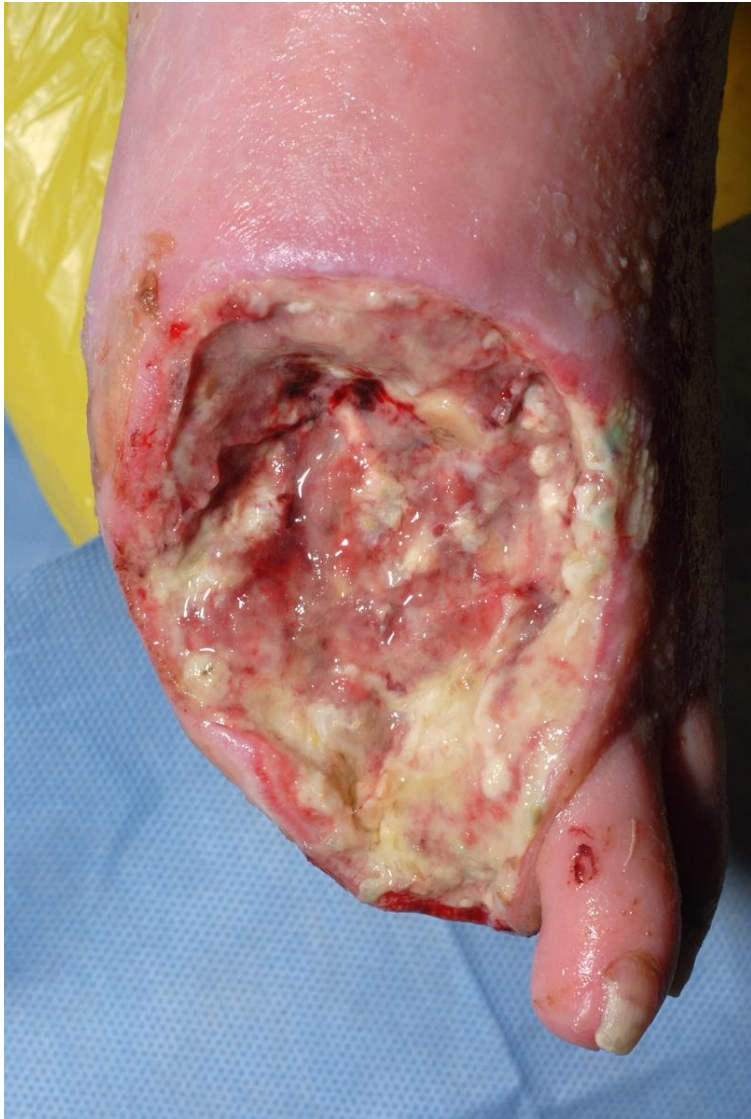
A 65-year-old gentleman who suffered from an acute diabetic foot infection that required incision and drainage. The patient suffered from a neuropathy but had an intact arterial supply. Two weeks following surgery the wound started to stall, (Figure 6) with increasing amounts of sloughy tissue visible at the base of the wound, there were no signs of infection, the wound bed appeared slightly dry and as such there was no evidence of wound edge migration. HydroClean plus™ was started at this point, after only 8 days (Figure 7) there was significant progression in the condition of the wound, the sloughy tissue had started to debride, and there was evidence of new healthy granulation growth. Hydroclean plus™ was continued until the wound was completely slough free allowing skin grafting.

Figure 6



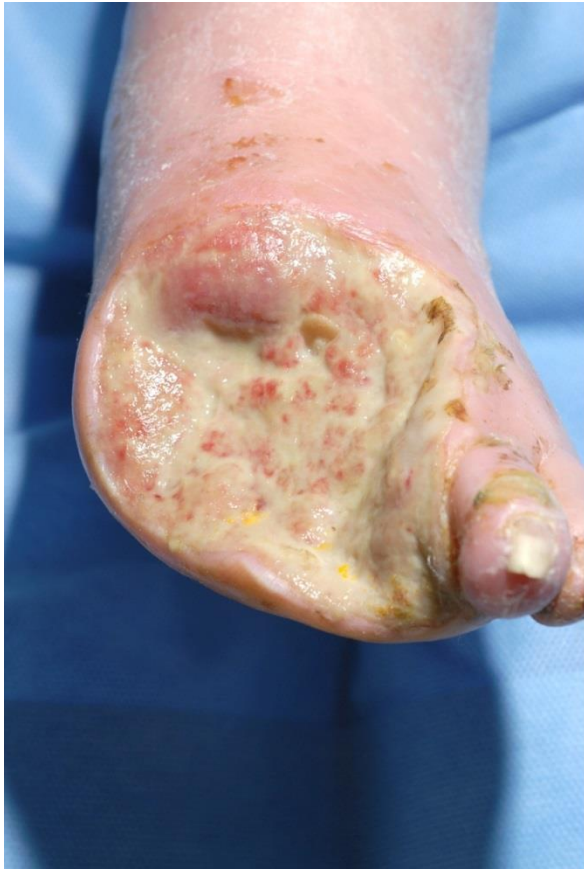

Figure 7



## Discussion

Successful management strategies for treatment of chronic wounds should include wound bed preparation in terms of the “TIME” framework which encompasses tissue management, inflammation and infection control, moisture balance, and epithelial (edge) advancement as presented in –Table 1 (Dowsett, 2008). The vital first step in this process is tissue management involving wound bed preparation, ensuring that where devitalised tissue is present effective debridement cleans the wound bed thus preparing it for healing. There are a variety of different effective debridement options available however using a wound dressing that allows speedy debridement will assist in reducing time to healing and simplify the wound care process. The case studies presented here clearly demonstrate

that HydroClean plus™ is able to remove devitalised tissue quickly and effectively, aiding in the preparation of the wound bed for healing.

#### TIME framework wound healing

As previously discussed, when using the TIME framework for tissue management an essential element is to remove devitalised tissue using various methods of debridement (Pilcher, 2016). HydroTherapy aims to assist later steps in the process that involve restoration of bacterial balance (including reduction of bacterial biofilms), which relates to Infection and inflammation of this framework and through achieving a moist wound healing environment healing will be enabled. Finally, removal of the physical and biochemical barriers for migration of the epithelium from wound edges enables healing (Mat Saad et al, 2013). The effectiveness of using HydroTherapy as a basis for treatment of various chronic wounds in this case study series within the TIME framework is demonstrated in Table 1.

The mode of action of HydroClean plus™ involves cleansing, debriding and absorbing in order to stimulate granulation tissue formation. The release of Ringer's solution from the superabsorbent polyacrylate core beads leads to the softening of necrotic tissue and fibrin coatings. At the same time, wound exudate (containing proteinaceous material and bacteria) is taken up into the body of the dressing. Further absorption of necrosis and fibrinous material softened by the cleansing action occurs. Together, these effects stimulate the quick formation of granulation tissue.

#### Hyper-hydration

The cases presented demonstrated that HydroTherapy may sometimes result in hyper-hydration of the skin surrounding the wound, as can be clearly seen in case 3 (Figure 8). This is a consequence of the autolytic debridement resulting from using HydroClean plus™, which aids in wound bed preparation. Initially this was some unease because it is commonly understood that excess exudate on the skin can jeopardise its integrity (Davies, 2013). However, it is important to note that although the presentation of hyper-hydration and maceration are similar they are not the same (Rippon et al.,

2016). Maceration results from liquids that are damaging to the skin such as wound exudate or urine (Gray and Weir, 2007) whereas hyper-hydration results from the moist environment, in these cases created by the Ringer's solution contained within the dressing. The most significant difference is that hyper hydration will resolve within a few minutes leaving no damage to the skin. More detail surrounding the differences is in Table 2.

These case studies clearly show (Figures 3, 5 and 8) that where hyper-hydration was apparent, supported by the presentation of white and wrinkled tissue, this was transient and the skin returned to a more normal state if left without the Ringer's solution that caused the hydrated environment, for example when the HydroClean plus™ dressing was no longer used. This does not happen if skin is macerated by wound fluid thus "excessive fluid is not *per se* the cause of skin damage but it is the content of the fluid that is of major importance" (Ousey et al, 2016).

Hydration assists wound healing

Additionally, results demonstrate the benefits of hydration not only in the context of debridement but also for healing. In fact, hydration of wounds has been shown to be important for many decades (Benbow, 2008). Table 3 highlights some of the benefits of hydration in wound healing. More importantly high levels of wound tissue hydration (hyper-hydration) have proved to be effective in aiding the healing process. A number of studies have indicated that a wound that is overly hydrated may not result in tissue damage (Breuing et al., 1992; Svensjö et al., 2000; Vranckx et al., 2002; Vogt et al., 1995), and rather suggest that a wound bathed in a hyper-hydrated environment may benefit from the advantages of moist wound healing (Junker et al., 2013).

## **Conclusion**

The initial process of HRWD involving HydroClean plus™ was successful in effectively removing devitalised tissue and aiding progression of healing in chronic wounds. As a straightforward method

of debridement we suggest nurses should consider hydrotherapy for treatment of chronic or stalled wounds.

## Tables and Figures

<b>Table 1. TIME Management framework supported by HWRDs</b>		
T	Tissue Non-Viable or Deficient - Does the wound contain non-viable tissue such as necrotic tissue, slough, non-viable tendon or bone?	HydroClean plus – removes devitalised tissue enables wound bed preparation.
I	Infection or Inflammation - Does the wound have signs of bacterial contamination, infection or inflammation?	HydroClean plus – removes devitalised tissue that provides a nidus for infection.
M	Moisture Imbalance - Does the wound have excess exudate or is the wound too dry?	HydroClean plus aids in absorption and management of wound exudate.
E	Edge of wound non-advancing or undermined - Are the edges of the wound undermined and is the epidermis failing to migrate across the granulation tissue?	HydroTac provides a continuum of hydration that aids wound healing.

**Table 2 Definitions and impact of Hydration, Hyper-Hydration and Maceration**

	<b>Definition</b>	<b>Damage potential</b>	<b>Healing potential</b>
<b>Hydration</b>	The process of providing an adequate amount of liquid to bodily tissues	Low	High
<b>Hyper-hydration</b>	The process of providing more than an adequate amount of liquid to bodily tissues, resulting in an effect on cellular/tissue structures and or processes	Low - moderate	Very High
<b>Maceration</b>	The softening and breaking down of skin resulting from prolonged exposure to moisture - exacerbated by the presence of chemical elements (specific enzymes - MMPs) that further act in tissue degradation	High to extremely high	None

**Table 3. Benefits of moist wound healing – taken from Ousey et al., 2016.**

- Faster wound healing (Winter, 1962; Dyson et al., 1988; Beam et al., 2008)
- Promote epithelialisation rate (Winter, 1962; Eaglstein, 2001; Ågren et al., 2001; Varghese et al., 1986; Rubio, 1991; Madden et al., 1989; Wigger-Alberti et al., 2009)
- Promote dermal/wound bed healing responses, e.g., cell proliferation, ECM synthesis (Svensjö et al., 2000; Dyson et al., 1992; Mosti, 2013; Korting et al., 2010; Chen et al., 1992; Leung et al., 2010; Field & Kerstein, 1994; Dowsett & Ayello, 2004; Katz et al., 1991)
- Reduces scarring (Atiyeh et al., 2003,2004; O'Shaughnessy et al., 2009; Mustoe & Gurjala, 2011; Tandara et al., 2007; Hoeksema et al., 2013)
- Retention of growth factors at wound site (Svensjö et al., 2000; Hackl et al., 2014; Powers et al., 2013; Chen et al., 1992; Attinger et al., 2006; Vogt et al., 1995)
- Lower wound infection rates (Kannon & Garret, 1995; Hutchinson & Lawrence, 1991; Lawrence, 1994)
- Reduces pain perception (Wiechula, 2003; Metzger, 2004; Leaper et al., 2012; Coutts et al., 2008; Feldman, 1991; Nemeth et al., 1991)
-



## References

Agren MS, Karlsmark T, Hansen JB, Rygaard J (2001) Occlusion versus air exposure on full-thickness biopsy wounds. *J Wound Care*, 10(8):301-4.

Atiyeh BS, El-Musa KA, Dham R (2003) Scar quality and physiologic barrier function restoration after moist and moist-exposed dressings of partial-thickness wounds. *Dermatol Surg*, 29(1): 14-20.

Atiyeh BS, Dham R, Costagliola M, Al-Amm CA, Belhaouari L (2004) Moist exposed therapy: an effective and valid alternative to occlusive dressings for postlaser resurfacing wound care. *Dermatol Surg*, 30(1):18-25.

Atkin L (2014) Understanding methods of wound debridement. *Br J Nurs*, 23(12): S10-2, S14-5.

Beam JW (2008) Occlusive dressings and the healing of standardized abrasions. *J Athl Train*, 43(6): 600-7.

Attinger CE, Janis JE, Steinberg J, Schwartz J, Al-Attar A, Couch K (2006) Clinical approach to wounds: débridement and wound bed preparation including the use of dressings and wound-healing adjuvants. *Plast Reconstr Surg*, 117(7 Suppl): 72S-109S.

Benbow M (2008) Exploring the concept of moist wound healing and its application in practice. *Br J Nurs*, 17(15):S4, S6, S8 passim.

Breuing K, Eriksson E, Liu P, Miller DR (1992) Healing of partial thickness porcine skin wounds in a liquid environment. *J Surg Res*, 52(1):50-8.

Chen WY, Rogers AA, Lydon MJ (1992) Characterization of biologic properties of wound fluid collected during early stages of wound healing. *J Invest Dermatol*, 99(5): 559-64.

Coutts P, Woo KY, Bourque S (2008) Treating patients with painful chronic wounds. *Nurs Stand*, 23(10): 42-6.

Doerler M, Reich-Schupke S, Altmeyer P, Stücker M (2012) Impact on wound healing and efficacy of various leg ulcer debridement techniques. *J Dtsch Dermatol Ges*, 10(9): 624-32.

Dowsett C (2008) Using the TIME framework in wound bed preparation. *Br J Community Nurs*, 13(6): S15-6, S18, S20 passim.

Dowsett C, Ayello E (2004) TIME principles of chronic wound bed preparation and treatment. *Br J Nurs*, 13(15): S16-23.

Dyson M, Young SR, Hart J, Lynch JA, Lang S (1992) Comparison of the effects of moist and dry conditions on the process of angiogenesis during dermal repair. *J Invest Dermatol*, 99(6): 729-33.

Dyson M, Young S, Pendle CL, Webster DF, Lang SM (1988) Comparison of the effects of moist and dry conditions on dermal repair. *J Invest Dermatol*, 91(5): 434-9.

Eaglstein WH (2001) Moist wound healing with occlusive dressings: a clinical focus. *Dermatol Surg*, 27(2):175-81.

Feldman ST (1991) The effect of epidermal growth factor on corneal wound healing: practical considerations for therapeutic use. *Refract Corneal Surg*, 7(3): 232-9.

Field FK, Kerstein MD (1994) Overview of wound healing in a moist environment. *Am J Surg*, 167(1A): 2S-6S.

Gray M, Weir D (2007) Prevention and treatment of moisture-associated skin damage (maceration) in the periwound skin. *J Wound Ostomy Continence Nurs*, 34(2): 153-7.

Hackl F, Kiwanuka E, Philip J, et al. (2014) Moist dressing coverage supports proliferation and migration of transplanted skin micrografts in full-thickness porcine wounds. *Burns*, 40(2): 274-80.

Hoeksema H, De Vos M, Verbelen J, Pirayesh A, Monstrey S (2013) Scar management by means of occlusion and hydration: a comparative study of silicones versus a hydrating gel-cream. *Burns*, 39(7): 1437-48.

Hutchinson JJ, Lawrence JC (1991) Wound infection under occlusive dressings. *J Hosp Infect*, 17(2): 83-94.

Junker JP, Kamel RA, Caterson EJ, Eriksson E (2013) Clinical Impact Upon Wound Healing and Inflammation in Moist, Wet, and Dry Environments. *Adv Wound Care (New Rochelle)*, 2(7): 348-356.

Kannon GA, Garrett AB (1995) Moist wound healing with occlusive dressings. A clinical review. *Dermatol Surg*, 21(7): 583-90.

Katz MH, Alvarez AF, Kirsner RS, Eaglstein WH, Falanga V (1991) Human wound fluid from acute wounds stimulates fibroblast and endothelial cell growth. *J Am Acad Dermatol*, 25(6 Pt 1): 1054-8.

Korting HC, Schöllmann C, White RJ (2011) Management of minor acute cutaneous wounds: importance of wound healing in a moist environment. *J Eur Acad Dermatol Venereol*, 25(2): 130-7.

Lawrence JC (1994) Dressings and wound infection. *Am J Surg*, 167(1A): 21S-24S.

Leaper DJ, Schultz G, Carville K, Fletcher J, Swanson T, Drake R (2012) Extending the TIME concept: what have we learned in the past 10 years?(\*). *Int Wound J*, 9(Suppl 2):1-19.

Leaper D, Assadian O, Edmiston CE (2015) Approach to chronic wound infections. *Br J Dermatol*, 173(2): 351-8.

Leung BK, LaBarbera LA, Carroll CA, Allen D, McNulty AK (2010) The effects of normal saline instillation in conjunction with negative pressure wound therapy on wound healing in a porcine model. *Wounds*, 22(7): 179-87.

Madden MR, Nolan E, Finkelstein JL, et al. (1989) Comparison of an occlusive and a semi-occlusive dressing and the effect of the wound exudate upon keratinocyte proliferation. *J Trauma*, 29(7): 924-31.

Margolis DJ, Allen-Taylor L, Hoffstad O, Berlin JA (2004) The accuracy of venous leg ulcer prognostic models in a wound care system. *Wound Repair Regen*, 12(2): 163-8.

Mat Saad AZ, Khoo TL, Halim AS (2013) Wound bed preparation for chronic diabetic foot ulcers. *ISRN Endocrinol*, 2013:608313.

Metzger S (2004) Clinical and financial advantages of moist wound management. *Home Healthc Nurse*, 22(9): 586-90.

Milne J (2015) Wound-bed preparation: the importance of rapid and effective desloughing to promote healing. *Br J Nurs*, 24 Suppl 20: S52-8.

Mosti G (2013) Wound care in venous ulcers. *Phlebology*, 28 Suppl 1:79-85.

Mustoe TA, Gurjala A (2011) The role of the epidermis and the mechanism of action of occlusive dressings in scarring. *Wound Repair Regen*, 19 Suppl 1: s16-21.

Nemeth AJ, Eaglstein WH, Taylor JR, Peerson LJ, Falanga V (1991) Faster healing and less pain in skin biopsy sites treated with an occlusive dressing. *Arch Dermatol*, 127(11): 1679-83.

Nunan R, Harding KG, Martin P. Clinical challenges of chronic wounds: searching for an optimal animal model to recapitulate their complexity. *Dis Model Mech*. 2014 Nov;7(11):1205-13

O'Brien M (2002) Exploring methods of wound debridement. *Br J Community Nurs*, 10-8.

O'Shaughnessy KD, De La Garza M, Roy NK, Mustoe TA (2009) Homeostasis of the epidermal barrier layer: a theory of how occlusion reduces hypertrophic scarring. *Wound Repair Regen*, 17(5): 700-8.

Ousey K, Cutting KF, Rogers AA, Rippon MG (2016) The importance of hydration in wound healing: reinvigorating the clinical perspective. *J Wound Care*, 25(3): 122, 124-30.

Percival SL, Suleman L (2015) Slough and biofilm: removal of barriers to wound healing by desloughing. *J Wound Care*, 24(11): 498, 500-3, 506-10

Pilcher M (2016) Wound cleansing: a key player in the implementation of the TIME paradigm. *J Wound Care*, 25(3 Suppl): S7-9.

Powers JG, Morton LM, Phillips TJ (2013) Dressings for chronic wounds. *Dermatol Ther*, 26(3): 197-206.

Rippon MG, Ousey K, Cutting KF (2016) Wound healing and hyper-hydration: a counterintuitive model. *J Wound Care*, 25(2):68, 70-5.

Rubio PA (1991) Use of semioclusive, transparent film dressings for surgical wound protection: experience in 3637 cases. *Int Surg*, 76(4): 253-4.

Sibbald GR, Goodman L, Reneeka P (2013). Wound bed preparation 2012. *J Cutan Med Surg*, 17 Suppl 1:S12-22.

Snyder RJ, Fife C, Moore Z (2016) Components and Quality Measures of DIME (Devitalized Tissue, Infection/Inflammation, Moisture Balance, and Edge Preparation) in Wound Care. *Adv Skin Wound Care*, 29(5): 205-15.

Svensjö T, Pomahac B, Yao F, Slama J, Eriksson E (2000) Accelerated healing of full-thickness skin wounds in a wet environment. *Plast Reconstr Surg*, 106(3):602-14.

Tandara AA, Kloeters O, Mogford JE, Mustoe TA (2007) Hydrated keratinocytes reduce collagen synthesis by fibroblasts via paracrine mechanisms. *Wound Repair Regen*, 15(4): 497-504.

Varghese MC, Balin AK, Carter DM, Caldwell D (1986) Local environment of chronic wounds under synthetic dressings. *Arch Dermatol*, 122(1):52-7.

Vogt PM, Andree C, Breuing K, et al. (1995) Dry, moist, and wet skin wound repair. *Ann Plast Surg*, 34(5): 493-500.

Vowden K, Vowden P (2011) Debridement made easy. *Wounds UK*, 7(4): 1-4.

Vranckx JJ, Slama J, Preuss S, et al. (2002) Wet wound healing. *Plast Reconstr Surg*, 110(7): 1680-7.

Weir D (2007) Wound debridement. In: Krasner DL (ed) *Chronic Wound Care: A Clinical Source Book for Healthcare Professionals*. Malvern: HMP Communications.

Wiechula R (2003) The use of moist wound-healing dressings in the management of split-thickness skin graft donor sites: a systematic review. *Int J Nurs Pract*, 9(2): S9-17.

Wigger-Alberti W, Kuhlmann M, Ekanayake S, Wilhelm D (2009) Using a novel wound model to investigate the healing properties of products for superficial wounds. *J Wound Care*, 18(3): 123-28, 131.

Winter GD (1962) Formation of the scab and the rate of epithelization of superficial wounds in the skin of the young domestic pig. *Nature*, 193: 293-4.

World Union of Wound Healing Societies (WUWHS) (2008) *Principles of best practice: Diagnostics and wounds. A consensus document*. London: MEP Ltd

Ousey K, Cutting KF, Rogers AA, Rippon MG. The importance of hydration in wound healing: reinvigorating the clinical perspective. *J Wound Care*. 2016 Mar;25(3):122, 124-30

ATKIN, L. 2014. Understanding methods of wound debridement. *British Journal of Nursing*, 23.

DAVIES, P. 2013. Exudate assessment and management. *British journal of community nursing*, 17, S18-S24.

MARGOLIS, D. J., ALLEN-TAYLOR, L., HOFFSTAD, O. & BERLIN, J. A. 2004. The accuracy of venous leg ulcer prognostic models in a wound care system. *Wounds repair and regeneration*, 12, 163-168.

POSNETT, J. & FRANKS, P. J. 2008. The burden of chronic wound care in the UK. *Nursing Times*, 104, 44-45.

SIBBALD, R. G., GOODMAN, L. & RENEEKA, P. 2013. Wound Bed Preparation 2012. *Journal of Cutaneous Medicine and Surgery*, 17, S12-S22.

WUWHS 2008. *Principles of best practice: Diagnostics and wounds. A consensus document*.