

Case Report

Autosomal dominant inheritance of non-syndromic renal hypoplasia and dysplasia: dramatic variation in clinical severity in a single kindred

Larissa Kerecuk¹, Anaar Sajoo², Lesley McGregor², Jonathan Berg³, Mushfequr R. Haq¹, Neil J. Sebire⁴, Coralie Bingham⁵, Emma L. Edghill⁵, Sian Ellard⁵, Judy Taylor¹, Sue Rigden¹, Frances A. Flinter² and Adrian S. Woolf⁶

¹Department of Paediatric Nephrology, Evelina Children's Hospital, ²Genetics Centre, Guy's and St Thomas' NHS Foundation Trust, London, ³Human Genetics Units, Ninewells Hospital and Medical School, University of Dundee, Dundee, ⁴Department of Paediatric Histopathology, Great Ormond Street Hospital for Children, London, ⁵Institute of Biomedical and Clinical Science, Peninsula Medical School, Exeter, and ⁶Nephro-Urology Unit, UCL Institute of Child Health, London, UK

Keywords: dysplasia; gene; hypoplasia; inheritance; nephrogenesis; renal failure

Introduction

'Congenital anomalies of the kidney and urinary tract' (CAKUT) include renal agenesis (absent kidneys), dysplasia (undifferentiated and metaplastic tissues) and hypoplasia (too few nephrons) [1]. In several multiorgan syndromes featuring CAKUT, mutations of genes expressed in renal tract development have been defined [1]. As examples, genes mutated in the renal-coloboma (*paired box 2*; *PAX2*), renal cysts and diabetes (*hepatocyte nuclear factor 1 β* ; *HNF1 β*) and branchio-oto-renal (*eyes absent 1*; *EYA1*) syndromes encode transcription factors and related proteins [2–4]. Here, we describe a remarkable, extended kindred with autosomal dominant inheritance of non-syndromic renal hypoplasia and dysplasia, with dramatic variations in clinical severity between individuals.

Family report

Clinical information was extracted from patients' notes; detailed discussions with individuals in the kindred was also used. There were no dysmorphic features, deafness, visual impairment (i.e. unexplained by refractive errors) or diabetes mellitus in this Caucasian family (Figure 1). There was no exposure

to known teratogens in pregnancies which could have given rise to affected individuals. Lower limits of normal for renal length as assessed by ultrasound (US) scanning, according to different ages, were taken from previous publications [5,6]. Glomerular filtration rates (GFRs) were directly measured or estimated for children [7] and adults [8] using standard formulae. Leucocyte DNA was collected from the index case, after parental consent. For *PAX2*, exons 2, 3 and 4 (encoding the paired-box) and exon 5 (containing the octapeptide domain) were amplified and sequenced as described [2]. For *HNF1 β* , the promoter, coding regions and intron-exon boundaries were amplified and sequenced: because *HNF1 β* gene deletions are described in CAKUT, this was sought using multiplex ligation-dependent probe amplification [3]. For *EYA1*, amplification and sequencing were performed to analyse exons 8 to 16, as described [4].

The index case (IV.8) was delivered by Caesarean section at 33 weeks gestation soon after oligohydramnios was noted on foetal US. Previous scans at 11, 14, 16 and 22 weeks had been normal: these had been performed because of a history of Potters sequence in two siblings (IV.3 and IV.4, described subsequently). Neonatally, she had renal impairment (plasma creatinine 313 $\mu\text{mol/l}$ on day 5). US revealed two small kidneys (right 1.8 cm and left 2.4 cm long; lower limit for gestational age, 3.0 cm) that were echogenic and lacked corticomedullary differentiation: there were no cysts or renal tract dilatation. A micturating urethrocytogram excluded vesicoureteric reflux (VUR), and the bladder and urethra were normal. Hence she had bilateral renal hypoplasia/dysplasia without urinary tract anatomical obstruction. Aged 3 years, her estimated GFR is 21 ml/min/1.73 m² and she is treated with oral alkali, vitamin D and iron supplements. She has mild proteinuria (1+ on dipstick)

Correspondence and offprint requests to: Prof. Adrian S. Woolf, Nephro-Urology Unit, UCL Institute of Child Health, 30 Guilford Street, London WC1N 1EH, UK. Email: A.Woolf@ich.ucl.ac.uk

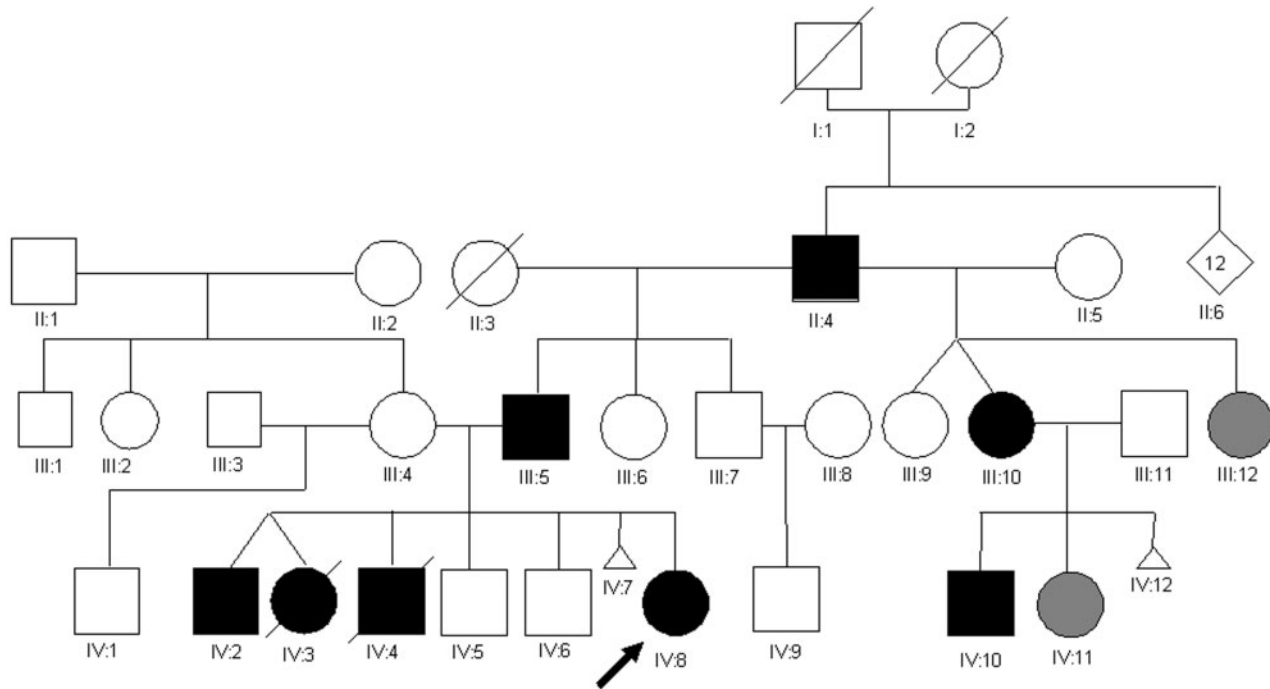


Fig. 1. Family tree. Black icons represent members who have renal dysplasia and/or hypoplasia; icons filled-in with grey are two individuals with ‘borderline’ abnormal radiology. Arrow indicates the index case (IV.8) and diagonal lines indicate that the individuals are no longer alive.

and is normotensive. On the hypothesis that she might have a ‘forme-fruste’ of the renal coloboma syndrome [9], her optic fundi were visualized and possible ‘mild colobomatous notches’ noted; however, no mutation was found in functional domains of *PAX2*. *HNF1B* sequencing revealed no abnormalities, nor was the gene deleted. *EYAI* sequencing demonstrated no missense or truncating mutations: she was heterozygous for 1656T > C which would not result in an amino-acid change (H552H). Her karyotype was normal (46, XX).

The index case was the product of the sixth pregnancy from two non-consanguineous parents (III.4 and III.5). The first pregnancy resulted in non-identical twins (IV.2 and IV.3) born at 34 weeks gestation. One, a boy (IV.2), is now 19 years old: he is normotensive with no proteinuria and his estimated GFR was 93 ml/min/1.73 m². US at 16 years revealed a normal left kidney (10.5 cm long) and a diffusely echobright, small right kidney (7.0 cm long; lower normal limit, 9.5 cm). The other twin, a girl (IV.3), was of low birth weight and died after 3 h; examination revealed features of Potter sequence (i.e. distortion of facial and external features secondary to oligohydramnios) and limited autopsy revealed two small kidneys consistent with Potter type IIB dysplasia [1]. The second pregnancy resulted in a term male infant (IV.4) who died neonatally; he had the Potter sequence and a similar autopsy result as IV.3. The third and fourth pregnancies resulted in the birth of two males (IV.5 and IV.6) who are alive and well at 12 and 16 years of age; both had normal renal US and neither has been further investigated. The fifth pregnancy ended in a

spontaneous miscarriage (IV.7), and no specific investigations were done. The mother of the index case had a previous marriage, resulting in a son who is alive and well: she has two siblings, and neither of these, nor her own parents, have a history of renal disease.

The index case’s asymptomatic father (III.5) was investigated with US, intravenous urography, ^{99m}Tc-dimercaptosuccinic acid (DMSA) renography and ^{99m}Tc-diethylenetriaminepentaacetic acid indirect cystography. On US, both kidneys were diffusely bright with loss of corticomedullary differentiation, the right being 9.0 cm and left being 10.4 cm in length (lower normal limit, 10.5 cm), with the latter contributing 61% of total function. The calyces were distorted but VUR was absent. The appearances are compatible with bilateral renal hypoplasia and/or mild dysplasia. His estimated GFR was 77 ml/min/1.73 m². The mother of the index case (III.4) is also asymptomatic and a renal US, performed in her fourth pregnancy, showed minimal bilateral pelvicalyceal dilatation, within normal limits for pregnancy. When the index case’s grandfather (II.4) was 31 years old, proteinuria was noted on screening at a Navy entry medical examination, and, after radiological examinations, he was told that ‘one kidney had not grown’. Proteinuria persisted and a renal biopsy 6 years later showed focal segmental glomerulosclerosis (original slides unavailable). He never had overt nephrotic syndrome but proteinuria persisted and renal function deteriorated. After reaching end-stage renal failure, he then had two kidney transplants, at 53 and 55 years, the first lost after 10 days from vascular rejection,

the second still functioning with an estimated GFR of 27 ml/min/1.73 m². He was one of 13 siblings but the only one known to have renal disease, although contact has been lost with most of these siblings and their families: neither of his parents are alive but were not reported to have had renal disease.

II.4 had a total of six children; three (III.5, described earlier, III.6 and III.7) from a first marriage and three (III.9, III.10 and III.12) in a second marriage. The first pregnancy of the second marriage resulted in non-identical female twins (III.9 and III.10) and one of these (III.10) presented with symptoms of cystitis at 19 years of age when she was found to have proteinuria (2+ on dipstick urinalysis, 0.87 g/l). US showed two small kidneys (right and left 8.8 cm long; lower normal limit, 10.0 cm) and a formal GFR was 70 ml/min/1.73 m². A renal biopsy at age 21 showed no significant abnormalities on light microscopy, although there was 'mild obliteration of foot processes' on electron microscopy. GFR a year later was 62 ml/min/1.73 m². Although her initial diagnosis was that of 'minimal change disease', she has never had nephrotic syndrome, and her clinical picture can be seen to be compatible with bilateral renal hypoplasia, although the subtype of 'oligomeganephronia' [9] appears to be excluded because, on biopsy, glomeruli were not enlarged. This individual's two sisters (III.9 and III.12) are normotensive: they were also screened using US and DMSA scans and urinary protein excretion: all investigations were within normal limits apart from modest asymmetry of renal function (left 57%, right 43%) on isotope scan of III.12.

III.10 has had two children (IV.10 and IV.11). The first, a boy (IV.10), was born at 37 weeks gestation following a pregnancy which was closely monitored from mid-gestation due to foetal growth retardation: however, no renal tract anomalies were reported prenatally. Post-natally, he was diagnosed with severe gastro-oesophageal reflux but specific renal investigations were not performed until 6 months of age when he presented in acute respiratory distress from pulmonary oedema: he was found to be in renal failure and required urgent dialysis. US showed two echogenic kidneys that lacked corticomedullary differentiation: the left was 4.0 cm long and the right was 4.2 cm long (lower normal limit, 4.5 cm): there was no renal tract dilatation and the urinary bladder appeared normal. A renal cortex biopsy showed two sclerosed glomeruli, with dilated tubules and widened interstitial spaces. He remained dialysis-dependent until the age of 27 months, when he had a successful living-related transplant (from his father). His current estimated GFR is 65 ml/min/1.73 m². He has never had hypertension. The second child, a girl (IV.11), was born at term with a low birth weight; at that time on US, the right kidney was 2.3 cm long and left 3.3 cm long (lower normal limit, 4.0 cm). A subsequent US scan at 6 months of age appeared more normal (right kidney 4.0 cm and left kidney 4.7 cm long; lower normal limit, 4.5 cm) and her plasma creatinine was 29 µmol/l, in the normal range. A third pregnancy ending in a

first trimester miscarriage (IV.12): it was not investigated further.

Discussion

Approximately 40% of the 836 UK children with end-stage renal failure have CAKUT and, with improving dialysis and transplantation, more such individuals can be expected to survive [10]: in the current kindred, there is one such child (IV.10) in this clinical category, and another (IV.8) having severe chronic renal failure, predicted to lead to renal replacement therapy. Despite advances in medical care, the most severe cases of CAKUT lead to prenatal renal failure, oligohydramnios and the Potter sequence, and these individuals will either undergo termination of pregnancy, or die soon after birth from combinations of renal and respiratory failure, as occurred in IV.3 and IV.4. Yet other individuals with CAKUT may be relatively well or even asymptomatic in childhood, only to be diagnosed in later life after screening for renal disease (e.g. II.4 and III.5); in some such adults, proteinuria and renal impairment are features of the disorder (e.g. II.4 and III.10), with progression to end-stage renal failure (II.4) a possibility. Interestingly, two of the adults with CAKUT in this kindred had received (in hindsight) erroneous diagnostic labels of 'primary' glomerular disorders ('focal segmental glomerulosclerosis' in II.4, and 'minimal change disease' in III.10); neither case, however, was overtly nephrotic.

Although renal hypoplasia and dysplasia are clearly 'developmental structural defects', it is of note that in none of the affected individuals was a renal tract malformation detected by US screening before birth. This is especially striking with regard to two of the surviving children who have severe renal impairment (IV.8 and IV.10): both had had repeated foetal US scans and the only 'clue' in one of them was oligohydramnios at 33 weeks gestation. Indeed, in a recent large study of infants with severe chronic renal failure [10], less than half of 80 with CAKUT were diagnosed antenatally.

Renal 'hypoplasia' and 'dysplasia' are, strictly-speaking, histopathological diagnoses: in the former, there are significantly fewer glomeruli/nephrons than normal in each kidney and an accurate count involves rigorous stereological methods on autopsy samples; 'dysplasia' means that kidneys contain, in whole or in part, undifferentiated and/or metaplastic tissues, and key features (e.g. malformed tubules surrounded by fibromuscular cells) may only be apparent in the medulla [1]. In clinical practice, the use of these diagnostic labels are therefore nearly always based on 'best guesses' from radiology. For example: kidneys that are significantly small on imaging, yet retain function and a normal outline, will usually be called 'hypoplastic' [11]; kidneys that have an irregular outline and have poor, or absent, function, and which also sometimes contain cysts, tend to be

called 'dysplastic'. In the current family, we can be definitive only with the two individuals who died as neonates (IV.3 and IV.4): on autopsy, both had very small, dysplastic kidneys. Other affected individuals may have had hypoplasia or dysplasia or a combination of the two. The family did not feature VUR, although this seems to often accompany renal hypoplasia in Japan [11].

In the Introduction, it was explained that CAKUT can feature in inherited multiorgan malformation syndromes. While such syndromes are clinically well-defined, and their genetic bases are increasingly being unravelled, it is less well-recognized that CAKUT (e.g. agenesis and dysplasia) has been described in multiple members of families in the absence of extra-renal features [12]. Although there are several published reports of families with more than one member affected by renal hypoplasia/dysplasia, the current report must represent, to our knowledge, one of the most extensive and clinically well-documented examples of this type of kindred. The inheritance pattern in the current family appears to be dominant, and X-linkage can be excluded with clear male–male transmission in three instances. Acting on the (unlikely) hypothesis that the family may have represented an incomplete form ('forme-fruste') of a genetically defined multiorgan syndrome that can be inherited in an autosomal dominant manner, mutations were sought in coding regions of *PAX2*, *EYAI* and *HNF1 β* , yet none were found. While the analyses performed do not completely rule out these genes (e.g. future analyses could focus on establishing whether there might exist mutations affecting the regulatory regions of these candidates), we note that in the current family, apart from a single observation of a possible ocular anomaly, there were no extra-renal features (e.g. dysmorphology, deafness, diabetes mellitus etc.) which would lead to the diagnosis of a known syndrome: the clinical features of several of these syndromes has recently been reviewed in detail [1]. Very recently, *urolakin IIIa*, which codes for a protein coating the urothelium, was shown to be mutated in a subset of individuals with CAKUT [13]; in future, it would be appropriate to consider *urolakin* analyses in the current family.

One hypothesis to explain proteinuria in some individuals in the current kindred, is 'acquired hyperfiltration damage'; an alternative idea is that glomerular lesions and proteinuria are manifestations of the same (yet-to-be-identified) mutation which causes hypoplasia and dysplasia; if this contention is correct, then this gene would be predicted to be expressed only in the renal tract and to code for a protein which is not only required for normal nephrogenesis but also for preservation of structural and functional integrity of mature glomeruli. In future, more detailed analyses of the nature of proteinuria in this kindred would be of interest.

A striking feature of several of autosomal dominant syndromes featuring renal tract malformations is an extreme variability in the severity of CAKUT between

individuals who have identical mutations [14] and this might be explained by (yet-to-be-defined) modifying genes. Another explanation for such variations could be environmental factors. For example, in experimental animals, composition of maternal diet during pregnancy affects metanephric growth and gene expression in offspring [15]. Whatever, the reason(s) for this variation, it is clear that the less-severely affected individuals may not present until adulthood. Furthermore, it is notable that there were two individuals in the current kindred (III.12 and IV.11) who had 'borderline abnormal' radiology: this may be compatible with the inherited disorder as having less than 100% penetrance. For those individuals with less severe involvement, the long-term prognosis is unclear: we suggest that they should at the least be followed-up with regular checks to exclude the onset and progression of renal impairment and proteinuria. Older, affected individuals in this family often have proteinuria without systemic hypertension, and it remains a possibility that blockade of angiotensin II activity might slow progression.

Acknowledgements. We thank family members for permission to report their stories, and the following laboratories for performing genetic diagnostic tests: DNA Diagnostic Laboratory, Great Ormond Street Hospital, London, UK and Center for Human Genetics, University of Leuven, Leuven, Belgium.

Conflict of interest statement. None declared.

References

1. Woolf AS, Price K, Scambler PJ, Winyard PJD. Evolving concepts in human renal dysplasia. *J Am Soc Nephrol* 2004; 15: 998–1007
2. Devriendt K, Matthijs G, Van Damme B *et al.* Missense mutation and hexanucleotide duplication in the *PAX2* gene in two unrelated families with renal-coloboma syndrome (MIM 120330). *Hum Genet* 1998; 103: 149–153
3. Edghill EL, Owens M, Harries LW *et al.* Hepatocyte nuclear factor-1 β gene deletions are common in subjects with unexplained renal disease and diabetes. *Diabet Med* 2006; 23 [Suppl 2]: 31
4. Rickard S, Parker M, van't Hoff W *et al.* Oto-facio-cervical (OFC) syndrome is a contiguous gene deletion syndrome involving *EYAI*: molecular analysis confirms allelism with BOR syndrome and further narrows the Duane syndrome critical region to 1 cM. *Hum Genet* 2001; 108: 398–403
5. Rosenbaum DM, Korngold E, Teele RL. Sonographic assessment of renal length in normal children. *Am J Roentgenol* 1984; 142: 467–469
6. Emamian SA, Nielsen MB, Pedersen JF, Ytte L. Kidney dimensions at sonography: correlation with age, sex, and habitus in 665 adult volunteers. *Am J Roentgenol* 1993; 160: 83–86
7. Morris MC, Allanby CW, Toseland P, Haycock GB, Chantler C. Evaluation of a height/plasma creatinine formula in the measurement of glomerular filtration rate. *Arch Dis Child* 1982; 57: 611–615
8. Levey AS, Bosch JP, Lewis JB, Greene T, Rogers N, Roth D. A more accurate method to estimate glomerular filtration rate from serum creatinine: a new prediction equation. Modification of Diet in Renal Disease Study Group. *Ann Int Med* 1999; 130: 461–470

9. Salomon R, Tellier AL, Attie-Bitach T *et al.* PAX2 mutations in oligomeganephronia. *Kidney Int* 2001; 59: 457–462
10. Kari JA, Gonzalez C, Ledermann SE, Shaw V, Rees L. Outcome and growth of infants with severe chronic renal failure. *Kidney Int* 2000; 57: 1681–1687
11. Hiraoka M, Hori C, Tsukahara H, Kasuga K, Ishihara Y, Sudo M. Congenitally small kidneys with reflux as a common cause of nephropathy in boys. *Kidney Int* 1997; 52: 811–816
12. McPherson E, Carey J, Kramer A *et al.* Dominantly inherited renal adysplasia. *Am J Med Genet* 1987; 26: 863–872
13. Jenkins D, Bitner-Glindzicz M, Malcolm S *et al.* *De novo* Uroplakin IIIa mutations cause renal adysplasia leading to severe kidney failure. *J Am Soc Nephrol* 2005; 16: 2141–2149
14. Schimmenti LA, Cunliffe HE, McNoe LA *et al.* Further delineation of renal-coloboma syndrome in patients with extreme variability of phenotype and identical PAX2 mutations. *Am J Hum Genet* 1997; 60: 869–878
15. Welham SJM, Riley PR, Wade A, Hubank M, Woolf AS. Maternal diet programs embryonic kidney gene expression. *Physiol Genomics* 2005; 22: 48–56

Received for publication: 19.06.06

Accepted in revised form: 9.08.06