



Grazette, A. J., Foote, J., Whitehouse, M. R., & Blom, A. W. (2016). A review of outcomes and modes of presentation following liner dissociation from Harris-Galante uncemented acetabular components. *Hip International*, 26(2), 149-152. [26692245]. DOI: 10.5301/hipint.5000316

Peer reviewed version

License (if available):
Unspecified

Link to published version (if available):
[10.5301/hipint.5000316](https://doi.org/10.5301/hipint.5000316)

[Link to publication record in Explore Bristol Research](#)
PDF-document

© Wichtig Publishing

University of Bristol - Explore Bristol Research

General rights

This document is made available in accordance with publisher policies. Please cite only the published version using the reference above. Full terms of use are available:
<http://www.bristol.ac.uk/pure/about/ebr-terms.html>

HIP INTERNATIONAL

A review of outcomes and modes of presentation following liner dissociation from Harris-Galante uncemented acetabular components --Manuscript Draft--

Manuscript Number:	HIPINT-D-15-00217R2
Full Title:	A review of outcomes and modes of presentation following liner dissociation from Harris-Galante uncemented acetabular components
Short Title:	Outcomes following liner dissociation from Harris-Galante acetabular cups
Article Type:	Original Article
Section/Category:	Arthroplasty
Keywords:	Arthroplasty; Liner dissociation; Outcomes; Revision
Corresponding Author:	Andrew James Grazette, MBChB University Hospitals Coventry and Warwickshire NHS Trust Coventry, West Midlands UNITED KINGDOM
Corresponding Author's Institution:	University Hospitals Coventry and Warwickshire NHS Trust
First Author:	Andrew James Grazette, MBChB
Order of Authors:	Andrew James Grazette, MBChB Julian Foote, MBChB Michael Whitehouse Ashley Blom
Manuscript Region of Origin:	UNITED KINGDOM
Abstract:	<p>Dissociation of the polyethylene liner is a known failure mechanism of the Harris Galante I and II uncemented acetabular components. The outcomes of revision surgery for this indication and the influence of time to diagnosis are not well described.</p> <p>We report a series of 29 cases revised due to this failure mechanism. The median time from primary to revision surgery was 13 years.</p> <p>At a median of 4 years follow up, the mean OHS was 34 (range 6-48) but results were poorer (mean 29, range 6-45) when the diagnosis and revision was delayed compared to when it was not (mean 39, range 20-48). A large proportion of our patients (n=14) presented with sudden onset of symptoms with or without trauma. Osteolysis was common in this series but the cup was well fixed in 20/29 cases. There was macroscopic damage to the shell in all cases.</p> <p>In our experience, prompt revision of liner dissociation optimises outcomes in this group of patients and radiology reporting alone is not sufficient to identify these cases.</p>
Additional Information:	
Question	Response
Please confirm that the manuscript has been seen and approved by all authors	Yes, I confirm on behalf of all authors that that the manuscript has been seen and approved by all authors
Please confirm that the manuscript is not under consideration for publication elsewhere in a similar form, in any language, except in abstract form	I confirm also on behalf of the co-authors that the manuscript is not under consideration for publication elsewhere in a similar form, in any language, except in abstract form
MEETING PRESENTATION	Not yet presented
Please disclose any financial support (grants and funds) received in support of	No financial support was received in support of the study.

the study. If none please state so.	
Conflict of Interest: state if any author has any conflict of interest. If none, please state so.	The authors declare no conflict of interests.
INFORMED CONSENT - If the manuscript includes experimental investigation on human subjects please include one of the following statements:	The manuscript does not report the results of an experimental investigation on human subjects
DECLARATION OF HELSINKI - If the manuscript includes experimental investigation on human subjects please include one of the following statements:	The manuscript does not report the results of an experimental investigation on human subjects
IC or IRB APPROVAL - in case of manuscripts reporting the results of experimental investigation on human subjects you will need to supply the date of acceptance by the appropriate institutional committee or review board.	This article does not include results of experimental investigations on human subjects
IC or IRB APPROVAL - I you replied YES, please add date of acceptance	
Clinical Trials Registration. For articles reporting on a clinical trial the Journal requires its prospective registration. Please provide the Clinical Trial unique Registration number during the submission process	The article does not report a clinical trial.
If the manuscript include animal experimentation, please state the adherence to the NIH Guide for the Care and Use of Laboratory Animals or equivalent	The manuscript does not report the results of an animal experimentation
Please indicate if any of the Authors are member of the European Hip Society or of any of the affiliated Societies	Michael Whitehouse - European Hip Society Ashley Blom - European Hip Society
Acknowledgements	Nil

A review of outcomes and modes of presentation following liner dissociation from Harris-Galante uncemented acetabular components.

Short title: Outcomes following liner dissociation from Harris-Galante acetabular cups.

Mr Andrew J Gazette¹⁺² MBChB, MRCS

Mr Julian Foote¹ MBChB, FRCS (Tr&Orth)

Mr Michael R Whitehouse¹ BSc, MBChB, MSc, PhD, FRCS (Tr&Orth), PGCert
(TLHE), FHEA

Ashley W Blom¹ MBChB, FRCS (Tr&Orth), PhD, MD

1. Musculoskeletal Research Unit, University of Bristol, School of Clinical Sciences, 1st Floor Learning & Research Building, Southmead Hospital, Bristol, BS10 5NB, UK
2. The Department of Trauma and Orthopaedic Surgery, University Hospitals Coventry and Warwickshire, University Hospital, Clifford Bridge Road, Coventry, CV2 2DX, UK

Corresponding author:

Andrew Grazette, Email: andygrazette@hotmail.com, Tel: +44 7834 177017,

Address: 8a Beaufort Road, Clifton, Bristol, BS8 2JZ, UK

Abstract:

Purpose

Dissociation of the polyethylene liner is a known failure mechanism of the Harris Galante I and II uncemented acetabular components. The outcomes of revision surgery for this indication and the influence of time to diagnosis are not well described.

Methods

We report a series of 29 cases revised due to this failure mechanism. The median time from primary to revision surgery was 13 years.

Results

At a median of 4 years follow up, the mean OHS was 34 (range 6-48) but results were poorer (mean 29, range 6-45) when the diagnosis and revision was delayed compared to when it was not (mean 39, range 20-48). A large proportion of our patients (n=14) presented with sudden onset of symptoms with or without trauma. Osteolysis was common in this series but the cup was well fixed in 20/29 cases. There was macroscopic damage to the shell in all cases.

Conclusions

In our experience, prompt revision of liner dissociation optimises outcomes in this group of patients and radiology reporting alone is not sufficient to identify these cases.

Keywords; Arthroplasty, Liner dissociation, Outcomes, Revision

Introduction

Uncemented modular acetabular components are commonly used in both primary and revision hip arthroplasty, and offer the surgeon a range of intraoperative options. Evidence from joint registries has shown good medium and long-term outcomes for such implants¹. The benefits of modularity must however be offset against the potential risks including the differing modes of failure. One of the recognised and previously documented modes of failure is disassembly of the acetabular cup with dissociation of the liner². This necessitates revision surgery with the attendant costs and morbidity.

The Harris-Galante acetabular cup (Zimmer, Warsaw, Indiana) is a porous coated modular acetabular component that has been widely used with good results^{3 4}. There have previously been a small number of reported cases of liner dissociation in this implant^{5 6}.

We report the largest series of polyethylene acetabular liner dissociation to date with 29 cases. The aim of this study is to look at the outcomes of patients who had a dissociated liner that necessitated revision total hip arthroplasty. Our secondary aims were to ascertain the mode of presentation of these patients, radiographic and intraoperative findings.

Methods

We conducted a review our institution's database for cases of revision total hip arthroplasty for liner dissociation. Between March 2001 and January 2014, there were 31 cases of revision surgery found for this indication. 2 cases were excluded from analysis as the acetabular cup was not a Harris-Galante (HG). This left 29 cases of revision total hip arthroplasty for liner dissociation in Harris-Galante cups (1 dissociation from HG I cup and 28 from HG II cups), performed at our centre.

Patients were contacted to determine current Oxford Hip Scores. Patient demographics, operative records, clinical notes including a description of presentation and radiographs were obtained and reviewed for the cases.

Radiographs were assessed for the following parameters. The cup inclination was measured by determining the horizontal axis of the radiograph according to the inter-teardrop line, constructing a line along the face of the cup and measuring the acute angle between these two lines. Cup migration was measured in the vertical axis (relative to the horizontal axis defined above) and in the horizontal axis (for this measurement, a vertical line was constructed perpendicular to the horizontal axis defined above at the lowest point of the tear drop, horizontal migration was measured relative to this line). Radiolucencies were measured according to the method of DeLee and Charnley⁷ and osteolysis⁸ was recorded in each of the DeLee and Charnley zones.

Of the 29 patients, 12 were male and 17 female. The median age of the patients was 70 (inter-quartile range (IQR) 63 to 77 years). The median age at revision surgery was 65 years (IQR 61-73 years). The median time from primary surgery to revision surgery was 13 years (IQR 10-16 years).

Data distribution was checked with the D'Agostino and Pearson omnibus test. The data distribution for the OHS was normally distributed therefore central tendency and distribution is described with the mean and range. For data that was non-parametric the central tendency of the data was described with the median value and data distribution by the inter-quartile range (IQR). The OHS in the groups was compared with an unpaired t-test. A post hoc power calculation was performed with a calculated effect size and an assumed alpha value of 0.05.

Results

The description of precipitating symptoms was recorded in 22 cases. Pre-revision radiographs were available in 23 cases. Operative reports and intraoperative findings were available for all cases. Current Oxford Hip Scores were available for 22 cases.

Oxford Hip Scores

The median time from revision surgery to assessment with the Oxford Hip Score was 53 months (IQR 34-86). The mean score was 34 (range 6-48) with 48 being the best outcome ⁹. The mean OHS in patients who had an initially missed diagnosis and a delay to theatre was 29 (range 6-45). The mean OHS in those undergoing revision surgery within one month of a correct diagnosis at specialist review (12 cases) was 39 (range 20-48). There was an observed trend to poorer outcomes in the delayed group but this difference was not significant ($p=0.065$) however the study is underpowered to detect a difference between the groups (post hoc power calculation, calculated effect size of 0.83 and assuming an alpha value of 0.05 the calculated power was 0.54).

Mode of presentation

14 patients described an episode of sudden onset pain in the hip and presented to primary care for evaluation. 11 of the patient presented to their primary care doctor and 3 to the Emergency Department. 3 patients had a fall preceding the episode of pain. Of the 11 patients presenting to their primary care doctor, 9 patients described the pain being followed by a “grating” or “clunking” sound

coming from the hip joint. 8 patients described hip pain, without an acute episode and in whom the diagnosis was an incidental finding. In 7 cases there was no description of the preceding symptoms available in the medical records and the patient did not recall the mode of presentation.

Where recorded, the median time from onset of symptoms to revision surgery was 123 days (IQR 49-227, n=20). The median time from specialist review to revision surgery was 29 days (IQR 18-192, n=22).

Specialist review

In 15 cases the diagnosis was made correctly at specialist review by a senior orthopaedic surgeon (Consultant or Specialist Registrar); this led to revision surgery at a median of 21 days (IQR 13-33 days). In 7 cases the diagnosis was missed, leading to a delay in surgery for these patients (median 540 days, IQR 175-600). In 7 cases there was no pre-operative diagnosis documented in the case notes.

In 10 cases there was a formal radiological report completed by a Radiologist. In 5 of the cases the diagnosis of wear or liner dissociation was missed on the formal radiology report.

Figure 1 shows an AP pelvic of a patient in which the formal radiology report missed the diagnosis of polyethylene liner dissociation.

Radiographic features

Pre-operative radiographs were assessed for abduction angle, cup migration, radiolucency and osteolysis. The median abduction angle of the cup was 42 degrees (IQR 34° to 51°). There was migration of the cup (>2 mm horizontal or vertical migration) in 4 out of 23 cases. 8 cases had radiolucency around the cup (the incidence per DeLee and Charnley zone is shown in [Figure 2](#)). 5 cases had radiolucency in a single zone as described by Charnley and DeLee and 3 cases had radiolucency in 2 zones. 22 out of 23 cases showed retroacetabular osteolysis (the incidence per DeLee and Charnley zone is shown in [Figure 3](#)). In 11 cases this was in a single zone. In 6 cases there was osteolysis in zones 1 and 2, and in 2 cases in zones 2 and 3. In 3 cases there was osteolysis in all 3 zones.

Operative Findings

Review of the operation notes yielded well-documented intraoperative findings. In all cases the liner had dissociated. There was also visible wear of the liner, damage to the femoral head and damage to the acetabular cup in all cases. There was liner fracture in 3 out of the 29 cases.

The shell was well fixed in 20 out of 29 cases, but there was obvious osteolysis in 27 cases. The acetabular cup was revised in all but 1 case. The acetabular cup and femoral stem was revised in 22 cases, and there was revision of the acetabular cup and femoral head alone in 6 cases.

Discussion

Modular acetabular components with a metal backed shell and a polyethylene liner are commonly used in total hip arthroplasty¹. It is well known that once the polyethylene liner has worn or rim fracture has occurred, it may deform and become dissociated¹¹. Furthermore, the HG prosthesis has locking tines that may break, thereby increasing the risk of liner dissociation¹².

This study shows that revision after liner dissociation leads to poor patient related outcomes especially if the diagnosis and surgery are delayed. Delay in surgery results in unnecessary pain and suffering for patients and in more difficult revision surgery due to aggressive wear of the metal backed shell with resultant metal contamination of surrounding tissues. It may therefore be better to pre-empt dissociation by exchanging worn liners.

We have noted some clear patterns of clinical symptoms associated with liner dissociation including a sudden onset of pain, a history of fall and a grating or clunking sound emanating from the hip. This is in contrast to the previous largest reported series of this pathology in which the majority of the cases were of spontaneous onset¹².

There are a number of limitations to this study. As a retrospective case series, there were no pre-operative Oxford hip scores were available. Also, due to the data collection being over a relatively long time period and variability in the

detail in the case notes, there are some incomplete data sets, weakening our analysis.

Liner dissociation is a rare event and thus clinicians do not have a high index of suspicion, particularly if they are not hip surgeons. A high dissociation rate was however noted for the HG 1 cup and a previous study reported that 7% of their acetabular components dissociated¹³. This prompted a change of design to the locking tines and polyethylene thickness in the HG 2 cup. Again, however, dissociation was a common failure mechanism for the second generation implant. A survey of the members of the American Association of Hip and Knee surgeons reported a revision rate of 15/10,000 for modular disassembly of the acetabulum². This low incidence may explain why in so many cases the initial diagnosis was missed in our cohort.

The radiological signs of liner dissociation have been described in the musculoskeletal radiology literature as a crescent shaped radiolucency medial to the femoral neck in conjunction with an eccentrically placed femoral head¹⁰. However, the same investigation can be interpreted in different ways by different specialists, and in our series the reporting radiologists often missed the diagnosis. It is our experience that in cases such as these, review of radiology by a Radiologist alone is not sufficient to detect this mode of failure. This may contribute to a delay in diagnosis, particularly in the context of community based follow up where General Practitioners are often dependent on Radiologist reports of imaging.

We have previously reported that exchange of a worn HG liner is a relatively benign procedure with a dislocation rate of approximately 12%, but low rates of all other complications¹⁴. Other authors have also reported low complications with isolated liner revision¹⁵, but this is not universal with some authors experiencing higher complications with liner exchange than complete revision of the acetabulum¹⁶.

In conclusion, in our series liner dissociation had a classic presentation of sudden onset pain followed by grinding or clunking in the hip joint. Liner dissociation is an easily missed diagnosis, even by radiologists. When liner dissociation is missed, it leads to revision surgery that may have poorer outcomes. Prompt diagnosis and early revision may be associated with better outcomes.

However, liner wear is common and easy to identify on radiographs. Liner exchange is a relatively benign operation. Furthermore, given the classic presentation of liner dissociation, it can be identified early and treated promptly.

Figure legend

1.

AP radiograph of the hips of a patient showing migration of the right femoral head within the acetabulum associated with polyethylene liner dissociation. The formal radiology report stated “AP Pelvis radiograph: Since the previous examination there has been a left total hip replacement. No complications. No change in the appearances on the right.”

2.

Graphic representation of the number of cases showing radiolucency in each of the three DeLee and Charnley zones.

3.

Graphic representation of the number of cases showing retroacetabular osteolysis in each of the three DeLee and Charnley zones.

References:

- 1 **10th Annual Report of the National Joint Registry for England, Wales and Northern Ireland**, Hemel Hempstead, 2013
2. Heck DA, Partridge CM, Reuben JD, Lanzer WL, Lewis CG, Keating EM. Prosthetic component failures in hip arthroplasty surgery. *J Arthroplasty*. 1995;10(5):575-580. [doi:10.1016/S0883-5403\(05\)80199-8](https://doi.org/10.1016/S0883-5403(05)80199-8). [Medline](#)
3. Anseth SD, Pulido PA, Adelson WS, Patil S, Sandwell JC, Colwell CW Jr. Fifteen-year to twenty-year results of cementless Harris-Galante porous femoral and Harris-Galante porous I and II acetabular components. *J Arthroplasty*. 2010;25(5):687-691. [doi:10.1016/j.arth.2009.05.033](https://doi.org/10.1016/j.arth.2009.05.033). [Medline](#)
4. Utting MR, Raghuvanshi M, Amirfeyz R, Blom AW, Learmonth ID, Bannister GC. The Harris-Galante porous-coated, hemispherical, polyethylene-lined acetabular component in patients under 50 years of age: a 12- to 16-year review. *J Bone Joint Surg Br*. 2008;90(11):1422-1427. [doi:10.1302/0301-620X.90B11.20892](https://doi.org/10.1302/0301-620X.90B11.20892). [Medline](#)
5. Werle J, Goodman S, Schurman D, Lannin J. Polyethylene liner dissociation in Harris-Galante acetabular components: a report of 7 cases. *J Arthroplasty*. 2002;17(1):78-81. [doi:10.1054/arth.2002.29327](https://doi.org/10.1054/arth.2002.29327). [Medline](#)
6. Han CD, Choe WS, Yoo JH. Late dissociation of the polyethylene liner from a modular acetabular metal shell after primary total hip arthroplasty—a report of five cases. *Yonsei Med J*. 1998;39(3):277-282. [doi:10.3349/ymj.1998.39.3.277](https://doi.org/10.3349/ymj.1998.39.3.277). [Medline](#)
7. DeLee JG, Charnley J. Radiological demarcation of cemented sockets in total hip replacement. *Clin Orthop Relat Res*. 1976;(121):20-32 [Medline](#).
8. Orishimo KF, Claus AM, Sychterz CJ, Engh CA. Relationship between polyethylene wear and osteolysis in hips with a second-generation porous-coated cementless cup after seven years of follow-up. *J Bone Joint Surg Am*. 2003;85-A(6):1095-1099 [Medline](#).
9. Murray DW, Fitzpatrick R, Rogers K, et al. The use of the Oxford hip and knee scores. *J Bone Joint Surg Br*. 2007;89(8):1010-1014. [doi:10.1302/0301-620X.89B8.19424](https://doi.org/10.1302/0301-620X.89B8.19424). [Medline](#)
10. White SP, Blom AW, Lee M, Smith EJ. The crescent sign: dissociation of the polyethylene liner from a modular acetabular component in total hip arthroplasty. *Skeletal Radiol*. 2005;34(10):620-624. [doi:10.1007/s00256-005-0927-6](https://doi.org/10.1007/s00256-005-0927-6). [Medline](#)
11. French K, Moore R, Gawel H, et al. Retrieval analysis of Harris-Galante I and II acetabular liners in situ for more than 10 years. *Acta Orthop*. 2012;83(4):366-373. [doi:10.3109/17453674.2012.717843](https://doi.org/10.3109/17453674.2012.717843). [Medline](#)
12. González della Valle A, Ruzo PS, Li S, Pellicci P, Sculco TP, Salvati EA. Dislodgment of polyethylene liners in first and second-generation Harris-Galante acetabular components. A report of eighteen cases. *J Bone Joint Surg Am*. 2001;83-A(4):553-559 [Medline](#).
13. Saito S, Ryu J, Seki M, Ishii T, Saigo K, Mori S. Analysis and results of dissociation of the polyethylene liner in the Harris-Galante I acetabular component. *J Arthroplasty*. 2008;23(4):522-526. [doi:10.1016/j.arth.2007.06.004](https://doi.org/10.1016/j.arth.2007.06.004).

Commented [eXtyles1]: CrossRef reports the volume should be "90-B" not "90" in reference 4 "Utting, Raghuvanshi, Amirfeyz, Blom, Learmonth, Bannister, 2008".

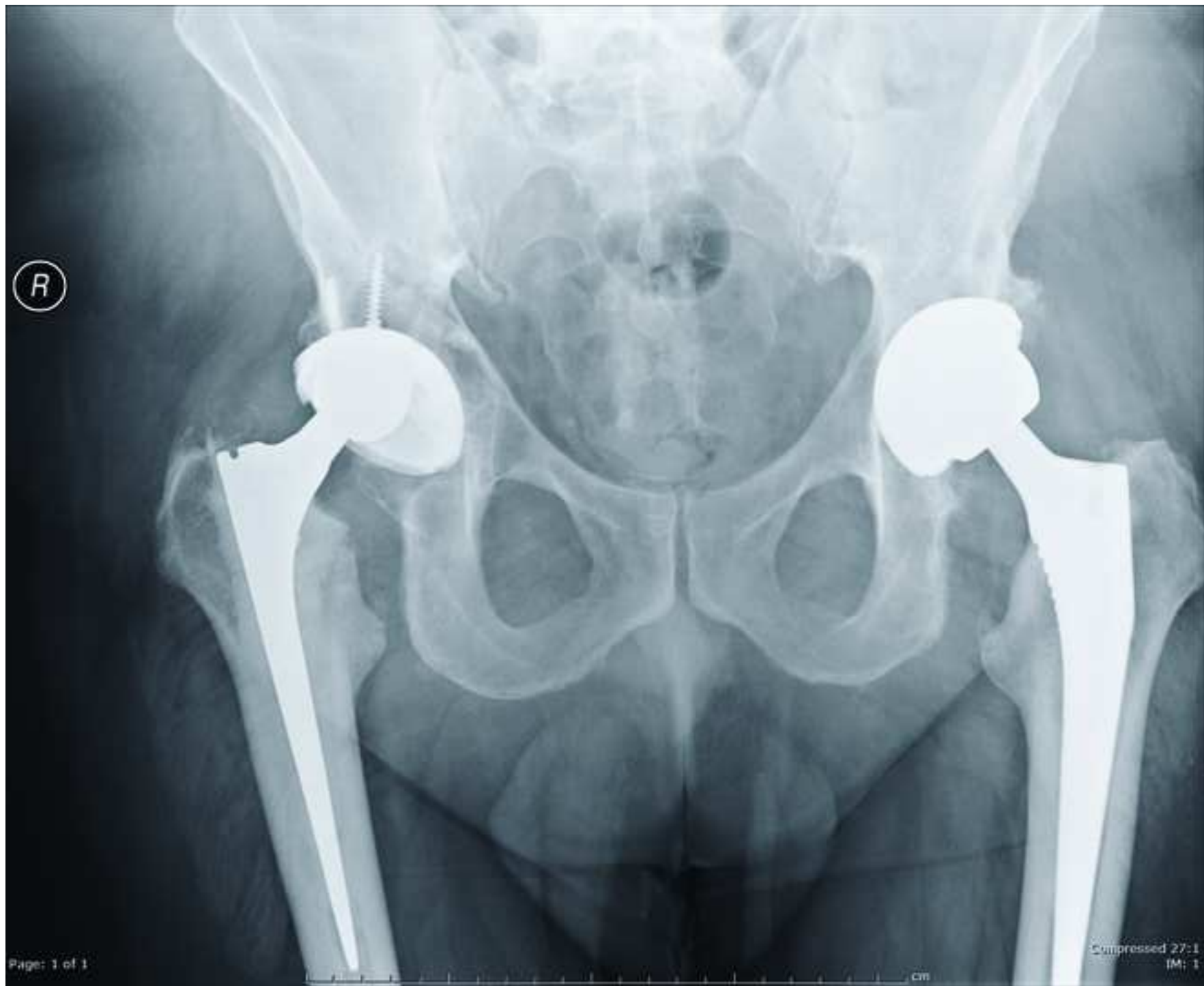Commented [eXtyles2]: CrossRef reports the volume should be "89-B" not "89" in reference 9 "Murray, Fitzpatrick, Rogers, et al, 2007".

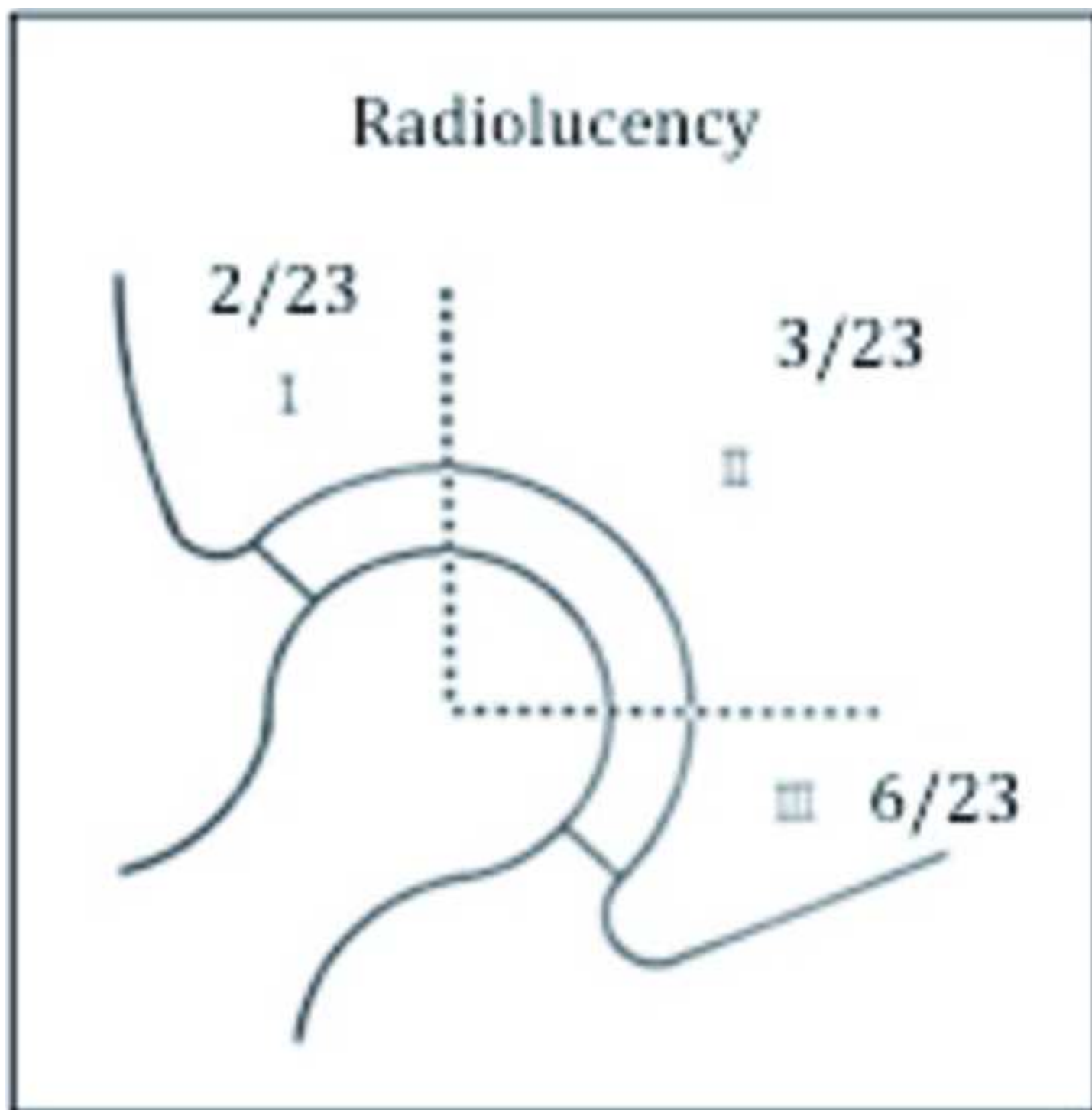
[Medline](#)

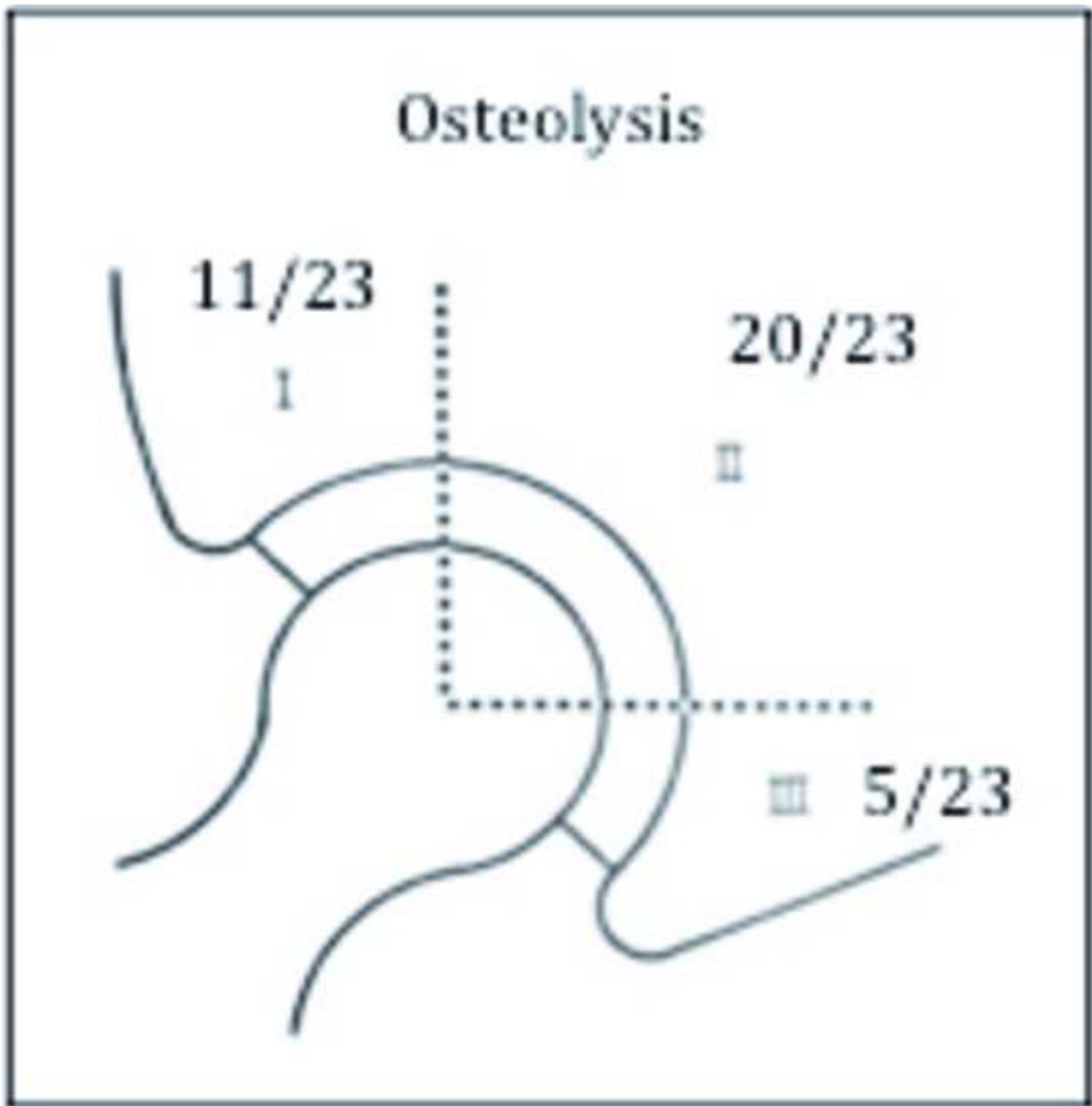
14. Blom AW, Astle L, Loveridge J, Learmonth ID. Revision of an acetabular liner has a high risk of dislocation. *J Bone Joint Surg Br.* 2005;87(12):1636-1638. [doi:10.1302/0301-620X.87B12.16349](https://doi.org/10.1302/0301-620X.87B12.16349). [Medline](#)
15. Archibeck MJ, Junick DW, Cummins T, Carothers J, White RE Jr. Polyethylene exchange in a second-generation cementless acetabular component. *J Arthroplasty.* 2009;24(6)(Suppl):69-72. [doi:10.1016/j.arth.2009.05.004](https://doi.org/10.1016/j.arth.2009.05.004). [Medline](#)
16. Talmo CT, Kwon YM, Freiberg AA, Rubash HE, Malchau H. Management of polyethylene wear associated with a well-fixed modular cementless shell during revision total hip arthroplasty. *J Arthroplasty.* 2011;26(4):576-581. [doi:10.1016/j.arth.2010.05.028](https://doi.org/10.1016/j.arth.2010.05.028). [Medline](#)

Commented [eXtyle3]: CrossRef reports the volume should be "87-B" not "87" in reference 14 "Blom, Astle, Loveridge, Learmonth, 2005".

Figure 1
[Click here to download Figure: Figure 1.tiff](#)







This document is signed by the corresponding author on behalf of all co-authors.

The author who signs this agreement has full right, power and authority to enter into this agreement on behalf of all co-authors. Listed Authors have agreed to be listed authors and have granted the signing author authority to enter into this agreement on their behalf.

Corresponding Author	Mr Andrew Grazette
Date	19/05/2015

Manuscript Title	A review of outcomes and modes of presentation following liner dissociation from Harris-Galante uncemented acetabular components.
------------------	---

Transfer of copyright

Authors agree to transfer and assign exclusively to **Wichtig Publishing Srl** (Publisher) all Author's right, title and interest in the Article, including, without limitation, the copyright therein. These rights include mechanical, electronic and visual reproduction; electronic storage and retrieval; and all other forms of electronic publication or any other types of publication including all subsidiary rights.

In return for the above rights, the authors retain the following rights:

Provided the source is fully quoted at all times, authors are hereby granted the right to:

- a) Reproduce the manuscript in whole or in part in any printed book or thesis of which they are the author(s).
- b) They and any academic institution where they work at the time may reproduce the manuscript in a reasonable number of copies for the purpose of course teaching. This does not apply if a commercial charge is made for the training course.
- c) To post a copy of the manuscript as accepted for publication after peer review (in word or text format) on the authors' website provided that they also link to the article on the journal's web site.
- d) To reuse figures or tables created by them and contained in the manuscript in other works created by them.

Compliance with funding bodies

Authors retain the right to provide a copy of the final peer-reviewed manuscript to the NIH or other funding agencies upon acceptance for publication, in accordance to the organization's policy. It is the authors' responsibility to take the necessary actions to achieve compliance.

Authorship responsibility


Each author certifies they have participated sufficiently in the preparation of this work to take public responsibility for it.

Each author warrants and certifies that:

- a) This work does not violate any trademark registrations nor the right of privacy of any person, contains libelous, obscene, or other unlawful matter, and does not infringe upon the statutory or common law copyright or any other right of any person or party.
- b) Each author warrants that this manuscript is original, has not been published elsewhere in any form, electronic or in print –in part, or its entirety – and is not being considered for publication elsewhere while under consideration for this publication.
- c) The authors certify also that the data on which the manuscript is based will be supplied upon request of the reviewers if required.
- d) Each author further warrants that he or she has obtained, prior to submission, written releases from patients whose names or photographs are submitted as part of the work and that they will be supplied upon request.
- e) Nothing in the contribution is obscene, defamatory, libelous, violates any right of privacy or infringes any intellectual property rights (including copyright, patent or trademark) or any other human, personal or other rights of any person or entity or is otherwise unlawful.
- f) Nothing in the contribution infringes any duty of confidentiality which any of the authors may owe to anyone else or violates any contract, express or implied, of any of the authors, and all of the institutions in which work recorded in the contribution was carried out have authorised its publication.
- g) If the contribution includes materials of others excerpts (text, figures, tables, or illustrations), the authors have obtained written permission from the copyright holder prior to submission to enable them to grant the rights contained herein. Copies of all such permissions are attached to the submission and credit to the original publication has been properly acknowledged in the manuscript.
- h) Authors hereby consent to the inclusion of electronic links from the contribution to third-party material wherever it may be located.

If the manuscript will for any reason not be published, the Publisher will give prompt notice to the Author and this agreement shall terminate. Neither the author(s) nor the publisher shall be under any further liability or obligation.

Signed for and on behalf of the authors: _____



Wichtig Publishing Srl

Via Friuli 72 | 20135 Milan, Italy | VAT 03945040156