

Yamagata Med J 2015 ; 33(1) : 9-15

Efficacy of Electrochemotherapy with Bleomycin to the Murine Osteosarcoma Model

Akira Ishikawa^{*,**}, Takashi Tsuchiya^{**}, Masato Sugawara^{**}, Michiaki Takagi^{**}

^{*}Department of Orthopaedic Surgery, Yamagata Prefectural Central Hospital

^{**}Department of Orthopaedic Surgery, Yamagata University Faculty of Medicine

(Accepted September 22, 2014)

ABSTRACT

Background : Electrochemotherapy is a unique treatment to enhance the drug permeability of tumor cells. It is believed that osteosarcoma lacks the membrane proteins, which constitutes an obstacle in achieving drug transport for chemotherapy. We performed the electrochemotherapy with bleomycin to evaluate the efficacy of the treatment in an animal model of osteosarcoma. The tumor response, tissue concentration of bleomycin and histology were analyzed.

Materials and Methods : SCID mice that had been subcutaneously implanted with osteosarcoma cells were subjected to electroporation, bleomycin, both or with no treatment as a control.

Results : Cells cycle arrest and growth inhibition were observed in the murine osteosarcoma only in the electroporation with bleomycin plus group. The tissue concentrations of bleomycin were high in the bleomycin plus group and low in the bleomycin alone group.

Conclusion : The present study indicates that electrochemotherapy with bleomycin may be an effective treatment for osteosarcoma.

Key words : Electroporation, Chemotherapy, Bleomycin, Treatment effectiveness, Osteosarcoma

Introduction

Osteosarcoma is the most common primary malignant tumor of bone in children and young adults and requires aggressive treatment due to its clinical behavior. Before the 1970s, osteosarcoma patients were mainly treated with amputation, and the five-year survival rate was less than 20% due to uncontrollable metastases. Postoperative adjuvant chemotherapy improved the prognosis during the 1970s¹⁾. In 1979, Rosen *et al.* advocated preoperative chemotherapy or neoadjuvant chemotherapy²⁾. After the introduction of these combined approaches with surgery and chemotherapy, wide resection of the tumor and limb-sparing operations with endoprosthesis were generally applied, and the prognosis of

patients with a localized osteosarcoma improved to a five-year survival rate of 50-60%^{3), 4)}.

It is believed that the cell membrane of osteosarcoma cells lacks the membrane proteins that participate in the membrane transport of drugs, which reduces the drug transport into the cells for cancer chemotherapy¹⁾. Because of the low permeability of the osteosarcoma cells to anticancer drugs, high dosages of these drugs have been used in the chemotherapy for osteosarcoma. However, this has not proven to be a solution to the problem of treating osteosarcoma.

However, a new mode of treatment to enhance the cytotoxic effects employing electrical pulses has been introduced in cancer chemotherapy in the past recent decade^{5), 6)}. This electrical pulse, generally termed electroporation, leads to the transient formation of a

pore on the cell membrane, and has been established in the area of genetic engineering as a means to raise the "in-flow" of a substance through cell membranes. Electroporation has commonly been applied for purposes such as the genetic transduction of DNA into cells^{7), 8)}. With regard to the application of this technique to cancer chemotherapy, there have been reports on electrochemotherapy (ECT) in which electroporation was employed in squamous cell carcinoma to enhance the transport of bleomycin (BLM), which is a water-soluble drug that normally resists permeation through the lipid bilayer of the cell membrane into cancer cells⁹⁻¹¹⁾. There have also been reports^{12), 13)} of the treatment of sarcoma-bearing animals that described a high response rate of these tumors. The use of ECT in the reports provided advantages of a high efficacy of treatment, a decrease in the effective drug dose and a reduction of toxicity and side effects.

In clinical practice, BLM has been administered for the treatment of osteosarcoma, mainly in advanced cases with pulmonary metastasis¹⁴⁾. Meanwhile, Rosen *et al.*²⁾ stated that BLM was effective against the primary foci of osteosarcoma. However, there have been no reports on the detailed mechanisms by which BLM exerts its antineoplastic effects against osteosarcoma.

We considered the feasibility of applying electroporation as a means to enhance the BLM transport into osteosarcoma cells, and conducted a study of ECT in a murine osteosarcoma model. The present study is the first trial to apply *in vivo* ECT with BLM for osteosarcoma. We chose to use BLM for this animal study on osteosarcoma, because the osteosarcomas have been reported to lack the membrane protein responsible for drug permeability, and BLM is poorly transported through the lipid bilayer of the cell membrane.

We observed the sequential changes of the tumor volume, the tissue concentration of BLM and the changes in histology to evaluate the efficacy of ECT with regard to the intracellular transport of BLM.

Materials and Methods

Animals Female, five-week-old, SCID mice (Fox

Chase SCID C.B-17/Icr-scid Jcl) were obtained from Japan Clea, and had an average weight of 25.0 g (range 21.0-27.6 g). These animals were housed under specific-pathogen free conditions because they had severe combined immunodeficiency and lacked both mature T cells and B cells.

Tumor The tumor was a surgical sample that had been collected from a patient with osteosarcoma of the osteoblastic type located at a proximal humerus. For preoperative chemotherapy, cis-diamminedichloroplatinum was given once, and high doses of methotrexate-citrovorum factor rescue therapies were given twice. The tumor continued to grow in spite of the chemotherapy, and the patient was subjected to a scapulo-thoracic transection. A sample was collected from the lesion of the amputated limb for use in the present study. The material was transferred into culture medium (Dulbecco's Modified Eagle Medium: Gibco BRL). The tumorous lump was minced into fine pieces and passed through an 18-gauge needle. Minced tumor mixed with media was injected subcutaneously into the back of each mouse. SCID mice were anesthetized in the contained filled with diethylether gas before the tumor implantation. Two weeks after the implantation of the osteosarcoma, solid and almost round tumors had developed on the back, with an average diameter of 6 mm (range 5-11 mm). At this time, the experimental treatment were started.

Electrochemotherapy (ECT) SCID mice were anesthetized with Nembutal[®] (Pentobarbital sodium solution, Dainippon Sumitomo Pharma Co. Ltd., Japan, contents of 50 mg/ml) at a dose of 0.5 mg/10 g body weight intraperitoneally. A total of 24 animals with established tumors were then classified into four different treatment groups, as follows:

a) Bleomycin (BLM) treatment : The dose of BLM, which was generously provided by NIPPON KAYAKU Co. Ltd., Japan, was set at one tenth of the dose that was lethal to 50% of mice (LD50) per animal. The dose of 0.25 mg BLM was dissolved in 100 μ l of physiological saline per animal (10 mg/kg), and was injected via an intramuscular route into the right femoral area. The groups that received BLM were designated as D(+) and the groups that did not was D(-).

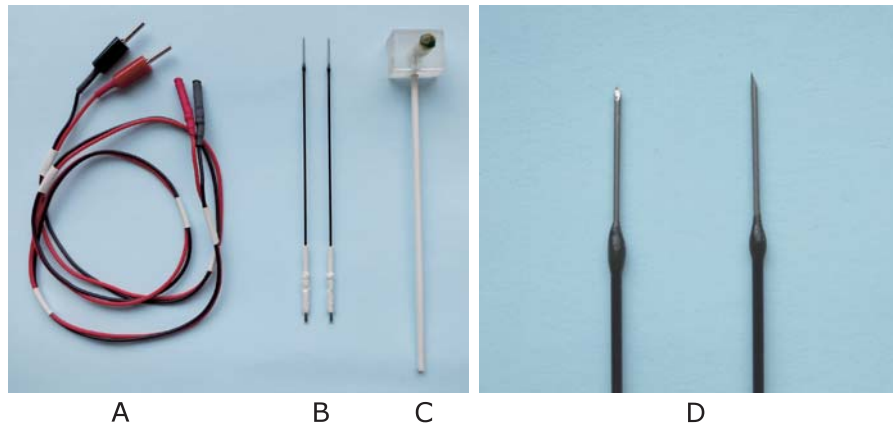


Figure 1. A set of needle electrode

A needle electrode is made of stainless steel with insulated handle, and its tip is coated by gold. The two electrodes can be fixed by a plastic shank fixture.

A : Code

B : Needle electrodes

C : Plastic shank fixture for the needle electrode

D : Magnified image of the tip of electrode

b) Electroporation (EP) treatment : The EP was started at 30 minutes after the injection of BLM into each SCID mouse. This 30-minutes interval was necessary to obtain the maximum blood concentration of BLM after intramuscular injection¹⁵⁾. A pulse generator (Electro Square Porator T820, Genetronics, Inc. USA) was used to deliver exponential pulses of variable voltage (500-3000 volts) and duration (0.99-99 milliseconds). Needle electrodes (Unique Medical Imada Inc. Sendai, Japan) made of stainless steel (Figure 1), which were inserted through the skin so that they were located on each side of the subcutaneous tumor at its maximum diameter. Eight exponential pulses of 1000 volt/cm for 99 μ seconds were given at 1Hz. The groups that were subjected to EP were designated as E(+), and those without were designated E(-).

c) Experimental Groups : These animals were assigned to the BLM plus EP group (D(+))E(+)), a group that received BLM without EP (D(+))E(-)), a group that was subjected to EP alone (D(-))E(+)), or a group that received neither BLM nor EP treatment (D(-))E(-)). The number (n) of SCID mice in each group was set at 6.

d) Tumor Size : With the maximum long axis of the tumor designated as A (mm) and the axis

perpendicular to A designated as B (mm), the volume V (mm³) was determined from the formula; $V = \pi A \times B^2 / 6$. Setting the volume at the start of the experiment at 1, the tumor size was determined sequentially as the changes from the start that were computed in volume ratios.

Tissue Concentration of BLM The tissue concentration of BLM (μ g/g) was determined by a microbiological analysis based on the *Bacillus subtilis* growth inhibitory concentration of the BLM¹⁶⁾ that had been extracted from the tumor and muscle. In the D(+))E(+)) group, the tumor was immediately excised after EP. In the D(+))E(-)) group, the tumor was excised at 30 minutes after the intramuscular injection of BLM. At the same time, the muscle was excised from the left femoral regions where no BLM had been injected, and was used as the control for an analysis of the intramuscular concentration of BLM. The tumor and muscle were excised, their weights were measured, and they were immediately stored at -80°C . For the bioassay of the BLM, tumor tissues were homogenized in 7.5% trichloroacetic acid at two-folded the volume of the tumor. Each lysate was centrifuged at 10000 rpm for 10 minutes at 4°C , and the supernatant was neutralized with 1000 ml of buffer (30.8 g of KOH, 18 mg of phenol red, 0.067 M

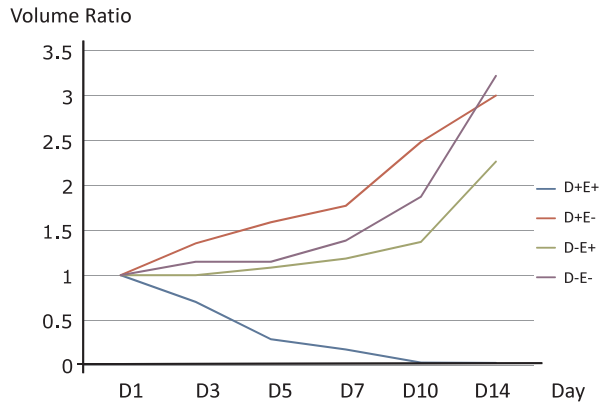


Figure 2. Sequential volume change of the tumor When the tumor volume on day 1 was set at 1, the tumor volume ratio was sequentially changed. On day 14, the volume ratio was reduced only in D(+)E(+) group. Numbers in each column represent the mean \pm SE, n=6.

phosphate buffered saline, pH7.2). The lowest measurable level of the concentration of BLM was 0.1-0.2 μ g/g. This method had an advantage of not being affected by BLM hydrase, a BLM-inactivating enzyme, during the extraction. The number of tissue samples used for the BLM concentration analysis was three each from D(+)E(+) group and D(+)E(-) group. NAC Co. Ltd., Japan, kindly analyzed the tissue concentrations of BLM.

Tissue preparation Tumor-bearing SCID mice were sacrificed before ECT as a control, and were also sacrificed at one week, three weeks and five weeks after ECT. The subcutaneous tumors on the backs of the mice were excised for the histological analyses. These materials were fixed in 4% paraformaldehyde for 24 hours, then embedded in paraffin. Sections were prepared for hematoxylin and eosin (HE) staining.

Immunohistochemistry Additionally, we performed immunohistochemical staining for macrophages using KP-1 mouse anti-human antibodies (DAKO Japan, Kyoto, Japan), and a secondary biotinylated antibody (the avidin-biotin complex staining method).

Statistical analysis The data are presented as the means \pm SE and were analyzed using the nonparametric Mann Whitney-U test to compare the tissue concentrations of BLM among the groups. These

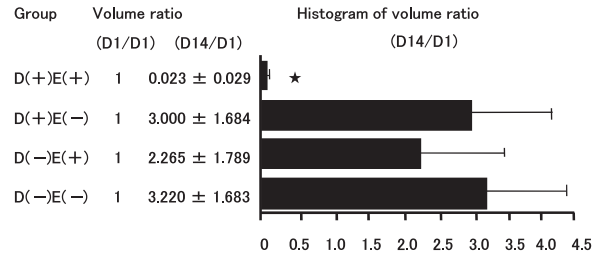


Figure 3. Volume ratio following electrochemotherapy When the tumor volume ratio on day 1 was set at 1, that for the D(+)E(+) group was reduced to 0.023 on day 14, showing that the combination with electroporation resulted in a significant reduction in tumor volume. The numbers in each column stand for the mean \pm SE, n=6.

★, $p < 0.01$ compared to other group.

statistical analyses were performed using the StatView J-4.5 software program (Abacus Concepts, Inc. Berkeley, USA). Differences were considered to be significant for values of $p < 0.05$.

Results

The SCID mice tolerated the treatment well and had no damage to the skin caused by electroporation.

Tumor response Among the four groups, marked tumor reduction was noted only in the D(+)E(+) group during the 14-days observation period (Figure 2). Among the six animals in this group, the tumor was eliminated completely in two animals on Day 10. The tumor volume ratio was sequentially reduced to 0.023 ± 0.029 on Day 14, showing a significant tumor reduction. In the D(+)E(-) group, the tumor sequentially increased in size, and no size reduction was noted for any of the tumors. The tumor volume ratio of 3.000 ± 1.684 on Day 14. In the D(-)E(+) group, the tumors increased in size, and no reduction in size was noted. The ratio reached to 2.265 ± 1.789 on Day 14. The D(-)E(-) group demonstrated a similar increase in tumor volume, reaching 3.220 ± 1.683 on Day 14, which was the highest among the four groups (Figure 3).

Tissue concentrations of BLM The mean concentra-

Efficacy of Electrochemotherapy with Bleomycin to the Murine Osteosarcoma Model

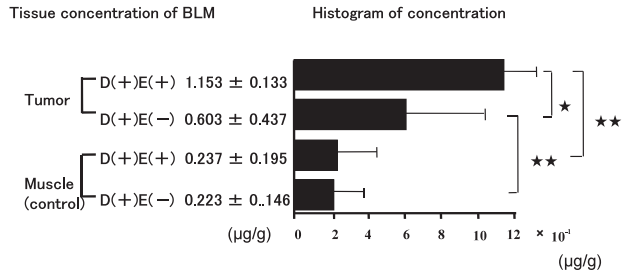


Figure 4. Tissue concentration of BLM

In one group, BLM was injected and followed by electroporation. In the other group, electroporation was omitted. In the former group, the BLM concentration in the tumor tissue was significantly raised. The tumor tissue concentration of BLM also exceeded that of the muscle tissue. No effects of electroporation were noted in the muscle tissue concentration that was used as the control. The numbers in each column represent the mean \pm SE, $n=3$.

★, $p < 0.05$ compared with electroporation or not.

★★, $p < 0.01$ compared with tumor and muscle tissue.

tion of BLM in the tumor tissue in the D(+)/E(-) group was $1.153 \pm 0.133 \mu\text{g/g}$, while it was $0.603 \pm 0.437 \mu\text{g/g}$ in the D(+)/E(-) group. These values were significantly different (★ $p < 0.05$). The BLM concentrations in the tumor tissues of the D(+)/E(+) group were also significantly higher than those in the muscular tissue used as a control (★★ $p < 0.01$). This difference was also found in the D(+)/E(-) group. In the D(+)/E(+) and D(+)/E(-) groups, the mean BLM concentrations of the muscle tissues used as the control were 0.237 ± 0.195 and $0.223 \pm 0.146 \mu\text{g/g}$, respectively, with no significant difference between these two values. Electroporation did not produce a notable difference

in the muscle concentration of BLM, which was not associated with the sites charged by the electrical pulse (Figure 4).

Histology In view of the histological findings before the ECT, the tumor tissue was localized in the fibrous capsule, and there were small cells sporadically located in the subcutaneous tissue around the tumor (as indicated by HE staining). At one week after ECT, the tumor tissue had divided into small lobules, and the capsule had changed into a thick band with round cell infiltration. At three weeks, there were massive hemorrhage and necrosis in the tumor tissue, and large monocytes were found around the tumor. At five weeks, the tumor cells had disappeared and monocyte infiltration occupied the entire region. In an investigation of the macrophage level determined by specific immunostaining (KP-1), infiltrating monocytes were identified at three weeks, and occupied the whole area at five weeks (Figure 5). In terms of the macroscopic findings, the tumor tissues were almost completely eradicated, with only traces of fibrous tissue still present at five weeks after ECT.

Based on these observations, it was concluded that electroporation after the intramuscular injection of BLM increased the BLM concentration in the subcutaneous tumor tissue on the backs of SCID mice, thus allowing the drug to exert a more potent cytotoxic effect against the osteosarcoma cells.

Discussion

The present study, the first trial to apply ECT to osteosarcoma in a murine model, indicated that BLM

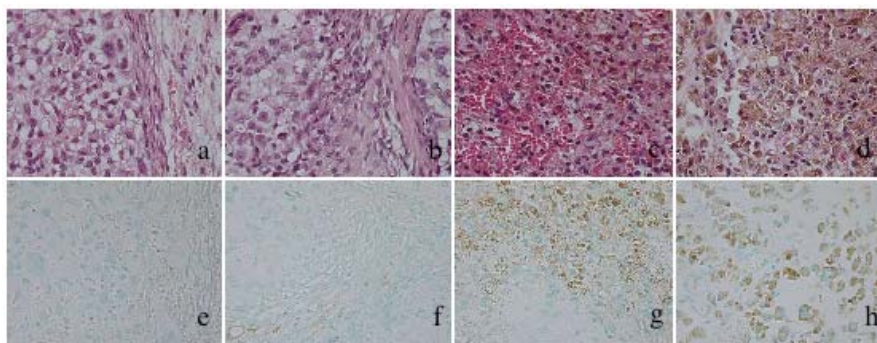


Figure 5. Histological changes

HE staining; a (before ECT), b (after 1 week), c (after 3 weeks), d (after 5 weeks), $\times 400$

KP-1 staining; e (before ECT), f (after 1 week), g (after 3 weeks), h (after 5 weeks), $\times 400$

could be detected at high concentrations in the osteosarcoma tissue, and that the tumor volume was reduced (or the tumors were completely eliminated) in less than two weeks from the start of treatment. This was considered to be due to the increased permeation of BLM into the tumor tissue, allowing it to exert cytotoxicity as an antineoplastic agent.

BLM is characterized by its specific pharmacokinetics and tissue affinity, and is distributed uniquely to each organ, with relatively high concentrations found in the lungs and skin, but has been shown to have almost no accumulation in bone marrow^{15), 17)}. We interpret the high concentration of BLM found in the osteosarcoma tissue in our specimens as follows: the affinity of BLM for osteosarcoma is greater than for muscle tissue as our data demonstrate that the concentration of BLM in osteosarcoma tissue without electroporation was $0.603 \pm 0.437 \mu\text{g/g}$, while that of BLM in muscle tissue was $0.223 \pm 0.146 \mu\text{g/g}$ under the same condition. We postulate that the accumulation of BLM in the osteosarcoma tissue through the enhancement by electroporation was further exaggerated by this tissue affinity. Due to the low permeability through the lipid bilayer, the BLM that flowed into the cells at a high concentration following ECT was prohibited from being transported back out of these cells after the resealing of the membranes; thus the agent tended to remain in the tumor cells for a prolonged period, which allowed it to exert its antineoplastic effects on the osteosarcoma.

Recently, there have been some reports that electrical pulses might provoke the closure of vessels afferent to the electropulsed area^{18)–20)}. This arterial closure might reduce the size of the tissue, while the venous occlusion would cause local congestion and edema, which would also have anti-tumor effects. In the present study, the tumor volume of the D(-)E(+) group illustrated exponential growth, but its growth was decreased compared to that of the D(-)E(-) group. This supports the idea that the effects of electroporation to the tumor might have led to vasospasms, and caused this growth suppression.

Histologically, the macrophage infiltration in the later period of observation after ECT with BLM indicated the possibility that there was immunoreponse involving the tumoricidal activity of macro-

phages²¹⁾. According to Morikawa, *et al.*²²⁾, BLM therapy activated tumoricidal macrophages that might participate in the host-mediated antitumor effects of BLM later. In the present study, macrophage infiltration was observed beginning at three weeks after ECT, so this reaction might be a secondary tumoricidal response to the combination of electrochemotherapy and BLM.

These results of the present study demonstrate that BLM accumulates in the tumor cells due to the agent's affinity for osteosarcoma, which is further enhanced by electroporation, thus achieving a potent antineoplastic effect. We conclude that electrochemotherapy with bleomycin may be an effective mode of treatment against osteosarcoma. Further studies are warranted to confirm the safety and efficacy of this treatment.

Acknowledgements

We are grateful to Ms. Eiko Saito for her help with the pathological specimen. The authors also appreciate Yamagata University for granting a Doctorate in Medicine based on this study.

References

1. Jaffe N: Adjuvant methotrexate and citrovorum factor treatment of osteogenic sarcoma. *N Engl J Med* 1974; 291: 994-997
2. Rosen G, Marcove RC, Caparros B, Nirenberg A, Kosloff C and Huvos A: Primary Osteogenic Sarcoma, The Rationale for Preoperative Chemotherapy and Delayed Surgery. *Cancer* 1979; 43: 2163-2177
3. Souhami RL, Craft AW, Van der Eijken JW, Nooij M, Spooner D, Bramwell VH, et al.: Randomized trial of two regimens of chemotherapy in operable osteosarcoma: a study of the European Osteosarcoma Intergroup. *Lancet* 1997; 350: 911-917
4. Haddox CL, Han G, Anijar L, Binitie O, Letson GD, Bui MM, et al.: Osteosarcoma in Pediatric Patients and Young Adults: A Single Institution Retrospective Review of Presentation, Therapy, and Outcome. *Sarcoma* 2014; Article ID 402509: 1-10
5. Mir LM, Orłowski S, Belehradek JJr and Paoletti C: Electrochemotherapy potentiation of antitumor effect of bleomycin by local electric pulses. *Eur J*

Efficacy of Electrochemotherapy with Bleomycin to the Murine Osteosarcoma Model

- Cancer 1991; 27: 68-72
6. Mali B, Jarm T, Snoj M, Sersa G, Miklavcic D: Antitumor effectiveness of electrochemotherapy: A systematic review and meta-analysis. *EJSO* 2013; 39: 4-16
 7. Teissie J and Tsong TY: Electric Field Induced Transient Pores in Phospholipid Bilayer Vesicles. *Biochemistry* 1981; 20: 1548-1554
 8. Neumann E, Schaefer-Ridder M, Wang Y and Hofschneider PH: Gene transfer into mouse lymphoma cells by electroporation in high electric fields. *EMBO J* 1982; 1: 841-845
 9. Orlowski S, Belehradek JJr, Paoletti C and Mir LM: Transient Electroporation of Cells in Culture Increase the Cytotoxicity of Anticancer Drugs. *Biochemical Pharmacology* 1988; 37: 4727-4733
 10. Belehradek M, Domenge C, Luboinski B, Orlowski S, Belehradek JJr and Mir LM: Electrochemotherapy, a New Antitumor Treatment First Clinical Phase I-II Trial. *Cancer* 1993; 72: 3694-3700
 11. Pron G, Belehradek JJr and Mir LM: Identification of a plasma membrane protein that specifically binds bleomycin. *Biochem Biophys Res Commun* 1993; 194: 333-337
 12. Mir LM, Orlowski S, Poddevin B and Belehradek JJr: Electrochemotherapy tumor treatment is improved by interleukin-2 stimulation of the host's defenses. *Eur Cytokine Netw* 1992: 3331-334
 13. Hyacinthe M, Jaroszeski MJ, Dang VV, Coppola D, Karl RC, Gilbert RA, et al.: Electrically enhanced drug delivery for the treatment of soft tissue sarcoma. *Cancer* 1999; 15: 409-417
 14. Mosende C, Gutierrez M, Caparros B and Rosen G: Combination Chemotherapy with Bleomycin, Cyclophosphamide and Dactinomycin for the Treatment of Osteogenic Sarcoma. *Cancer* 1977; 40: 2779-2786
 15. Fujita H: Pharmacokinetics of anticancer agents, Bleomycins. *Pharma Medica* 1985; 3: 128-142
 16. Ohnuma T, Holland J.F, Masuda H, Waligunda JA and Goldberg GA: Microbiological assay of bleomycin: inactivation, tissue distribution, and clearance. *Cancer* 1974; 33: 1230-1238
 17. Umezawa H, Takeuti T, Hori S, Sawa T and Ishizuka M: Studies on the Mechanism of Antitumor Effect of Bleomycin on Squamous Cell Carcinoma. *J Antibiotics* 1972; 25: 409-420
 18. Ramirez LH, Orlowski S, An D, Bindoula G, Dzodic R, Ardouin P, et al.: Electrochemotherapy on liver tumours in rabbits. *Br J Cancer* 1998; 77: 2104-2111
 19. Sersa G, Cemazar M, Parkins CS and Chaplin DJ: Tumour blood flow changes induced by application of electric pulses. *Eur J Cancer* 1999; 35: 672-677
 20. Markelc B, Sersa G, Cemazar M: Differential mechanisms associated with vascular disrupting action of electrochemotherapy: intravital microscopy on the level of single normal and tumor blood vessels. *PLoS One*. 2013; 8(3): e59557
 21. Engstrom PE, Ivarsson K, Tranberg KG, Stenram U, Salford LG and Persson BRR: Electrically Mediated Drug Delivery for Treatment of an Adenocarcinoma Transplanted into Rat Liver. *Anticancer Res* 2001; 21: 1817-1822
 22. Morikawa K, Hosokawa M, Hamada J, Xu ZY and Kobayashi H: Possible participation of tumoricidal macrophages in the therapeutic effect of bleomycin on a transplantable rat fibrosarcoma. *Cancer Res* 1986; 46: 684-688