

Notice of the Cystohepatic Ducts in Cholecystectomy: A Report with Review of the literatures

**Ichiro Hirai, Akiko Takeshita, Toshiyuki Moriya, Akihiko Suzuki,
Jinfeng Ma, Koichi Suto, Akira Fuse, Wataru Kimura**

*Department of Gastroenterological and General Surgery,
Yamagata University School of Medicine, Yamagata, Japan
(Accepted October 4, 2005)*

ABSTRACT

A 74-year-old man presented with epigastralgia and was diagnosed as having cholelithiasis. Endoscopic retrograde cholangiopancreatography (ERCP) initially visualized the cystic duct with the Heister valve from the common bile duct, and then two intra-hepatic biliary ducts of segment 5 (B5) were visualized from the neck of the gallbladder. There was a contrast medium filling defect in B5, which was considered to be due to an incarcerated stone. Magnetic resonance cholangiopancreatography (MRCP) and three-dimensional computed tomography (CT) cholangiography showed similar findings, suggesting that the patient had a biliary anomaly of the cystohepatic duct in which two intrahepatic bile ducts (B5) flowed into the neck of the gallbladder and a stone incarcerated in the neck of the gallbladder.

At surgery, during mobilization of the gallbladder, there was a thick string between the liver and the gallbladder, and this was considered to be the junction of B5 with the gallbladder. Therefore, the neck of the gallbladder was cut, and an incarcerated stone 10 mm in diameter was removed. Intraoperative cholangiography revealed that the cystohepatic ducts were preserved. The postoperative course was uneventful and there was no bile leakage or liver dysfunction.

Although cystohepatic duct is a rare biliary anomaly, the surgeon should be alert for its possible presence during cholecystectomy. When cholecystectomy is scheduled, more than one preoperative examination by three-dimensional CT cholangiography, MRCP or ERCP should be performed, and the surgeon should be careful not to overlook any biliary anomaly.

Key words : cystohepatic duct, biliary duct anomaly, cholecystectomy, three-dimensional computed tomography, gallstone

Address for Correspondence : Wataru Kimura, Department of Gastroenterological and General Surgery, Graduate School of Medicine, University of Yamagata, 2-2-2 Iida-Nishi, Yagata-city, Yamagata 990-9585, Japan

INTRODUCTION

Anomalies of the bile ducts are rare but occur with sufficient frequency, and therefore surgeons should bear in mind that various types exist. Recently, laparoscopic surgery has become the standard treatment for cholecystectomy. However, biliary tract injury is still a serious surgical complication. Tsalis et al. reported that bile duct injury occurred in 0.4-1.0% of all laparoscopic cholecystectomy procedures¹. Variations in biliary anatomy can increase the risk of ductal injuries when laparoscopic cholecystectomy is performed. Therefore, if the surgeon divides an anomalous biliary duct, various complications may occur, such as bile leakage, bile peritonitis, biliary stricture, obstructive jaundice, cholangitis and liver abscess²⁻⁴.

Cystohepatic duct is a rare biliary anomaly observed in 0.7% of all surgical cases and in 1.5% of all cadaveric dissections⁵. Here we report a case of intrahepatic bile ducts flowing into the gallbladder (cystohepatic ducts), which is an anomaly surgeons should be aware of during cholecystectomy.

CASE REPORT

A 74-year-old man, who had undergone coronary bypass for myocardial infarction at the age of 50 years, developed epigastralgia in January, 1999 and was diagnosed as having cholelithiasis. From October, 2003, he again suffered epigastralgia after eating, and was admitted for surgery on November, 2004. Laboratory tests revealed no abnormalities of liver function and no elevation of biliary enzymes. The conjunctivae were not icteric,

and no Murphy sign was evident in the abdomen.

Preoperative examinations

Preoperative ultrasonography showed a gallstone in the gallbladder, and computed tomography (CT) revealed a corresponding high-density mass in the neck and fundus of the gallbladder. CT showed lack of the segment 6, which was considered as congenital anomaly. Endoscopic retrograde cholangiopancreatography (ERCP) from the common bile duct initially visualized the cystic duct with the Heister valve (Fig. 1), then two intra-hepatic biliary ducts of segment 5 (B5) were visualized from the neck of the gallbladder. There was a contrast medium filling defect in the neck of the gallbladder, and this was considered to be due to an incarcerated stone. Several defects in the gallbladder were also evident. Magnetic resonance cholangiopancreatography (MRCP) showed similar findings (Fig. 2).

We considered this patient to have a biliary anomaly, and therefore carried out additional three-dimensional CT cholangiography after intravenous infusion of 100 ml of meglumine iotroxate (Biliscopin; Schering, Berlin, Germany) over 30 minutes. Spiral CT (Asterion, Toshiba, Tokyo, Japan) was performed 15-90 min later. The data were used to create a maximum intensity projection (MIP), and three-dimensional cholangiography data were reconstructed using a computer (Workstation ZioM900, AMIN, Tokyo, Japan). Three-dimensional CT cholangiography clearly revealed two intrahepatic bile ducts (B5) joining the neck of the gallbladder and an incarcerated stone in B5 (Fig. 3). Bile duct of the segment 6 was not detected with ERCP, MRCP and three-dimensional CT cholangiography.

Cystohepatic Ducts

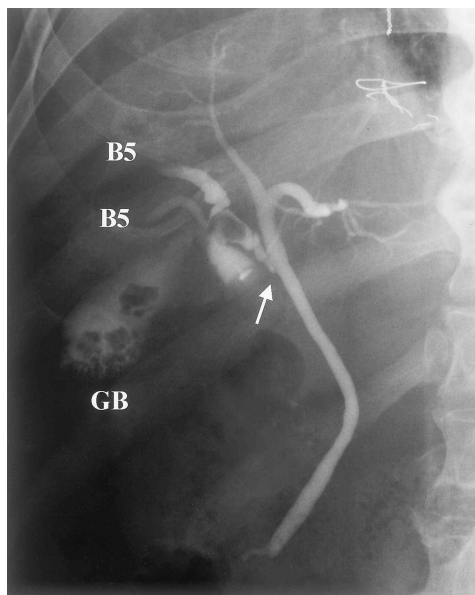


Fig. 1.

Endoscopic retrograde cholangiopancreatography (ERCP) from the common bile duct initially visualized a cystic duct with a Heister valve (*arrow*). Then two intra-hepatic biliary ducts of segment 5 (B5) were visualized from the neck of the gallbladder (GB). There was a contrast medium filling defect in the neck of the gallbladder, and this was considered to be due to an incarcerated stone.

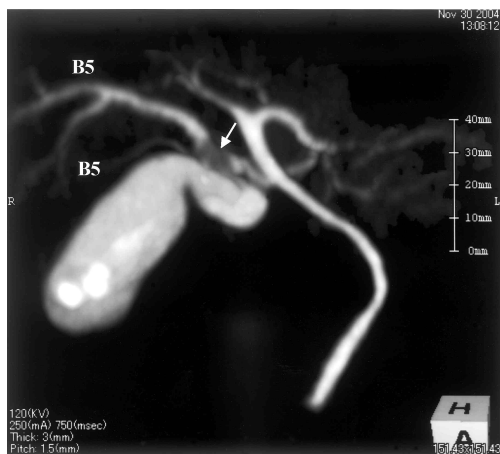

Fig. 3.

Three-dimensional CT cholangiography clearly revealed intrahepatic bile ducts (B5) joining the neck of the gallbladder and an incarcerated stone (*arrow*).

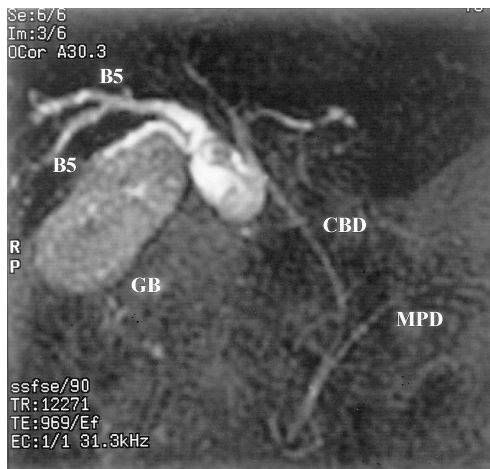


Fig. 2.

Magnetic resonance cholangiopancreatography (MRCP) showed findings similar to those of ERCP. However, as the intrahepatic bile duct and neck of the gallbladder overlapped in the MRCP image, it was slightly difficult to diagnose the biliary anomaly. GB, gallbladder; CBD, common bile duct; MPD, main pancreatic duct.

Operative findings

Surgery was performed using open laparotomy, rather than laparoscopy, because of the presence of the biliary anomaly. The gallbladder was dissected meticulously from the liver bed. Unlike the situation in a normal cholecystectomy, the neck of the gallbladder could not be retracted to the ventral side. Similarly, the cystic duct was not located in the usual area (Calot triangle). After mobilization of the gallbladder, a thick string was noted between the liver and the gallbladder and this was considered to be the junction of B5 with the gallbladder. Therefore, the neck of the gallbladder was cut, and the incarcerated stone, 10 mm in diameter, was removed (Fig. 4).

Intraoperative cholangiography from the neck of the gallbladder revealed two apparently preserved intrahepatic bile ducts (B5)

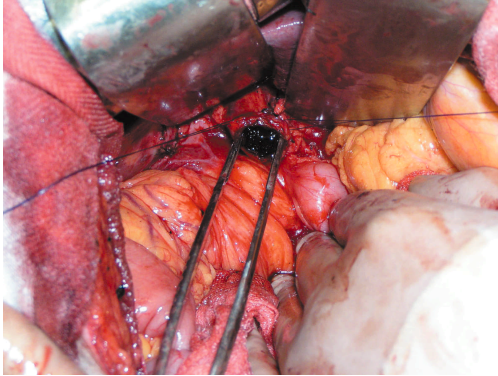


Fig. 4.
The neck of the gallbladder was cut, and an incarcerated stone 10 mm in diameter was extracted from B5.

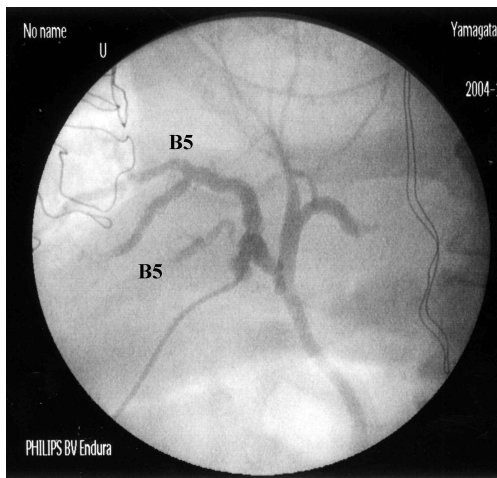


Fig. 5.
Intraoperative cholangiography from the neck of the gallbladder revealed two apparently preserved intrahepatic bile ducts (B5).

(Fig. 5). Preoperatively, we scheduled insertion of a T-tube into B5 when the cut end of the gallbladder was closed to the intrahepatic bile ducts. However, as there was enough distance from the cut end to the intrahepatic bile ducts, we decided to suture the cut end of the gallbladder neck without T-tube insertion. A schematic representation of this procedure is presented in Fig. 6.

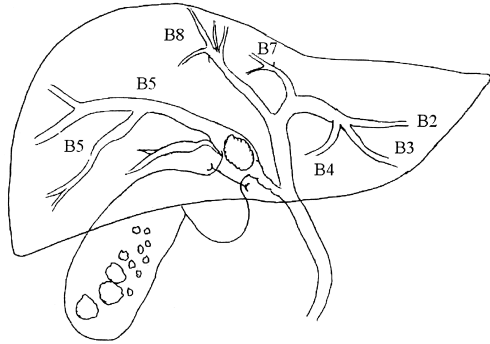


Fig. 6.
Schematic representation of the operative findings. There were two intrahepatic bile ducts (B5) joining the neck of the gallbladder and an incarcerated stone. B2, B3, B4, B7, and B8 are the bile ducts for segments 2, 3, 4, 7, and 8, respectively.

The postoperative course was uneventful, without bile leakage or liver dysfunction. At the outpatient clinic, three-dimensional CT cholangiography showed good bile passage in B5, and no stricture.

DISCUSSION

Classification of biliary anomalies

Embryologically, the liver and biliary tracts arise from an area on the ventral aspect of the gut, at the junction between the foregut and the midgut, which is divided into a cephalic portion and a caudal portion. The cephalic portion is termed the pars hepatica, and gives rise to the liver and the hepatic and common hepatic ducts. The caudal portion is the precursor of the gallbladder and its cystic duct, and it is termed the pars cystica. The common bile duct is derived from the antrum, which is the common portion of the hepatic diverticulum⁶⁾. Variations of the biliary ducts are considered to occur due to abnormalities

Cystohepatic Ducts

during development of the biliary tract. Mentzer et al. reported that about 10% of humans have anomalous biliary tracts^{7,8}.

Accessory bile ducts are aberrant ducts draining individual segments of the liver, and include intrahepatic bile ducts that do not enter the hepatic duct as normal, but instead enter the cystic duct, common bile duct or duodenum^{5-7, 9-11}. Accessory bile ducts are derived more frequently from the right lobe of the liver than from the left lobe, and have a reported frequency of about 2-18%^{8,12}. Drainage of the cystic duct into the main right hepatic duct is another somewhat uncommon biliary anomaly¹³.

The first description of hepatocholecystic duct was given by Luschka, who concluded that such ducts communicate between the liver and the gallbladder¹⁴. The existence of the Luschka duct is one of the reasons why drainage of the liver bed is necessary after cholecystectomy¹⁵. Previous reports have documented various biliary anomalies associated with accessory bile ducts, which in some cases also included bile ducts of individual liver segments that drained into the cystic duct or gallbladder^{12,16,17}, thus leading to confusion. Champetier et al. considered it advisable to reserve the proper term cystohepatic or cholecyst duct for anomalous intrahepatic bile ducts draining into the gallbladder¹⁸. Cystohepatic ducts are invariably bile ducts of the right hepatic lobe and may serve a subsegment or segment, a sector, or exceptionally the whole of the right hepatic lobe, and drain into the gallbladder¹⁸. Some authors have reported biliary drainage of the right and left hepatic ducts into the gallbladder^{12,16,19,20}. Cystohepatic duct is considered to arise through persistence of fetal connections, either single

or multiple, between the gallbladder and the liver¹¹. There have been a few reports about cystohepatic duct^{9,21}, which is rare biliary anomaly observed in 0.7% of all surgical cases and 1.5% of all cadaveric dissections⁵. Sectorial cystohepatic ducts most often drain the right posterior segment and rarely the right anterior segment¹⁸. However, in the present case, the cystohepatic duct drained the anterior segment (B5), a situation that has been reported only rarely^{18,22}.

Differential diagnosis between accessory bile duct and cystohepatic duct is very important, but may be relatively easy if cholangiography can reveal the location of the Heister valve. Benson has classified biliary anomaly as follows: 1. Long cystic duct showing low fusion with the common bile duct. 2. Abnormal fusion of the right and left hepatic ducts with the cystic duct entering at the confluence. 3. Accessory bile duct. 4. Cystic duct entering the right hepatic duct. 5. Cystohepatic duct⁵.

The Luschka duct is reported to be a structure 1-2 mm in diameter that drains a variably sized subsegment of the posterior segment of the right liver to empty into the right hepatic or common bile duct, or rarely, the cystic duct. McQuillan reported that Luschka ducts were found in 30% of all post-mortem dissections, and that most of them were located fairly centrally within the gallbladder²³. Postoperative complication may occur rarely if a Luschka duct is ligated during surgery. In the present case, intrahepatic bile duct (B5) was thick, being 3 mm in diameter, and was therefore considered to be a cystohepatic duct, different from a Luschka duct. Also, outflow drainage of the gallbladder occurred through the B5 bile duct, suggesting that this anomaly may have been the cause of

gallstone formation. However, as the patient had diabetes mellitus, hypertension, and hyperlipidemia, and had undergone a coronary bypass operation, it seemed more likely that the gallstone had formed because of underlying hyperlipidemia.

Diagnosis of cystohepatic duct

Fortunately, in this case, we were able to diagnose the biliary anomaly preoperatively, and the postoperative course was uneventful. This may have been due to our multidisciplinary diagnostic approach involving ERCP, MRCP, and three-dimensional CT cholangiography.

Some authors have reported that preoperative examination of the biliary tract by spiral computed tomography scanning after intravenous infusion cholangiography is technically simple, less invasive, and may be helpful for avoiding damage to the bile duct, especially in patients with biliary duct anomalies^{24,25}. Kwon et al. reported that three-dimensional CT cholangiography provides images of similar accuracy to ERCP, and significantly superior to those of intravenous cholangiography²⁵. In contrast, ERCP gives a clear image, but is rather invasive and not always successful. Yamamoto et al. have also reported that MRCP is useful for diagnosis of biliary tree anomalies²⁰. In our patient, the intrahepatic bile duct and neck of the gallbladder overlapped in the MRCP, making it slightly difficult to diagnose the biliary anomaly. Three-dimensional CT cholangiography allows observation from various angles and to diagnose cystohepatic duct without confusion due to overlapping effects.

There are occasions when preoperative imaging examinations cannot perform efficient-

ly, for example during emergency surgery for acute cholecystitis or traumatic injury, and some authors have strongly recommended the routine use of intraoperative cholangiography^{2,8,13}. Intraoperative fluoroscopy is of significant help for either avoiding bile duct injuries or discovering them immediately. In the present case, if the cystic duct had been cut and intraoperative cholangiography had been performed through the proximal cut end of the cystic duct, the B5 duct would not have been visualized. Therefore, in order to avoid injury of the cystohepatic duct, it needs to be visualized preoperatively. In other cases, it may be possible to diagnose cystohepatic duct by intraoperative cholangiography via a gallbladder puncture, even if a cystic duct is present.

Surgical procedure for cystohepatic duct

When abnormal ducts are discovered, they should be preserved or anastomosed, unless they are very small accessory ducts²². However, many authors have reported the presence of a thick string between the gallbladder and the liver, and that this can be subsequently divided^{2-4,6,21}. Seibert et al. reported the occurrence of postoperative bile peritonitis due to bile leakage from an aberrant right anterior hepatic duct at reoperation⁴. They anastomosed the aberrant bile duct with the jejunum. Another reported treatment option is insertion of a T-tube into the cut end of the aberrant cystic duct¹⁵. Stokes et al. reported dissection of a cystohepatic duct and its anastomosis to the duodenum over a Y-tube¹⁶. During relaparoscopy, Klotz et al. were able to identify and clip an accessory bile duct in the caudal part of the liver bed². Although conservative therapy with a nasobiliary tube is reportedly effective for bile leakage from a cystohepatic

duct³⁾, the duct was considered too thin.

In the present case, if laparoscopic cholecystectomy had been performed without recognizing the biliary anomaly, the cystic duct would have been initially dissected. Then during dissection of the gallbladder from the liver bed, the thick cystohepatic ducts would have been divided, and thus bile leakage might have occurred from the liver bed. If the cystic duct or cystohepatic ducts had been ligated, drainage of the segmental bile duct (B5), which served a large volume of the liver, would have been interrupted, and could have resulted in complications such as bile leakage, biloma, cholangitis, liver abscess, intrahepatic calculi, or atrophy of segment 5. Because our patient had two thick cystohepatic ducts (B5), it might not have been possible to alleviate bile leakage using a nasobiliary catheter.

Laparoscopic cholecystectomy has been associated with a higher incidence of bile duct injury than conventional open cholecystectomy because of the two-dimensional operative view. Therefore, we recommend conventional open cholecystectomy for patients with cystohepatic duct. The surgical procedure for cystohepatic duct is easy and less invasive by dissect gallbladder side and preserved cystohepatic duct, rather than anastomose of cystohepatic duct and jejunum. If a biliary anomaly exists, initial dissection of the cystic duct is dangerous. We recommend that dissection of the gallbladder should be done from the fundus downward, preserving a thick string. The safest option is to confirm the course of the biliary duct by intraoperative cholangiography from the gallbladder, and then to dissect the gallbladder wall and preserve the cystohepatic duct.

CONCLUSION

We have described a rare case of intrahepatic bile duct flow into the gallbladder (cystohepatic ducts), to which surgeons should be alert during cholecystectomy. When cholecystectomy is scheduled, more than one type of preoperative imaging, including three-dimensional CT cholangiography, MRCP or ERCP should be performed, to ensure that this biliary anomaly is not overlooked. Intraoperative cholangiography from the gallbladder is also useful for the detection of cystohepatic duct.

REFERENCES

1. Tsalis KG, Christoforidis EC, Dimitriadis CA, Kalfadis SC, Botsios DS, Dadoukis JD: Management of bile duct injury during and after laparoscopic cholecystectomy. *Surg Endosc* 2003; 17: 31-37
2. Klotz HP, Schlumpf R, Largiader F: Injury to an accessory bile duct during laparoscopic cholecystectomy. *Surg Laparosc Endosc* 1992; 2: 317-320
3. Edelman DS: Bile leak from the liver bed following laparoscopic cholecystectomy. *Surg Endosc* 1994; 8: 205-207
4. Seibert D, Matulis SR, Griswold F: A rare right hepatic duct anatomical variant discovered after laparoscopic bile duct transection. *Surg Laparosc Endosc* 1996; 6: 61-64
5. Benson EA, Page RE: A practical reappraisal of the anatomy of the extrahepatic bile ducts and arteries. *Br J Surg* 1976; 63: 853-860
6. Goor DA, Ebert PA: Anomalies of the biliary tree. *Arch Surg* 1972; 104: 302-309
7. Mentzer SH: Anomalous bile ducts in man; based on a study of comparative anatomy. *JAMA* 1929; 93: 1273-1277
8. Berci G: Biliary duct anatomy and anomalies: the role of intraoperative cholangi-

- ography during laparoscopic cholecystectomy. *Surg Clin NA* 1992; 72: 1069-1075
9. Flint ER: Anomalies of the right hepatic, cystic, and gastroduodenal arteries, and the bile ducts. *Br J Surg* 1923; 10: 509-519
 10. Johnson EV, Anson BJ: Variations in the formation and vascular relationships of the bile ducts. *Surg Gynecol Obstet* 1952; 94: 669-686
 11. Hayes MA, Golderberg IS, Bishop CL: The developmental basis for bile duct anomalies. *Surg Gynecol Obstet* 1958; 107: 447-456
 12. Kihne MJ, Schenken JR, Moor BJ, Karrer FW: Persistent cholecystohepatic ducts. *Arch Surg* 1980; 115: 972-974
 13. Kullman E, Borch K, Lindström E, Svanvik J, Anderberg B: Value of routine intraoperative cholangiography in detecting aberrant bile ducts and bile duct injuries during laparoscopic cholecystectomy. *Br J Surg* 1996; 83: 171-175
 14. Luschka H: Die anatomie des menschlichen bauches. Tubingen: H. Lauppschen, Buchhandlung, 1863: 255
 15. Foster JH, Wayson EE: Surgical significance of aberrant bile ducts. *Am J Surg* 1962; 104: 14-19
 16. Stokes TL, Old L: Cholecystohepatic duct. *Am J Surg* 1978; 135: 703-705
 17. Reid SH, Cho SR, Shaw CI, Turner MA: Anomalous hepatic duct inserting into cystic duct. *AJR* 1986; 147: 1181-1182
 18. Champetier J, Létoublon C, Alnaasan I, Charvin B: The cysthepatic ducts: surgical implications. *Surg Radiol Anat* 1991; 13: 203-211
 19. Hashimoto M, Ishikawa T, Iizuka T, Matsuda M, Watanabe G: Right hepatic duct emptying into the cystic duct: report of a case. *Surg Endosc* 2002; 16: 359
 20. Yamamoto S, Sakuma A, Rokkaku K, Nemoto T, Kubota K: Anomalous connection of the right hepatic duct into the cystic duct: utility of magnetic resonance cholangiopancreatography. *Hepatogastroenterology* 2003; 50: 643-644
 21. Neuhoff H, Bloomfield S: The surgical significance of an anomalous cholecystohepatic duct. *Ann Surg* 1945; 122: 260-265
 22. Williams C, Williams AM: Abnormalities of the bile ducts. *Ann Surg* 1955; 141: 598-605
 23. McQuillan T, Manolas SG, Hayman JA, Kune GA: Surgical significance of the bile duct of Luschka. *Br J Surg* 1989; 76: 696-698
 24. Kwon AH, Uetsji S, Ogura T, Kamiyama Y: Spiral computed tomography scanning after intravenous infusion cholangiography for biliary duct anomalies. *Am J Surg* 1997; 174: 396-402
 25. Toyoda H, Hayakawa K, Kikkawa M, Fukushima H, Kataoka M, Mukaihara S, et al.: Usefulness of three-dimensional CT cholangiography for patients prior to laparoscopic cholecystectomy. *Radiat Med* 2000; 18: 161-166