

University of Arkansas, Fayetteville  
**ScholarWorks@UARK**

---

Theses and Dissertations

---


5-2013

# Efficacy of Probiotics for Reducing the Incidence of Lameness in Broilers Grown on Wire Flooring

John Matthew Stark

*University of Arkansas, Fayetteville*

Follow this and additional works at: <http://scholarworks.uark.edu/etd>

 Part of the [Animal Diseases Commons](#), and the [Poultry or Avian Science Commons](#)

---

## Recommended Citation

Stark, John Matthew, "Efficacy of Probiotics for Reducing the Incidence of Lameness in Broilers Grown on Wire Flooring" (2013).  
*Theses and Dissertations*. 669.

<http://scholarworks.uark.edu/etd/669>

This Thesis is brought to you for free and open access by ScholarWorks@UARK. It has been accepted for inclusion in Theses and Dissertations by an authorized administrator of ScholarWorks@UARK. For more information, please contact [scholar@uark.edu](mailto:scholar@uark.edu), [ccmiddle@uark.edu](mailto:ccmiddle@uark.edu).



EFFICACY OF PROBIOTICS FOR REDUCING THE INCIDENCE OF LAMENESS IN  
BROILERS GROWN ON WIRE FLOORING

EFFICACY OF PROBIOTICS FOR REDUCING THE INCIDENCE OF LAMENESS IN  
BROILERS GROWN ON WIRE FLOORING

A thesis submitted in partial fulfillment  
of the requirements for the degree of  
Master of Science in Poultry Science

By

John Matthew Stark  
University of Arkansas  
Bachelor of Science in Poultry Science, 2008

May 2013  
University of Arkansas

## Abstract

Growing broilers on wire flooring provides an excellent experimental model for reproducibly triggering significant levels of lameness. In Pilot Study #1 using broilers from Line C grown on wire flooring, adding the Biomin probiotic PoultryStar® to the feed reduced the percentage of lameness by half when compared with broilers that received the control diet alone. In Pilot Study # 2 using broilers from Line B grown on wire flooring, adding the PoultryStar® probiotic reduced the percentage of lameness to 8% when compared with 28% lameness in broilers that received the control diet alone. The objective of this study was to conduct a replicated experiment to determine if probiotics consistently reduced the incidence of lameness in broilers reared on wire flooring. Male broiler chicks from Cobb-Vantress Line B were placed at 1 day of age in pens having flat wire flooring within environmental chambers 1 through 10 inside the Poultry Environmental Research Lab at the University of Arkansas Poultry Research Farm. On day 14, birds were culled to 50 per pen, yielding a density of 1ft<sup>2</sup>/chick. A corn and soybean meal-based diet formulated to meet minimum National Research Council standards (1994) for all ingredients was provided *ad libitum* as the control feed. Broilers in chambers 1, 3, 5, 7 and 9 were provided the control feed while chambers 2, 4, 6, 8 and 10 were provided the same feed mixed with the probiotic throughout the experiment (50 lbs of control feed blended with 12.5 g PoultryStar® probiotic). The birds in all pens were “walked” and observed for lameness every two days starting on day 15 and continuing until the end of the experiment on day 56. Birds unable or unwilling to walk were diagnosed as “clinically lame” and humanely euthanized with CO<sub>2</sub> gas. They were then necropsied to assess sub-clinical lesion incidences including femoral head separation, femoral head transitional degeneration, femoral head necrosis, tibial head necrosis, and tibial dyschondroplasia. Findings from the study indicate that

for broilers grown on wire flooring, diets containing the probiotic PoultryStar® consistently reduced the incidence of lameness when compared with birds fed the control diet alone.

This thesis is approved for recommendation  
to the Graduate Council.

Thesis Director:

---

Dr. Robert F. Wideman Jr.

Thesis Committee:

---

Dr. Nicholas B. Anthony

---

Dr. Dan J. Donoghue

**Thesis Duplication Release**

I hereby authorize the University of Arkansas Libraries to duplicate this thesis when needed for research and/or scholarship.

Agreed

---

John Matthew Stark

Refused

---

John Matthew Stark



## **Acknowledgements**

I would like to thank Dr. Robert F. Wideman Jr., my thesis advisor, for his continued support and patience throughout my research and the preparation of this document. In addition, I want to thank committee members Dr. Nicholas B. Anthony and Dr. Dan J. Donoghue for their advice and encouragement on my thesis preparation and for serving on my thesis defense committee. I would also like to thank BIOMIN Holding GmbH, Herzogenburg, Austria, and Cobb-Vantress Incorporated, Siloam Springs, Arkansas, for their supporting grants that made this project possible.

## Table of Contents

<b>Introduction</b>	1
<b>Literature Review</b>	5
Lameness in Broilers Attributable to Bacterial Chondronecrosis with Osteomyelitis	5
Etiology of BCO	6
Growth Plate Development for the Femur and Tibiotarsus	7
Route of Blood-flow to Growth Plate in BCO	8
Impact of Flooring Type on Lameness in Broilers	9
Previous Studies on BCO	10
Potential Routes of Bacterial Translocation	11
Role of Probiotics	12
Selection of Probiotics for Poultry	13
Hypothesis	15
<b>Materials and Methods</b>	16
<b>Results</b>	19
Appendix A: Clinical Lameness Diagnostic Sequence	23
Figure 2—Lameness per Environmental Chamber or Diet Treatment	24
Figure 3—Diagnosis Categories for Clinically Lam Broilers	25
Figure 4—Left vs. Right Leg Comparisons for Clinically Lam Broilers	26
Figure 5—Body Weights of Survivors on Day 56	27
Figure 6—Diagnostic Categories for Survivors on Day 56	28
Figure 7—Left vs. Right Leg Comparisons for Survivors on Day 56	29
Figure 8—Same Leg Femur vs. Tibia Correlations for Day 56 Survivors	30
Figure 9—Diagnosis Categories for Clinically Lam vs. Survivors	31
<b>Discussion</b>	32
<b>Works Cited</b>	40

## **Introduction**

Broiler lameness is an area of major concern to the poultry industry and merits extensive research with regard to its etiology and the subsequent association between skeletal abnormalities and leg disorders (Skinner-Noble and Teeter, 2009). Estimated financial losses due to skeletal abnormalities cost the broiler industry approximately \$120 million per year, or \$ 0.16 per broiler raised in the U.S. (Cook, 2000). Bacterial chondronecrosis with osteomyelitis (BCO), formerly known as ‘femoral head necrosis’, is a disease of fast growing poultry that frequently is diagnosed in the proximal end of the femur. BCO has been recognized as one of the most important causes of leg weakness and mortality in broiler chickens for many years (McNamee et al., 1999). The term BCO encompasses necrotic degeneration and microbial infection occurring primarily within the proximal head (articular cartilage or epiphysis, growth plate or physis, and metaphysis) of the femur and tibiotarsus, with the caveat that other rapidly growing bones, including the vertebrae, also may be affected (e.g., spondylopathy or spondylitis) (Wideman et al., 2012). Broilers typically become lame with BCO late in their grow-out period, most commonly after 30 days of age, and thus their value is lost after significant economic input (McNamee and Smyth, 2000; Butterworth et al., 2001). BCO was first reported as a cause of lameness in broilers in Australia (Nairn and Watson, 1972) and has since been recognized as a major problem in broiler flocks in other countries including the United States, Canada, and Europe (McNamee and Smyth, 2000).

In a survey of broiler chickens in Northern Ireland, the most predominant cause of lameness was attributed to the development of BCO of the femur and tibio-tarsus that was associated with *Staphylococcus aureus* (McNamee et al., 1998; Rodgers et al., 2006).

*Staphylococcus aureus* is considered one of the most prominent bacterial pathogens of man and

animals with a particular propensity to infect tissues of the musculoskeletal system, and is considered the leading cause of osteomyelitis (Smeltzer and Gillasp, 2000). While BCO lesions have repeatedly included *Staphylococcus aureus* as the most common source of bacterial infection, other bacteria also have been isolated from BCO lesions, including but not limited to: *Escherichia coli*, coagulase negative staphylococci, and *Enterococcus spp.* (McNamee and Smyth, 2000). BCO lesions may only be visible to the naked eye in 40 to 67% of cases, so it is almost certainly underdiagnosed as a cause of lameness since histological examination is rarely carried out in field studies of broiler lameness (McNamee and Smyth, 2000).

Today's broilers are routinely subjected to the stresses of fast growth, rapid weight gain, and environmental challenges due to their housing and management, all of which can contribute to the incidence of skeletal diseases in broiler fowl (El Boushy, 1974; Thorp, 1994), especially in rapidly growing males (Santora et al., 2001; Julian, 2005). A common cause of lameness in these rapidly growing birds is the separation of the articular cartilage from the growth plate. This epiphyseal separation (epiphyseolysis, femoral head separation) can potentially lead to infection (Thorp et al., 1993; Thorp, 1994; Julian, 1998; Julian, 2005; Durairaj et al., 2009). Infection also develops in response to pressure-induced micro-fractures at the physis and diaphysis of the proximal femur and tibia (physeal osteochondrosis). These micro-fractures form due to the imposition of excessive torque and shear stress on the structurally immature cartilaginous growth plates of the proximal leg bones (Julian, 2005; Wideman et al., 2012). The growth plates contain chondrocytic lacunae in which thin walled metaphyseal blood vessels expand and form small vascular saccules. These micro-vascular saccules are highly permeable and permit blood-borne bacteria to escape through discontinuities (openings or fenestrations) at the tips of the metaphyseal vessels. The accumulation of bacteria within this region clearly can promote the

establishment of a bacterial infection in the growth plate, particularly in the event of sluggish circulation (Trueta, 1959; Howlett, 1980; Thorp et al., 1993; McNamee and Smyth, 2000). Heterophils have been documented in the extravascular spaces surrounding these sacculles suggesting that gaps in the growth plate can potentially harbor bacteria in direct contact with the physal cartilage matrix (Howlett, 1980; Howlett et al., 1984; McNamee and Smyth, 2000). Bacterial foci can develop at sites where the physal vasculature becomes occluded by micro-thrombi and in small fractures and clefts that commonly develop in the femoral and tibial cartilage due to stress and torque (Thorp, 1988; Bradshaw et al., 2002). Bacterial translocation into the circulatory system could potentially occur through the epithelial barriers of the respiratory system and/or the gastrointestinal tract, initiating a bacterial infection such as BCO. The micro-fracturing induced on the epiphyseal-physal cartilage due to the mechanical torque and shear stress on broiler leg joints facilitates colonization by blood-borne bacteria translocated from the respiratory and gastrointestinal tracts (Wideman et al., 2012).

One of the major causes of the stress and torque placed on the legs of broilers is the type of flooring on which they are reared. When a bird walks, pressure on the floor is generated which is a function of body weight, balance, and the way a bird places its footing on the flooring surface (Nääs et al., 2009). When the bird's footing is unstable, the distribution of the body weight and balance are upset. This imbalance can cause excess shear and torque upon susceptible leg joints. In a study highlighting the performance of broilers grown on litter with those grown on a variety of raised flooring systems, Andrews et al. (1990) found that the body weights for broilers grown on raised flooring were either superior to or not significantly different from the body weights of broilers grown on conventional litter flooring. In a separate study, Andrews et al. (1974) found that broilers reared on wire and litter flooring had a lower incidence

of leg abnormalities than birds raised on a plastic mat flooring. When leg abnormalities have been observed in birds reared in cages with wire flooring, the incidence of lameness was attributed to a lack of exercise and locomotion, as highlighted in a review by Bradshaw et al., (2002). Wideman et al. (2012) were able to trigger high incidences of BCO in broiler flocks over a span of five experiments by rearing the birds at relatively low densities in raised wire flooring pens large enough to permit normal levels of exercise and locomotion, thus proving that BCO can be triggered when broilers were able to walk and exercise.

Rearing broilers on raised wire flooring can significantly increase the torque and stress imposed upon the leg bones, thereby increasing the subclinical damage to the proximal growth plates of the femora and tibiae. The resulting formation of micro-fractures and cartilage clefts need not progress to clinical BCO unless bacterial translocation, infection and proliferation ensue. Broilers may develop BCO when bacteria enter the bloodstream from the gastrointestinal tract and are translocated to torque- and stress-induced micro-fractures, voids and clefts in the growth plates of rapidly elongating leg bones. McNamee and Smyth (2000) highlighted in their review of BCO in poultry that preliminary studies of bacterial interference to control staphylococcal infections proved successful in chickens. The mechanism of bacterial interference, such as with the use of probiotics, is thought to be a function of competition by the interfering bacterium for the same tissue receptor sites as the secretion of a bacteriocin that is the bactericidal for *Staphylococcus aureus* (McNamee and Smyth, 2000). It is our hypothesis that pre-treating chicks with an effective probiotic should reduce bacterial translocation from the gastrointestinal tract and thereby reduce the incidence of BCO in broilers reared on wire flooring.

## **Literature Review**

### **Lameness in Broilers Attributable to Bacterial Chondronecrosis with Osteomyelitis (BCO)**

Leg abnormalities resulting in lameness, also known as leg weakness, are considered among the most severe welfare problems in modern broiler production (Weeks et al., 2000). Talaty et al. (2009) highlighted a national survey of broiler companies indicating that broiler flocks experience 1.1% mortality due to leg problems with an additional 2.1% of the birds being condemned or downgraded at processing as a result of leg abnormalities. Estimated financial losses due to skeletal abnormalities cost the broiler industry approximately \$120 million per year, or \$ 0.16 per broiler raised in the U.S. (Cook, 2000). When adjusted for inflation, the economic losses can be estimated at approximately \$160 million per year in 2012 dollars. Leg abnormalities are influenced by various factors including growth rates, genetics, environmental conditions, management, nutrition, locomotive activity, toxins, age, and infectious diseases (Rath et al., 2000; Talaty et al., 2009). One of the most prominent causes of leg disorders resulting in lameness in commercial broilers aged between 34 and 70 days is known as bacterial chondronecrosis with osteomyelitis (BCO), which primarily is associated with lesions in the proximal end of the femur and tibiotarsus (Thorp et al., 1993; McNamee et al., 1999). Wideman et al. (2012) emphasized that the term BCO encompasses the necrotic degeneration and microbial infection that occurs primarily within the proximal heads (articular cartilage or epiphysis, growth plate or physis, and metaphysis) of the femur and tibiotarsus, with the caveat that other rapidly growing bones including the vertebrae may also be affected (e.g., spondylopathy or spondylitis). BCO has been documented as a cause of lameness in commercial broilers since 1972 (Nairn and Watson, 1972) and has been recognized as a major problem in broiler flocks in Australia, the United States, Canada, and Europe (Thorp et al., 1993; McNamee

et al., 1999; McNamee and Smyth, 2000). Macroscopically, BCO has been described as focal areas of caseous exudate or lytic areas, which cause affected bones to be fragile. Lesions observed during experimental investigations varied from a small pale area adjacent to the growth plate to a large zone of yellow necrotic tissue extending from the growth plate to the medullary cavity (Skeeles 1997; McNamee et al., 1999; McNamee and Smyth, 2000). From a diagnostic perspective, bone histology is not routinely applied, thus the incidence of BCO is likely highly underestimated when only macroscopic (direct visual) examination is used to assess the prevalence of the condition (McNamee et al., 1998; McNamee and Smyth, 2000). Several opportunistic pathogens have been isolated from BCO lesions. *Staphylococcus aureus* appears repeatedly as the most common cause of bacterial infection although other bacteria also have been isolated from BCO lesions including but not limited to *Escherichia coli*, coagulase-negative staphylococci and *Enterococcus spp.* (McNamee and Smyth, 2000).

### **Etiology of BCO**

The exact pathogenesis of BCO remains unknown; however, there are many theories as to the primary cause of its development (McNamee and Smyth, 2000). Young broilers subjected to fast growth, rapid weight gain, and stress due to their housing and management are more susceptible to skeletal diseases (El Boushy, 1974; Thorp, 1994). Among the previously stated non-infectious causes of lameness and leg disorders, the most common cause can be attributed to rapid growth rates, particularly in the case of rapidly growing males (Santora et al., 2001; Julian, 2005). Julian (2005) emphasized that the bones of rapidly growing broilers may not develop sufficient strength to support their weight toward the end of grow-out. It is common for these lame broilers to use a wing tip for support during locomotion and during hip flexion on the ipsilateral side of a leg disorder, while loudly vocalizing when pressure is placed on the affected



side (Thorp et al., 1993). Separation of the articular cartilage from the growth plate in these rapidly growing birds is a common cause in lameness, and epiphyseal separation (epiphyseolysis, femoral head separation) can lead to infection (Thorp et al., 1993; Thorp, 1994; Julian, 1998; Julian, 2005; Durairaj et al., 2009). Infection also develops when pressure-induced micro-fractures occur in the physis and diaphysis of the proximal femur and tibia. Bacterial infection ensues in this case leading to pain and discomfort when heavy broilers stand and walk (Julian, 2005). McNamee and Smyth (2000) reviewed the etiology of the development of BCO. Based on a study initially performed by Nairn and Watson (1972), *Staphylococcus aureus* and/or *Escherichia coli* were injected intravenously into turkeys and produced osteomyelitis within the terminal vessels of the growth plate. This suggested that osteomyelitis was caused by the spread of bacteria from small foci of infection in the growing ends of metaphyseal blood vessels within the hypertrophic region of the cartilaginous growth plate (Emslie and Nade, 1983; Aldersen et al., 1986; McNamee and Smyth, 2000).

### **Growth Plate Development for the Femur and Tibiotarsus**

The growth plates are responsible for lengthening the long bones such as the femur and tibiotarsus in poultry. Once established, these cartilaginous growth plates tend to be maintained at a constant thickness: growth and proliferation of cells in the proliferating zones is followed by resorption accompanied by the ingrowth of metaphyseal blood vessels and associated undifferentiated mesenchymal cells. Regularly spaced metaphyseal vascular complexes penetrate beyond the level of dense matriceal calcification. This allows columns of cartilage to extend into the metaphysis and act as scaffolding for initial bone formation (Howlett, 1980). Rapidly growing poultry are subjected to an increased risk of failures of bone development and maturation as processes that normally strengthen the leg bones can fail to maintain pace with the

modern bird's overall rate of body weight gained. The result is that excess physical load is generated on immature bones, predisposing them to deformity and fragility (Rath et al., 2000). Structural elements greatly contribute to the maturation and strength of bone; however, the normal deposition of these elements can be affected under adverse conditions including stress, infections, and inflammation that are risk factors for reduced bone integrity and bone weakness (Rath et al., 2000).

### **Route of Blood-flow to Growth Plate in BCO**

The femoral head is particularly vulnerable to osteomyelitis whenever circulation in the metaphyseal vessels becomes sluggish due to a bird's immobility. Bacteria also may become deposited at site of pre-existing pathologies. This includes sites where the physeal vasculature becomes occluded by micro-thrombi and in small fractures and clefts that commonly develop in the femoral and tibial cartilage due to stress and torque (Thorp, 1988; Bradshaw et al., 2002). The growth plates contain chondrocytic lacunae and the thin walled metaphyseal blood vessels expand into the lacunae, forming small vascular saccules. The presence of heterophils has been documented in the extravascular spaces surrounding these saccules, thus suggesting that clefts in the growth plate can harbor bacteria in direct contact with the physeal cartilage matrix (Howlett, 1980; Howlett et al., 1984; McNamee and Smyth, 2000). Howlett (1980) documented that metaphyseal capillaries occasionally rupture, allowing blood elements to pour out into degenerating chondrocytic lacunae. Nevertheless, most blood-borne cellular elements can escape from the blood through discontinuities (openings or fenestrations) in the advancing tips of metaphyseal capillaries. These openings in the endothelial layer could allow any sluggish circulation at the tips of the long narrow metaphyseal vessels of the growth plate to facilitate the

accumulation of bacteria and thus promote the establishment of a bacterial infection (Trueta, 1959; Thorp et al., 1993; McNamee and Smyth, 2000).

### **Impact of Flooring Type on Lameness in Broilers**

One of the major influences that should be considered in assessing lameness of broilers is the type of flooring on which the birds are reared. Factors including litter scarcity and increased cost have the poultry industry looking for alternatives to the conventional litter flooring for broiler grow-out. Raised flooring, such as that used in the present study, can allow for the manure to pass through the flooring and away from the birds. Separating the birds from their feces reduces the broilers' direct contact with microorganisms found within the feces and provides a litter free system for the grow-out period. Andrews et al. (1990) highlighted several previous studies in which the performance of broilers grown on litter was compared with broilers grown on a wide variety of raised floorings both in cages and in floor pens. In all of these studies, the body weights for broilers grown on raised flooring were either superior or not significantly different from the body weights of broilers grown on a conventional litter flooring system. While the type of flooring system had no negative impact on body weights, the main impact of flooring type was on the leg bones' strength. There have been very few studies showing a consistent incidence of leg abnormalities in broilers reared on wire flooring. Andrews et al. (1974) found that broilers reared on wire and litter flooring had a lower incidence of leg abnormalities when compared with a high plastic mat flooring material. When leg abnormalities have been observed in birds reared in cages with wire flooring, the lameness has been attributed to a lack of locomotion and exercise. Bradshaw et al. (2002) noted that past studies of broilers housed in cages where exercise is restricted show a high incidence of skeletal disorders attributable to 'twisted leg' or 'slipped tendons' (also known as perosis) when compared with

group-housed birds with a litter floor. Similarly, Andrews and Goodwin (1973) attributed previously reported differences in tibial breaking strength between cage and floor-reared birds to a lack of exercise in birds reared in cages. When a bird walks, pressure on the floor is generated which is a function of body weight and balance and is an indication of the way the bird places its footing on a particular surface (Nääs et al., 2009). When the bird's flooring is unstable, the distribution of the body weight and balance are upset, causing excess shear and torque upon susceptible leg joints. Wideman et al. (2012) were able to successfully upset this balance and weight distribution by creating a raised wire flooring model. The wire flooring model reproducibly triggered significant levels of lameness and BCO in birds beginning approximately at 4-5 weeks of age. Presumably the mechanical micro-trauma to the epiphyseal cartilage caused by footing instability produces niches and clefts in the damaged cartilage, thereby facilitating colonization by blood-borne bacteria and resulting in the development of BCO.

### **Previous Studies on the Etiology of BCO**

Previous attempts to evaluate the etiology of BCO have been performed within broiler flocks; however, in most cases, the birds have been injected intravenously with bacteria in an attempt to induce infection within the femoral and tibial joints. Emslie and Nade (1983) injected 30 chickens intravenously at 29 days of age with *Staphylococcus aureus* in an attempt to induce abscess formation in the growth plates of the long bones. Histologic observations were restricted to the development of abscesses in the proximal tibia and distal femur of the left leg. In their study, birds were necropsied at 6, 12, 24, 48, 96 and 192 hour intervals after the bacterial injection. Birds necropsied 24 hours or more after bacterial injection exhibited osteomyelitis (infection of the bone). In birds that were necropsied less than 24 hours post-inoculation, microscopic examination revealed osteomyelitic foci at the end of the metaphyseal tunnels

within the hypertrophic zone of cartilage formation in the growth plate. The histologic examination of the experimental abscesses confirmed that bacteria were deposited initially within the metaphyseal vessels, which are the terminal branches of the nutrient artery and supply the zone of cartilage transformation in the growth plate.

### **Potential Routes of Bacterial Translocation**

While Emslie and Nade (1983) provided details of how the bacteria were able to successfully colonize the growth plate of broilers, they failed to show how bacterial translocation occurs under normal commercial growing conditions since their experimental protocol involved inoculating the birds intravenously with bacteria. Dinev (2009) highlighted a report by Riddell (1997) stating that *Staphylococcus spp.* was the most common bacterium isolated from arthritis/tendonitis/osteomyelitis in broilers from west Canada. He went on to note an additional increase in the presence of musculoskeletal infection associated with *Escherichia coli*. With these bacteria being the common microbial determinants in leg disorders, theories regarding the probable routes of infection have been proposed in several previous reports. Staphylococci are normal inhabitants of the skin and upper respiratory tract such as the nares and mouth of healthy birds (Zhu et al., 1999). With this bacterial pathogen being commonly seen in broilers, routes of entry must be available for the pathogen to cause an infection leading to an occurrence of BCO. There are three proposed routes to which the bacterium could enter the circulatory system and thus cause disease within the broiler. One route proposed by McNamee and Smyth (2000), was based on an earlier study (Smith, 1954), in which a bacterial infection was thought to be associated with conditions in which wounding, particularly of the feet, was likely to occur. This would be considered an obvious route of entry since *Staphylococcus aureus* is normally found on the skin surface of broilers. While this is a plausible theory, it is likely not the most prominent

route for bacterial translocation for a large population of broilers. Another portal for bacterial infections in poultry could be through the epithelial barrier of the respiratory tract. Respiratory exposure is considered a major route of entry for staphylococcus, as poor air quality and/or “hot” respiratory vaccines can facilitate staphylococcal entry (Jensen and Miller, 2001). A third possible route for bacterial entry into the circulatory system is through the gut wall via gastrointestinal leakage. Jensen and Miller (2001) state that it is plausible for staphylococcal organisms to enter the blood stream through the intestinal blood vessels if the protective lining of the intestine were to be damaged as could occur during an outbreak of coccidiosis. This is why effective control of coccidiosis is considered essential for reducing the possibility of systemic bacterial infection (Jensen and Miller, 2001).

### **Role of Probiotics**

In a review describing the role of probiotics in the poultry industry, Kabir (2009) summarized the mechanism of action of probiotics in poultry to include: (i) maintaining normal intestinal microflora by competitive exclusion and antagonism; (ii) altering metabolism by increasing digestive enzyme activity and decreasing bacterial enzyme activity and ammonia production; (iii) improving feed intake and digestion; and (iv) stimulating the immune system of the bird. Since the 1950's, antimicrobial agents have been used in animals at subtherapeutic concentrations in feed additives as a means of promoting growth and ostensibly by reducing the risk of bacterial infections of animals bred for human consumption (Hamer, 2002). Although the full impact on humans is unknown, several studies over the past decades have shown that this practice results in low-level exposure to antimicrobials in people who consume animal products, and their use in animals appears to be an important contributing factor in the development of antibiotic-resistant bacterial pathogens harmful to humans (Hamer, 2002). In 1994, the World

Health Organization deemed probiotics to be the next-most important line of defense after commonly prescribed antibiotics are rendered useless by antibiotic resistance (Drisko et al., 2003). With the increased scrutiny regarding the use of antimicrobial agents in food animals in today's agricultural market, the use of probiotics as a means of prevention and treatment of disease is a logical choice that must be evaluated in veterinary medicine for future use (Weese, 2002). Although a number of definitions have been proposed to describe probiotics, an appropriate definition was suggested by the earlier work of Havenaar et al. (1992), who defined probiotics as "mono or mixed cultures of live microorganisms which, when applied to animal or man, beneficially affect the host by improving the properties of the indigenous microflora" (Holzapfel et al., 1998). The normal microflora of the intestinal tract of poultry consists of a diverse population of bacteria which are in a competition for survival as they compete for various attachment sites and nutrients from ingesta passing through the intestine (Jeffery, 1999). Microbial populations within the gastrointestinal tract of poultry can colonize very quickly after hatching (O'Dea et al., 2006). It is during this early time period when a stable gut microflora is most needed because the chick is most vulnerable to colonization by undesirable pathogens (O'Dea et al., 2006). Probiotics may play a significant role in gut microflora health by having the potential to reduce plasma concentrations of bacterial endotoxins, at least in part by inhibiting translocation of bacteria across the gastrointestinal wall into the bloodstream (Vanderhoof, 2001; Drisko et al., 2003).

### **Selection of Probiotics for Poultry**

Kabir (2009) reviewed the earliest investigations of the use of probiotics in poultry, including the pioneering work of Nurmi and Rantala (1973) who implied that naturally occurring intestinal microorganisms from adult chickens that were resistant to *Salmonella* might be used in

very low challenge oral doses into the crop of 1 week old chicks to achieve adult-type resistance to *Salmonella*. While Nurmi and Rantala (1973) achieved the first successful “competitive exclusion”, as it became to be known, they did not demonstrate a practical method for distribution of their bacterial interference to flocks of thousands of birds. Over time, methods were developed for administering probiotic supplements in animal feed including pellets, capsules, pastes, powders and granules (Fuller, 1989). There are many perceived desirable traits for the selection of functional probiotics, including: (i) probiotics must be normal inhabitants of the gut; (ii) probiotics must be able to adhere to the intestinal epithelium and overcome potential hurdles such as low pH in the stomach and the presence of bile acids in the intestine; and, (iii) probiotics must be able to successfully compete with other micro-organisms in the gastrointestinal tract (Kabir, 2009). A variety of microbial species have been used as probiotics, including the species of *Bacillus*, *Bifidobacterium*, *Enterococcus*, *E. coli*, *Lactobacillus*, *Lactococcus*, *Streptococcus*, a variety of yeast species, and undefined mixed cultures (Patterson and Burkholder, 2003). The most common probiotics for monogastric animals, such as pigs and poultry, are yeasts (*Saccharomyces boulardii*), and bacteria (*Lactobacillus* spp., *Enterococcus* spp., *Pediococcus* spp., *Bacillus* spp.) targeting the hindgut where an abundant and very diverse microbial population resides, mainly composed of bacteria and archaea (Chaucheyras-Durand and Durand, 2010).



## **Hypothesis**

Rearing broilers on wire flooring significantly increases the torque and stress imposed upon the leg bones, thereby increasing the subclinical damage to the proximal growth plates of the femora and tibiae. The resulting formation of micro-fractures and cartilage clefts need not progress to clinical lameness unless bacterial infection and proliferation ensue. Broilers develop lameness attributable to BCO when bacteria are translocated from the gastrointestinal tract into the systemic circulation, thereby causing the infection of torque- and stress-induced micro-fractures, voids and clefts in the growth plates of rapidly elongating leg bones. It is our hypothesis that pre-treating chicks with an effective probiotic should reduce bacterial translocation from the gastrointestinal tract and thereby reduce the incidence of BCO in broilers reared on wire flooring.

## Materials and Methods

A replicated experiment was conducted to determine if the Biomin Probiotic PoultryStar® could consistently reduce the incidence of lameness in broilers reared on flat wire flooring. Male broiler chicks from Cobb-Vantress Line B were placed at 1 day of age in pens (5 x 10 feet) containing flat wire flooring within environmental chambers 1 through 10 (dimensions: 3.7 m long x 2.5 m wide x 2.5 m high) inside the Poultry Environmental Research Lab at the University of Arkansas Poultry Research Farm (**Figure 1**). The environmental chambers utilized single-pass ventilation at a constant rate of 6 m<sup>3</sup> per minute per chamber. Initially the chicks were placed at 90 per pen, and on day 14 of the experiment, the birds were culled down to 50 per pen in order to provide a density of 1 ft<sup>2</sup> per chick. The photoperiod was set for 23 hours of light and 1 hour of darkness for the duration of the experiment. Thermoneutral temperatures were maintained throughout: 32°C for days 1 to 3, 31°C for days 4 to 6, 29°C for days 7 to 10, 26°C for days 11 to 14, and 24°C thereafter. Two tube-type feeders were positioned at the front of the pen and one row of nipple waterers was positioned at the back of the pen, thus forcing the chicks to travel the length of the floor to eat and drink (**Figure 1**). A corn and soybean meal-based diet formulated to meet minimum National Research Council standards (1994) for all ingredients was provided *ad libitum* as the control feed. Broilers in environmental chambers 1, 3, 5, 7, and 9 were provided the control feed throughout the experiment. Broilers in chambers 2, 4, 6, 8, and 10 were provided the same feed mixed with the Biomin probiotic beginning on day 1 and continuing throughout the experiment (50 lbs of control feed mixed with 12.5 g Biomin probiotic PoultryStar®). The PoultryStar® probiotic is a proprietary blend of dried *Enterococcus faecium*, *Bifidobacterium animalis*, *Pediococcus acidilactici*, and *Lactobacillus reuteri* fermentation products.

Beginning on day 15 and continuing until the conclusion of the experiment on day 56, all birds in each pen were walked every two days to look for symptoms of lameness. Birds exhibiting an obvious limp in their gait while dipping one or both wings and/or birds that had difficulty in standing were diagnosed as being clinically lame and were humanely euthanized with CO<sub>2</sub> gas. All birds that died or developed clinical lameness were recorded by chamber number and the date on which they were removed from the experiment. The birds were then necropsied to assess sub-clinical lesion incidences. Necropsies were performed within 30 minutes of euthanasia in order to minimize post mortem induction of epiphyseolysis. Based on necropsy observations, birds were assigned to one of the following categories: Normal = femur head and proximal tibia head appear entirely normal; Cull = runts and individuals that failed to thrive or appeared to be clinically ill; U = unknown cause of death; NE = necrotic enteritis; SDS = sudden death syndrome (flipover, heart attacks); PHS = pulmonary hypertension syndrome, ascites; KB = kinky back (spondylolisthesis); TW = twisted leg or slipped tendon (perosis); TD = tibial dyschondroplasia; Lam-Und = lameness for undetermined reasons; FHS = proximal femoral head separation (epiphyseolysis); FHT = proximal femoral head transitional degeneration; FHN = proximal femoral head necrosis; THN = tibial head necrosis; and, Total Lam = KB + TW + UNK + TD + FHS + FHT + FHN + THN. On days 56 and 57, the birds remaining in all chambers were weighed, euthanized and necropsied to assess sub-clinical lesion incidences. Lameness incidences or proportion were compared using Z-tests (Sigma-Stat), using the individual bird or leg as the experimental unit (n = number of birds or number of legs evaluated).



**Figure 1.** Pens constructed with flat wire flooring and placed within ten environmental chambers (dimensions: 3.7 m long x 2.5 m wide x 2.5 m high) at the University of Arkansas Poultry Research Farm. Feeders were placed at the front of the pen and a nipple watering system was placed at the back of the pen forcing the birds to travel the length of the pen to eat and drink. This experimental model reproducibly triggers significant levels of lameness attributable to BCO.

## Results

When the cumulative data for clinical lameness observed from days 15 through 56 were evaluated for the individual environmental chambers (**Figure 2**), some variability was observed within each diet treatment (Control feed = odd-numbered chambers; Biomin feed = even-numbered chambers). Although variability was noted, no statistical difference was found in the incidence of lameness within each respective treatment (e.g. comparing Control chamber 1 = 44% vs. Control chamber 7 = 20%:  $P = 0.089$ ; Biomin chamber 2 = 24% vs. Biomin chamber 10 = 10%:  $P = 0.173$ ). Nonetheless, the difference in clinical lameness between the diet treatments (chambers pooled) was highly significant ( $P = 0.001$ ) (**Figure 2**). Broilers that were given the probiotic feed developed approximately two-thirds the overall incidence of lameness when compared with broilers fed the Control diet alone (19.6% vs. 33.2%, respectively).

The diagnoses for the development of clinical lameness of birds from day 15 to day 56 are shown according to their particular diet treatments in **Figure 3**. Using the diagnostic hierarchy shown in **Appendix A**, clinically lame birds that did not have an obvious cause for their lameness such as Twisted Leg or Spondylolisthesis would be euthanized and have their femoral heads evaluated for further observation. A bird could only be assigned a diagnosis of THN as the reason for lameness when obvious lesions of the proximal femoral head (FHS, FHT, and FHN) were not present. If a clinically lame bird was to exhibit both a femoral head lesion and tibial head lesion, then the femoral head lesion was given priority for the underlying diagnosis. The most prevalent diagnoses for lame birds were THN, FHN, and FHS. Incidences of spondylolisthesis, FHT, and FHN did not differ significantly between the diet treatments ( $P = 0.137, 0.280, \text{ and } 0.592$ , respectively); however, the percentage of clinically lame birds

diagnosed as having THN did differ significantly between the Control and Biomin diet treatments ( $P = 0.008$ ; Z-test).

All birds succumbing to clinical lameness through day 56 were necropsied in order to evaluate the incidence of macroscopic lesions in the proximal femoral and tibial heads of both legs to see if any correlation occurred that would make one leg more susceptible than the other to developing lesions. **Figure 4** illustrates the incidences of all lesions that were observed in both legs of clinically lame birds from both diet treatments, for a combined total of 244 left and right legs in the comparison. When pooled by diagnostic category independent of diet treatment group, no tendencies were revealed for lesions to form preferentially in either the left or right leg ( $P \geq 0.602$ ; Z-test). Differences in the percentages of FHS, FHT, FHN, and THN illustrated in **Figures 3** and **4** reflect differences between the hierarchically dominant lesion to which clinical lameness was attributed (**Figure 3, Appendix A**) versus all of the lesions that were detected in all of the proximal femoral and tibial heads upon necropsy (**Figure 4**). For instance, if a broiler had FHS in one femur, FHN in the second femur, and THN in one tibia, then a diagnosis of 'FHN' would have been recorded as the reason for clinical lameness in **Figure 3**, but all three lesions were included in **Figure 4**.

Broilers that survived to day 56 without developing clinical lameness were weighed and necropsied. Individual body weights by chamber are shown in **Figure 5**. The average body weight for chamber 9 was significantly higher than the average body weight for chamber 10 ( $3.48 \pm 0.05$  kg vs.  $3.17 \pm 0.05$  kg, respectively, Mean  $\pm$  SEM;  $P = 0.001$ ), but chamber 10 also was found to have the lowest mortality of all chambers (10%, **Figure 2**) and therefore had the highest bird density. Crowding and thus restricted access to feeders may have slightly altered potential growth for chamber 10. Another comparison that was found to differ significantly in

average body weight was for Biomin chamber 6 versus Control chamber 7 ( $3.42 \pm 0.10$  kg vs.  $3.20 \pm 0.05$  kg, respectively Mean  $\pm$  SEM;  $P = 0.036$ ); however, none of the remaining comparisons among chambers differed ( $P \geq 0.173$ ), nor was there a significant difference when the average body weights were pooled by diet treatment and compared (Control =  $3.35 \pm 0.03$  kg,  $n = 154$ ; Biomin =  $3.27 \pm 0.03$  kg,  $n = 177$ , Mean  $\pm$  SEM;  $P = 0.081$ ).

**Figure 6** demonstrates the diagnostic categories for the 658 legs (all birds pooled by diet treatment) of all broilers that survived to day 56 without developing lameness. FHS was observed in 53.2% of the birds fed the Control diet and in 58.2% of those fed the Biomin diet, yet the incidences of FHT, FHN, and THN were less than 12% for both diet treatments. The incidence of FHN tended to be higher in the birds fed the Biomin diet treatment, yet there was no significant difference when comparing the Control diet for incidence of FHN ( $P = 0.106$ ). In addition, the remaining diagnostic comparisons between treatments also did not differ significantly ( $P = 0.139$  for THN). Throughout the whole population of survivors, only 26% were categorized as having macroscopically normal proximal femoral and tibial heads; however, 74% from both diet treatments combined were documented as having at least one lesion that characterized the bird as having the sub-clinical potential to become lame (FHS, FHT, FHN, or THN). Of this percentage, 66 to 70% of the lesions were located in the proximal femoral head.

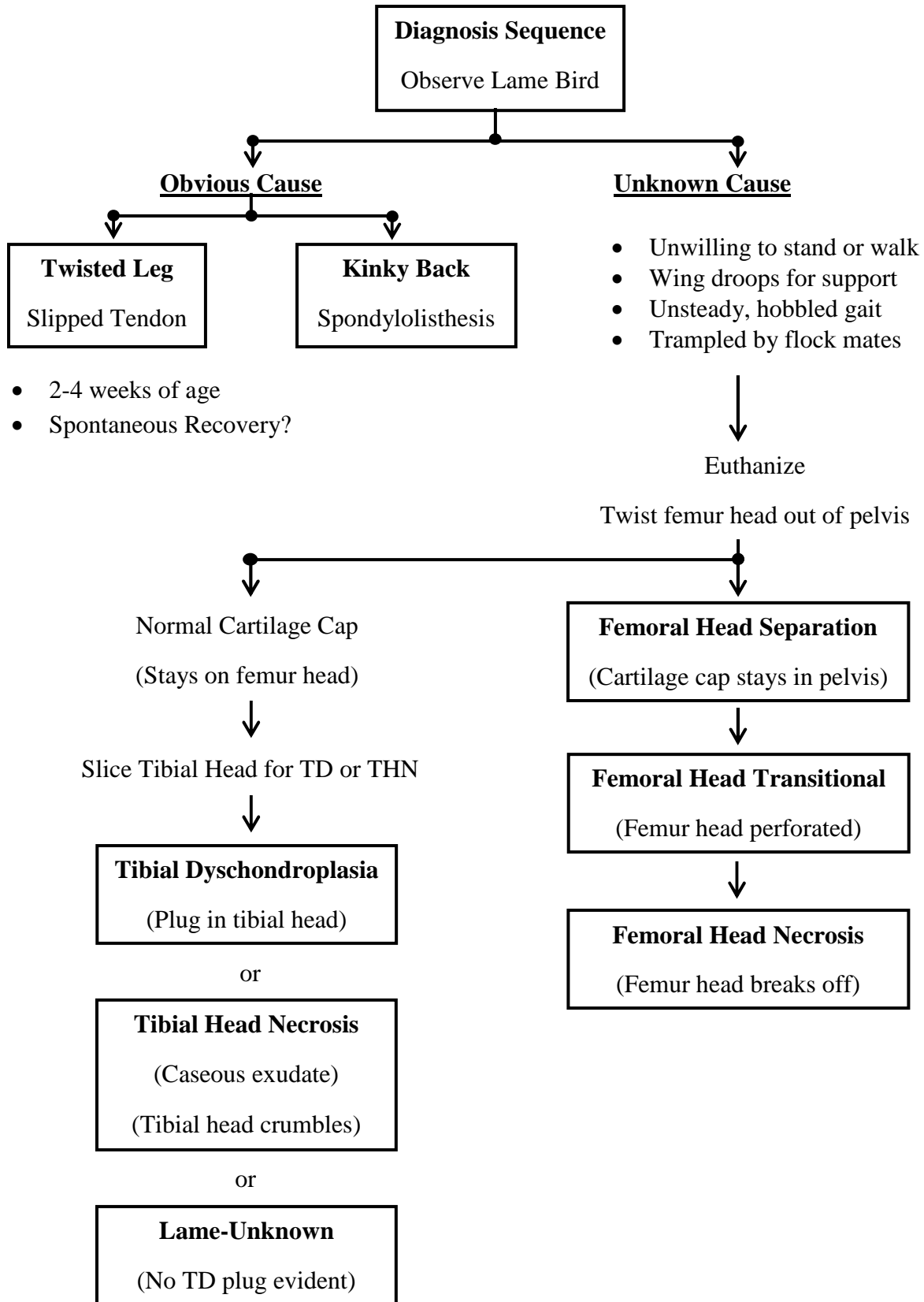
**Figure 7** illustrates comparisons of the left vs. right legs when pooled by diagnostic category for day 56 survivors independent of the diet treatment group. No evidence was found that linked sub-clinical lesions forming preferentially in either the left or right leg. Regardless of whether the proximal femoral head was normal or exhibited FHS, FHT, or FHN within the same leg (right and left legs combined), the ipsilateral proximal tibial head was significantly (Femur Normal, Femur FHS, Femur FHT) or numerically (Femur FHN) more likely to remain normal

rather than to exhibit macroscopic indications of THN (**Figure 8**) ( $P = 0.001, 0.001, 0.001,$  and  $0.341$  respectively).

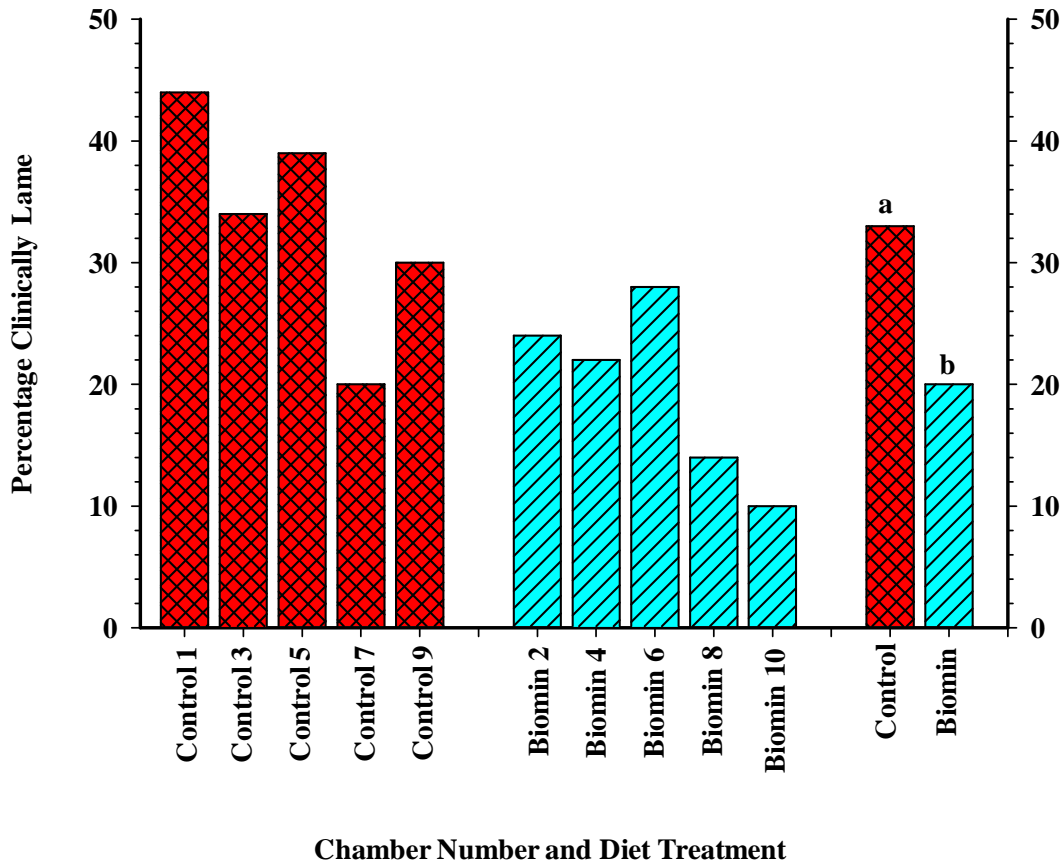
**Figure 9** summarizes the principle diagnostic categories for all birds that developed clinical lameness versus all birds that survived to day 56 without developing clinical lameness (left and right legs and diet treatments pooled together). When reviewing the femoral diagnostic categories, the day 56 survivors had higher incidences of FHS, but lower incidences of FHN when compared with clinically lame birds ( $P = 0.001$ ). For tibial head observations, the surviving broilers had higher incidences of normal tibiae and lower incidences of THN when compared with the clinically lame birds ( $P = 0.001$ ). Clinically lame birds were found to exhibit THN in 59.3% of the population while only 40.7% of the lame birds were found to have normal tibiae. For the surviving population only 13.6% of their tibiae displayed THN while 86.4% were normal ( $P = 0.001$ ). These findings provide solid evidence that there is a specific and highly significant relationship between clinical lameness and THN.



**APPENDIX A: Clinical Lameness Diagnostic Sequence**

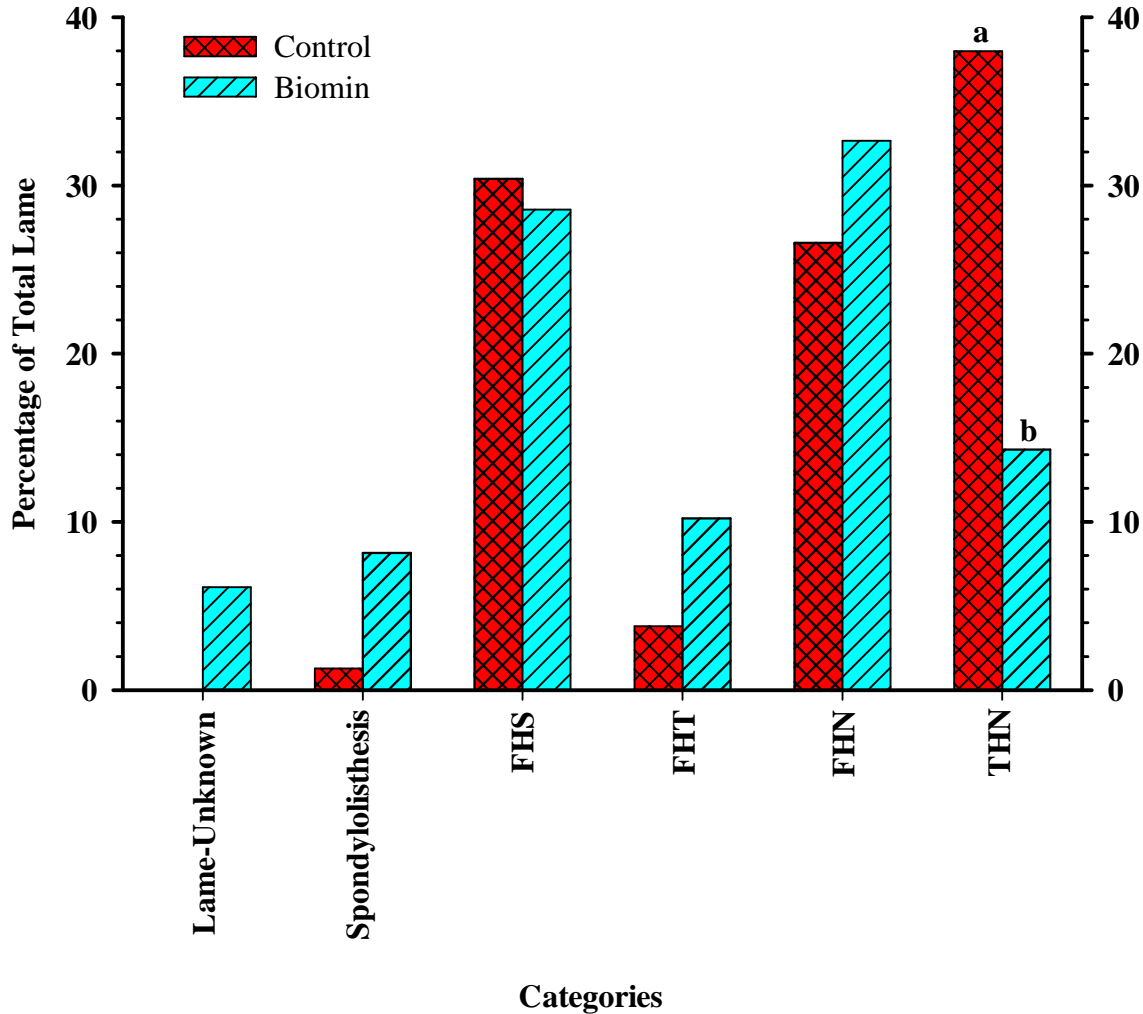


### Lameness per Environmental Chamber or Diet Treatment



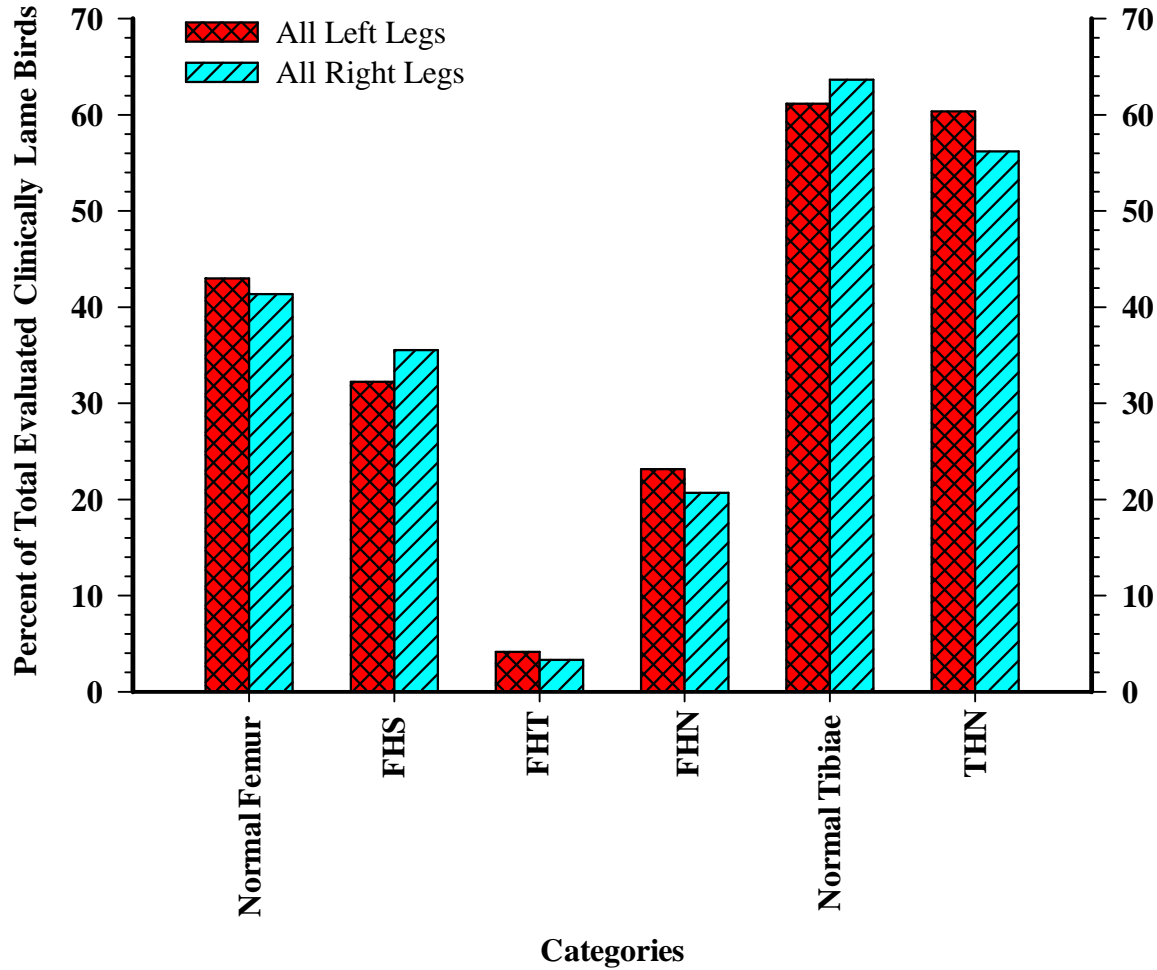
**Figure 2.** Broilers from Line B were grown on wire flooring in environmental chambers and were fed either a Control diet (Control Feed, odd-chambered chambers) or the control diet mixed with the Biomin PoultryStar® probiotic (Biomin feed, even-numbered chambers). Lameness incidences are shown by individual chamber (numbers 1 to 10) as well as with the chambers pooled by diet treatment (Control diet vs. Biomin diet).<sup>a,b</sup> The lameness incidences for all chambers pooled by diet treatment differed significantly ( $P = 0.001$ ; 77/238 for Control diet, 45/250 for the Biomin diet) based on a Z-test. (Percent clinically lame Control group:  $33.4 \pm 4.09$  standard error; Percent clinically lame Biomin group:  $19.6 \pm 3.31$  standard error.)

### Diagnosis Categories for Clinically Lamé Broilers

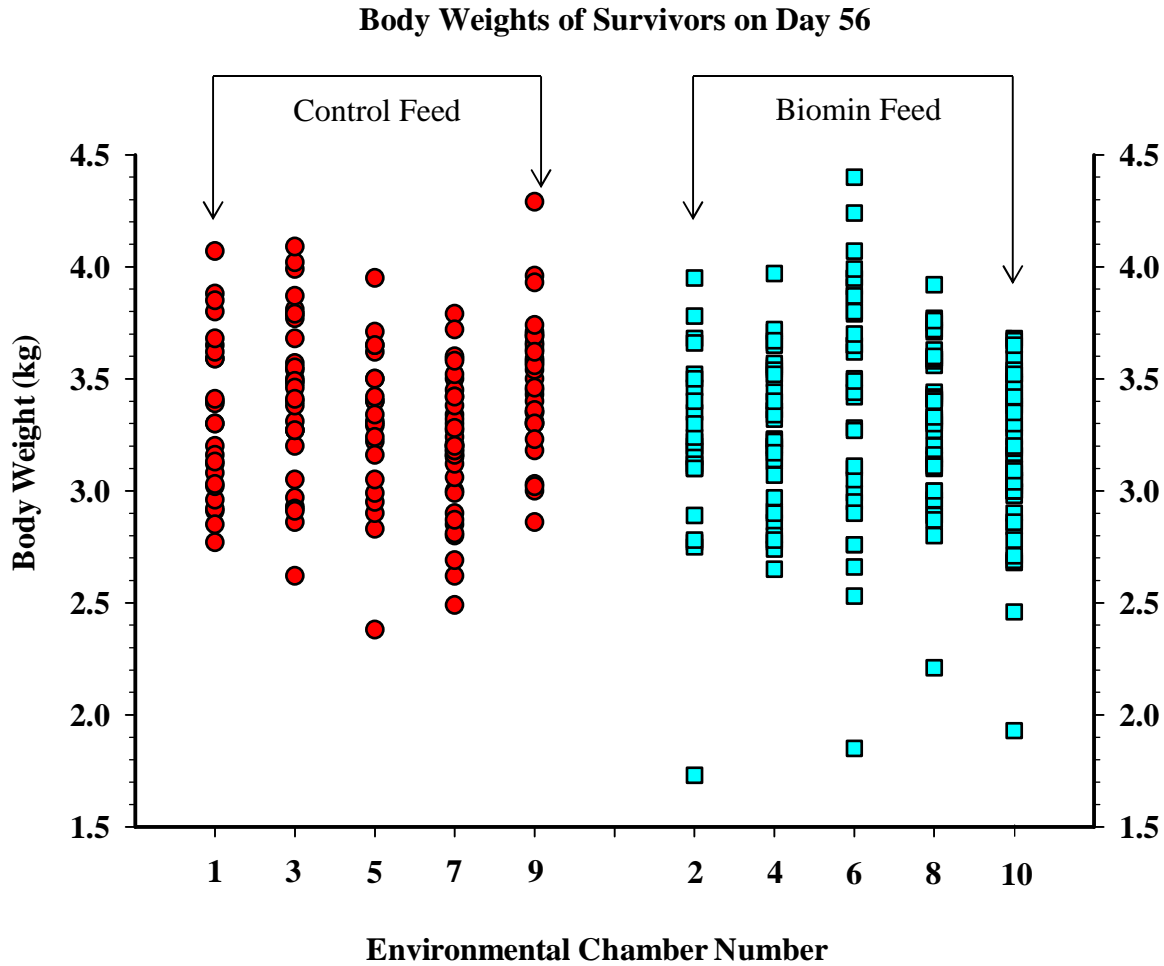


**Figure 3.** Diagnosis categories for clinically lame broilers fed the Control diet or the control diet mixed with Biomin PoultryStar® probiotic included: Lame-Unknown (cause of lameness could not be determined); Spondylolisthesis (kinky back); FHS (femoral head separation); FHT (femoral head transitional degeneration); FHN (femoral head necrosis); and, THN (tibial head necrosis). <sup>a,b</sup> THN incidences differed significantly between the Control and Biomin diet treatments ( $P = 0.008$ ; Z-test). Incidences of Spondylolisthesis, FHT, and FHN did not differ significantly between the diet treatments ( $P = 0.137$ ,  $0.280$ , and  $0.592$  respectively).

### Left vs. Right Leg Comparisons for Clinically Lamé Broilers

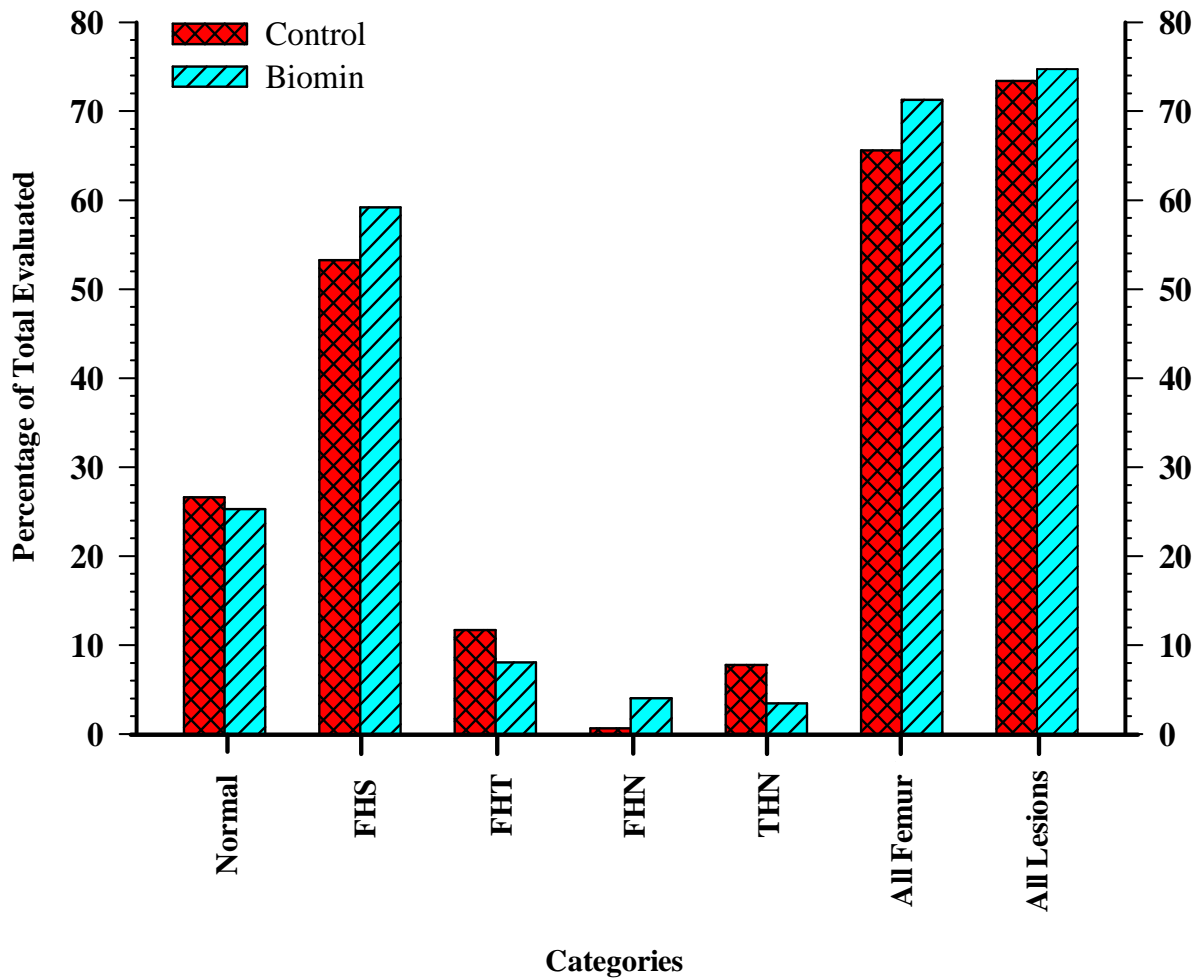


**Figure 4.** All birds succumbing to clinical lameness through 56 days of age were necropsied to evaluate the incidence of macroscopic lesions in the proximal femoral and tibial heads of both legs for both diet treatments. Diagnostic categories for the femur include: Normal, FHS, FHT, and FHN. For the proximal tibial head, diagnostic categories included Normal or THN. When pooled by diagnostic category independent of diet treatment group, no tendency was revealed for lesions to form preferentially in either the left or right leg ( $P \geq 0.602$  for THN; Z-test).



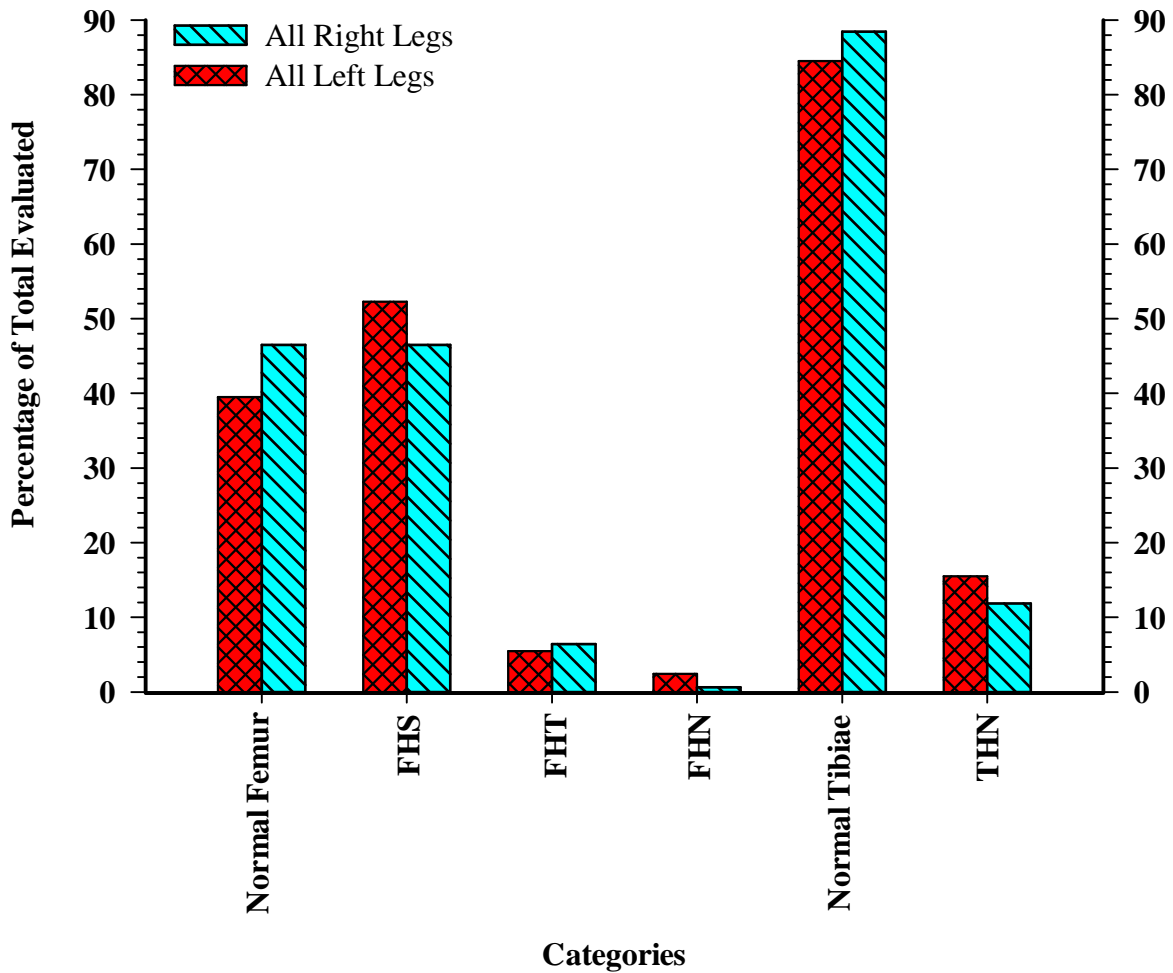
**Figure 5.** Broilers that survived through day 56 and did not develop lameness were euthanized and weighed prior to being necropsied. Individual body weights are displayed by chamber number and correlates to their respective diet treatments (Odd-numbered chambers: Control diet; Even-numbered chambers: Control diet plus Biomin PoultryStar® mixed into feed). The average body weight for Control chamber 9 was significantly higher than for Biomin chamber 10 ( $3.48 \pm 0.05$  kg vs.  $3.17 \pm 0.05$  kg, respectively, Mean  $\pm$  SEM;  $P = 0.001$ ). In addition, the average body weight for Biomin chamber 6 was significantly higher than for Control chamber 7 ( $3.42 \pm 0.10$  kg vs.  $3.20 \pm 0.05$  kg, respectively Mean  $\pm$  SEM;  $P = 0.036$ ); however, none of the remaining comparisons among chambers differed significantly ( $P \geq 0.173$ ). (Average Control group weight:  $3.35\text{kg} \pm 0.15$  kg standard error; Average Biomin group weight  $3.27$  kg  $\pm 0.18$  kg)

### Diagnosis Categories for Survivors on Day 56



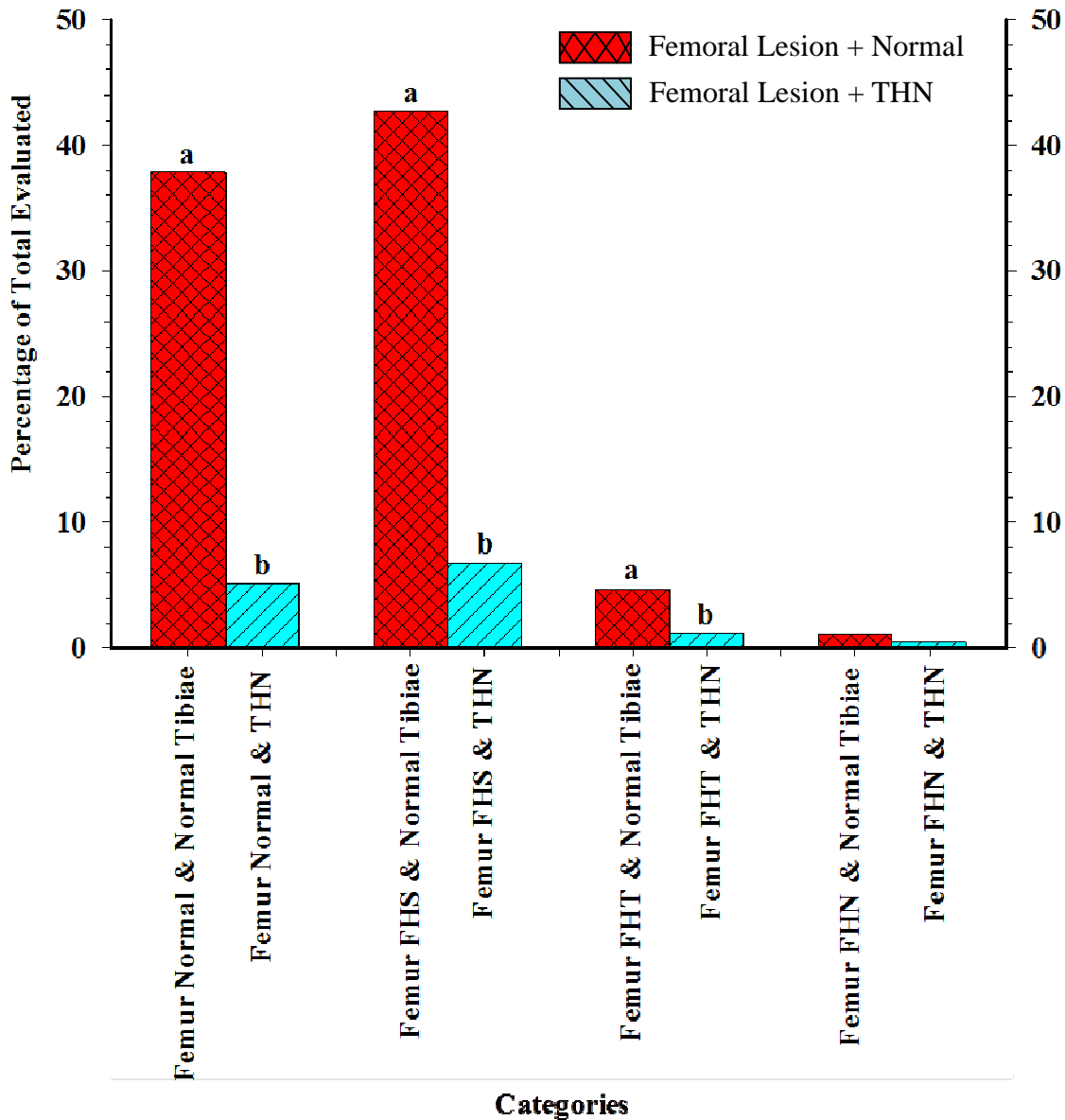
**Figure 6.** All broilers that did not succumb to clinical lameness were necropsied on day 56 to evaluate the incidence of sub-clinical macroscopic lesions in the proximal femoral and tibial heads. Combining diet treatments and left and right legs, 658 legs were evaluated. Diagnostic categories for the femur included Normal, FHS, FHT, and FHN. Diagnostic categories for the proximal tibial head were normal or THN. The incidence of FHN tended to be higher in birds fed the Biomin diet; however, when compared to the control diet, the incidence of FHN did not differ significantly nor did any of the remaining comparisons of diet treatments between diagnostic categories ( $P \geq 0.106$  for FHN; Z-test).

### Left vs. Right Leg Comparisons for Survivors on Day 56



**Figure 7.** Broilers that did not develop clinical lameness were subjected to necropsy on day 56 to evaluate the incidence of sub-clinical macroscopic lesions in proximal femoral and tibial heads. A total of 658 legs were evaluated when combining diet treatments and left and right legs. Diagnostic categories for femur included: Normal, FHS, FHT, and FHN. Proximal tibial head diagnostic categories included Normal or THN. When pooled by diagnostic category independent of diet treatment group, no tendency was revealed for lesions to form preferentially in either the left or right leg ( $P=0.160$  for FHS; Z-test).

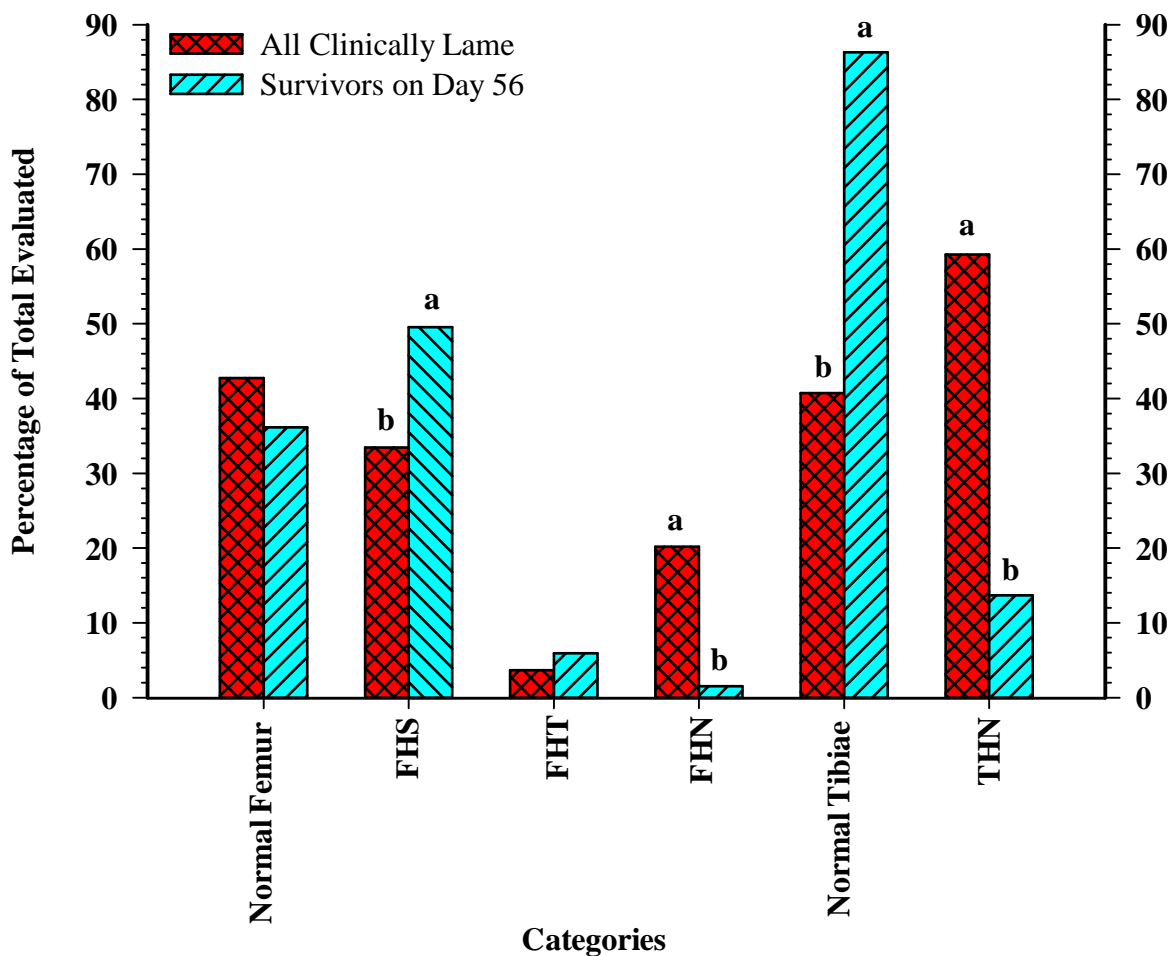
**Same-Leg Femur vs. Tibia Correlations for Day 56 Survivors  
(Right & Left Legs Pooled; Control & Biomin Pooled)**



**Figure 8.** Broilers that did not develop clinical lameness were necropsied on day 56 to evaluate the incidence of sub-clinical macroscopic lesions in proximal femoral and tibial heads (658 right and left legs combined for both diet treatments). Regardless of whether the proximal femoral head was normal or exhibited one of the macroscopic lesions, within the ipsilateral leg the proximal tibial head was significantly (Femur Normal, Femur FHS, or Femur FHT) more likely to remain normal rather than to exhibit macroscopic indications of THN ( $P = <0.001, <0.001, \text{ and } <0.001$ , respectively; Z-test).



**Diagnosis Categories for Clinically Lamé vs. Survivors  
(Right & Left Legs Pooled; Control & Biomin Diets Pooled)**



**Figure 9.** Combining both diet treatments 128 birds developed clinical lameness and 329 birds survived to Day 56 without succumbing to lameness. Combining left and right legs, 256 and 658 legs were evaluated within the clinically lame and survivors groups, respectively. Different superscripts denote a significant difference ( $P = 0.001$ ) between the clinically lame and survivors groups within a diagnostic category (Normal femur, FHS, FHT, FHN, Normal Tibiae, and THN) (Z-test).

## **Discussion**

The goal of this study was to evaluate the efficacy of adding the Biomin probiotic PoultryStar® to the broilers' feed beginning at 1 day of age, in an attempt to reduce the incidence of lameness triggered by wire flooring. The mode of action by which probiotics reduce the infection of susceptible leg joints leading to lameness is relatively unknown at this time. It is possible that stress elicited by various factors, such as the wire flooring model, tend to create an imbalance in the birds' intestinal microflora thus lowering the body's defense mechanisms. The wire-flooring model promotes high growth rates and normal levels of activity at lower stocking densities when compared with cage-rearing systems, while using unstable footing to impose additional torque and strain on susceptible leg joints (Wideman et al., 2012). However, the continuous feeding of probiotics to poultry could maintain beneficial intestinal microflora by competitive exclusion and by antagonistic activity towards pathogenic bacteria (Jin et al., 1997). Probiotics allow birds to obtain the proper microbial balance thus allowing them to receive a "boost" in the establishment of an appropriate or beneficial microbial population (Jernigan et al., 1985). In addition, probiotics can allow a reasonable alternative to the use of antibiotics which may potentially upset normal microflora and lead to collateral problems such as the development of drug-resistant bacteria (Awad et al., 2009).

Mild, moderate, or severe physeal osteochondrosis (e.g., the formation of clefts, voids and micro-fractures in the growth plate and metaphyseal cartilage), often occur in seemingly healthy broilers that display no symptoms of lameness. This suggests that mechanical damage to the proximal growth plates of leg bones alone may not be the sole origin to the incidence of lameness, but rather that ensuing bacterial infections within osteochondrotic clefts, such as that caused by excessive torque and shear stress from the wire flooring, is the main cause for the

development of BCO in broilers (McNamee et al., 1998; Wideman et al., 2012). Sluggish circulation in metaphyseal vessels that are mechanically damaged or partially occluded also may contribute to bacterial infection within the epiphyseal-physeal cartilage (Thorp and Waddington, 1997, Wideman et al., 2012). The actual incidence of BCO is likely to be underestimated during investigation of lameness in broilers unless the growth plate of the femur and tibiotarsus are examined for lesions both macro- and microscopically (McNamee and Smyth, 2000). Broilers may remain fully capable of standing and walking with an acceptable gait yet still possess early lesions that are consistent with the pathological progression to terminal BCO (Wideman and Pevzner, 2012; Wideman et al., 2012). Evidence of this was found in the survivors on day 56 where the birds were capable of walking without exhibiting obvious symptoms of lameness, yet they often displayed early BCO lesions (Figures 6, 7, 8). Another factor tested with this experiment involved the comparison of all four proximal growth plates and the potential influence of lesions to form preferentially on the ipsilateral or contralateral legs (Figure 7). No evidence was found that linked sub-clinical lesions forming favorably in either the left or right leg nor did the status of the proximal femoral head determine the status of the ipsilateral or contralateral proximal tibial head or vice versa. These findings are consistent with the proposal by McNamee et al. (1998) that physeal chondronecrosis is just as commonly found in healthy, sound birds as it is in lame birds and that the triggering factor for birds succumbing to lameness is infection and bacterial colonization of the damaged areas. In addition, the observations of the present study were also consistent with reports by Thorp et al. (1993) who found that ‘proximal femoral degeneration’ (now known better as BCO) was most commonly attributed to a bacterial infection that caused a bacterial chondritis of the epiphyseal and physeal cartilages as well as metaphyseal osteomyelitis with varying involvement of surrounding tissues including the

articular cartilage. Furthermore, the conditions of infectious and non-infectious cases were histologically distinct from one another. The infectious cases were noted as having bacterial foci surrounded by a distinct region of chondrocyte necrosis and cartilage degeneration, whereas non-infectious cases were characterized by vascular occlusion, cleft formation, and focal disorganization and degeneration of the cartilage matrix. These findings collectively suggest that the pathogenesis of BCO is not instantaneous as many sub-clinically affected broilers may not exhibit obvious symptoms of lameness and yet they may still possess lesions primarily consisting of osteochondrosis. It is only when bacterial infection ensues in these osteochondrotic clefts that the sub-clinically affected birds begin suffering the adverse effects of lameness due to BCO (Wideman et al., 2012).

Environmental stressors and immunosuppression have been associated with the etiology of spontaneous BCO outbreaks in commercial broiler flocks (Wideman and Pevzner, 2012). In a review of skeletal disorders in fowl, Thorp (1994) described the condition known as osteochondrosis as a disturbance of endochondral ossification that occurs in the extremities of bones that have been growing normally. He lists a variety of lesions that have been described in the proximal femur of growing broilers including metaphyseal osteomyelitis with separation of the proximal femur from the shaft, and separation of the cartilaginous epiphysis from the femur on dis-articulation of the coxofemoral joint. These lesions in some cases may be attributed to underlying pathologies of the growth plate including osteochondrosis, osteomyelitis, and dyschondroplasia and trauma with subsequent epiphyseolysis (Thorp, 1994). Microscopic lesions of osteochondrosis in the fowl include thrombosed and occluded vessels in both the cartilaginous epiphysis and the proliferating zone of the physis, as well as distinct tears or clefts that occur in the cartilage (Thorp, 1994). These small clefts and other focal disturbances in the

physis of the femur and tibiae are thought to facilitate bacterial colonization and ultimately lead to the development of BCO. The wire flooring model used in the present study amplifies mechanical stress on the proximal growth plates and chronically applies additional torque and shear stress on susceptible leg joints, leading to the development of significant levels of BCO.

El-Lethey et al. (2003) demonstrated that the immune response of chickens can be compromised by the stress-related parameters involved with both genetic and environmental factors. The effect of stress on the immune system is mediated either by endocrinological changes, involving the hypothalamus—pituitary—adrenocortical (HPA) axis, or by the involvement of the sympathetic nervous system and neuropeptides. The primary glucocorticoid secreted in stressful situations by the avian adrenal gland is corticosterone. This glucocorticoid induces immunosuppression and thus jeopardizes the bird's antimicrobial resistance. El-Lethey et al., (2003) found that when chickens were housed on slat surfaces instead of deep floor litter, profound immunosuppression ensued. A related study was performed by Huff et al., (2000) who revealed that rapidly growing turkeys can develop osteomyelitis of the proximal tibial head (turkey osteomyelitis complex; TOC) due to bacterial colonization by opportunistic pathogens. The incidence of TOC increased when turkeys experience environmental stressors and subsequent immunosuppression typical of modern day turkey production. Stress-mediated immunosuppression can reduce the birds' resistance to bacterial infection. A number of different bacterial species have been isolated from TOC lesions; however, the most prominent opportunistic pathogens isolated were *Staphylococcus aureus* and *Escherichia coli*. With several different bacterial strains having been isolated from TOC lesions, it is proposed that this condition may be influenced more by the immunological state or the environmental stressors imposed upon the host instead of by the virulence of any single species or strain of bacteria (Huff

et al., 1998; Huff et al., 2000). These findings suggest that environmental factors, such as the type of flooring system that birds are reared upon, can indeed influence the birds' immune response and their ability to fight off potential pathogenic bacterial infections. Probiotics therefore may be used to bridge the gap created by immunosuppression from environmental stressors, by priming the birds' immune system with beneficial microbes. Birds with a suitably primed immune system may be able to better defend against opportunistic pathogens when environmental stress otherwise compromises their defenses.

Various stressors (e.g. burn, surgery, and hemorrhagic shock) promote the translocation of indigenous bacteria from the gastrointestinal tract to extraintestinal sites, including the mesenteric lymph node complex, liver, spleen and other organs (Ando et al., 2000). These observations provide a plausible basis for bacteria having a route of entry into the circulatory system and becoming redistributed into susceptible leg joints in birds with BCO. Regarding the role of bacterial translocation and bacteremia in the etiology of BCO, probiotics hypothetically may reduce the onset of lameness by competitively excluding potentially pathogenic bacteria through the addition of beneficial intestinal organisms in chicks and poults in the early stages of broiler placement. The competitive exclusion approach of inoculating day-old chicks with adult microflora successfully demonstrates the impact of the intestinal organism on disease resistance and intestinal function (Kabir, 2009). This will ultimately lead to influences in the development of the chick's immune response as the probiotics will compete for (unspecified) receptor sites within the gut (Mead, 2000; Kabir, 2009). The concept of a balanced intestinal microbiota enhancing resistance to infection and reduction in resistance when the intestinal microbiota is disturbed is important in understanding the microbe-host relationship. While the constitution of balanced and disturbed populations is not clear, certain microbial populations, lactobacilli and

bifidobacterial species, appear to be sensitive to stress and tends to decrease when a bird is under stress (Patterson and Burkholder, 2003). With these two species being represented within the PoultryStar® probiotic, is reasonable to concur that the addition of this probiotic to the feed can ultimately prime the immune system in advance of stress-associated mediators and create a more improved, healthy gastrointestinal tract for the birds.

Adding the Biomin PoultryStar® probiotic prophylactically to the control feed at 1 day of age significantly reduced the incidence of lameness in broilers reared on wire flooring when compared with hatch-mates grown on the same wire flooring and fed the control feed alone (19.6 vs. 33.2 % respectively;  $P = 0.001$ ). As it is currently understood, our wire flooring model promotes osteochondrosis by chronically amplifying the mechanical stress and torque imposed on the epiphyseal-physeal cartilage, thereby enhancing the incidence of physeal osteochondrosis accompanied by mechanical truncation or thrombotic occlusion of metaphyseal vessels (Wideman et al., 2012). The addition of the probiotic theoretically lowers the incidence of BCO by modifying the normal gut microflora and thus reducing the likelihood for potential translocation of pathogenic bacteria from the gastrointestinal tract to the osteochondrotic clefts and damaged metaphyseal vessels. Reduced bacterial translocation should reduce bacterial colonization and lameness attributable to BCO. A previous study using the Biomin PoultryStar® probiotic was conducted by Mountzouris et al. (2007) which focused on the effect of the probiotic on broiler growth performance and the composition of cecal microflora. This research showed that the probiotic resulted in beneficial modulation of the gut microflora, as evidenced by significant ( $P \leq 0.05$ ) increases in the concentration of bacteria belonging to the *Bifidobacterium spp.*, *Lactobacillus spp.*, and gram positive cocci. These positive responses were noted in experiments in which the probiotic was administered in both feed (PF) and water

forms (PFW) and compared against a control feed and antibiotic (avilamycin) feed treatment. In a follow up study, Mountzouris et al. (2010) confirmed the potential of the Biomin PoultryStar® probiotic's ability to fortify beneficial microorganisms in the intestinal microflora. This was demonstrated by significant elevations of *Lactobacillus* and *Bifidobacterium spp.* in the cecal digesta of 42-d-old broilers when compared to the cecal microflora of broilers at day 14. The concentrations of *Lactobacillus* and *Bifidobacterium spp.* reached their maximum concentrations at day 28 and later declined but remained significantly higher than the respective concentrations determined at day 14. Throughout the study, the concentration of coliforms decreased with age and was ultimately found to be significantly lower than the probiotic concentration levels on day 42 ( $P = 0.048$ ). These observations demonstrate that the Biomin PoultryStar® probiotic may indeed have the beneficial health effects necessary to potentially improve the normal gut microflora and lower the risk of pathogenic bacterial translocation out of the gastrointestinal tract to areas of possible bacterial colonization such as seen in BCO. Furthermore, the feed conversion ratio in both the PFW and PF treatments (Mountzouris et al., 2007) were found to be no different than the antibiotic treatment suggesting that probiotics may in fact be a plausible alternative to antibiotics to the improvement of growth performance and disease prevention in broilers.

In conclusion, it is believed that the combination of single pass ventilation, (excellent air quality), wire flooring (instability causing shear stress and torque), and the continuous feeding of PoultryStar® throughout the experiment (ongoing re-inoculation) likely constituted ideal conditions under which the probiotic elicited beneficial responses to the bird's gastrointestinal microflora and immune system. Bacterial translocation from the gastrointestinal tract to susceptible leg joints was apparently reduced or retarded by the addition of probiotics to the



experimental groups' feed thus delaying the progressive deterioration of early lesions associated with osteochondrotic clefts produced by the stress of the wire flooring. Broilers fed the PoultryStar® probiotic had a significant overall reduction in the onset of lameness contributed to BCO vs. broilers fed the control diet alone (19.6% vs. 33.2% respectively). This experiment indicates that the administration of probiotics prophylactically to the feed of 1-day-old chicks can provide a plausible alternative to antibiotics for reducing the incidence of lameness in broiler flocks attributed to the condition of BCO.

## Works Cited

- Alderson, Mark, David Spears, Kerry Emslie, and Sydney Nade. "Acute Haematogenous Osteomyelitis and Septic Arthritis-A Single Disease." *The Journal of Bone and Joint Surgery* 68.2 (1986): 268-74.
- Ando, Tetsuya, Rhonda F. Brown, Rodney D. Berg, and Adrian J. Dunn. "Bacterial Translocation Can Increase Plasma Corticosterone and Brain Catecholamine and Indolamine Metabolism." *American Journal of Physiology* 279 (2000): R2164-2172.
- Andrews, L. D., and T. L. Goodwin. "Performance of Broilers in Cages." *Poultry Science* 52.2 (1973): 723-28.
- Andrews, L. D., R. L. Seay, G. C. Harris, Jr., and G. S. Nelson. "Flooring Materials for Caged Broilers and Their Effect Upon Performance." *Poultry Science* 53.3 (1974): 1141-146.
- Andrews, L. D., T. S. Whiting, and L. Stamps. "Performance and Carcass Quality of Broilers Grown on Raised Floorings and Litter." *Poultry Science* 69.10 (1990): 1644-651.
- Awad, W. A., K. Ghareeb, S. Abdel-Raheem, and J. Bohm. "Effects of Dietary Inclusion of Probiotic and Synbiotic on Growth Performance, Organ Weights, and Intestinal Histomorphology of Broiler Chickens." *Poultry Science* 88.1 (2009): 49-56.
- Bradshaw, R.H., R.D. Kirkden, and D.M. Broom. "A Review of the Aetiology and Pathology of Leg Weakness in Broilers in Relation to Welfare." *Avian and Poultry Biology Reviews* 13.2 (2002): 45-103.
- Butterworth, A., N. A. Reeves, D. Harbour, G. Werrett, and S. C. Kestin. "Molecular Typing of Strains of Staphylococcus Aureus Isolated from Bone and Joint Lesions in Lamé Broilers by Random Amplification of Polymorphic DNA." *Poultry Science* 80 (2001): 1339-343.
- Cook, M. E. "Skeletal Deformities and Their Causes: Introduction." *Poultry Science* 79.7 (2000): 982-84.
- Chaucheyras-Durand, F., and H. Durand. "Probioitcs in Animal Nutrition and Health." *Beneficial Microbes* 1.1 (2010): 3-9.
- Dinev, I. "Clinical and Morphological Investigations on the Prevalence of Lameness Associated with Femoral Head Necrosis in Broilers." *British Poultry Science* 50.3 (2009): 284-90.
- Drisko, Jeanne A., Cheryl K. Giles, and Bette J. Bischoff. "Probioitcs in Health Maintenance and Disease Prevention." *Alternative Medicine Review* 8.2 (2003): 143-55.

- Durairaj, V., R. Okimoto, K. Rasaputra, F. D. Clark, and N. C. Rath. "Histopathology and Serum Clinical Chemistry Evaluation of Broilers With Femoral Head Separation Disorder." *Avian Diseases* 53.1 (2009): 21-25.
- El Boushy, A. R. "Skeletal Problems in Commercial Broilers." *World's Poultry Science Journal* 30.3 (1974): 183-92.
- El-Lethey, H., Beat Huber-Eicher, and Thomas W. Jungi. "Exploration of Stress-induced Immunosuppression in Chickens Reveals Both Stress-resistant and Stress-susceptible Antigen Responses." *Veterinary Immunology and Immunopathology* 95.3-4 (2003): 91-101.
- Emslie, Kerry R., and Sydney Nade. "Acute Hematogenous Staphylococcal Osteomyelitis: A Description of the Natural History in an Avian Model." *The American Journal of Pathology* 110.3 (1983): 333-45.
- Fuller, R. "Probiotics in Man and Animals: A Review." *Journal of Applied Bacteriology* 66 (1989): 365-78.
- Hamer, Davidson H. "From the Farm to the Kitchen Table: The Negative Impact of Antimicrobial Use in Animals on Humans." *Nutrition Reviews* 60.8 (2002): 261-64.
- Havenaar R., Ten Brink, B., Huis in 't Veld, J.H.J. In: Fuller, R. (Ed.), *Probiotics: The Scientific Basis*. By London ; New York: Chapman & Hall, 1992. 209-24.
- Holzappel, Wilhelm H., Petra Haberer, Johannes Snel, Ulrich Schillinger, and Jos H. J. HuisIn't Veld. "Overview of Gut Flora and Probiotics." *International Journal of Food Microbiology* 41 (1998): 85-101.
- Howlett, C. R. "The Fine Structure of the Proximal Growth Plate and Metaphysis of the Avian Tibia: Endochondral Osteogenesis." *Journal of Anatomy* 130.4 (1980): 745-68.
- Howlett, C. R., M. Dickson, and A. K. Sheridan. "The Fine Structure of the Proximal Growth Plate of the Avian Tibia: Vascular Supply." *Journal of Anatomy* 139.1 (1984): 115-32.
- Huff, G. R., W. E. Huff, J. M. Balog, and N. C. Rath. "The Effects of Dexamethasone Immunosuppression on Turkey Osteomyelitis Complex in an Experimental Escherichia Coli Respiratory Infection." *Poultry Science* 77 (1998): 654-61.
- Huff, G. R., W. E. Huff, N. C. Rath, and J. M. Balog. "Turkey Osteomyelitis Complex." *Poultry Science* 79 (2000): 1050-056.
- Jeffery, Joan S. "Use of Competitive Exclusion Products for Poultry." *Poultry Fact Sheet No. 30* (Mar. 1999): 1-4. Print. Cooperative Extension, University of California.

- Jensen, Eric L., and Carolyn L. Miller. "Staphylococcus Infections in Broiler Breeders." *Aviagen North America*, 2001. Web. 31 May 2012.  
<[http://www.canadianpoultry.ca/cms\\_pdfs/AviaTech\\_Staph.pdf](http://www.canadianpoultry.ca/cms_pdfs/AviaTech_Staph.pdf)>.
- Jernigan, M. A., R. D. Miles, and A. S. Arafa. "Probiotics in Poultry Nutrition-a Review." *World's Poultry Science Journal* 41 (1985): 99-107.
- Jin, L. Z., Y. W. Ho, N. Abdullah, and S. Jalaludin. "Probiotics in Poultry: Modes of Action." *World's Poultry Science Journal* 53.4 (1997): 351-68.
- Julian, R. J. "Rapid Growth Problems: Ascites and Skeletal Deformities in Broilers." *Poultry Science* 77.12 (1998): 1773-1780.
- Julian, Richard J. "Production and Growth Related Disorders and Other Metabolic Diseases of Poultry – A Review." *The Veterinary Journal* 169.3 (2005): 350-69.
- Kabir, S. M. Lutful. "The Role of Probiotics in the Poultry Industry." *International Journal of Molecular Science* 10 (2009): 3531-546.
- McNamee, P. T., J. J. McCullagh, B. H. Thorp, H. J. Ball, D. Graham, S. J. McCullough, D. McConaghy, and J. A. Smyth. "Study of Leg Weakness in Two Commercial Broiler Flocks." *Veterinary Record* 143.5 (1998): 131-35.
- McNamee, Perpetua T., J. J. McCullagh, J. D. Rodgers, B. H. Thorp, H. J. Ball, T. J. Connor, Deirdre McConaghy, and Joan A. Smyth. "Development of an Experimental Model of Bacterial Chondronecrosis with Osteomyelitis in Broilers following Exposure to *Staphylococcus aureus* by Aerosol, and Inoculation with Chicken Anaemia and Infectious Bursal Disease Viruses." *Avian Pathology* 28.1 (1999): 26-35.
- McNamee, Perpetua T., and Joan A. Smyth. "Bacterial Chondronecrosis with Osteomyelitis ('femoral head necrosis') of Broiler Chickens: A Review." *Avian Pathology* 29.5 (2000): 477-95.
- Mead, G. C. "Prospects for 'Competitive Exclusion' Treatment to Control Salmonellas and Other Foodborne Pathogens in Poultry." *The Veterinary Journal* 159.2 (2000): 111-23.
- Mountzouris, K. C., P. Tsirtsikos, E. Kalamara, S. Nitsch, G. Schatzmayr, and K. Fegeros. "Evaluation of the Efficacy of a Probiotic Containing *Lactobacillus*, *Bifidobacterium*, *Enterococcus*, and *Pediococcus* Strains in Promoting Broiler Performance and Modulating Cecal Microflora Composition and Metabolic Activities." *Poultry Science* 86 (2007): 309-17.

- Mountzouris, K. C., P. Tsitrsikos, I. Palamidi, A. Arvaniti, M. Mohnl, G. Schatzmayr, and K. Fegeros. "Effects of Probiotic Inclusion Levels in Broiler Nutrition on Growth Performance, Nutrient Digestibility, Plasma Immunoglobulins, and Cecal Microflora Composition." *Poultry Science* 89.1 (2010): 58-67.
- Naas, I. A., I. C. L. A. Paz, M. S. Baracho, A. G. Menezes, L. G. F. Bueno, I. C. L. Almeida, and D. J. Moura. "Impact of Lameness on Broiler Well-being." *The Journal of Applied Poultry Research* 18.3 (2009): 432-39.
- Nairn, M. E., and A. R. A. Watson. "Leg Weakness of Poultry—A Clinical and Pathological Characterization." *Australian Veterinary Journal* 48.12 (1972): 645-56.
- NRC. "Nutrient Requirements of Poultry." 9<sup>th</sup> rev. ed. (1994) Natl. Acad. Press, Washington, DC.
- Nurmi, E., and M. Rantala. "New Aspects of Salmonella Infection in Broiler Production." *Nature* 241.5386 (1973): 210-11.
- O'Dea, E. E., G. M. Fasenko, G. E. Allison, D. R. Korver, G. W. Tannock, and L. L. Guan. "Investigating the Effects of Commercial Probiotics on Broiler Chick Quality and Production Efficiency." *Poultry Science* 85 (2006): 1855-863.
- Patterson, J. A., and K. M. Burkholder. "Application of Prebiotics and Probiotics in Poultry Production." *Poultry Science* 82 (2003): 627-31.
- Rath, N. C., G. R. Huff, W. E. Huff, and J. M. Balog. "Factors Regulating Bone Maturity and Strength in Poultry." *Poultry Science* 79.7 (2000): 1024-032.
- Riddell, C. "Leg Problems Still Important." *Poultry Digest* 56 (1997): 28-31.
- Riddell, C., and R. Springer. "An Epizootiological Study of Acute Death Syndrome and Leg Weakness in Broiler Chickens in Western Canada." *Avian Diseases* 29 (1985): 90-102.
- Rodgers, John, John McCullagh, Perpetua McNamee, Joan Smyth, and Hywel Ball. "The Anti-nuclease Humoral Immune Response of Broiler Chickens Exposed to Staphylococcus Aureus, Infectious Bursal Disease Virus and Chicken Anaemia Virus in an Experimental Model for Bacterial Chondronecrosis and Osteomyelitis." *Avian Pathology* 35.4 (2006): 302-08.
- Sanotra, G. S., J. D. Lund, A. K. Ersbøll, J. S. Petersen, and K. S. Vestergaard. "Monitoring Leg Problems in Broilers: A Survey of Commercial Broiler Production in Denmark." *World's Poultry Science Journal* 57.1 (2001): 55-69.
- Skeeles, J. Kirk. "Staphylococcosis." *Diseases of Poultry*. Ed. B. W. Calnek, H. John Barnes, Charles W. Beard, Larry R. McDougald, and Y. M. Saif. 10th ed. Ames, Iowa, USA: Iowa State UP, 1997. 247-53. Print. Chapter 11.

- Skinner-Noble, D. O., and R. G. Teeter. "An Examination of Anatomic, Physiologic, and Metabolic Factors Associated with Well-being of Broilers Differing in Field Gait Score." *Poultry Science* 88.1 (2009): 2-9.
- Smeltzer, M. S., and A. F. Gillasp. "Molecular Pathogenesis of Staphylococcal Osteomyelitis." *Poultry Science* 79 (2000): 1042-049.
- Smith, H. W. "Experimental Staphylococcal Infections in Chickens." *Journal of Pathology and Bacteriology* 47 (1954): 81-87.
- Talaty, P. N., M. N. Katanbaf, and P. Y. Hester. "Life Cycle Changes in Bone Mineralization and Bone Size Traits of Commercial Broilers." *Poultry Science* 88.5 (2009): 1070-077.
- Thorp, B. H. "Pattern of Vascular Canals in the Bone Extremities of the Pelvic Appendicular Skeleton in Broiler Type Fowl." *Res. Vet. Sci.* 44 (1988): 112-23.
- Thorp, Barry H. "Skeletal Disorders in the Fowl: A Review." *Avian Pathology* 23.2 (1994): 203-36.
- Thorp, B. H., and D. Waddington. "Relationships between the Bone Pathologies, Ash and Mineral Content of Long Bones in 35-day-old Broiler Chickens." *Research in Veterinary Science* 62.1 (1997): 67-73.
- Thorp, B. H., C. C. Whitehead, L. Dick, J. M. Bradbury, R. C. Jones, and A. Wood. "Proximal Femoral Degeneration in Growing Broiler Fowl." *Avian Pathology* 22.2 (1993): 325-42.
- Trueta, J. "The Three Types of Acute Haematogenous Osteomyelitis." *The Journal of Bone and Joint Surgery* 41-B.4 (1959): 671-680.
- Vanderhoof, Jon A. "Probiotics: Future Directions." *The American Journal of Clinical Pathology* 73 (2001): 1152S-155S.
- Weeks, C. A., T. D. Danbury, H. C. Davies, P. Hunt, and S. C. Kestin. "The Behaviour of Broiler Chickens and its Modification by Lameness." *Applied Animal Behaviour Science* 67 (2000): 111-25.
- Weese, J. Scott. "Microbiologic Evaluation of Commercial Probioitcs." *Journal of the American Veterinary Medical Association* 220.6 (2002): 794-97.
- Wideman Jr., R. F., and I. Pevzner. "Dexamethasone Triggers Lameness Associated with Necrosis of the Proximal Tibial Head and Proximal Femoral Head in Broilers." *Poultry Science* (2012) (*in press*).

- Wideman, Jr., R. F., K. R. Hamal, J. M. Stark, J. Blankenship, H. Lester, K. N. Mitchell, G. Lorenzoni, and I. Pevzner. "A Wire-flooring Model for Inducing Lameness in Broilers: Evaluation of Probiotics as a Prophylactic Treatment." *Poultry Science* 91.4 (2012): 870-883.
- Zhu, Xiang Y., Robert E. Porter, Jr., and Patricia Y. Hester. "Delayed-Type Hypersensitivity Reaction Induced in Broilers via Trachea Inoculation of Killed *Staphylococcus Aureus*." *Poultry Science* 78 (1999): 1711-716.

