

# HIV Infection and Ocular Disease in South Africa



Erik Schaftenaar



# HIV Infection and Ocular Disease in South Africa

Erik Schaftenaar

HIV Infection and Ocular Disease in South Africa

ISBN: 978-94-6169-889-6

The research described in this thesis was conducted in part at the ophthalmology outpatient department of hospitals and at primary healthcare facilities within the Mopani District, Limpopo Province, South Africa and at the department of Viroscience, Erasmus Medical Center, Rotterdam, the Netherlands, and supported in part by Anova Health Institute, the Rotterdamse Stichting Blindenbelangen and the Rotterdam Global Health Initiative. Anova Health Institute receives a grant from the US President's Emergency Plan for AIDS Relief (PEPFAR) program via the US Agency for International Development under Cooperative Agreement [grant number AID-674-A-12-00015]. The views expressed in this thesis do not necessarily reflect those of PEPFAR or USAID. The funders had no role in study design, data collection and analysis, decision to publish, or preparation of the thesis.

Financial support for the design and printing of this thesis by the following companies is gratefully acknowledged: Blindenstichting voor Zuid-Afrika, Hetteema Heerema-leen, Orange Babies, Koninklijke Visio, AMO Netherlands B.V., Santen Pharmaceutical Co. Ltd., Théa Pharma and ZEISS.

Cover design by: Erik Schaftenaar, Tanja Bencun and Anthony Dalton.

Lay-out and printing: Optima Grafische Communicatie, Rotterdam, the Netherlands.

Photographs: Chapter 2-6, 8-9 and 11 by Erik Schaftenaar  
Chapter 7 by Vincent Schaftenaar, [www.joephography.nl](http://www.joephography.nl)  
Chapter 10 by Tanja Schaftenaar

© Erik Schaftenaar, 2016.

All rights reserved. No part of this publication may be reproduced, stored in a retrieval database or published in any form or by any means, electronic, mechanical or photocopying, recording or otherwise, without the prior written permission of the author.

# **HIV Infection and Ocular Disease in South Africa**

## **HIV infectie en oogziekten in Zuid-Afrika**

### **Proefschrift**

ter verkrijging van de graad van doctor aan de  
Erasmus Universiteit Rotterdam  
op gezag van de  
rector magnificus

Prof.dr. H.A.P. Pols

en volgens besluit van het College voor Promoties.

De openbare verdediging zal plaatsvinden op  
woensdag 21 september 2016 om 09.30 uur

door

**Erik Schaftenaar**  
geboren te Wageningen

**Erasmus University Rotterdam**

The logo of Erasmus University Rotterdam, featuring the word "Erasmus" in a stylized, cursive script.

## **PROMOTIECOMMISSIE**

Promotoren: Prof.dr. A.D.M.E. Osterhaus  
Prof.dr. G.M.G.M. Verjans  
Prof.dr. R.P.H. Peters

Overige leden: Prof.dr. C.A.B. Boucher  
Prof.dr. H.P. Endtz  
Prof.dr. J.C. van Meurs

**It always seems impossible until it's done**

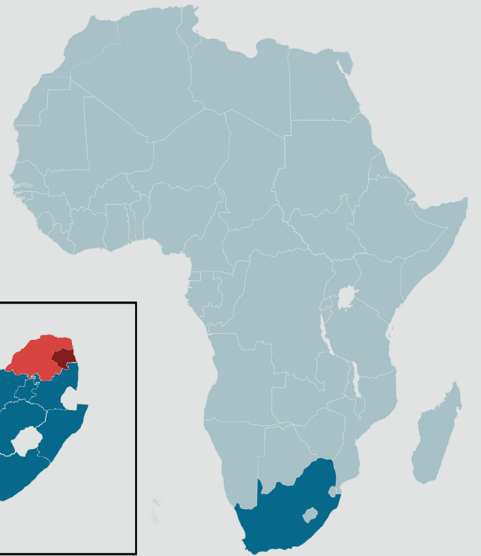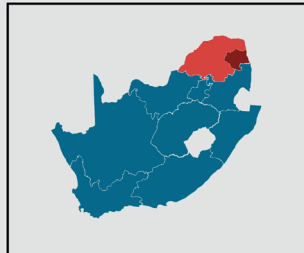
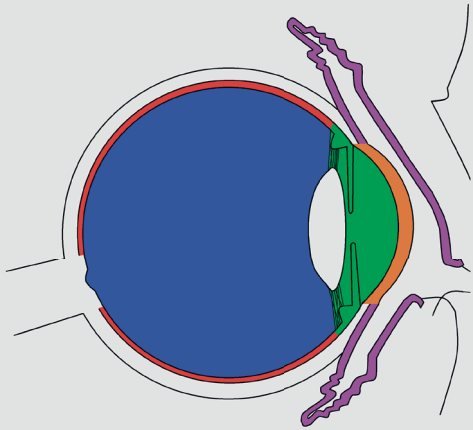
*Nelson Rolihlahla Mandela*





## TABLE OF CONTENTS

<b>Chapter 1</b>	General introduction In part based on: Ocular infections in sub-Saharan Africa in the context of high HIV prevalence. <i>Tropical Medicine and International Health, 2014.</i>	9
<b>Chapter 2</b>	High seroprevalence of human herpesviruses in HIV-infected individuals attending primary healthcare facilities in rural South Africa. <i>PloS One, 2014.</i>	37
<b>Chapter 3</b>	Clinical and corneal microbial profile of infectious keratitis in a high HIV prevalence setting in rural South Africa. <i>European journal of clinical microbiology &amp; infectious diseases, 2016.</i>	55
<b>Chapter 4</b>	Early- and late-stage ocular complications of herpes zoster ophthalmicus in rural South Africa. <i>Tropical Medicine and International Health, 2016.</i>	69
<b>Chapter 5</b>	Uveitis is predominantly of infectious origin in a high HIV and TB prevalence setting in rural South Africa. <i>British Journal of Ophthalmology, 2016.</i>	81
<b>Chapter 6</b>	Good visual outcome of tuberculous chorioretinitis after ART initiation in a HIV-infected patient. <i>International Ophthalmology, 2014.</i>	93
<b>Chapter 7</b>	HIV-infected individuals on long-term antiretroviral therapy are at higher risk for ocular disease. Submitted, 2016.	99
<b>Chapter 8</b>	Summarizing discussion In part based on: Anterior chamber paracentesis to improve diagnosis and treatment of infectious uveitis in South Africa. <i>South African Medical Journal, 2015.</i>	117
<b>Chapter 9</b>	Nederlandse samenvatting	141
<b>Chapter 10</b>	About the author Curriculum vitae PhD portfolio List of publications	153 155 157
<b>Chapter 11</b>	Dankwoord	161



# Chapter 1

## General introduction

In part based on:

Ocular infections in sub-Saharan Africa in the context of high HIV prevalence.

Erik Schaftenaar, Eric C.M. van Gorp, Christina Meenken, Albert D.M.E. Osterhaus, Lies Remeijer, Helen E. Struthers, James A. McIntyre, G. Seerp Baarsma, Georges M.G.M. Verjans and Remco P.H. Peters.

*Trop Med Int Health* 2014; **19**: 1003-14.



## 1. EYE DISEASE AND VISUAL IMPAIRMENT

Eye disease and its complications are a significant health problem worldwide that impact greatly on quality of life. Visual impairment, the main consequence of eye disease, is one of the most common and feared disabilities among human beings [1]. The World Health Organisation (WHO), based on the International Classification of Diseases (ICD-10) (**Table 1**), estimates that 285 million individuals are visually impaired worldwide of whom 39 million are blind [2-3]. Moreover, due to demographic trends such as increased longevity and population growth, the prevalence of visual impairment will most likely increase in the upcoming decades [1, 4-5].

The prevalence of visual impairment differs geographically with the developing world hit hardest. Ninety percent of visually impaired individuals live in low-resource countries and the relation between lower socioeconomic status and higher rates of visual disability is unequivocal [2, 6]. In sub-Saharan Africa, an estimated 26 million individuals live with visual impairment of whom 5.9 million individuals are classified blind [2]. For South Africa, the estimated national prevalence of visual impairment in individuals aged 50 years and above is 13.8%, but regional prevalence rates differ extensively [7]. For example, this reported national prevalence is much higher compared to a population based study from Cape Town in the same age group that reported a prevalence of 4.9%. The difference in prevalence observed in these studies suggests that visual impairment is a significant larger problem in rural compared to urban settings [8]. Lower socioeconomic status of individuals living in rural settings is most likely one of the main reasons for this difference, but other causes including different availability and accessibility of ophthalmic services, which are far more available and accessible in urban settings compared to rural settings may also play a role [6, 9-10].

Visually impaired individuals – as well as their families and communities – face serious social, educational, employment and economic challenges and visual impairment

**Table 1.** Classification of visual impairment and blindness according to the International Classification of Diseases [3].

Category	Presenting distance visual acuity	
	Worse than	Equal to or better than
0 Mild or no visual impairment		6/18
1 Moderate visual impairment	6/18	6/60
2 Severe visual impairment	6/60	3/60
3 Blindness	3/60	1/60 <sup>a</sup>
4 Blindness	1/60 <sup>a</sup>	Light perception
5 Blindness	No light perception	
9 Undetermined or unspecified		

<sup>a</sup>or counts fingers at 1 meter.

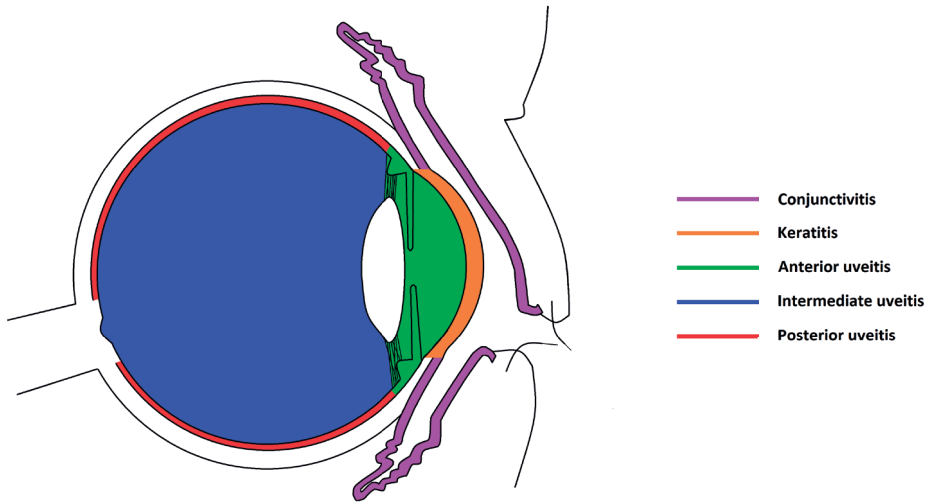
impacts substantially on the quality of life and increases the risk of death [10-12]. On a larger scale, visual impairment and blindness causes a considerable economic burden for the society and consequently put a major burden on healthcare resources, especially in developing countries where resources are already limited [13]. As 80% of all causes of visual impairment are preventable or curable if recognised early and managed promptly, improvement of eye care and prevention of visual impairment should be set a national health priority by governments, especially in low-resource countries where the burden of visual disability is disproportionately high [2, 6].

Globally, the main causes of visual impairment and blindness are uncorrected refractive errors and cataracts [2]. However, the spectrum of eye disease causing visual impairment and blindness differs geographically and is related to regional differences in human immunodeficiency virus (HIV) prevalence [14-15]. For sub-Saharan African countries, the coinciding high HIV prevalence contributes not only to the burden of visual impairment, but also increases the role of serious and sight-threatening eye infections [16-20].

## 2. INFECTIOUS DISEASES OF THE EYE

The human eye is the complex organ of vision that lies within the bony orbit of the skull. It contains three compartments: (1) the anterior chamber, (2) the posterior chamber and (3) the vitreous cavity. The eyeball consists of three concentric layers: (1) the outermost layer that consists of the clear *cornea* anteriorly and the opaque *sclera* posteriorly, (2) the middle highly vascular layer the *uvea*, which consists of the choroid, ciliary body and iris and (3) the innermost photosensitive layer the *retina* [21]. The eye is well protected against infections by a combination of mechanical, anatomical and immunological defence mechanisms [22]. Nonetheless, eye infections remain one of the most common diseases in ophthalmology, with conjunctivitis, keratitis and uveitis as the most common infections of the eye (**Figure 1**) [14, 22-27].

*Infectious conjunctivitis* ('red eye') is the inflammatory process of the conjunctiva, the thin vascular mucous membrane that consists of the bulbar conjunctiva, attached to the sclera and limbus of the cornea and the palpebral conjunctiva, which covers the inner surface of the eyelid. Infectious conjunctivitis is characterized by a red eye, cellular infiltration, vascular dilatation and exudation. Acute conjunctivitis is generally self-limiting or easily treated, although specific types of conjunctivitis such as infection with *Neisseria gonorrhoea* can cause blindness. *Infectious keratitis* is caused when pathogens breach the corneal defence mechanisms and infect the cornea. The cornea, a transparent avascular protective membrane, is the most important refractive medium of the eye. Corneal infection, and subsequent corneal opacification and scarring, can



**Figure 1.** Overview of the anatomic distribution of the most common infectious eye diseases [28].

lead to severe visual impairment and ultimately blindness. This condition, along with ocular trauma, are considered the most common cause of visual disability and unilateral blindness in sub-Saharan Africa and has been called ‘the silent epidemic’ that warrants more attention due to its serious impact on population health [14, 24, 27, 29]. *Uveitis* refers to intraocular inflammation of the iris, ciliary body, vitreous, retina or choroid. The disease is classified by the International Uveitis Study Group into anterior, intermediate and posterior uveitis dependent on the segment affected or panuveitis when all segments are inflamed [30]. The visual impact of uveitis depends on the part of the eye that is affected. In sub-Saharan Africa, uveitis is an important cause of visual impairment and blindness [31]. The aetiology of uveitis is diverse and includes infectious and non-infectious causes. Data from the African continent are limited, but suggest that pathogens may play an important role in uveitis [31-32].

Ocular infections can be of viral, bacterial, fungal and/or protozoan origin. The likelihood of a specific pathogen largely depends on the ocular tissue affected (**Table 2**).

## 2.1 Virus infections of the eye

A genetically diverse group of viruses, including DNA (e.g. *Herpesviridae*) and RNA (e.g. *Togaviridae*) viruses, is able to cause a wide variety of ocular disease including blepharitis, conjunctivitis, keratitis and uveitis [33]. Especially viruses of the *Herpesviridae* family are important pathogens in ophthalmology as they are endemic worldwide and able to cause devastating recrudescence ocular disease [33].

Human herpesviruses (HHVs) are members of the *Herpesviridae* virus family, a large family of double-stranded DNA enveloped viruses [34]. Members of this family are

**Table 2.** Distribution of pathogenic microorganisms causing eye infections in sub-Saharan Africa [28].

Condition	Pathogenic microorganism	
<b>Conjunctivitis</b>	Viruses	No data available on distribution
	Bacteria	<i>Chlamydia trachomatis</i>
		<i>Neisseria gonorrhoea</i>
		<i>Staphylococcus aureus</i>
		<i>Streptococcus pneumonia</i>
		<i>Staphylococcus albus</i>
<i>Haemophilus influenzae</i>		
<b>Keratitis</b>	Viruses	Varicella-zoster virus
		Herpes simplex virus
	Bacteria	<i>Pseudomonas aeruginosa</i>
		<i>Escherichia coli</i>
		<i>Streptococcus pneumonia</i>
		<i>Staphylococcus aureus</i>
		<i>Staphylococcus albus</i>
	Fungi	Filamentous fungi
	Protozoa	<i>Onchocerca volvulus</i>
		<i>Acanthamoeba sp.</i>
<b>Uveitis</b>	Viruses	Herpes simplex virus
		Varicella-zoster virus
		Cytomegalovirus
	Bacteria	<i>Mycobacterium tuberculosis</i>
		<i>Treponema pallidum</i>
	Protozoa	<i>Toxoplasma gondii</i>
		<i>Onchocerca volvulus</i>

classified into three subfamilies based on genomic and biological properties: *Alpha-herpesvirinae*, *Betaherpesvirinae* and *Gammaherpesvirinae* [35]. Today, nine HHVs have been identified: herpes simplex virus 1 (HSV-1), herpes simplex virus 2 (HSV-2), human cytomegalovirus (CMV), varicella-zoster virus (VZV), Epstein-Barr virus (EBV), *Human herpesviruses 6A, 6B, 7*, (HHV-6A, HHV-6B and HHV-7) and Kaposi's sarcoma-associated herpesvirus (HHV-8) (**Table 3**) [35].

Whereas primary infection HHVs are commonly asymptomatic, localised or systemic disease may occur. Independent of clinical outcome, primary HHV infection will result



**Table 3.** Human herpesviruses [35].

Designation	Common Name	Subfamily <sup>a</sup>	Eye manifestation <sup>b</sup>
Human herpesvirus 1	Herpes simplex virus type 1	α	Blepharitis, conjunctivitis, keratitis and uveitis
Human herpesvirus 2	Herpes simplex virus type 2	α	Keratitis, uveitis and congenital cataract
Human herpesvirus 3	Varicella-zoster virus	α	Herpes zoster ophthalmicus, keratitis and uveitis
Human herpesvirus 4	Epstein-Barr virus	γ	Conjunctivitis, keratitis and uveitis
Human herpesvirus 5	Human cytomegalovirus	β	Uveitis
Human herpesvirus 6		β	Optic neuritis and uveitis
Human herpesvirus 7		β	Unknown
Human herpesvirus 8	Kaposi's sarcoma virus	γ	Conjunctival Kaposi sarcoma

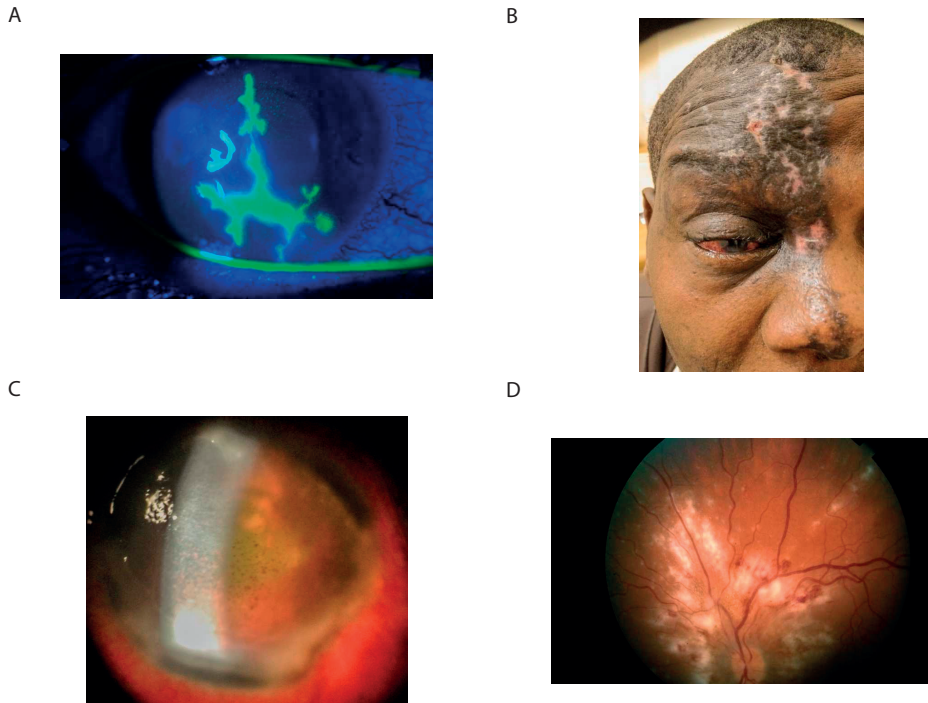
<sup>a</sup> α: *alphaherpesvirinae*; β: *betaherpesvirinae* and γ: *gammaherpesvirinae*.

<sup>b</sup> Most common eye manifestations caused by the respective herpesvirus.

in a lifelong latent infection in neurons (*Alphaherpesvirinae*) or lymphocytes (*Betaherpesvirinae* and *Gammaherpesvirinae*) and reactivate from latent infection resulting in a symptomatic shedding of the virus or occasionally causing recrudescence disease [33, 35-37]. The mechanisms that lead to reactivation after asymptomatic latency are largely unknown, but immunosenescence due to therapy, disease or ageing play a role [35, 38]. High seroprevalence of HHVs is found in humans worldwide, but data from South Africa are unavailable [39]. HHVs can cause a wide variety of benign (HHV-6 and 7) and even malignant disease (EBV and HHV-8) [33, 36-37]. HSV-1, VZV and CMV are the most common viral causes of infectious ocular disease worldwide [33, 40].

HSV-1 is transmitted following contact with an active herpetic lesions or an individual shedding virus asymptotically [41]. Primary infection occurs usually during early childhood via the orofacial route and rarely causes clinical manifestations [41-41]. After primary infection, viral latency is established in sensory neurons (i.e. trigeminal and/or sacral ganglia) and thereafter HSV-1 may reactivate intermittently to cause asymptomatic virus shedding and/or recurrent orofacial and ocular lesions [41-41]. The spectrum of eye diseases caused by HSV-1 is diverse and includes blepharitis, conjunctivitis, keratitis and uveitis [40, 43]. Recrudescence HSV-1 keratitis, occasionally accompanied with corneal opacification and scarring, is the most common eye complication and the leading cause of infectious corneal blindness in developed countries (**Figure 2A**) [40, 44]. Whereas data from South Africa are limited, the impact of the disease is expected to be high due to limited access to targeted treatment [44].

VZV infection causes two clinically distinct diseases: varicella (chickenpox) and herpes zoster (shingles) [45]. Varicella, result of primary VZV infection, is usually benign and occurs predominantly in children. It is characterised by a vesicular exanthema and usu-



**Figure 2.** Clinical presentation of herpesvirus-induced eye diseases. **(A)** Typical dendritic lesion of the cornea in herpes simplex keratitis. **(B)** Herpes zoster ophthalmicus of the right side of the face with hyperaemia of the conjunctiva and keratouveitis. **(C)** Anterior uveitis with localized stromal oedema, keratic precipitates and cells and flare in the anterior chamber due to infection with varicella-zoster virus. **(D)** Posterior uveitis (retinitis) with retinal bleeding and necrosis due to infection with cytomegalovirus.

ally accompanied by fever [45]. Following primary infection, VZV establishes a latent infection in both trigeminal and the majority of dorsal root ganglia [46]. After a period of latency, reactivation leads to herpes zoster, a painful localised vesicular rash [45]. Reactivation of latent VZV located within the ophthalmic division of the innervating trigeminal nerve causes herpes zoster ophthalmicus (HZO) (**Figure 2B**) [47]. HZO represents up to a quarter of all cases of herpes zoster [47-48]. If left untreated, eye involvement occurs in >50% of HZO patients causing high visual morbidity (**Figure 2C**) [47-49]. HZO-associated eye diseases include conjunctivitis, scleritis, keratitis, uveitis, optic neuritis, ocular cranial-nerve palsies, neuralgia and eyelid deformities [47, 50-51]. The burden of HZO in sub-Saharan African countries is high, mainly due to the high HIV prevalence and limited access to appropriate anti-viral treatment [52]. HIV-infected individuals have a higher risk of developing HZO (>15-times higher) compared to HIV-uninfected individuals and have a higher incidence and severity of HZO-associated eye diseases [53-54]. Data from South Africa suggest that an increasing proportion of younger HIV-infected patients are affected by HZO [52].

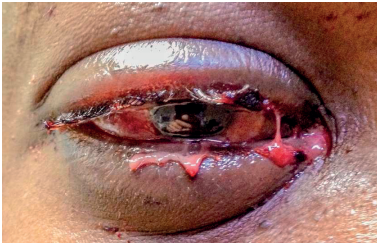CMV infection may occur congenitally causing serious neurological and/or post-natal disabilities of infected babies [55]. After primary infection, CMV persists in hematopoietic progenitor cells and its replication is tightly controlled by the immune system [56]. In case of immunodeficiency, CMV viraemia and virus dissemination can occur [57]. Disseminated CMV infection may cause full thickness retinitis resulting into retinal necrosis and irreversible blindness, but other less severe eye manifestations like corneal endotheliitis may also occur (**Figure 2D**) [57-58]. The estimated prevalence of CMV retinitis among HIV-infected individuals initiating antiretroviral therapy (ART) in sub-Saharan Africa ranges from 0 to 5%, but several studies suggest that this may be an underestimation [59-61]. The only available study from South Africa reports a low prevalence of CMV retinitis among HIV-infected individuals (1.3%), but reasons for this low prevalence remain unclear [62].

## 2.2 Bacterial eye infections

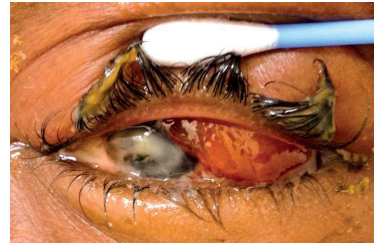Bacteria can be classified according to their cell wall as Gram-positive or Gram-negative. Both Gram-positive (e.g. *Staphylococcus aureus* and *S. albus*) and Gram-negative (e.g. *Pseudomonas aeruginosa* and *Escherichia coli*) bacteria are prevalent causes of eye infections, in particular infectious conjunctivitis and keratitis (**Figure 3A-C**) [63-64]. Studies on the prevalence and spectrum of bacterial eye infections in South Africa are unavailable, but one specific bacterium warrants specific attention due to its high prevalence in South Africa and the high coinciding prevalence with HIV infection: *Mycobacterium tuberculosis*.

*M. tuberculosis* is an aerobic, intracellular, acid-fast bacillus that causes tuberculosis (TB). *M. tuberculosis* is highly prevalent in South Africa. In year 2013, this country had the third highest number of TB incident cases globally: 410,000–520,000 cases/year [65]. Approximately 62% are co-infected with HIV, which has a destructive effect on TB progression and is associated with higher reactivation and recurrence rates [66]. Tuberculosis is primarily transmitted through inhalation of *M. tuberculosis* containing aerosols [66]. During primary infection, *M. tuberculosis* can be eliminated immediately, cause immediate onset of active disease (primary disease) and/or will establish a lifelong latent infection. The stage of TB infection is in part determined of the host's immune system [66-67]. Reactivation may occur several years later due to deprived immunity associated with co-morbidities like HIV co-infection [66-67]. Tuberculosis is a major cause of morbidity worldwide and predominantly affects the lungs, but can cause disease in many human organs including the brain, ileum and eyes [66]. The bacterium may reach the eye following haematogenous dissemination from pulmonary or extrapulmonary sites, per direct ocular infection or cause ocular disease, especially choroiditis, via an allergic/hypersensitivity reaction incited by *M. tuberculosis*. Ocular TB diseases, including interstitial keratitis and uveitis (**Figure 3D**), cause significant eye morbidity in endemic countries, particularly in settings with high HIV prevalence [68-69].

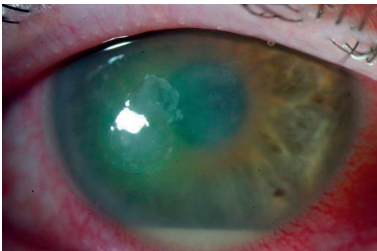A



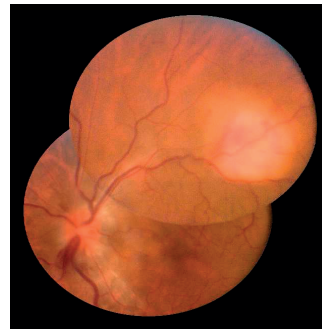B



C



D



**Figure 3.** Clinical presentation of bacterial eye diseases. **(A)** Bacterial conjunctivitis accompanied by conjunctival chemosis with profuse, hyperacute purulent discharge due to infection with *Neisseria gonorrhoeae*. **(B)** Bacterial keratoconjunctivitis accompanied by severe conjunctival chemosis and swelling of the upper eyelid with mucopurulent discharge and severe corneal ulceration with corneal perforation due to *Staphylococcus aureus*. **(C)** Corneal ulceration with hypopyon and hyperaemia of the conjunctiva due to *Pseudomonas aeruginosa*. **(D)** A chorioretinal granuloma, papilledema, retinal vasculitis and mild vitritis due to *Mycobacterium tuberculosis*.

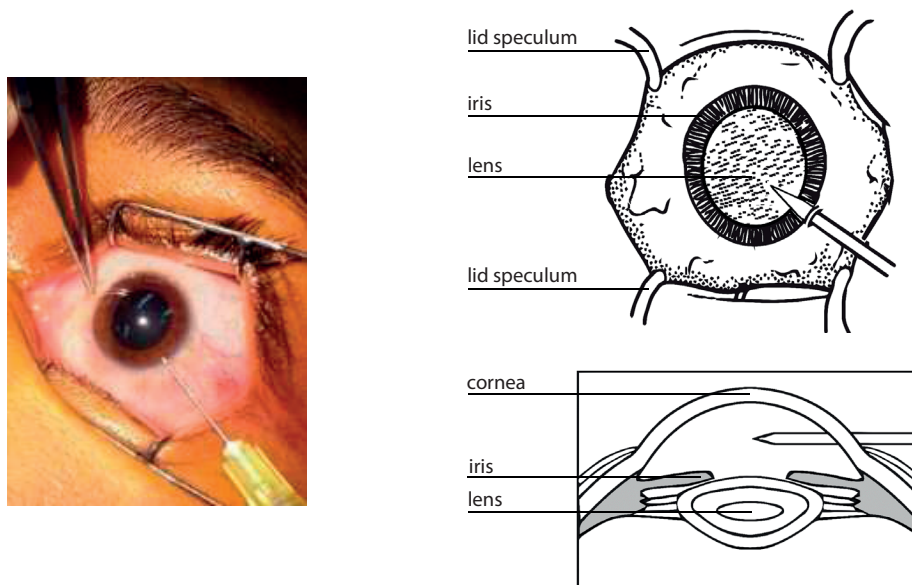
### 2.3 Laboratory diagnostics in eye infections

Ocular infections, untreated or inappropriately treated, may lead to serious eye complications including visual impairment and blindness. Early diagnosis and subsequent initiation of adequate antimicrobial treatment is of paramount importance for good visual outcome [70-71]. Although initiation of empirical treatment based on patient's history and clinical characteristics might be feasible in some cases, misdiagnosis may occur when different pathogens present with similar clinical characteristics leading to devastating visual outcomes. Therefore, antimicrobial treatment must be initiated or altered on the basis of both clinical and microbiological evaluation and subsequent clinical response to therapy. A wide range of investigative modalities are available that supplement clinical diagnosis that provide supportive evidence for disease management.

Conventional microbiological examination of clinical samples obtained from the site of ocular infection (e.g. microscopy of stained cornea/conjunctival smears and culture for suspected bacteria and viruses) are often performed to determine the causative pathogen [72]. Whereas bacterial conjunctivitis cases are usually self-limiting or respond well to broad-spectrum antibiotics, certain clinical characteristics and cases require further investigation for determination of the alternative pathogen involved as additional treatment is needed [73]. For example, hyperacute purulent discharge and eyelid oedema may indicate involvement of *N. gonorrhoeae*, a sexually transmitted pathogen that requires additional systemic therapy [73]. Swabbing or scraping the site of the corneal infiltrate or ulcer should be performed to diagnose infectious keratitis. Thorough microscopic examination of ocular tissue or fluid specimens (e.g. bacterial Gram staining or virus antigen-specific immunocytology) may provide rapid identification of the pathogen involved, but further culture and subsequent drug sensitivity testing of the bacterium or virus may be necessary for adjusted treatment options. Whereas Gram staining is used to demonstrate the presence of bacteria, fungi and parasites, potassium hydroxide wet mounts are recommended to identify bacterial and fungal elements [72]. Microbial culture should be performed in both bacterial and fungal media, which should be examined for growth daily and incubated for >2 weeks [72]. If bacteria are grown, subsequent drug susceptibility testing is optional to determine the most effective antibiotic treatment. Microscopic examination and microbial culture of intra-ocular samples (e.g. vitreous fluid or retinal biopsy) are rarely used, but might be helpful to distinguish between infectious and non-infectious causes of uveitis. Especially in cases who are refractory to treatment [74-75].

Although confirmation by microscopic examination and microbial culture remains the gold standard to identify the triggering pathogen in most microbial eye infections, these assays are time consuming and have a low sensitivity leading to delayed or even false negative diagnosis, respectively [72, 76]. Molecular diagnostic utilities, particularly polymerase chain reaction (PCR) analysis are rapid (hours instead of days/weeks), specific and more sensitive [72, 76]. PCR analysis are commonly performed on nucleic acids isolated from corneal swabs or scrapings of keratitis patients, and in case of uveitis aqueous humour or vitreous fluid (**Figure 4**). Specific primer/probe sets have been designed to detect the majority of ocular disease inducing viruses with high specificity and sensitivity [77-79].

Only few laboratory tests have additional value in the diagnostic process of eye infections [81-82]. Serological analysis may be helpful if ocular syphilis or toxoplasmosis is suspected as the clinical picture in these conditions is most often atypical. Clinical diagnosis can therefore be confirmed by serological detecting of antibodies against *Treponema pallidum* or *Toxoplasma gondii* [81, 83]. A supplementary test to PCR is detection of local antibody production to the triggering pathogen. This includes quantitative



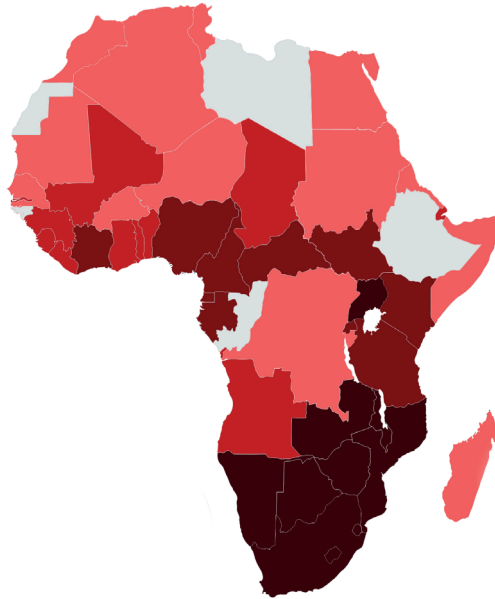
**Figure 4.** Photograph and schematic overview of anterior chamber paracentesis for the aspiration of aqueous humour [80].

total IgG and pathogen-specific IgG testing in the intra-ocular fluid and paired serum. Local intra-ocular antibody production, defined as Goldmann-Witmer coefficient (GWC), has shown its additional diagnostic value diagnosing patients with infectious uveitis [71]. Whereas pathogen-specific nucleic acids commonly become undetectable 2 weeks after the onset of disease, specific antibodies remain detectable for many weeks in intra-ocular fluid. PCR and GWC are therefore complementary and contribute considerably to the differential diagnosis of infectious uveitis [71].

### 3. HIV AND THE EYE

#### 3.1 Virology and clinical disease

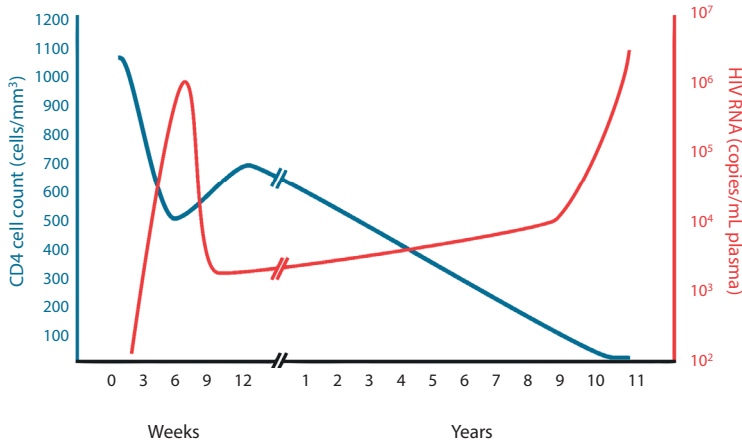
HIV is a member of the family *Retroviridae*, subfamily *Lentivirinae* and genus *Lentivirus* [84]. HIV can be divided into two major types: HIV type 1 (HIV-1) and type 2 (HIV-2). HIV-1 is the most pathogenic and most prevalent HIV type worldwide, whereas HIV-2 is restricted to western Africa [84]. Hereafter 'HIV' refers to HIV-1 unless stated otherwise. Sub-Saharan Africa is highly affected by the epidemic of HIV with an estimated 25.8 million HIV-infected individuals in 2014 (**Figure 5**) [85]. South Africa has the largest HIV epidemic worldwide, with an estimated 6.8 million HIV-infected individuals and an HIV prevalence of 18.9% in adults aged between 15 to 49 years old [86].



**Figure 5.** Estimated HIV prevalence among adults (15–49 years) in African countries [86]. Note. This figure is based on the most recent data from the UNAIDS (Joint United Nations Programme on HIV/AIDS). Intensity red colour of countries refers to the HIV prevalence. Countries with the lightest colour have a prevalence rate of <0.1% and countries with the darkest colour a prevalence rate of 10.6% to 27.7%. Countries with no HIV prevalence data available are in grey.

HIV targets several human cells including CD4 T-cells, macrophages and dendritic cells [84, 87]. Untreated HIV infection leads to high viremia and subsequent depletion of CD4 T-cells causing immunodeficiency (**Figure 6**) [87]. In the advanced stage of the disease, HIV-infected individuals are at increased risk to develop opportunistic infections and tumours. Advanced immunodeficiency will lead to death [87-88].

Currently there is no cure for HIV, but available ART has made HIV infection a treatable chronic viral disease [89]. ART consists of a combination of drugs that target the HIV life cycle in order to stop HIV replication [88]. In South Africa, the first line treatment of HIV in all new patients is the combination of a nucleotide reverse transcriptase inhibitor (Tenofovir), a nucleoside reverse transcriptase inhibitor (Emtricitabine) or cytosine analogue (Lamivudine) and a non-nucleoside reverse transcriptase inhibitor (Efavirenz), preferably in a fixed dose combination which became available in South Africa in April 2013 [90]. Initiation of ART results in prolonged disease-free survival, reduced viremia, immunologic repletion of CD4 T-cells and reductions in hospitalization and mortality [91-94]. Early start of ART before the CD4 T-cell counts drops below 200 cells/ml, results in a near-normal quality of life and life expectancy in HIV-infected adults [93-94]. In South Africa, the ART eligibility criteria are constantly adapted to new insights. Until 2015, lifelong ART was initiated in adults if CD4 T-cell counts was  $\leq 350$  cells/mm<sup>3</sup> or in



**Figure 6.** The course of untreated HIV infection defined by the dynamic changes in CD4 T-cell count (blue line) and plasma viremia (red line). Primary infection is characterised by high plasma viremia and a rapid drop of CD4 T-cells. Viremia decreases dramatically after several weeks due to development of virus-specific CD8 T-cells and antibody secreting B-cells. At the same time, the CD4 T-cell counts rebound. The immune system slowly deteriorates due to chronic HIV infection with the number of CD4 T-cells decreasing and concurrent increase of viremia [87].

adults with severe HIV disease (WHO stage 3 or 4) irrespective of the CD4 T-cell count [90]. Although recent insights show benefits of ART initiation directly after confirmed diagnosis of HIV infection in all individuals regardless of their CD4 T-cell count, the current South African guideline uses a CD4 T-cell threshold of  $\leq 500$  cells/mm<sup>3</sup> [95-96]. Unfortunately, despite recent scale-up of ART services, estimated ART coverage in South Africa is still low, especially in rural settings [86]. As a result, many patients are initiated at low CD4 T-cell counts putting them at increased risk for disease for HIV related conditions including ocular diseases.

### 3.2 Eye disease associated with HIV

Eye disease and its complications occur in 50-75% in HIV-infected individuals at some point during the course of their illness and are strongly associated with level of immunodeficiency; an eye disease might even be the first clinical sign of HIV infection [54, 59]. The clinical spectrum of eye disease in HIV-infected individuals is extensive and most ocular tissues can be affected (**Table 4**) [97-98]. HIV-associated eye diseases are categorised into four groups: (1) eye infections, (2) unusual malignancies, (3) vascular and metabolic eye disease and (4) neuro-ophthalmic disease. As the spectrum of eye disease in HIV is extensive, only the most common and important presentations will be discussed.

In resource-poor settings, eye infections are the most common and devastating HIV-associated ocular diseases: mainly infectious keratitis and uveitis [98]. Infectious keratitis is usually due to VZV or HSV-1 causing recrudescence of keratitis due to viral reactivation al-



**Table 4.** Eye conditions associated with HIV [98-99].

Site of condition	Condition
<b>External eye (adnexal and orbital)</b>	Orbital cellulitis due to <i>Aspergillus</i> spp. infection Non-Hodgkin's lymphoma Herpes zoster ophthalmicus Molluscum contagiosum of the eyelid Kaposi's sarcoma of eyelid and conjunctiva Keratoconjunctivitis sicca Squamous cell carcinoma of conjunctiva Conjunctival microvasculopathy
<b>Anterior segment</b>	Infectious keratitis Anterior uveitis
<b>Posterior segment</b>	Endophthalmitis due to <i>Candida</i> spp. infection Cytomegalovirus retinitis Syphilis retinitis Acute retinal necrosis Progressive outer retinal necrosis Pneumocystis choroiditis Tuberculous chorioretinitis Toxoplasmic chorioretinitis HIV retinopathy
<b>Neuro-ophthalmic</b>	Neurosyphilis Cryptococcal meningitis Toxoplasmosis of central nervous system Lymphoma of central nervous system

though bacterial and fungal keratitis also occurs. HIV-induced immunosuppression not only results in higher recurrence rates of VZV or HSV-1 keratitis, but also causes a more severe clinical course leading to significant ocular morbidity [59, 97, 99-100]. In addition, HZO warrants special attention as it is a strong marker for HIV infection in individuals <40 years of age [54]. Early recognition and testing for HIV can prevent serious ocular complications by initiation of oral and topical antiviral treatment as well as initiation of ART if required. Infectious uveitis can be caused by a wide variety of pathogens and geographic differences are described. In Western countries, CMV retinitis is still the most common cause of eye disease before the initiation of ART. In the pre-ART era, up to 40% of HIV-infected individuals had CMV retinitis, typically when CD4 T-cell counts were below 50 cells/mm<sup>3</sup> [59, 97]. In sub-Saharan Africa, CMV retinitis is relatively uncommon, occurring in <5% of HIV-infected individuals [31, 101]. In contrast to developed countries, TB is considered the most important opportunistic infection in HIV-infected individuals in sub-Saharan Africa. Ocular morbidity caused by *M. tuberculosis* is therefore expected to be high in sub-Saharan Africa. Disease manifestation in HIV-infected individuals is usually atypical compared to non-infected persons, making it difficult to diagnose the disease leading to undertreatment [67, 102-104].

Despite their minimal impact on vision, two HIV-associated ocular malignancies warrant attention in sub-Saharan Africa: (1) squamous cell carcinoma of the conjunctiva

(SCCC) and (2) Kaposi's sarcoma (KS). SCCC is a cancer of the epithelial surface of the eye that has become more common in sub-Saharan Africa, particular in young individuals and more aggressive due to the HIV epidemic [105]. The incidence of SCCC in sub-Saharan Africa is currently 3.4 cases per 100,000 men/year [105]. HIV infection is a major risk factor for the development of SCCC and is associated with a higher recurrence rate after treatment [105-108]. KS, a painless mesenchymal tumour, is also strongly associated with HIV infection [98, 108-109]. KS affects the skin and mucous membranes and is caused by HHV-8 infection [98, 109-110]. Ocular KS mainly involves the eyelids and conjunctiva [110]. In sub-Saharan Africa, KS is considered the most frequently HIV-associated malignancy, however geographic differences have been reported [111]. A study among HIV-infected individuals on ART in South Africa reported the KS incidence rate is substantial: 138/100,000 person-years [111].

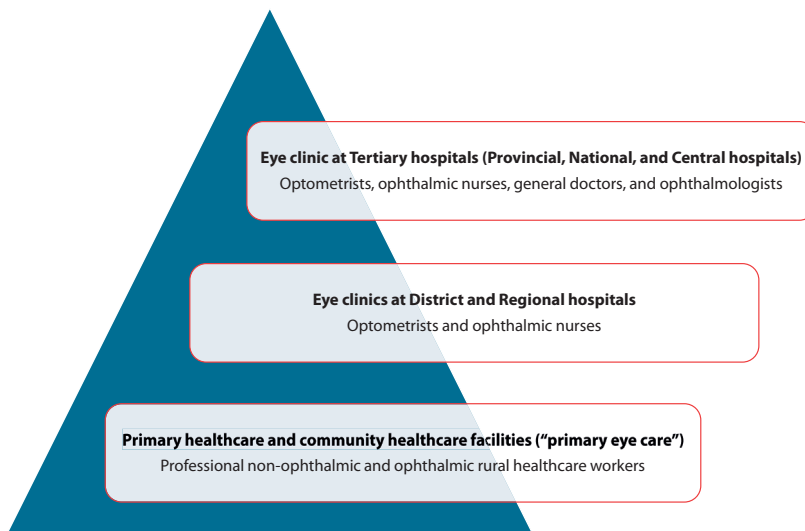
Vascular and metabolic complications of HIV in the eye are very common affecting up to 70% HIV-infected individuals, but normally causes only mild visual impairment [59, 97, 112]. Microvascular changes due to HIV affect several tissues of the eye including the conjunctiva, optic disc and the retina. HIV retinopathy is the most common vascular complication [97, 112]. HIV retinopathy is a retinal microvasculopathy characterised by cotton-wool spots (i.e. infarcts of the nerve fibre layer), intraretinal haemorrhages and retinal microaneurysm [112-113]. The pathogenesis of HIV retinopathy remains largely unknown, but haemorrhagic abnormalities like increased plasma viscosity and circulating HIV-specific immune-complexes are involved [112-113]. Analogous to other HIV-associated eye diseases like CMV retinitis, HIV retinopathy tends to occur more often in advanced HIV infection when the CD4 T-cell counts drop below 100 cells/mm<sup>3</sup> [97, 101].

The introduction of ART has resulted in a decrease in the incidence of most eye diseases, especially CMV retinitis [114-115]. However, ART also led to an increase of eye conditions such as ocular immune reconstitution inflammatory syndrome (IRIS), a common and serious short-term complication that may develop 8-16 weeks following ART initiation and usually manifests as uveitis referred to as immune recovery uveitis (IRU) [116]. The incidence of IRU in South Africa is unknown, but estimates suggest a prevalence ranging from 0.11 to 0.83 per person/year with a reported point prevalence up to 20% among HIV-infected individuals who develop ART-mediated IRIS [117]. Although available studies, predominately performed in developed countries, showed a strong association with a history of CMV infection, other pathogens such as HSV-1, VZV and *M. tuberculosis* may also play a role in the development of IRU [118-121]. Important risk factors for developing IRU include low CD4 T-cell counts at baseline before ART initiation and fast onset of retroviral suppression [116]. Alternatively, long-term complications of ART led to a rise of metabolic and vascular causes of ocular disease such as cataract and hypertensive retinopathy, which are considered serious complication of HIV infection and ART therapy [114-115].

#### 4. EYE CARE IN SOUTH AFRICA

Eye care is provided at all healthcare levels in South Africa with primary eye care (PEC) as the cornerstone. PEC involves eye care rendered by professional, non-ophthalmic or ophthalmic, rural healthcare workers [122]. The idea of PEC was primarily founded to reduce the two most important causes of blindness in developing countries: vitamin-A deficiency and trachoma. Currently, PEC is an efficient and beneficial way of reaching rural communities and plays a crucial role in primary healthcare in South Africa [122-123]. PEC is based at primary healthcare (PHC) and community healthcare (CHC) facilities with referral to the eye clinic at the local hospital (**Figure 7**). In rural settings, eye units at these hospitals are run by optometrists and specialized ophthalmic nurses [124-125]. As such, the PHC/CHC facility is the first point of eye care for many patients. However, PEC faces a large number of challenges and the quality of eye care in the primary healthcare setting varies extensively.

In general, the status of public eye care in South Africa is poor and contrasts the private sector in South Africa and that of public eye care in Western countries, but the quality varies considerably between urban and rural areas. For example, ophthalmologists are mainly concentrated in urban areas leaving rural communities far away from the highest quality of eye care professionals [123]. Effective eye care depends on many factors with the availability of budget, essential resources and drugs, human resources and referral and mobility options as most important. Data from South Africa are limited with regard to eye services at PHC level and referral hospitals, especially in rural settings

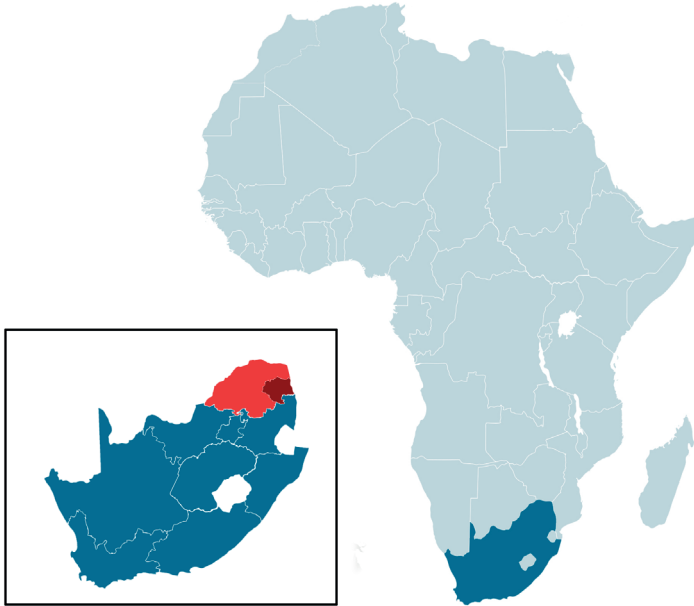


**Figure 7.** Eye care pyramid in South Africa.

[124]. Available data from sub-Saharan African countries reported poor eye care quality, with limited practitioners-to-patient ratios, inadequate resources, inaccessible services, poor state funding and a lack of educational programs as major causes [126]. To improve the quality of eye care and to eliminate avoidable blindness, a global initiative was initiated in 1999 by the WHO and the International Agency for the Prevention of Blindness (Vision 2020: the right to sight) [127]. This program provided a paradigm shift in the way of thinking from individual patient to population care and impressive achievements in eye care provision were reported [128]. Vision 2020 was updated in 2013 by the WHO Global Action Plan 2014-19 (Towards Universal Eye Health) with the goal to reduce avoidable visual impairment as a global public health problem and to secure access to rehabilitation services for the visually impaired individuals [129]. The target was set on the reduction in prevalence of avoidable blindness and visual impairment by 25% by 2019 through (1) data collection on prevalence of visual impairment, (2) training of more eye care professionals, (3) provision of comprehensive eye care and (4) elimination of social and economic obstacles. Although South Africa takes part in the WHO Global Action Plan activities, eye care in South Africa still faces many challenges, especially in rural settings where the burden of eye disease is highest [Schaftenaar E; unpublished data]. Lack of ophthalmological expertise and skills, essential resources, ophthalmic drugs and referral systems are major challenges in rural settings that stress the need of urgent in-depth health system strengthening [Schaftenaar E; unpublished data].

## 5. STUDY SETTING

All studies included in this thesis were conducted in South Africa, with the rural Mopani District of the Limpopo Province as the cornerstone (**Figure 8**). Mopani District is one of the national priority districts on basis of poor quality of healthcare and high rates of poverty, illiteracy and unemployment and it has one the highest HIV prevalence rates (24.6% among pregnant women in 2013) in South Africa [130]. To provide public healthcare services, 100 nurse-managed PHC facilities are available throughout the district. These facilities refer to six district hospitals and one regional hospital. Currently, rapid scale-up of health services including services for eye care is ongoing. However, eye care will remain limited to specialist nurses working in few PHC facilities and in most hospitals. The only available ophthalmologists in public care are outside the Mopani District at the tertiary referral hospital of Mankweng (Capricorn District, Limpopo Province). However, due to logistic and operational challenges and high workload, referral to specialist care is extremely challenging and frequently problematic.



**Figure 8.** Map of Africa with South Africa (dark blue), Limpopo Province (light red) and Mopani District (dark red) highlighted.

## 6. AIM AND OUTLINE OF THIS THESIS

The burden of eye disease in South Africa is considered high, but limited data are available. The aim of the studies presented in this thesis was to provide novel insight into the clinical field of ophthalmology in a high HIV prevalence setting in rural South Africa to improve clinical care and visual outcome of patients affected by HIV-associated eye diseases. To determine the burden of eye diseases and its relation with HIV infection, this thesis focusses on the most important HIV-associated eye infections (keratitis and uveitis) and the effects of chronic HIV infection and ART use.

To obtain insight in the potential burden of HHV-related eye diseases, we determined the seroprevalence of HHVs in HIV-infected ART-naïve individuals in the rural Mopani district in **Chapter 2** and identified risk factors associated with the HHV seropositive status. **Chapter 3** and **Chapter 5** describe two cross-sectional studies on the microbiological aetiology and clinical manifestations of infectious keratitis and uveitis. Both ocular disease entities are well known to cause significant visual morbidity, but data from rural settings with high HIV prevalence have been unavailable. The aim of both studies was to determine the prevalence and clinical manifestations of different pathogens involved and to identify clinical data to improve future diagnosis and management of these conditions. **Chapter 4** expands on both studies and reports on the spectrum of ocular complications of VZV infection as we observed a high number of HZO cases with

late ocular complications during the course of these cross-sectional studies. This HZO study provides clinical data and recommendations for healthcare workers to improve management and outcome of disease. Moreover, it highlights the important role of HIV co-infection to prevent future ocular complications and ensure adequate testing and counselling for HIV in HZO cases. **Chapter 6** describes a case of tuberculous chorioretinitis in a HIV-infected adult after recent initiation of ART in rural South Africa that was most likely IRIS-associated. Ocular IRIS is a well-known phenomenon after ART initiation, but is frequently missed in rural settings. This case report stresses the importance of early detection and treatment of ocular immune reconstitution inflammatory syndrome and the role of *M. Tuberculosis* in eye infections. The study described in **Chapter 7** determined the occurrence and severity of ocular diseases in HIV-infected individuals on ART and indicates that regular ophthalmological monitoring of these individuals is warranted to prevent a future large burden of visual impairment.

## 7. REFERENCES

1. Rosenberg EA and Sperazza LC. The visually impaired patient. *Am Fam Physician* 2008; **77**: 1431-6.
2. Pascolini D and Mariotti SP. Global estimates of visual impairment: 2010. *Br J Ophthalmol* 2012; **96**: 614-8.
3. World Health Organization. International Statistical Classification of Diseases and Related Health Problems 10th Revision 2016. Available at: <http://apps.who.int/classifications/icd10/browse/2016/en#/H53-H54>.
4. Bourne R, Price H and Stevens G. Global burden of visual impairment and blindness. *Arch Ophthalmol* 2012; **130**: 645-7.
5. Frick KD and Foster A. The magnitude and cost of global blindness: an increasing problem that can be alleviated. *Am J Ophthalmol* 2003; **135**: 471-6.
6. Dandona R and Dandona L. Socioeconomic status and blindness. *Br J Ophthalmol* 2001; **85**: 1484-8.
7. Freeman EE, Roy-Gagnon MH, Samson E, et al. The global burden of visual difficulty in low, middle, and high income countries. *PLoS One* 2013; **8**: e63315.
8. Cockburn N, Steven D, Lecuona K, et al. Prevalence, causes and socio-economic determinants of vision loss in Cape Town, South Africa. *PLoS One* 2012; **7**: e30718.
9. Lecuona K and Cook C. South Africa's cataract surgery rates: why are we not meeting our targets? *S Afr Med J* 2011; **101**: 510-2.
10. Evans TG. Socioeconomic consequences of blinding onchocerciasis in west Africa. *Bull World Health Organ* 1995; **73**: 495-506.
11. Langelaan M, de Boer MR, van Nispen RM, et al. Impact of visual impairment on quality of life: a comparison with quality of life in the general population and with other chronic conditions. *Ophthalmic Epidemiol* 2007; **14**: 119-26.
12. Taylor HR, Katala S, Muñoz B, et al. Increase in mortality associated with blindness in rural Africa. *Bull World Health Organ* 1991; **69**: 335-8.
13. Köberlein J, Beifus K, Schaffert C, et al. The economic burden of visual impairment and blindness: a systematic review. *BMJ Open* 2013; **3**: e003471.
14. Whitcher JP, Srinivasan M and Upadhyay MP. Corneal blindness: a global perspective. *Bull World Health Organ* 2001; **79**: 214-21.
15. Nasoodi A, Lim LT, Al-Ani A, et al. What you can see in your patient's eyes? Review of ocular manifestations of HIV in HAART era. *Int J STD AIDS* 2008; **19**: 4-11.
16. Cook C. Glaucoma in Africa: size of the problem and possible solutions. *J Glaucoma* 2009; **18**: 124-8.
17. Congdon NG, Friedman DS and Lietman T. Important causes of visual impairment in the world today. *JAMA* 2003; **290**: 2057-60.
18. Poole TR. Causes of blindness in Northern Tanzania: a hospital and rural health centre based study. *Int Ophthalmol* 2001; **24**: 195-8.
19. Ronday MJ, Stilma JS, Barbe RF, et al. Blindness from uveitis in a hospital population in Sierra Leone. *Br J Ophthalmol* 1994; **78**: 690-3.
20. Shukla D, Rathinam SR and Cunningham ET Jr. Contribution of HIV/AIDS to global blindness. *Int Ophthalmol Clin* 2007; **47**: 27-43.
21. Klotz SA, Penn CC, Negvesky GJ, et al. Fungal and parasitic infections of the eye. *Clin Microbiol Rev* 2000; **13**: 662-85.
22. Paulsen FP, Schaudig U and Thale AB. Drainage of tears: impact on the ocular surface and lacrimal system. *Ocul Surf* 2003; **1**: 180-91.

23. Ronday MJ, Stilma JS, Barbe RF, et al. Aetiology of uveitis in Sierra Leone, west Africa. *Br J Ophthalmol* 1996; **80**: 956-61.
24. Whitcher JP, Srinivasan M and Upadhyay MP. Corneal blindness: a global perspective. *Bull World Health Organ* 2001; **79**: 214-21.
25. Chang JH and Wakefield D. Uveitis: a global perspective. *Ocul Immunol Inflamm* 2002; **10**: 263-79.
26. Rathinam SR and Namperumalsamy P. Global variation and pattern changes in epidemiology of uveitis. *Indian J Ophthalmol* 2007; **55**: 173-83.
27. Upadhyay MP, Srinivasan M and Whitcher JP. Microbial keratitis in the developing world: does prevention work? *Int Ophthalmol Clin* 2007; **47**: 17-25.
28. Schaftenaar E, van Gorp EC, Meenken C, et al. Ocular infections in sub-Saharan Africa in the context of high HIV prevalence. *Trop Med Int Health* 2014; **19**: 1003-14.
29. Burton MJ, Pithuwa J, Okello E, et al. Microbial keratitis in East Africa: why are the outcomes so poor? *Ophthalmic Epidemiol* 2011; **18**: 158-63.
30. Jabs DA, Nussenblatt RB and Rosenbaum JT; Standardization of Uveitis Nomenclature (SUN) Working Group. Standardization of uveitis nomenclature for reporting clinical data. Results of the First International Workshop. *Am J Ophthalmol* 2005; **140**: 509-16.
31. London NJ, Rathinam SR and Cunningham ET Jr. The epidemiology of uveitis in developing countries. *Int Ophthalmol Clin* 2010; **50**: 1-17.
32. Barry RJ, Nguyen QD, Lee RW, et al. Pharmacotherapy for uveitis: current management and emerging therapy. *Clin Ophthalmol* 2014; **8**: 1891-911.
33. Newman H and Gooding C. Viral ocular manifestations: a broad overview. *Rev Med Virol* 2013; **23**: 281-94.
34. McGeoch DJ, Rixon FJ and Davison AJ. Topics in herpesvirus genomics and evolution. *Virus Res* 2006; **117**: 90-104.
35. Pellett PE and Roizman B. The Family of Herpesviridae: A brief introduction. In: Knipe DM, Howley PM, Griffin DE, et al, eds. *Fields Virology*. 5th ed. Vol. 2. Philadelphia: Lippincott-Williams and Wilkins, 2007: 2479-99.
36. Croen KD. Latency of the human herpesviruses. *Annu Rev Med* 1991; **42**: 61-7.
37. Lynn WA and Lightman S. The eye in systemic infection. *Lancet* 2004; **364**: 1439-50.
38. Burke BL, Steele RW, Beard OW, et al. Immune responses to varicella-zoster in the aged. *Arch Intern Med* 1982; **142**: 291-3.
39. Miller CS, Berger JR, Mootoor Y, et al. High prevalence of multiple human herpesviruses in saliva from human immunodeficiency virus-infected persons in the era of highly active antiretroviral therapy. *J Clin Microbiol* 2006; **44**: 2409-15.
40. Remeijer L, Osterhaus A and Verjans G. Human herpes simplex virus keratitis: the pathogenesis revisited. *Ocul Immunol Inflamm* 2004; **12**: 255-85.
41. Sacks SL, Griffiths PD, Corey L, et al. HSV shedding. *Antiviral Res* 2004; **63**: S19-26.
42. Rowe AM, St Leger AJ, Jeon S, et al. Herpes keratitis. *Prog Retin Eye Res* 2013; **32**: 88-101.
43. Toma HS, Murina AT, Areaux RG Jr, et al. Ocular HSV-1 latency, reactivation and recurrent disease. *Semin Ophthalmol* 2008; **23**: 249-73.
44. Farooq AV and Shukla D. Herpes simplex epithelial and stromal keratitis: an epidemiologic update. *Surv Ophthalmol* 2012; **57**: 448-62.
45. Heininger U and Seward JF. Varicella. *Lancet* 2006; **368**: 1365-76.
46. Kennedy PG and Cohrs RJ. Varicella-zoster virus human ganglionic latency: a current summary. *J Neurovirol* 2010; **16**: 411-8.



47. Liesegang TJ. Herpes zoster ophthalmicus natural history, risk factors, clinical presentation, and morbidity. *Ophthalmology* 2008; **115**: 53-12.
48. Shaikh S and Ta CN. Evaluation and management of herpes zoster ophthalmicus. *Am Fam Physician* 2002; **66**: 1723-30.
49. Vafai A and Berger M. Zoster in patients infected with HIV: a review. *Am J Med Sci* 2001; **321**: 372-80.
50. Marsh RJ and Cooper M. Ophthalmic herpes zoster. *Eye (Lond)* 1993; **7**: 350-70.
51. Kaufman SC. Anterior segment complications of herpes zoster ophthalmicus. *Ophthalmology* 2008; **115**: S24-32.
52. Richards JC, Maartens G and Davidse AJ. Course and complications of varicella zoster ophthalmicus in a high HIV seroprevalence population (Cape Town, South Africa). *Eye (Lond)* 2009; **23**: 376-81.
53. Buchbinder SP, Katz MH, Hessel NA, et al. Herpes zoster and human immunodeficiency virus infection. *J Infect Dis* 1992; **166**: 1153-6.
54. Bayu S and Alemayehu W. Clinical profile of herpes zoster ophthalmicus in Ethiopians. *Clin Infect Dis* 1997; **24**: 1256-60.
55. Huygens A, Dauby N, Vermijlen D, et al. Immunity to cytomegalovirus in early life. *Front Immunol* 2014; **5**: 552.
56. Sinclair J. Human cytomegalovirus: Latency and reactivation in the myeloid lineage. *J Clin Virol* 2008; **41**: 180-5.
57. Lynn WA and Lightman S. The eye in systemic infection. *Lancet* 2004; **364**: 1439-50.
58. Chee S, Bacsal K, Jap A, et al. Clinical features of cytomegalovirus anterior uveitis in immunocompetent patients. *Am J Ophthalmol* 2008; **145**: 834-40.
59. Kestelyn PG and Cunningham ET Jr. HIV/AIDS and blindness. *Bull World Health Organ* 2001; **79**: 208-13.
60. Stewart MW. Optimal management of cytomegalovirus retinitis in patients with AIDS. *Clin Ophthalmol* 2010; **4**: 285-99.
61. Ford N, Shubber Z, Saranchuk P, et al. Burden of HIV-related cytomegalovirus retinitis in resource-limited settings: A Systematic Review. *Clin Infect Dis* 2013; **57**: 1351-61.
62. Pathai S, Gilbert C, Weiss HA, et al. Differing spectrum of HIV-associated ophthalmic disease among patients starting antiretroviral therapy in India and South Africa. *Trop Med Int Health* 2011; **16**: 356-9.
63. Ubani UA. Bacteriology of external ocular infections in Aba, South Eastern Nigeria. *Clin Exp Optom* 2009; **92**: 482-9.
64. Capriotti JA, Pelletier JS, Shah M, et al. The etiology of infectious corneal ulceration in Sierra Leone. *Int Ophthalmol* 2010; **30**: 637-40.
65. World Health Organization. Global tuberculosis report 2014. Geneva: World Health Organization; 2014.
66. Lawn SD and Zumla AI. Tuberculosis. *Lancet* 2011; **378**: 57-72.
67. Gupta V, Gupta A and Rao NA. Intraocular tuberculosis – an update. *Surv Ophthalmol* 2007; **52**: 561-87.
68. Basu S, Monira S, Modi RR, et al. Degree, duration, and causes of visual impairment in eyes affected with ocular tuberculosis. *J Ophthalmic Inflamm Infect* 2014; **4**: 3.
69. Bodaghi B and LeHoang P. Ocular tuberculosis. *Curr Opin Ophthalmol* 2000; **11**: 443-8.
70. Allan BD and Dart JK. Strategies for the management of microbial keratitis. *Br J Ophthalmol* 1995; **79**: 777-86.

71. De Groot-Mijnes JD, Rothova A, Van Loon AM, et al. Polymerase chain reaction and Goldmann-Witmer coefficient analysis are complimentary for the diagnosis of infectious uveitis. *Am J Ophthalmol* 2006; **141**: 313-8.
72. Sharma S. Diagnosis of infectious diseases of the eye. *Eye* 2012; **26**: 177-84.
73. Azari AA and Barney NP. Conjunctivitis: a systematic review of diagnosis and treatment. *JAMA* 2013; **310**: 1721-9.
74. Margolis R, Brasil OF, Lowder CY, et al. Vitrectomy for the diagnosis and management of uveitis of unknown cause. *Ophthalmology* 2007; **114**: 1893-7.
75. Lobo A and Lightman S. Vitreous aspiration needle tap in the diagnosis of intraocular inflammation. *Ophthalmology* 2003; **110**: 595-9.
76. Taravati P, Lam D and Van Gelder RN. Role of molecular diagnostics in ocular microbiology. *Curr Ophthalmol Rep* 2013; **1**.
77. Kaye SB, Baker K and Bonshek R. Human herpesviruses in the cornea. *Br J Ophthalmol* 2000; **84**: 563-71.
78. Panda A, Pal Singh T, Satpathy G, et al. Comparison of polymerase chain reaction and standard microbiological techniques in presumed bacterial corneal ulcers. *Int Ophthalmol* 2015; **35**: 159-65.
79. Zhao G, Zhai H, Yuan Q, et al. Rapid and sensitive diagnosis of fungal keratitis with direct PCR without template DNA extraction. *Clin Microbiol Infect* 2014; **20**: 776-82.
80. Schaftenaar E, Lecuona K, Baarsma S, et al. Anterior chamber paracentesis to improve diagnosis and treatment of infectious uveitis in South Africa. *S Afr Med J* 2015; **105**: 628-30.
81. Kijlstra A. The value of laboratory testing in uveitis. *Eye (Lond)* 1990; **4**: 732-6.
82. Teoh SC and Dick AD. Diagnostic techniques for inflammatory eye disease: past, present and future: a review. *BMC Ophthalmol* 2013; **13**: 41.
83. Wade NK. Diagnostic testing in patients with ocular inflammation. *Int Ophthalmol Clin* 2000; **40**: 37-54.
84. Freed EO and Martin MA. HIVs and Their Replication. In: Knipe DM, Howley PM, Griffin DE, et al., eds. *Fields Virology*. 5th ed. Vol. 2. Philadelphia: Lippincott-Williams and Wilkins, 2007: 2479-99.
85. Joint United Nations Programme on HIV/AIDS (UNAIDS). Fact sheet 2015. Geneva: UNAIDS; 2015.
86. Joint United Nations Programme on HIV/AIDS (UNAIDS). AIDSinfo. Available at: <http://aidsinfo.unaids.org/>.
87. Simon V, Ho DD and Abdool Karim Q. HIV/AIDS epidemiology, pathogenesis, prevention, and treatment. *Lancet* 2006; **368**: 489-504.
88. Volberding PA and Deeks SG. Antiretroviral therapy and management of HIV infection. *Lancet* 2010; **376**: 49-62.
89. Ray M, Logan R, Sterne JA, et al. The effect of combined antiretroviral therapy on the overall mortality of HIV-infected individuals. *AIDS* 2010; **24**: 123-37.
90. Department of Health, Republic of South Africa. The South African antiretroviral treatment guidelines 2013. Department of Health, Republic of South Africa, Pretoria, 2013.
91. Ananworanich J, Schuetz A, Vandergeeten C, et al. Impact of multi-targeted antiretroviral treatment on gut T cell depletion and HIV reservoir seeding during acute HIV infection. *PLoS One* 2012; **7**: e33948.
92. Palella FJ Jr, Baker RK, Moorman AC, et al. Mortality in the highly active antiretroviral therapy era: changing causes of death and disease in the HIV outpatient study. *J Acquir Immune Defic Syndr* 2006; **43**: 27-34.
93. Johnson LF, Mossong J, Dorrington RE, et al. Life expectancies of South African adults starting antiretroviral treatment: collaborative analysis of cohort studies. *PLoS Med* 2013; **10**: e1001418.

94. Cohen MS, Smith MK, Muessig KE, et al. Antiretroviral treatment of HIV-1 prevents transmission of HIV-1: where do we go from here? *Lancet* 2013; **382**: 1515-24.
95. Günthard HF, Aberg JA, Eron JJ, et al. Antiretroviral treatment of adult HIV infection: 2014 recommendations of the International Antiviral Society-USA Panel. *JAMA* 2014; **312**: 410-25.
96. Department of Health, Republic of South Africa. National consolidated guidelines for the prevention of mother-to-child transmission of HIV (PMTCT) and the management of HIV in children, adolescents and adults. Department of Health, Republic of South Africa, Pretoria, 2014.
97. Cunningham ET Jr and Margolis TP. Ocular manifestations of HIV infection. *N Engl J Med* 1998; **339**: 236-44.
98. Holland GN. AIDS and ophthalmology: the first quarter century. *Am J Ophthalmol* 2008; **145**: 397-408.
99. Robinson MR, Ross ML and Whitcup SM. Ocular manifestations of HIV infection. *Curr Opin Ophthalmol* 1999; **10**: 431-7.
100. Liesegang TJ. Herpes simplex virus epidemiology and ocular importance. *Cornea* 2001; **20**: 1-13.
101. Nkomazana O and Tshitswana D. Ocular complications of HIV infection in sub-Saharan Africa. *Curr HIV/AIDS Rep* 2008; **5**: 120-5.
102. Beare NA, Kublin JG, Lewis DK, et al. Ocular disease in patients with tuberculosis and HIV presenting with fever in Africa. *Br J Ophthalmol* 2002; **86**: 1076-9.
103. Tabbara KF. Ocular tuberculosis: anterior segment. *Int Ophthalmol Clin* 2005; **45**: 57-69.
104. Abu El-Asrar AM, Abouammoh M and Al-Mezaine HS. Tuberculous uveitis. *Int Ophthalmol Clin* 2010; **50**: 19-39.
105. Gichuhi S, Sagoo MS, Weiss HA, et al. Epidemiology of ocular surface squamous neoplasia in Africa. *Trop Med Int Health* 2013; **18**: 1424-3.
106. Waddell KM, Lewallen S, Lucas SB, et al. Carcinoma of the conjunctiva and HIV infection in Uganda and Malawi. *Br J Ophthalmol* 1996; **80**: 503-8.
107. Poole TR. Conjunctival squamous cell carcinoma in Tanzania. *Br J Ophthalmol* 1999; **83**: 177-9.
108. Makupa II, Swai B, Makupa WU, et al. Clinical factors associated with malignancy and HIV status in patients with ocular surface squamous neoplasia at Kilimanjaro Christian Medical Centre, Tanzania. *Br J Ophthalmol* 2012; **96**: 482-4.
109. Lewallen S and Courtright P. HIV and AIDS and the eye in developing countries: a review. *Arch Ophthalmol* 1997; **115**: 1291-5.
110. Moraes HV Jr. Ocular manifestations of HIV/AIDS. *Curr Opin Ophthalmol* 2002; **13**: 397-403.
111. Rohner E, Valeri F, Maskew M, et al. Incidence rate of Kaposi sarcoma in HIV-infected patients on antiretroviral therapy in Southern Africa: a prospective multicohort study. *J Acquir Immune Defic Syndr* 2014; **67**: 547-54.
112. Stewart MW. Human immunodeficiency virus and its effects on the visual system. *Infect Dis Rep* 2012; **4**: e25.
113. Vrabec TR. Posterior segment manifestations of HIV/AIDS. *Surv Ophthalmol* 2004; **49**: 131-57.
114. Accorinti M, Pirraglia MP, Corradi R, et al. Changing patterns of ocular manifestations in HIV seropositive patients treated with HAART. *Eur J Ophthalmol* 2006; **16**: 728-32.
115. Pathai S, Lawn SD, Weiss HA, et al. Increased ocular lens density in HIV-infected individuals with low nadir CD4 counts in South Africa: evidence of accelerated aging. *J Acquir Immune Defic Syndr* 2013; **63**: 307-14.
116. Otiti-Sengeri J, Meenken C, van den Horn GJ, et al. Ocular immune reconstitution inflammatory syndromes. *Curr Opin HIV AIDS* 2008; **3**: 432-7.

117. Kempen JH, Min YI, Freeman WR, et al. Risk of immune recovery uveitis in patients with AIDS and cytomegalovirus retinitis. *Ophthalmology* 2006; **113**: 684-94.
118. Henderson HWA and Suzanne M Mitchell SM. Treatment of immune recovery vitritis with local steroids. *Br J Ophthalmol* 1999; **83**: 540-5.
119. Robinson MR, Reed G, Csaky KG, et al. Immune-recovery uveitis in patients with cytomegalovirus retinitis taking highly active antiretroviral therapy. *Am J Ophthalmol* 2000; **130**: 49-56.
120. Zamir E, Hudson H, Ober RR, et al. Massive mycobacterial choroiditis during highly active antiretroviral therapy: another immune-recovery uveitis? *Ophthalmology* 2002; **109**: 2144-8.
121. Dhasmana DJ, Dheda K, Ravn P, et al. Immune reconstitution inflammatory syndrome in HIV-infected patients receiving antiretroviral therapy: pathogenesis, clinical manifestations and management. *Drugs* 2008; **68**: 191-208.
122. Courtright P, Seneadza A, Mathenge W, et al. Primary eye care in sub-Saharan African: do we have the evidence needed to scale up training and service delivery? *Ann Trop Med Parasitol* 2010; **104**: 361-7.
123. Onakpoya OH, Adeoye AO, Adegbehingbe BO, et al. Assessment of human and material resources available for primary eye-care delivery in rural communities of southwestern Nigeria. *West Indian Med J* 2009; **58**: 472-5.
124. Lecuona K. Analysis of eye care services in South Africa's public sector. *Community Eye Health* 2007; **20**: 72.
125. du Toit R, Faal HB, Etya'ale D, et al. Evidence for integrating eye health into primary health care in Africa: a health systems strengthening approach. *BMC Health Serv Res* 2013; **13**: 102.
126. Naidoo K. Poverty and blindness in Africa. *Clin Exp Optom* 2007; **90**: 415-21.
127. Pizzarello L, Abiose A, Ffytche T, et al. VISION 2020: The Right to Sight: a global initiative to eliminate avoidable blindness. *Arch Ophthalmol* 2004; **122**: 615-20.
128. Foster A and Resnikoff S. The impact of Vision 2020 on global blindness. *Eye (Lond)* 2005; **19**: 1133-5.
129. World Health Organization. Universal eye health: a global action plan 2014-2019. Geneva: World Health Organization; 2013.
130. Department of Health, Republic of South Africa. The 2013 National antenatal sentinel HIV prevalence survey South Africa. Department of Health, Republic of South Africa, Pretoria, 2015.





# Chapter 2

## **High seroprevalence of human herpesviruses in HIV-infected individuals attending primary healthcare facilities in rural South Africa.**

Erik Schaftenaar, Georges M.G.M. Verjans, Sarah Getu, James A. McIntyre, Helen E. Struthers, Albert D.M.E. Osterhaus and Remco P.H. Peters.

*PLoS One* 2014; **9**: e99243.

## **ABSTRACT**

Seroprevalence data of human herpesviruses (HHVs) are limited for sub-Saharan Africa. These are important to provide an indication of potential burden of HHV-related disease, in particular in human immunodeficiency virus (HIV)-infected individuals who are known to be at increased risk of these conditions in the Western world. In this cross-sectional study among 405 HIV-infected and antiretroviral therapy naïve individuals in rural South Africa the seroprevalence of HHVs was: herpes simplex virus type 1 (HSV-1) (98%), herpes simplex virus type 2 (HSV-2) (87%), varicella zoster virus (VZV) (89%), and 100% for both Epstein-Barr virus (EBV) and cytomegalovirus (CMV). Independent factors associated with VZV seropositivity were low educational status and having children. Lack of in-house access to drinking water was independently associated with positive HSV-1 serostatus, whereas Shangaan ethnicity was associated with HSV-2 seropositivity. Increasing age was associated with higher IgG titres to both EBV and CMV, whereas CD4 cell count was negatively associated with EBV and CMV IgG titres. Moreover, IgG titres of HSV-1 and 2, VZV and CMV, and CMV and EBV were positively correlated. The high HHV seroprevalence emphasizes the importance of awareness of these viral infections in HIV-infected individuals in South Africa.



## INTRODUCTION

Herpes simplex virus type 1 (HSV-1) and 2 (HSV-2), varicella zoster virus (VZV), Epstein-Barr virus (EBV), and cytomegalovirus (CMV) are human herpesviruses (HHV) that are prevalent worldwide. HHV Infections can lead to a variety of clinical conditions that range in severity from cold sores and genital ulcers (HSV), and chickenpox (VZV) to potentially sight-threatening (e.g. CMV uveitis and HSV keratitis) or even life-threatening diseases such as HSV encephalitis and EBV-associated malignancies [1-3]. Primary HHV infections, commonly acquired at young age, lead to a life-long latent infection with intermittent reactivation resulting in periodic asymptomatic or recrudescence disease. The host immune system is pivotal to resolve lytic infections and to inhibit HHV reactivation from latency. Consequently, reactivation of HHV is much more frequent among immunocompromised individuals including those infected with human immunodeficiency virus (HIV) [4-5]. Also, HIV-infected individuals have an increased risk of developing more severe HHV-related disease [4-5]. Even after the introduction of antiretroviral therapy (ART), HIV-infected individuals remain at risk of developing severe HHV-related diseases as ART-induced recuperation of adaptive immunity may result in vigorous anti-HHV cellular immune responses. In the case of residual ocular CMV infection, restored CMV immunity may lead to sight-threatening immune recovery uveitis [6]. HHV infections clinically interact with HIV, contribute substantially to hospitalization, morbidity and mortality and some HHVs (e.g. HSV-2) may even facilitate HIV transmission [4, 7-8]. This is of particular importance in sub-Saharan Africa where HIV prevalence rates are at their highest. Despite the roll-out of ART programmes in this region, ART coverage is still low [9]. Many HIV-infected patients seek healthcare with considerably more advanced immunodeficiency and may present with clinically different HHV-related diseases compared to individuals in resource-rich countries. In contrast to developed countries, where HHV seroprevalence and occurrence of associated diseases are well-documented, there is only scarce information available on the seroprevalence and risk factors of HHV infections in sub-Saharan Africa. This information is important to provide an indication of the burden of HHV infections which is particularly relevant for HIV-infected individuals who are known to be at increased risk for development of HHV-induced disease due to reactivation.

## MATERIAL AND METHODS

### Study setting and population

Study participants were recruited between September 2012 and January 2013 at primary healthcare (PHC) facilities across the Mopani District (Limpopo Province, South Africa),

where the two main ethnic groups are Sotho (46%) and Shangaan (44%) [10]. Participating PHC facilities were selected by ratio of population-size of each of five sub-districts with a minimum of two PHC facilities/sub-district. Within each sub-district, PHC facilities were selected based on the number of patients on the 'wellness, pre-ART programme', geographic location and size of the catchment area. Individuals who had an indication to draw blood for determination of CD4 count (CD4 T-cells/mm<sup>3</sup> blood) were eligible for this study. Criteria to participate were adult age (i.e. 18 years and older) and no prior ART exposure. Low educational status and low financial income were defined as having no education or primary school only, and persons with a government grant as the main source of income, respectively. The study was performed according to the tenets of the Helsinki Declaration, approved unconditionally by the Human Research Ethics Committee (Medical) of the University of the Witwatersrand, Johannesburg, South Africa (reference number: M120546), and written informed consent was obtained from all participants.

### **Study and laboratory procedures**

Demographic and clinical data were collected upon inclusion. A whole blood sample was drawn and diagnostic CD4 counts were determined using the Cytomics FC 500 MPL platform (Beckman Coulter). Serological analysis was performed at the Laboratory of Viroscience at the Erasmus Medical Center in Rotterdam, The Netherlands. HHV-specific serum IgG titres were determined using Serion ELISA classic tests (Virion Serion) on the Anthos-Labtec AR8001 platform (Anthos Labtec). ELISAs were performed and data interpreted (i.e. seropositive, borderline or seronegative) per manufacturer's guidelines (Virion Serion).

### **Statistical analysis**

Clinical and laboratory data were double-entered and validated using EPI-INFO version 3.5.4 (Centers for Disease Control). Description of study population and seroprevalence is done using number with proportion and mean with standard deviation. To identify factors associated with HHV-specific positive serostatus, excluding persons with borderline ELISA results, univariate analysis was performed using Chi-squared test, or Fisher's Exact test if appropriate, for categorical variables and Mann-Whitney and Student T-test for continuous variables. Data are presented as odds ratio (OR) with 95% confidence interval (CI), mean with standard deviation (SD) or as median. To identify factors independently associated with seropositive status variables with P-values <0.10 in univariate analysis, and age and gender as potential confounders, were included in multivariate analysis using logistic regression (forward Likelihood Ratio) with HHV seropositivity as dichotomous measure of outcome. The potential correlation of log<sub>2</sub> HHV IgG titres with age and CD4 count was analysed using Spearman's correlation coefficient. Multiple

linear regression analysis was performed to determine potential association of age and CD4 count, adjusting for gender and ethnicity, with the log2 HHV titre as continuous measure of outcome, providing assumptions for linear regression were met. Statistical analyses were conducted using PASW Statistics and P-values <0.05 were considered statistically significant.

## RESULTS

### Study population

The study population of 405 HIV-infected and ART-naïve adults consisted of 72 (18%) men and 333 (82%) women (**Table 1**). The mean age was  $37.9 \pm 11.5$  years. Men were

**Table 1.** Demographic characteristics of study participants (n=405).

Characteristic	
Gender (male)	72 (18)
Age in years (mean (SD))	38 (11)
Ethnicity	
Shangaan	255 (65)
Sotho	138 (35)
Marital status	
Never married	243 (60)
Married	129 (32)
Divorced or widowed	33 (8)
Has children	352 (87)
Individuals in household	5.1 (2.3)
Low educational status	192 (47)
Currently employed	103 (25)
Low financial income	184 (46)
In-house access to drinking water	25 (6.2)
In-house access to latrine	20 (5.0)
Keeps livestock	24 (5.9)
CD4 cell count in cells/mm <sup>3</sup> (mean (SD))	382 (226)
Clinical HIV-stage <sup>a</sup>	
Stage 1	344 (85)
Stage 2	25 (6.0)
Stage 3	35 (9.0)
Stage 4	0 (0)

Data are presented as number (%) unless otherwise indicated. SD = standard deviation; HIV = human immunodeficiency virus.

<sup>a</sup>Clinical HIV-staging was done according to the WHO Clinical Staging of HIV/AIDS [11].

significantly older (mean age of 42 versus 37 years,  $P=0.002$ ), more often employed (age-adjusted OR (aOR)=4.5; 95% CI: 2.6–7.7,  $P<0.001$ ), were or had been married (aOR=1.8; 95% CI: 1.0–3.1,  $P<0.05$ ) and had lower mean CD4 counts than women (306 vs. 398 cells/mm<sup>3</sup>;  $P<0.001$ ). Most participants had children (87%) and some had limited access to in-house drinking water (6.2%) and latrine (5.0%). Thirty (8%) participants were newly diagnosed for HIV infection, 354 (87%) attended the ‘wellness, pre-ART programme’ and 21 (5%) individuals attended the clinic for baseline results before ART initiation. Mean CD4 count was  $382 \pm 226$  CD4 T-cells/mm<sup>3</sup> and fifty percent of participants had CD4 counts  $\leq 350$  cells/mm<sup>3</sup>, which is the threshold in South Africa to initiate ART [12].

### Seroprevalence of HHVs

HHV seroprevalence was determined in 402 samples (three were unavailable after transport); serum HHV ELISA data are summarized in **Table 2**. Excluding borderline results, HHV seroprevalence was very high: HSV-1 98% (95% CI: 96–99%); HSV-2 87% (95% CI: 83–90%); VZV 89% (95% CI: 86–92%) and 100% for both EBV and CMV. Seroprevalence was similar between individuals with CD4 count below and above 350 cells/mm<sup>3</sup> for HSV-1 (98% vs. 97%;  $P=0.33$ ), HSV-2 (89% vs. 84%;  $P=0.17$ ) and VZV (91% vs. 88%;  $P=0.35$ ). Neither HHV seropositive status with CD4 count nor clinical HIV and HHV-related clinical symptoms was associated at time of sampling. The frequency of reported HHV-related clinical symptoms was low and not associated with the respective HHV seropositive status. History of chickenpox was reported by 72 (20%) of VZV seropositive and 5 (12%) of VZV seronegative individuals ( $P=0.2$ ) and herpes zoster by 50 (14%) and 4 (10%), respectively. Among HSV-1 seropositive individuals a history of cold sores and oral lesions was reported by 54 (15%) and 49 (14%) study participants, respectively. HSV-1 seronegative individuals did not report these diseases. Anogenital lesions were reported by 77 (24%) and 10 (20%) HSV-2 seropositive and seronegative study participants, respectively.

**Table 2.** Seroprevalence of human herpesviruses in HIV-infected individuals (n=402).

	HSV-1	HSV-2	VZV	EBV	CMV
<b>Positive</b>	361 (90)	316 (79)	353 (88)	400 (99.5)	402 (100)
<b>Borderline</b>	32 (8.0)	37 (9)	7 (1.7)	2 (0.5)	0 (0)
<b>Negative</b>	9 (2.2)	49 (12)	42 (10)	0 (0)	0 (0)

Data are presented as number (%). HSV = human simplex virus; VZV = varicella zoster virus; EBV = Epstein-Barr virus; CMV = cytomegalovirus.

### Factors associated with positive HHV serostatus

Crude clinical and demographic factors associated with individuals’ HHV seropositive vs. seronegative status for HSV-1, HSV-2 and VZV are summarized in **Table 3**. The 100% seroprevalence for EBV and CMV precluded calculation of such factors. Adjusting for age

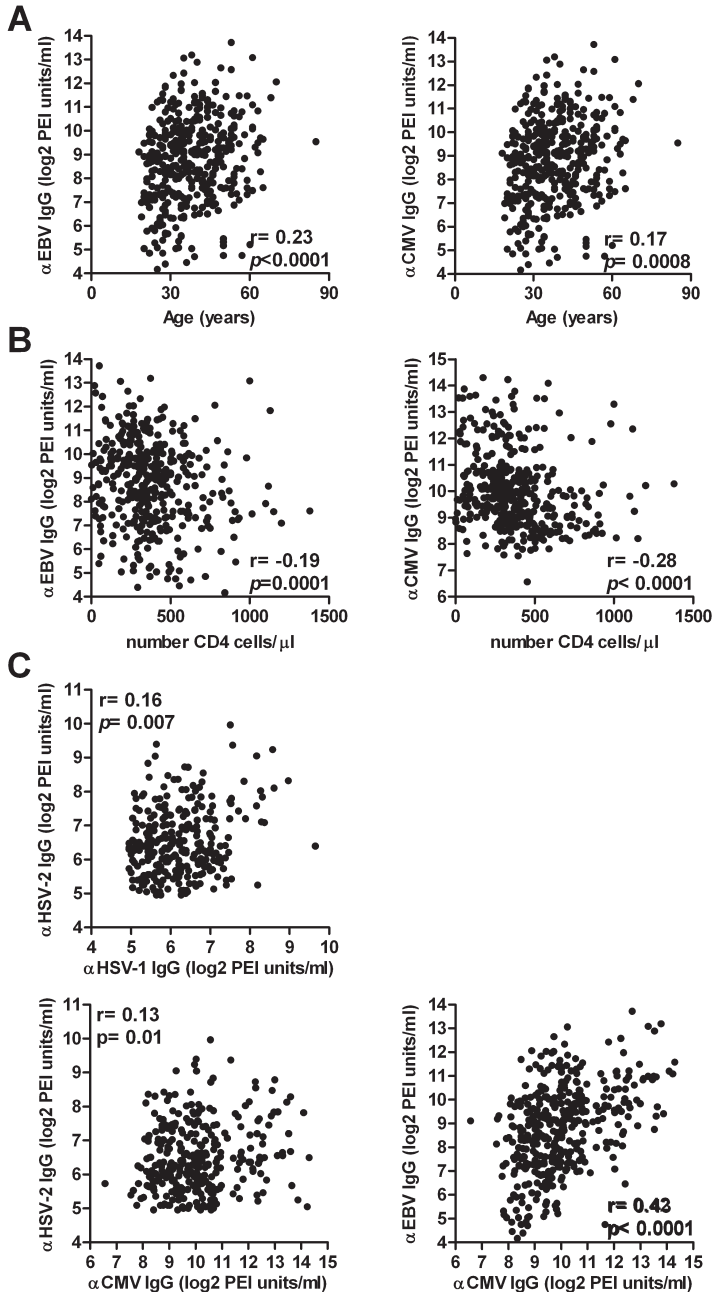
**Table 3.** Crude risk factors associated with HSV-1, HSV-2, and VZV serostatus.

	HSV-1 serology				HSV-2 serology				VZV serology			
	Positive (n=361)	Negative (n=9)	Crude odds ratio (95% CI)	P-value	Positive (n=316)	Negative (n=49)	Crude odds ratio (95% CI)	P-value	Positive (n=353)	Negative (n=42)	Crude odds ratio (95% CI)	P-value
Age in years	38 (11)	34 (9)	na	0.4	39 (12)	34 (10)	na	0.02	39 (11)	32 (10)	na	0.001
Gender												
Men	62 (98)	1 (2)	1.7 (0.2–13.5)	1.0	53 (86)	9 (14)	0.9 (0.4–2.0)	0.8	61 (86)	10 (14)	0.7 (0.3–1.4)	0.3
Women	299 (97)	8 (3)	1		262 (87)	40 (13)	1		292 (90)	32 (10)	1	
Ethnicity												
Shangaan	235 (98)	6 (2)	0.7 (0.1–3.4)	1.0	206 (91)	20 (9)	2.4 (1.3–4.5)	0.006	222 (89)	27 (11)	0.8 (0.4–1.7)	0.6
Sotho	116 (98)	2 (2)	1		103 (81)	24 (19)	1		122 (91)	12 (9)	1	
Low educational status	166 (46)	1 (11)	6.8 (0.8–55)	0.07	148 (47)	22 (45)	1.1 (0.6–2.0)	0.8	178 (50)	8 (19)	4.3 (1.9–9.6)	<0.0001
Currently employed	91 (25)	2 (11)	1.2 (0.2–4.8)	1.0	81 (26)	13 (27)	1.0 (0.5–1.9)	0.9	90 (26)	11 (26)	1.0 (0.5–2.0)	0.9
Low financial income	163 (45)	1 (11)	6.7 (0.8–54)	0.08	145 (46)	17 (35)	1.6 (0.9–3.0)	0.1	163 (46)	16 (38)	1.4 (0.7–2.7)	0.3
Marital status												
Never married	220 (98)	5 (2)	1.2 (0.3–4.7)	0.7	191 (88)	27 (12)	1.2 (0.7–2.3)	0.5	206 (87)	32 (13)	0.4 (0.2–0.9)	0.03
Married, widowed or divorced	141 (97)	4 (3)	1		125 (85)	22 (15)	1		147 (94)	10 (6)	1	
In-house access to drinking water	22 (6.1)	3 (33)	0.13 (0.03–0.55)	0.02	17 (5.4)	7 (14)	0.3 (0.1–0.9)	0.03	23 (6.5)	2 (4.8)	1.4 (0.3–6.1)	1.0
In-house access to latrine	17 (4.7)	2 (22)	0.17 (0.03–0.90)	0.07	13 (4.1)	6 (12)	0.3 (0.1–0.9)	0.03	17 (4.8)	3 (7.1)	0.7 (0.2–2.3)	0.5
Clinical HIV-stage												
Stage 1	304 (97)	9 (3)	–	0.4	265 (86)	42 (14)	0.7 (0.3–1.8)	0.5	302 (90)	34 (10)	1.2 (0.5–2.9)	0.7
Stages 2-4	56 (100)	0 (0)	1		51 (89)	6 (11)	1		51 (88)	7 (12)	1	

**Table 3.** Crude risk factors associated with HSV-1, HSV-2, and VZV serostatus. (continued)

	HSV-1 serology			HSV-2 serology			VZV serology		
	Positive (n= 361)	Negative (n= 9)	P-value	Positive (n= 316)	Negative (n= 49)	P-value	Positive (n= 353)	Negative (n= 42)	P-value
CD4 cell count in cells/mm <sup>3</sup>	373 (219)	491 (285)	na	381 (236)	398 (188)	0.6	386 (228)	374 (224)	na
History of cold sores	54 (15)	0 (0.0)	0.97 (0.95-0.99)	-	-	-	-	-	-
History of oral lesions	49 (14)	0 (0.0)	0.97 (0.95-0.99)	44 (14)	10 (20)	0.2	-	-	-
History of anogenital lesions	87 (24)	1 (11)	2.5 (0.3-21)	77 (24)	10 (20)	0.5	-	-	-
History of chickenpox	-	-	-	-	-	-	72 (20)	5 (12)	1.9 (0.7-5.0)
History of vesicular rash	-	-	-	-	-	-	50 (14)	4 (10)	1.6 (0.5-4.6)

Data are shown as numbers (%) or mean (sd). Crude odds ratios were calculated for demographic and clinical characteristics between positive and negative serological status. CI, Confidence interval; P-value, Pearson Chi-square; na, not applicable; VZV, varicella zoster virus; HSV-1, herpes simplex virus 1; HSV-2, herpes simplex virus 2.



**Figure 1.** Scatter plots of factors associated with human herpesvirus-specific serum IgG titres. Correlation between serum EBV and CMV IgG titres and the individual's (A) Age and (B) CD4 cell count. (C) Correlation between serum IgG titres of different human herpesviruses. Serum IgG titres, presented as binary logarithmic PEI/ml values, were calculated based on corresponding reference sera from the Paul-Ehrlich Institute (Erlangen, Germany). The Spearman correlation test was used for statistical analysis. HSV-1, herpes simplex virus 1; HSV-2, herpes simplex virus; VZV, varicella zoster virus; EBV, Epstein-Barr virus and CMV, cytomegalovirus.

and gender, lack of in-house access to drinking water (aOR=7.7; 95% CI: 1.8–33,  $P=0.006$ ) and Shangaan ethnicity (aOR=2.4; 95% CI: 1.2–4.5,  $P=0.008$ ) were independently associated with positive HSV-1 and HSV-2 serostatus, respectively. Low educational status (aOR=4.0; 95% CI: 1.8–9.0,  $P=0.01$ ), having children (aOR=2.2; 95% CI: 1.0–4.9,  $P=0.04$ ) and a higher number of children in the household ( $P=0.007$ ) were independently associated with VZV seropositivity, including adjustment for age and gender (data not shown).

Next, we assayed potential correlations between HHV-specific IgG titres and paired individual's laboratory and clinical data (**Figure 1**). EBV and CMV IgG titres correlated significantly with age and CD4 count. Increasing age was associated with higher EBV ( $R^2=0.05$ ,  $P<0.001$ ) and CMV IgG titres ( $R^2=0.03$ ,  $P=0.0008$ ) (**Figure 1A**), whereas increasing CD4 count was negatively associated with EBV ( $R^2=-0.04$ ,  $P=0.0001$ ) and CMV IgG titres ( $R^2=0.08$ ,  $P<0.0001$ ) (**Figure 1B**). There was no association of CD4 count with HSV-1, HSV-2 and VZV IgG titre (see supplemental **Figure S1**). Higher HSV-1 IgG titres were detected among men (median 88 U/mL versus 66 U/mL in women;  $P=0.001$ ). Furthermore, HSV-1 and HSV-2 ( $R^2=0.03$ ,  $P=0.007$ ), CMV and VZV ( $R^2=0.02$ ,  $P=0.013$ ) and CMV and EBV ( $R^2=0.18$ ,  $P<0.0001$ ) IgG titres were positively correlated (**Figure 1C**). No associations of age, gender and ethnicity were observed between IgG titres for the other HHVs.

Finally, multivariate analysis of determinants of HHV titre was performed for age, gender, ethnicity and CD4 count. In individuals with similar gender and ethnicity, there was an association for every one year increase in age (0.17 unit) and every cell reduction in CD4 count ( $-0.25$  unit) with CMV IgG titre. Also, for every one year increase in age the EBV IgG titre was associated with a 0.17 unit increase in titre in subjects comparable in gender, ethnicity and CD4 count, whereas male gender was associated with a decrease in HSV-1 IgG titre ( $-0.17$  unit; see supplemental **Table S1**). No associations between HSV-2 and VZV IgG titres and the aforementioned factors were observed.

## DISCUSSION

This study reports on the seroprevalence of HSV-1, HSV-2, VZV, EBV and CMV among HIV-infected and ART-naïve adults in rural South Africa. We showed that HHV seroprevalence in this population is very high. We identified several demographic factors that were associated with a seropositive status for HSV-1, HSV-2 and VZV, but did not observe that clinical history of HHV infection is predictive for the individual's HHV serostatus.

We observed a relatively high seroprevalence of HHVs which confirms observations in other studies addressing seroprevalence of these viruses among HIV-infected individuals in Africa. Estimates of HSV-1 and HSV-2 seroprevalence among adult HIV-infected individuals vary across Africa, ranging from 65 to 90% in studies from South Africa, Kenya, Lesotho and Tanzania [13-17]. High prevalence rates (>85%) have also been reported



for VZV, CMV and EBV in HIV-infected adult individuals from several African countries [13-14, 18]. These infections may be acquired in early childhood as illustrated by the 100% CMV seroprevalence among a small cohort of city-dwelling HIV-infected children in Kenya [19]. As such, a generally high seroprevalence of HHVs is manifest among adults with HIV-infection across Africa. It should be noted that we recruited a selected group of individuals in our study (HIV-infected and ART-naïve adults) and that our findings should not be extrapolated to the general adult African population including either HIV negative or HIV positive adults on ART therapy. Since HIV-infection is associated with increased HHV seroprevalence, it may be expected that seroprevalence of these viruses in the general population would be lower as for example shown for HSV and EBV [1, 20].

We identified several factors associated with seropositive status for 5 individual HHVs, but these should be interpreted with caution as seroprevalence was very high, resulting in a relatively small group of seronegative participants, and the effect of chance associated with multiple comparison cannot be ruled out. In addition, we like to point out that the use of prevalence odds ratio instead of prevalence ratio may have resulted in an overestimation of the observed associations; although there are pros and cons to both measures of effect [21-22]. Low socioeconomic status – represented here as lack of in-house access to drinking water – was appeared to be associated with HSV-1 seropositivity. Shangaan ethnicity was independently associated with HSV-2 seropositivity, suggesting a higher HSV-2 infection rate among Shangaan compared to Sotho. This potential association may be due to different sexual risk behaviour between these ethnic groups [unpublished data]. However, our study did not confirm previously described associations of seropositivity for HSV-2 and female gender, age, and other socioeconomic factors, but this may be due to the high seroprevalence in our study population [23-27]. As reported earlier, VZV seropositive status associated independently with age, low educational status, having children and number of children, and number of individuals in the household [28-32]. Notably, no association was observed between the individual's seropositive HHV status and a history of corresponding HHV-specific clinical symptoms. This could be due to recall bias as some infections would have occurred in early childhood (e.g. varicella); other infections can have a subclinical course (e.g. CMV, HSV) without ever presenting with clear symptoms or being recognised by the individual. As such, based on the poor predictive value, it would not be possible to identify individuals with seropositive status, and thus at increased risk of HHV reactivation and complications, based on clinical history taking.

We observed a moderate positive associations between EBV and CMV IgG titres and age. As most individuals are infected with HHV during childhood, increasing reactivation rates of the respective HHVs during ageing and/or progress of HIV infection may have attributed to this association [33-34]. Indeed, age-related waning of cellular immunity and higher reactivation rates of latent HHVs resulting in increased HHV-specific IgG and

IgM titres have been reported [33, 35-36]. The negative association of EBV and CMV IgG titres with CD4 count is in line with two recent studies describing significant increase of activated HHV-specific CD4 T-cells in HIV-infected individuals compared to HIV naïve individuals [37-38]. Decreasing CD4 count due to HIV replication is associated with activation of CMV- and EBV-specific CD4 T-cells as part of chronic immune activation, which may subsequently stimulate humoral responses and produce higher IgG titres in time.

The observed weak, though significant associations between serum IgG levels of different HHVs suggest that risk factors of reactivation leading to higher IgG titres partially overlap. The associations between HSV-1 and HSV-2, and EBV and CMV IgG titres may in part be attributed to the anatomic and cellular site and corresponding immune responses involved in controlling viral latency. Both HSV types establish latency in sensory neurons, whereas lymphocytes are the main cell type of CMV (hematopoietic progenitor cells) and EBV (B-cells) latency [39-41]. HIV infection may inhibit specific immune cell types and mechanisms that are commonly involved in controlling either latent neurotropic (HSV-1 and HSV-2) and lymphotropic (EBV and CMV) herpesviruses. Moreover, the positive association between age and CD4 count with both EBV and CMV strengthen this assumption that immunity to both viruses is entangled, which warrants further studies [36]. However, contrary to our results, the observed association in the latter study was between CMV and HSV-1 IgG titres and was only significant in individuals <45 years old. In addition, CMV seropositivity, but not CMV IgG titres, has been associated with increased VZV IgG titres [34]. Since all individuals in our study cohort were CMV seropositive a similar association analysis could not be performed.

There are several limitations to this study. First, PHC facilities were not randomly selected within the five sub-districts in Mopani, which may have resulted in some degree of bias in obtaining a population estimate for the Mopani District. However, since PHC facilities were sampled by ratio of sub-district's population-size with a minimum of two PHC facilities per sub-district and no geographical variation was observed, we consider our study cohort representative for HIV-infected individuals attending PHC facilities in the Mopani district. Second, only individuals attending PHC facilities were included, a population that may be different for some demographic characteristics compared to those not seeking healthcare. Generally, the latter group ultimately presents with lower CD4 counts and higher risk of HHV-related disease suggesting an under- rather than overestimate of seroprevalence. Third, considerably more women than men were included in this study, but statistical analyses were adjusted for gender. Fourth, the use of self-reported clinical history of HHV infection may have resulted in some degree of recall bias, especially since all participants were adults. Finally, we did not include HHVs type 6 and 8 in our seroprevalence study; HHV-8 in particular is associated with morbidity (Kaposi sarcoma) in HIV-infected individuals.

HHV infections have currently limited priority and awareness in the (pre-)ART programme of South Africa. The herein reported high HHV seroprevalence and consequently high risk for HHV-related diseases among HIV-infected individuals warrant increased awareness among healthcare workers in rural South Africa for early clinical signs of these conditions to initiate prompt antiviral treatment: e.g. early diagnosis and treatment of herpes zoster ophthalmicus to prevent corneal blindness [4, 6]. In conclusion, seroprevalence of HHVs in rural South Africa is very high and recognition and awareness of HHV-related diseases is warranted.

## **ACKNOWLEDGEMENTS**

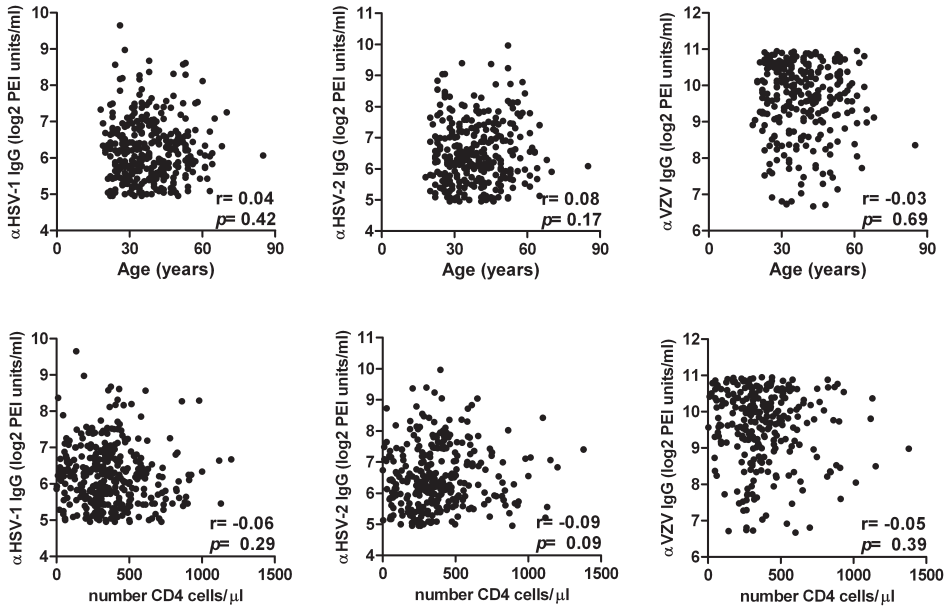
The authors thank the Tzaneen Anova Health Institute staff and the local staff of the participating PHC facilities for their cooperation and participation in the study. We also thank Lancet Laboratories in Tzaneen (Tzaneen, South Africa) for providing the workspace to perform serum separation and for providing storage capacity of the serum samples.

## REFERENCES

1. Adjei AA, Armah HB, Gbagbo F, et al. Seroprevalence of HHV-8, CMV, and EBV among the general population in Ghana, West Africa. *BMC Infect Dis* 2008; **8**: 111.
2. Weiss HA, Buvé A, Robinson NJ, et al. The epidemiology of HSV-2 infection and its association with HIV infection in four urban African populations. *AIDS* 2001; **15**: S97-108.
3. Dollard SC, Butler LM, Jones AM, et al. Substantial regional differences in human herpesvirus 8 seroprevalence in sub-Saharan Africa: insights on the origin of the "Kaposi's sarcoma belt". *Int J Cancer* 2010; **127**: 2395-401.
4. Chakraborty N, Bhattacharyya S, De C, et al. Incidence of multiple Herpesvirus infection in HIV seropositive patients, a big concern for Eastern Indian scenario. *Virology* 2010; **7**: 147-53.
5. Jansen K, Haastert B, Michalik C, et al. Incidence and risk factors of herpes zoster among hiv-positive patients in the german competence network for HIV/AIDS (KompNet): a cohort study analysis. *BMC Infect Dis* 2013; **13**: 372-81.
6. Otiti-Sengeri J, Meenken C, van den Horn GJ, et al. Ocular immune reconstitution inflammatory syndromes. *Curr Opin HIV AIDS* 2008; **3**: 432-7.
7. Miller CS, Berger JR, Mootoor Y, et al. High Prevalence of Multiple Human Herpesviruses in Saliva from Human Immunodeficiency Virus-Infected Persons in the Era of Highly Active Antiretroviral Therapy. *J Clin Microbiol* 2006; **44**: 2409-15.
8. Patel P, Bush T, Mayer KH, et al. Prevalence and risk factors associated with herpes simplex virus-2 infection in a contemporary cohort of HIV-infected persons in the United States. *Sex Transm Dis* 2012; **39**: 154-60.
9. Wringe A, Floyd S, Kazooba P, et al. Antiretroviral therapy uptake and coverage in four HIV community cohort studies in sub-Saharan Africa. *Trop Med Int Health* 2012; **17**: e38-48.
10. Statistics South Africa. The South Africa I know, the home I understand / Statistics South Africa. Pretoria: Statistics South Africa; 2012.
11. World Health Organization. Interim World Health Organization Clinical Staging of HIV/AIDS and HIV/AIDS Case Definitions for Surveillance Geneva, Switzerland: African Region, 2005. Available: <http://www.who.int/hiv/pub/guidelines/clinicalstaging.pdf>.
12. World Health Organization. Antiretroviral therapy for HIV infection in adults and adolescents: recommendations for a public health approach – 2010 revision. Geneva: World Health Organization; 2010.
13. Rabenau HF, Lennemann T, Kircher C, et al. Prevalence- and gender-specific immune response to opportunistic infections in HIV-infected patients in Lesotho. *Sex Transm Dis* 2010; **37**: 454-9.
14. Compston LI, Li C, Sarkodie F, et al. Prevalence of persistent and latent viruses in untreated patients infected with HIV-1 from Ghana, West Africa. *J Med Virol* 2009; **81**: 1860-8.
15. Nyiro JU, Sanders EJ, Ngetsu C, et al. Seroprevalence, predictors and estimated incidence of maternal and neonatal Herpes Simplex Virus type 2 infection in semi-urban women in Kilifi, Kenya. *BMC Infect Dis* 2011; **11**: 155.
16. Mmbaga EJ, Leyna GH, Stray-Pedersen B, et al. Herpes simplex virus type-2 and human immunodeficiency virus infections in a rural population in Kilimanjaro Tanzania. *East Afr J Public Health* 2011; **8**: 28-32.
17. Aubert B, Ballard R, Campbell C, et al. HIV infection among youth in a South African mining town is associated with herpes simplex virus-2 seropositivity and sexual behaviour. *AIDS* 2001; **15**: 885-98.
18. Ghebrekidan H, Rudén U, Cox S, et al. Prevalence of herpes simplex virus type 1 and 2, cytomegalovirus, and varicella-zoster virus infections in Eritrea. *J Clin Virol* 1999; **12**: 53-64.
19. Chakraborty R, Rees G, Bourbouliou D, et al. Viral coinfections among African children infected with human immunodeficiency virus type 1. *Clin Infect Dis* 2003; **36**: 922-4.

20. Lingappa JR, Kahle E, Mugo N, et al. Characteristics of HIV-1 discordant couples enrolled in a trial of HSV-2 suppression to reduce HIV-1 transmission: the partners study. *PLoS One* 2009; **4**: e5272.
21. Pierce N. Effect measures in prevalence studies. *Environ Health Perspect* 2004; **112**: 1047-50.
22. Zochetti C, Consonni D and Bertazzi PA. Relationship between prevalence rate ratios and odds ratios in cross-sectional studies. *Int J Epidemiol* 1997; **26**: 220-3.
23. Smith JS and Robinson NJ. Age-specific prevalence of infection with herpes simplex virus types 2 and 1: a global review. *J Infect Dis* 2002; **186**: S3-28.
24. Uribe-Salas F, Palma-Coca O, Sánchez-Alemán MA, et al. Population-based prevalence of antibodies against herpes simplex virus type 2 and socio-demographic characteristics in Mexico. *Trans R Soc Trop Med Hyg* 2009; **103**: 151-8.
25. Wald A. Herpes simplex virus type 2 transmission: risk factors and virus shedding. *Herpes* 2004; **11**: 130A-7A.
26. Chatterjee K, Dandara C, Gyllensten U, et al. A Fas gene polymorphism influences herpes simplex virus type 2 infection in South African women. *J Med Virol* 2010; **82**: 2082-6.
27. Weiss H. Epidemiology of herpes simplex virus type 2 infection in the developing world. *Herpes* 2004; **11**: 24A-35A.
28. Masuet-Aumatell C, Ramon-Torrell JM, Casanova-Rituerto A, et al. Seroprevalence of varicella-zoster virus infection in children from Cochabamba: tropical or temperate pattern? *Trop Med Int Health* 2013; **18**: 296-302.
29. Alvarez y Muñoz MT, Torres J, Damasio-Santana L, et al. Susceptibility to varicella-zoster infection in individuals 1 to 29 years of age in Mexico. *Arch Med Res* 1999; **30**: 60-3.
30. Silhol R, Alvarez FP, Arena C, et al. Micro and macro population effects in disease transmission: the case of varicella. *Epidemiol Infect* 2010; **138**: 482-90.
31. Nichols RA, Averbek KT, Poulsen AG, et al. Household size is critical to varicella-zoster virus transmission in the tropics despite lower viral infectivity. *Epidemics* 2011; **3**: 12-8.
32. Heininger U, Braun-Fahrländer C, Desgrandchamps D, et al. Seroprevalence of varicella-zoster virus immunoglobulin G antibodies in Swiss adolescents and risk factor analysis for seronegativity. *Pediatr Infect Dis J* 2001; **20**: 775-8.
33. Stowe RP, Kozlova EV, Yetman DL, et al. Chronic herpesvirus reactivation occurs in aging. *Exp Gerontol* 2007; **42**: 563-70.
34. Ogunjimi B, Theeten H, Hens N, et al. Serology indicates cytomegalovirus infection is associated with varicella-zoster virus reactivation. *J Med Virol* 2014; **86**: 812-9.
35. Glaser R, Strain EC, Tarr KL, et al. Changes in Epstein-Barr virus antibody titers associated with aging. *Proc Soc Exp Biol Med* 1985; **179**: 352-5.
36. Stowe RP, Peek MK, Cutchin MP, et al. Reactivation of herpes simplex virus type 1 is associated with cytomegalovirus and age. *J Med Virol* 2012; **84**: 1797-1802.
37. Smith MZ, Bastidas S, Karrer U, et al. Impact of antigen specificity on CD4+ T cell activation in chronic HIV-1 infection. *BMC Infect Dis* 2013; **13**: 100.
38. Haas A, Rehr M, Graw F, et al. HIV-1 replication activates CD4+ T cells with specificities for persistent herpes viruses. *EMBO Mol Med* 2010; **2**: 231-44.
39. Camarena V, Kobayashi M, Kim JY, et al. Nature and duration of growth factor signaling through receptor tyrosine kinases regulates HSV-1 latency in neurons. *Cell Host Microbe* 2010; **8**: 320-30.
40. Sinclair J. Human cytomegalovirus: Latency and reactivation in the myeloid lineage. *J Clin Virol* 2008; **41**: 180-5.
41. Kurth J, Spieker T, Wustrow J, et al. EBV-infected B cells in infectious mononucleosis: viral strategies for spreading in the B cell compartment and establishing latency. *Immunity* 2000; **13**: 485-95.

## SUPPORTING INFORMATION



**Figure S1.** Scatter plots of age and CD4 cell count with specific serum IgG titres for HSV-1, HSV-2 and VZV. Serum IgG titres, presented as binary logarithmic PEI/ml values, were calculated based on corresponding reference sera from the Paul-Ehrlich Institute (Erlangen, Germany). The Spearman correlation test was used for statistical analysis. HSV-1, herpes simplex virus 1; HSV-2, herpes simplex virus; VZV, varicella zoster virus.

**Table S1.** Results of multivariate linear regression analysis of age, gender, ethnicity and CD4 cell count with log2 IgG titre of individual human herpes viruses.

	<b>Beta</b>	<b>P-value</b>	<b>R<sup>2</sup></b>	<b>F-statistic</b>	<b>P-value</b>
<b>HSV-1 IgG titre</b>					
<i>Intercept</i>	6.96				
Age	-0.02	0.8	0.035	3.13	0.02
Gender	-0.17	0.002			
Ethnicity	-0.01	0.9			
CD4 cell count	-0.04	0.5			
<b>HSV-2 IgG titre</b>					
<i>Intercept</i>	6.09				
Age	0.09	0.1	0.014	1.11	0.4
Gender	0.04	0.5			
Ethnicity	-0.06	0.3			
CD4 cell count	0.06	0.3			
<b>VZV-1 IgG titre</b>					
<i>Intercept</i>	10.6				
Age	-0.05	0.4	0.006	0.54	0.7
Gender	-0.05	0.3			
Ethnicity	-0.02	0.38			
CD4 cell count	-0.03	0.6			
<b>EBV IgG titre</b>					
<i>Intercept</i>	7.31				
Age	0.17	<0.001	0.027	3.66	0.006
Gender	-0.03	0.5			
Ethnicity	-0.04	0.5			
CD4 cell count	-0.07	0.2			
<b>CMV IgG titre</b>					
<i>Intercept</i>	9.34				
Age	0.17	0.001	0.076	8.92	<0.001
Gender	0.04	0.4			
Ethnicity	0.03	0.6			
CD4 cell count	-0.25	<0.001			

HSV, herpes simplex virus; VZV, varicella-zoster virus; CMV, cytomegalovirus; EBV, Epstein-Barr virus.





# Chapter 3

## **Clinical and corneal microbial profile of infectious keratitis in a high HIV prevalence setting in rural South Africa.**

Erik Schaftenaar, Remco P.H. Peters, G. Seerp Baarsma, Christina Meenken, N. Sellina Khosa, Sarah Getu, James A. McIntyre, Albert D.M.E. Osterhaus and Georges M.G.M. Verjans.

*Eur J Clin Microbiol Infect Dis*, 2016. In press.

## ABSTRACT

The purpose of this investigation was to determine the clinical and corneal microbial profile of infectious keratitis in a high human immunodeficiency virus (HIV) prevalence setting in rural South Africa. Data in this cross-sectional study were collected from patients presenting with symptoms of infectious keratitis (n=46) at the ophthalmology outpatient department of three hospitals in rural South Africa. Corneal swabs were tested for herpes simplex virus type 1 (HSV-1) and 2 (HSV-2), varicella zoster virus (VZV) and adenovirus DNA by real-time polymerase chain reaction (PCR) and for bacteria and fungi by culture. Based on clinical history, disease characteristics and laboratory results, 29 (63%) patients were diagnosed as viral keratitis, including 14 (48%) viral keratitis cases complicated by bacterial superinfection, and 17 (37%) as bacterial keratitis. VZV and HSV-1 DNA was detected in 11 (24%) and 5 (11%) corneal swabs, respectively. Among clinically defined viral keratitis cases, a negative viral swab was predominantly (93%) observed in cases with subepithelial inflammation and was significantly associated with an increased duration of symptoms ( $P=0.003$ ). The majority of bacteria cultured were Gram-positive (24/35), including *Staphylococcus epidermidis* and *S. aureus*. Viral aetiology was significantly associated with a history of herpes zoster ophthalmicus ( $P<0.001$ ) and a trend was observed between viral aetiology and HIV infection ( $P=0.06$ ). Twenty-one (47%) keratitis cases were complicated by anterior uveitis, of which 18 (86%) were HIV-infected cases with viral keratitis. The data implicate a high prevalence of herpetic keratitis, in part complicated by bacterial superinfection and/or uveitis, in HIV-infected individuals presenting with infectious keratitis in rural South Africa.

## INTRODUCTION

Infectious keratitis is a major cause of ocular morbidity worldwide and the most common cause of unilateral corneal blindness in low-resource settings [1]. The estimated population incidence of infectious keratitis in these settings is up to 800 per 100,000/year, which is about 70-times higher than in high-resource settings [1]. Early diagnosis is essential as visual outcome depends on prompt initiation of targeted antimicrobial treatment [2-3]. The spectrum of keratitis-associated pathogens is diverse and includes viruses, bacteria, fungi and protozoa. Moreover, the clinical picture and aetiology of infectious keratitis varies geographically as it is subject to both environmental and host factors [1-2].

Viruses, in particular human alpha herpesviruses, are well-known in Western countries for causing recurrent and devastating keratitis, but data from sub-Saharan African countries are scarce and solely based on clinical diagnosis [4-6]. The high human immunodeficiency virus (HIV) prevalence in this region may play an important role in the distribution of keratitis-associated pathogens as HIV-infected individuals are at higher risk for viral keratitis, particularly varicella zoster virus (VZV) keratitis [7]. However, management of infectious keratitis in this region predominantly involves (presumptive) antibiotic and/or anti-fungal treatment, which may lead to inappropriate treatment of patients with viral keratitis thereby increasing the risk of visual disability [8]. Elucidation of both the aetiology of infectious keratitis, in particular the potential role of viruses, and the associated clinical picture in a high HIV prevalence setting such as rural South Africa is of paramount importance to improve diagnosis and clinical management aimed to prevent visual impairment and blindness.

The aim of the current study was to determine the clinical and corneal microbial profile of infectious keratitis in a high HIV prevalence setting in rural South Africa.

## MATERIAL AND METHODS

### Study population and setting

This cross-sectional study was conducted at the ophthalmology outpatient department of three hospitals in rural South Africa (Mopani District) between September 2013 and May 2015. Criteria for participation were adult age ( $\geq 18$  years old), no recent history of ocular surgery or trauma, willingness to test for HIV and a clinical diagnosis of keratitis based on slit-lamp examination: inflammation of the cornea with or without the presence of a corneal epithelial defect [2-3, 9]. Contact lens wearers were excluded. Infectious keratitis was classified as viral, bacterial, fungal and/or protozoan on the basis of clinical history (e.g. history of unilateral painful skin rash in the dermatomal distribution of the trigeminal nerve as a sign of VZV infection), disease characteristics (e.g. typical

herpetic corneal dendrites, disciform keratitis or an epithelial defect associated with a larger infiltrate as a sign of bacterial keratitis), laboratory results and response to initiated treatment according to current diagnostic criteria [3, 10-11]. Infectious keratitis patients presenting with uveitis were defined as keratouveitis. Treatment of infectious keratitis was initiated according to standard treatment guidelines for hospitals from the Department of Health of South Africa [12]. Ethical clearance for this study was obtained from the Human Research Ethics Committee (University of the Witwatersrand; Johannesburg, South Africa; project ID: M130201). Written informed consent was obtained from all participants.

### **Ophthalmic examination**

Demographic and clinical data were collected using a questionnaire and full ophthalmic examination performed, including visual acuity using an "illiterate E" Snellen chart at a distance of 6 meters, slit lamp examination, intraocular pressure using the Icare TA01i (Icare Finland Oy; Helsinki, Finland) and dilated indirect funduscopy. Visual acuity after treatment was also determined at routine clinical follow-up visits. Visual impairment was defined according to the International Classification of Diseases on the basis of the individual's visual acuity [13]. Counselling and HIV testing following routine practice were performed for all participants who reported to be HIV-uninfected or were unaware of their HIV status. Diagnostic CD4 counts were determined in all HIV-infected participants.

### **Laboratory analyses**

Corneal samples were collected from the affected eye under topical anaesthesia using a corneal swab and an eyelid spreader to prevent contamination from the eyelids. Due to the lack of ophthalmological care in this region, we chose to perform corneal swabbing instead of corneal scraping as complications due to corneal swabbing are less likely to occur. All samples were collected by the same investigator (author ES). First, a corneal swab for virus detection was obtained in 5 mL collection medium (Puritan diagnostics; Guilford, CT). Viral swabs were examined for herpes simplex virus type 1 (HSV-1), HSV type 2 (HSV-2), VZV and adenovirus DNA by real-time PCR using virus specific primer/probe combinations at the diagnostic laboratory of the department Viroscience (Erasmus Medical Center; Rotterdam, The Netherlands) as described elsewhere [14]. The sensitivity of the virus-specific real-time PCR assays, as defined by the 95% hit rate on the electron microscopy counted virus stocks, was about 100 virus genome-equivalent copies/mL. A second swab (Transystem™) for bacterial and fungal culture (Copan diagnostic Inc.; Murrieta, CA) was obtained from the same eye. Microbial examination, including Gram-stain microscopy and culture was performed on swabs for bacteria and fungi at the Lancet Laboratory according to standard diagnostic procedures (Tzaneen, South Africa).

## Statistical analysis

Data were double-entered into EPI-INFO version 3.5.4 (Centers for Disease Control; Atlanta, GA) and analysed using IBM SPSS Statistics version 22 (IBM; New York City, NY). Descriptions of study population and clinical and laboratory findings is performed using number with proportion and median with interquartile range (IQR) and stratified to HIV status. Demographic, clinical and laboratory factors were compared between different aetiologies of keratitis to identify factors associated with infectious keratitis. Comparison was done by Chi-squared tests with Fisher's Exact if appropriate for categorical variables and Mann-Whitney for continuous variables. Data are presented as odds ratio (OR) with 95% confidence interval (CI) or as median with IQR.

## RESULTS

### Demographics and clinical presentation

We recruited 46 patients clinically diagnosed with infectious keratitis, consisting of 29 (63%) women and 17 (37%) men with median age of 41 (IQR 31–59) years (**Table 1**). Twenty-eight (61%) participants were HIV-infected of which 6 (21%) were tested reactive to HIV for the first time and 13 (46%) were on antiretroviral therapy (ART). Median CD4 count at enrolment was 226 (IQR 156–329) CD4 T-cells/mm<sup>3</sup> for those on ART and 299 (IQR 160–396) CD4 T-cells/mm<sup>3</sup> for ART naïve participants.

Reduced vision was the most common complaint reported at enrolment (100%) followed by eye pain (96%), tearing (72%) and photophobia (65%). Median duration of symptoms was 19 (IQR 11–38) days. Twenty-six (57%) patients had been referred from a primary healthcare (PHC) facility. Fourteen (30%) patients reported use of topical antibiotic eye ointment (Chloramphenicol) prior to inclusion, unfortunately only 3 patients (21%) used the ointment adequately. At ophthalmic examination, an epithelial defect was the most common observed clinical characteristic (65%) followed by signs of anterior chamber inflammation (52%). Corneal infiltration was the most common clinical characteristic associated with an epithelial defect (33%) followed by corneal dendrites (27%), punctate epithelial keratitis (20%) and corneal ulceration (20%). In cases of sub-epithelial inflammation, stromal keratitis was the most observed clinical characteristic (56%) followed by subepithelial infiltration (31%) and endothelial inflammation (13%). An intraocular pressure of >21 mmHg was observed in 9 of 43 (21%) patients.

### Microbial laboratory analyses on corneal swabs

Viral DNA was detected from corneal swabs in 16 of 45 (36%) patients; one viral corneal swab was unavailable for viral diagnostics. Whereas HSV-2 and adenovirus DNA was un-

**Table 1.** Characteristics of infectious keratitis patients enrolled in this study.

	HIV infected (n=28)	HIV uninfected (n=18)	Crude odds ratio (95% CI)	P-value
Gender				
Female	22 (76)	7 (24)	5.8 (1.6–21.3)	0.01
Male	6 (35)	11 (65)		
Age in years	38 (31–45)	52 (27–72)	na	0.19
Ethnicity				
Sotho	19 (66)	10 (34)	1.7 (0.5–5.7)	0.53
Shangaan	9 (53)	8 (47)		
Low educational status	10 (36)	9 (50)	0.6 (0.2–1.9)	0.37
Low financial income	22 (79)	14 (78)	1.0 (0.3–4.4)	1.00
CD4 cell count in cells/mm <sup>3</sup>	254 (162–353)	Na	na	na
Days between onset of eye complaints and presentation	18 (11–49)	23 (9–38)	na	0.93
Referred from primary healthcare facility	18 (64)	8 (44)	2.3 (0.7–7.5)	0.23
Use of topical antibiotics prior enrolment	10 (36)	4 (22)	1.9 (0.5–7.5)	0.51
Diagnosis (clinical and laboratory data combined)				
Viral keratitis (n=15)	10 (67)	5 (33)	3.7 (1.1–13.3) <sup>a</sup>	0.06
Viral and bacterial keratitis (n=14)	11 (79)	3 (21)		
Bacterial keratitis (n=17)	7 (41)	10 (59)		

Data are shown as number (%) or median (interquartile range). CI, Confidence interval; P-value, Pearson Chi-square or Mann-Whitney U test; na, not applicable; HIV, human immunodeficiency virus.

<sup>a</sup>Crude odds ratio and P-value were calculated for viral keratitis (including viral and bacterial keratitis) vs. bacterial keratitis.

detectable by PCR, 11 (24%) and 5 (11%) swabs were positive for VZV [median PCR cycle threshold (Ct) value of 37.0 (IQR 32.2–38.9)] and HSV-1 [median PCR Ct value of 33.0 (IQR 26.6–36.7)] DNA, respectively (**Table 2**). Bacteria were cultured from corneal swabs of 29 (63%) patients, mainly Gram-positive bacteria (69%) with *Staphylococcus epidermidis* as the most common detected bacterium (36%) followed by *S. aureus* (14%) and *S. capitis* (9%). Based on clinical history, disease characteristics, laboratory results and response to initiated treatment (i.e. antibiotics or antiviral), 29 (63%) patients were diagnosed as viral keratitis, including 14 (48%) viral keratitis cases complicated by bacterial superinfection and 17 (37%) as bacterial keratitis (**Table 2**).

Among patients diagnosed with viral keratitis, 15 (52%) corneal swabs were positive for viral DNA and 14 (48%) were negative. Positive viral swabs were predominantly obtained from cases with epithelial inflammation (67%) with dendritic corneal lesions (70%) as the most common epithelial inflammation followed by geographic ulcers (20%). Negative viral swabs were predominantly obtained from cases with subepithelial inflammation (13 of 14, 93%). Only in one (7%) case with an epithelial inflammation, presenting with

**Table 2.** Aetiology of infectious keratitis defined by clinical and laboratory diagnostic methods.

	HSV-1 PCR <sup>POS</sup>	VZV PCR <sup>POS</sup>	Microbial culture positive
<b>HIV infected patients (n=28):</b>			
<b>Viral keratitis (n=10)</b>			
Laboratory confirmed diagnosis (n=4)	n=2	n=2	No bacterium cultured
Clinical diagnosis only (n=6)	None	None	No bacterium cultured
<b>Viral and bacterial keratitis (n=11)</b>			
Laboratory confirmed diagnosis (n=8)	n=1	n=7	<i>Staphylococcus epidermidis</i> (n=3) <i>Staphylococcus aureus</i> (n=2) <sup>a</sup> <i>Bacillus</i> species (n=1) <i>Stenotrophomonas maltophilia</i> (n=1) <i>Staphylococcus epidermidis</i> and <i>Escheria coli</i> (n=1)
Clinical diagnosis only (n=3)	None	None	<i>Staphylococcus capitis</i> (n=1) <i>Staphylococcus epidermidis</i> (n=1) <i>Enterobacter cloacae</i> (n=1)
<b>Bacterial keratitis (n=7)<sup>b</sup></b>			
Laboratory confirmed diagnosis (n=7)	None	None	<i>Staphylococcus epidermidis</i> (n=2) <i>Pseudomonas aeruginosa</i> (n=2) <i>Staphylococcus capitis</i> (n=1) <i>Staphylococcus aureus</i> and <i>Streptococcus viridans</i> (n=1) <i>Corynebacterium</i> , <i>Enterococcus faecalis</i> , <i>Escheria coli</i> and <i>Candida albicans</i> (n=1)
Clinical diagnosis only (n=0)	None	None	No bacterium cultured
<b>HIV uninfected patients (n=18):</b>			
<b>Viral keratitis (n=5)</b>			
Laboratory confirmed diagnosis (n=2)	n=2	None	No bacterium cultured
Clinical diagnosis only (n=3)	None	None	No bacterium cultured
<b>Viral and bacterial keratitis (n=3)</b>			
Laboratory confirmed diagnosis (n=1)	None	n=1	<i>Staphylococcus aureus</i> and <i>Proteus mirabilis</i> (n=1)
Clinical diagnosis only (n=2)	None	None	<i>Staphylococcus epidermidis</i> (n=1) <i>Staphylococcus capitis</i> and <i>Acinetobacter haemolyticus</i> (n=1)
<b>Bacterial keratitis (n=10)</b>			
Laboratory confirmed diagnosis (n=8)	None	n=1 <sup>c</sup>	<i>Staphylococcus epidermidis</i> (n=4) <i>Staphylococcus aureus</i> (n=1) <i>Pseudomonas aeruginosa</i> (n=1) <i>Staphylococcus epidermidis</i> and <i>Proteus mirabilis</i> (n=1) <i>Streptococcus viridans</i> and <i>Haemophilus influenza</i> (n=1)
Clinical diagnosis only (n=2)	None	None	No growth in culture (n=2)

HIV, human immunodeficiency virus; HSV-1, herpes simplex virus type 1; VZV, varicella zoster virus.

<sup>a</sup>HSV-1 DNA was detected in combination with *Staphylococcus aureus*

<sup>b</sup>One viral corneal swab was unavailable after transport.

<sup>c</sup>Vascular leakage of VZV DNA from extensive corneal neovascularisation most likely resulted in detection of VZV DNA.

a dendritic lesion typical for HSV-1 epithelial keratitis, no viral DNA could be detected. Notably, subepithelial inflammation was significantly associated with higher median PCR Ct values [median of 38.2 (IQR 37.4–39.1)] for subepithelial inflammation vs. 32.6 (IQR 26.7–35.0) for epithelial inflammation,  $P=0.005$ ). Furthermore, viral DNA negative swabs were significantly associated with an increased duration of symptoms [median of 37 (IQR 23–92)] days for cases with DNA negative swabs vs. 14 (IQR 6–18) days for cases with DNA positive swabs,  $P=0.003$ ). A reported history of herpes zoster ophthalmicus (OR=46.9, 95% CI 7.4–287.6;  $P<0.001$ ) was associated with a viral aetiology of keratitis and a trend between viral aetiology and HIV infection (OR=3.7, 95% CI 1.1–13.3;  $P=0.06$ ) was also observed. Among viral keratitis cases, a bacterial superinfection was associated with lower CD4 cell counts [median of 168 (IQR 92–322)] cells/mm<sup>3</sup> for viral keratitis with bacterial superinfection vs. 312 (IQR 212–490) cells/mm<sup>3</sup> for viral keratitis,  $P<0.05$ ).

Twenty-one (47%) keratitis cases were complicated by anterior uveitis of which 18 (86%) were viral keratitis (**Table 3**). Viral DNA was detected in corneal swabs of 11 of 18 (61%) keratouveitis patients: VZV ( $n=10$ ) and HSV-1 ( $n=1$ ). Keratouveitis cases were significantly more common among HIV-infected than HIV-uninfected individuals (OR=16.9, 95% CI 3.2–89.7,  $P<0.001$ ), among patients with an intraocular pressure of  $>21$  mmHg

**Table 3.** Factors associated with the development of uveitis in infectious keratitis patients.

	<b>Uveitis present (n=21)</b>	<b>Uveitis absent (n=25)</b>	<b>Crude odds ratio (95% CI)</b>	<b>P-value</b>
Gender				
Female	16 (55)	13 (45)	3.0 (0.8–10.6)	0.13
Male	5 (30)	12 (70)		
Age in years	38 (32–49)	41 (30–62)	na	0.68
Low educational status	10 (53)	9 (47)	1.6 (0.5–5.3)	0.55
Low financial income	18 (86)	18 (72)	2.3 (0.5–10.5)	0.26
HIV infected	19 (91)	9 (36)	16.9 (3.2–89.7)	$<0.001$
CD4 cell count in cells/mm <sup>3</sup>	226 (137–332)	343 (194–427)	na	0.09
Days between onset of eye complaints and presentation	18 (11–45)	24 (9–39)	na	0.97
Intraocular pressure of $>21$ mmHg	7 (33)	2 (9) <sup>a</sup>	5.0 (0.9–27.7)	0.05
Diagnosis (clinical and laboratory data combined)				
Viral keratitis ( $n=15$ )	7 (47)	8 (53)	7.6 (1.8–32.7) <sup>b</sup>	0.005
Viral and bacterial keratitis ( $n=14$ )	11 (79)	3 (24)		
Bacterial keratitis ( $n=17$ )	3 (18)	14 (82)		

Data are shown as number (%) or median (interquartile range). CI, Confidence interval; P-value, Pearson Chi-square or Mann-Whitney U test; na, not applicable; HIV, human immunodeficiency virus.

<sup>a</sup>Three keratitis patients without uveitis had no recorded intraocular pressure.

<sup>b</sup>Crude odds ratio and P-value were calculated for viral keratitis (including viral and bacterial keratitis) vs. bacterial keratitis.



than  $\leq 21$  mmHg (OR=5.0, 95% CI 0.9–27.7; P=0.05) and among viral than bacterial aetiology (OR=7.6, 95% CI 1.8–32.7; P=0.005). Also, a trend between lower CD4 cell counts and uveitis was observed among those with HIV-infection [median of 226 (IQR 137–332)] cells/mm<sup>3</sup> for keratouveitis vs. 343 (IQR 194–427) cells/mm<sup>3</sup> for keratitis, P=0.09).

### **Clinical outcome of disease**

Follow-up after treatment initiation was poor. Thirty-four of 46 (74%) patients had one or more follow-up visits and the median follow-up time was 7 (IQR 7–28) days. The affected eye was visually impaired at the last follow-up visit after treatment initiation in 17 of 34 (50%) patients of which 8 (47%) were blind. Severe visual impairment and blindness was significantly associated with increased duration of symptoms [median of 36 (IQR 20–112)] days for severe visual impairment and blindness vs. 14 (IQR 6–37) days for no severe visual impairment and blindness (P=0.02). Adjusting for duration of symptoms, no demographic or clinical characteristics were associated with severe visual impairment and blindness (data not shown). Notably, a bacterial superinfection in viral keratitis patients was not associated with poorer outcome after treatment.

## **DISCUSSION**

This study reports on the clinical and corneal microbial profile come of infectious keratitis in patients presenting to the ophthalmology outpatient department of three hospitals in a high HIV prevalence setting in rural South Africa. The data implicate that corneal herpesvirus infections, in part complicated by bacterial superinfection and/or uveitis, are relatively more frequently associated with infectious keratitis in HIV-infected individuals with pronounced visual morbidity. A significant association between HIV infection and keratouveitis was noted, suggesting its potential use as clinical marker to prompt investigation of the patient's HIV status.

The observed high frequency of viral aetiology of infectious keratitis in our study has not been described before in sub-Saharan Africa and is higher than observations in similar studies from Australia and China [2, 15]. The major role of herpesviruses might be due to the high HIV prevalence, because a trend was observed between HIV-infection and viral keratitis. Our data are in line with observations reporting increased susceptibility of HIV-infected individuals to viral keratitis [7]. We identified VZV as the most prevalent viral cause of infectious keratitis in our study population. This contrasts previous studies from sub-Saharan Africa and high-resource countries that report a predominant role of HSV-1 causing viral keratitis [5-6, 16]. The important role of VZV in our study might be due to the high HIV prevalence as HIV-infected individuals are at higher risk for VZV keratitis than for HSV-1 keratitis [7, 17]. Unfortunately, previous studies from sub-Saharan Africa

did not report on the patients' HIV status [5-6]. Reasons for the observed minor role of HSV-1 in our study remain unclear as seroprevalence of HSV-1 among HIV-infected ART naïve individuals in our setting is very high (98%) [18]. Adenovirus was not detected in our study, which contrasts earlier studies performed in high-resource settings where adenovirus is identified as an important causative pathogen of keratoconjunctivitis [19]. Studies from sub-Saharan Africa are not available, but our results may suggest that geographical factors play a role in the different pathogen distribution observed.

The distribution of bacterial pathogens, largely Gram-positive bacteria, confirms observations in other studies from sub-Saharan Africa [8, 20]. Bacteria were detected in almost half of the viral keratitis cases and bacterial superinfection was associated with lower CD4 cell count. Although limited data are available on the clinical consequences of bacterial superinfections in viral keratitis, bacterial superinfections may worsen visual outcome of HSV keratitis if appropriate treatment is delayed [21]. In our study, however, poorer visual outcome after treatment was not associated with bacterial superinfection. A fungus (*Candida albicans*) was detected in only one patient diagnosed with bacterial keratitis. This is in sharp contrast to similar studies from Ghana and Tanzania that reported fungi as the causative pathogen in up to 50% of keratitis cases of keratitis [22-23]. This may be due to the exclusion of traumatic keratitis as trauma is one of the most important risk factors for fungal keratitis or due to the geographical differences as fungal keratitis is more likely to occur toward tropical latitudes [2-3].

PCR analyses of corneal swabs supported the clinical observation of viral keratitis in cases with epithelial inflammation. In cases with subepithelial inflammation, however, detection of viral DNA was often negative and, if positive just above the detection limit of the qPCR. This is in line with a study that observed a lower percentage of keratitis cases with positive HSV-1 DNA in patients with subepithelial inflammation compared to patients with epithelial inflammation [24]. Furthermore, increased disease duration was associated with a negative viral swab in cases with a clinical viral keratitis diagnosis.

Anterior uveitis was an important complication of infectious keratitis in our study, in particular in cases of viral aetiology and among HIV-infected individuals. This poses a challenge as management of keratouveitis requires specialized treatment. The association between HIV infection and the development of anterior uveitis, combined with the observed trend between immunodeficiency and anterior uveitis, suggest that cell-mediated immunity plays an important role controlling corneal infection [25-26]. Also, the presence of anterior uveitis might be used as a pointer of HIV infection that indicates the need of HIV counselling and testing in patients presenting with this condition.

The visual outcome at last follow-up visit after treatment of infectious keratitis observed in our study was poor and associated with increased duration of symptoms which confirms observations from a study from Tanzania addressing visual outcome in infectious keratitis [8]. Unfortunately, we did not collect data to determine reasons for

this delay, but both patient- and healthcare system-associated factors may have played a role. A potential contributing factor to the poor visual outcome observed, is initial mismanagement at PHC level as none of the referred patients from PHC facilities received topical antiviral and/or adequate antibiotic treatment.

A limitation to this study is the small sample size which might have resulted in an overestimation of the relationships found. Follow-up studies on larger number of keratitis patients from rural settings with high HIV prevalence are warranted to validate the trends found in this study. Also, we included patients at the outpatient department of hospitals and not at PHC facilities, which may have resulted in some degree of bias towards viral keratitis as potential bacterial keratitis cases were more likely treated successfully at PHC level. In addition, as we excluded patients with traumatic keratitis and contact lens wearers it is likely that there is some degree of bias towards viral keratitis as these are important predisposing factors for microbial keratitis [2]. However, we expect the degree of this bias to be limited as we excluded only two keratitis cases due to trauma and none for the use of contact lenses.

In conclusion, the results of this study implicate that herpetic keratitis, in part complicated by bacterial superinfection and/or uveitis, is relatively more common among HIV-infected individuals presenting with infectious keratitis in rural South Africa. This warrants an increase of the awareness among healthcare workers in these settings for early clinical signs of herpetic keratitis and prompt initiation of antiviral treatment in these cases to prevent blindness. Moreover, the significant association between HIV infection and keratouveitis warrants examination of the patient's HIV status.

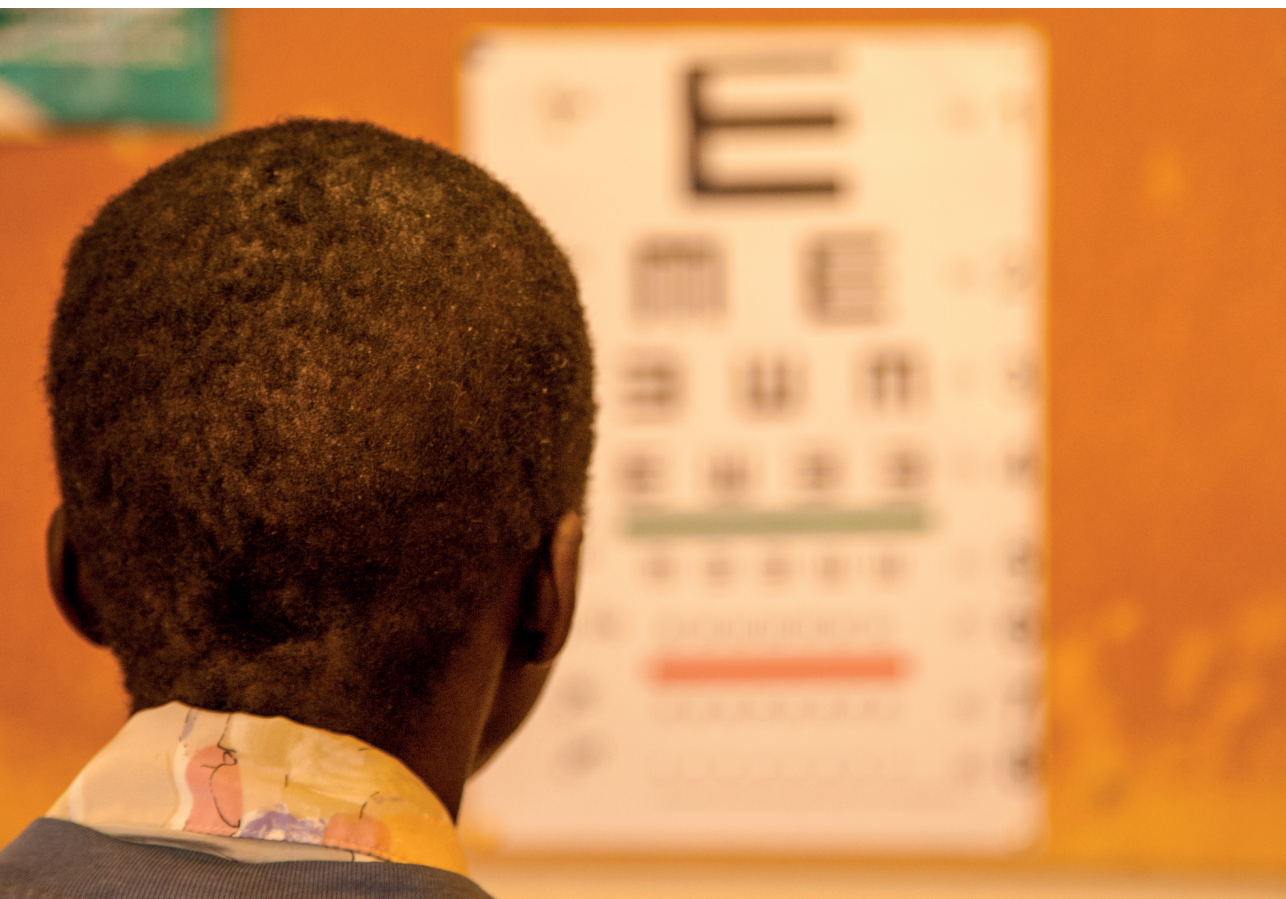## **ACKNOWLEDGEMENTS**

We thank all patients who participated in this study. Our further gratitude goes to the staff of Anova Health Institute and the staff of the ophthalmology outpatient department of the three hospitals in the Mopani District that participated in this study for their invaluable contribution, efforts and support. We also thank Lancet Laboratories in Tzaneen (Tzaneen, South Africa) for providing the workspace to perform serum separation and for providing storage capacity of the serum samples.

**REFERENCES**

1. Upadhyay MP, Srinivasan M and Whitcher JP. Microbial keratitis in the developing world: does prevention work? *Int Ophthalmol Clin* 2007; **47**: 17-25.
2. Keay L, Edwards K, Naduvilath T, et al. Microbial keratitis predisposing factors and morbidity. *Ophthalmology* 2006; **113**: 109-16.
3. Thomas PA and Geraldine P. Infectious keratitis. *Curr Opin Infect Dis* 2007; **20**: 129-41.
4. Newman H and Gooding C. Viral ocular manifestations: a broad overview. *Rev Med Virol* 2013; **23**: 281-94.
5. Yorston D and Foster A. Herpetic keratitis in Tanzania: association with malaria. *Br J Ophthalmol* 1992; **76**: 582-5.
6. Ashaye A and Aimola A. Keratitis in children as seen in a tertiary hospital in Africa. *J Natl Med Assoc* 2008; **100**: 386-90.
7. Hodge WG, Seiff SR and Margolis TP. Ocular opportunistic infection incidences among patients who are HIV positive compared to patients who are HIV negative. *Ophthalmology* 1998; **105**: 895-900.
8. Burton MJ, Pithuwa J, Okello E, et al. Microbial keratitis in East Africa: why are the outcomes so poor? *Ophthalmic Epidemiol* 2011; **18**: 158-63.
9. Schwartz GS, Harrison AR and Holland EJ. Etiology of immune stromal (interstitial) keratitis. *Cornea* 1998; **17**: 278-81.
10. Green LK and Pavan-Langston D. Herpes simplex ocular inflammatory disease. *Int Ophthalmol Clin* 2006; **46**: 27-37.
11. Kaufman SC. Anterior segment complications of herpes zoster ophthalmicus. *Ophthalmology* 2008; **115**: S24-32.
12. The National Department of Health of South Africa. Standard treatment guidelines and essential medicines list for hospital level. The National Department of Health, Pretoria, South Africa; 2012.
13. World Health Organisation. ICD-10 Classifications of Mental and Behavioural Disorder: Clinical Descriptions and Diagnostic Guidelines. World Health Organisation, Geneva; 2015.
14. van Nierop GP, Hintzen RQ and Verjans GM. Prevalence of human Herpesviridae in cerebrospinal fluid of patients with multiple sclerosis and noninfectious neurological disease in the Netherlands. *J Neurovirol* 2014; **20**: 412-8.
15. Cao J, Yang Y, Yang W, et al. Prevalence of infectious keratitis in Central China. *BMC Ophthalmol* 2014; **14**: 43.
16. Liesegang TJ. Herpes simplex virus epidemiology and ocular importance. *Cornea* 2001; **20**: 1-13.
17. Hodge WG and Margolis TP. Herpes simplex virus keratitis among patients who are positive or negative for human immunodeficiency virus: an epidemiologic study. *Ophthalmology* 1997; **104**: 120-4.
18. Schaftenaar E, Verjans GMGM, Getu S, et al. High seroprevalence of human herpesviruses in HIV-infected individuals attending primary healthcare facilities in rural South Africa. *PLoS One* 2014; **9**: e99243.
19. Ghebremedhin B. Human adenovirus: Viral pathogen with increasing importance. *Eur J Microbiol Immunol (Bp)* 2014; **4**: 26-33.
20. Ubani UA. Bacteriology of external ocular infections in Aba, South Eastern Nigeria. *Clin Exp Optom* 2009; **92**: 482-9.
21. Boisjoly HM, Pavan-Langston D, Kenyon KR, et al. Superinfections in herpes simplex keratitis. *Am J Ophthalmol* 1983; **96**: 354-61.

22. Hagan M, Wright E, Newman M, et al. Causes of suppurative keratitis in Ghana. *Br J Ophthalmol* 1995; **79**: 1024-8.
23. Poole TR, Hunter DL, Maliwa EM, et al. Aetiology of microbial keratitis in northern Tanzania. *Br J Ophthalmol* 2002; **86**: 941-2.
24. Kakimaru-Hasegawa A, Kuo CH, Komatsu N, et al. Clinical application of real-time polymerase chain reaction for diagnosis of herpetic diseases of the anterior segment of the eye. *Jpn J Ophthalmol* 2008; **52**: 24-31.
25. Levin MJ, Smith JG, Kaufhold RM, et al. Decline in varicella-zoster virus (VZV)-specific cell-mediated immunity with increasing age and boosting with a high-dose VZV vaccine. *J Infect Dis* 2003; **188**: 1336-44.
26. Kezuka T, Sakai J, Minoda H, et al. A relationship between varicella-zoster virus-specific delayed hypersensitivity and varicella-zoster virus-induced anterior uveitis. *Arch Ophthalmol* 2002; **120**: 1183-8.



# Chapter 4

## **Early- and late-stage ocular complications of herpes zoster ophthalmicus in rural South Africa.**

Erik Schaftenaar, Christina Meenken, G. Seerp Baarsma, James A. McIntyre, Georges M.G.M. Verjans and Remco P.H. Peters.

*Trop Med Int Health* 2016; **21**: 334-9.

## ABSTRACT

**Objectives.** To describe the spectrum of ocular complications of herpes zoster ophthalmicus (HZO) in rural South Africa.

**Methods.** Patients presenting with visual complaints and active or healed HZO at the ophthalmology outpatient department of three hospitals in rural South Africa were included in this study. Demographic and clinical data were collected and HIV status was determined for all participants.

**Results.** Forty-eight patients were included and the majority (81%) were HIV-infected. Poor vision was reported by 94% of patients, painful eye by 79% and photophobia by 63%. A diverse spectrum of ocular complications was observed with corneal inflammation and opacification as the most frequent (77%) followed by anterior uveitis (65%). The majority of patients (65%) presented with late stage ocular complications associated with irreversible loss of vision whereas early stage complications, such as punctate epithelial keratitis and anterior uveitis were less common. Blindness of the affected eye was observed in 68% of patients with late stage complications. There was a considerable delay between onset of symptoms and first presentation to the ophthalmology outpatient department (median time 35 days; range 1-2500 days) and longer delay was associated with late stage ocular complications ( $P=0.02$ ).

**Conclusions.** HZO patients present with relatively late stage ocular complications and blindness among these patients is common. The delayed presentation to the ophthalmology outpatient department of hospitals in our rural setting is of concern and efforts to improve this situation are of paramount importance to improve ocular outcomes of HZO.



## INTRODUCTION

Herpes zoster ophthalmicus (HZO) is the clinical manifestation of reactivation of latent varicella-zoster virus (VZV) infection located within the ophthalmic branch of the trigeminal nerve [1-4]. Due to impaired cell-mediated immunity, human immunodeficiency virus (HIV)-infected individuals are at increased risk of developing HZO (relative incident risk of 6.6) compared to HIV-uninfected individuals [5-8]. If cutaneous HZO is left untreated, ocular involvement occurs in more than half of patients and leads to chronic debilitating pain, visual impairment and eventually (unilateral) blindness [1-3, 9]. These ocular complications are more common among HIV-infected individuals and have a more severe clinical presentation and higher recurrence rate, especially in individuals with low CD4 count [1, 3, 6, 8].

The spectrum of ocular complications of HZO is diverse. Corneal inflammation and opacification (49-89%) and anterior uveitis (43-92%) are the most common complications, but ocular cranial-nerve palsies, neuralgia, eyelid deformities, (blepharo-)conjunctivitis, (epi-)scleritis and optic neuritis may also occur [1-4, 7, 9-13]. In the acute phase of HZO 'early' corneal complications are may develop such as punctate epithelial keratitis and dendritic keratitis; these are associated with minimal risk of visual impairment. However, if left untreated, progression to chronic, late-stage corneal complications with serious visual impairment due to corneal opacification and ulceration may develop [1, 3]. Additionally, in cases where uveitis occurs, mild HZO-associated acute anterior uveitis may progress to sight-threatening stages due to chronic inflammation leading to corneal oedema, iris atrophy, posterior synechiae and cataract formation [3, 7]. Thus, early recognition of ocular involvement in HZO patients and subsequent initiation of targeted oral and topical treatment is essential to prevent ocular morbidity.

South Africa is highly affected by the HIV epidemic and the clinical presentation of dermal HZO is relatively common [14]. Data on ocular manifestations of HZO in HIV-infected sub-Saharan Africans are scarce [9, 14-15]. The aim of this study was to describe the spectrum of ocular complications of HZO and, in particular, to distinguish between early and late stage ocular complications as these impact on visual prognosis.

## MATERIAL AND METHODS

### Study setting and population

This study was conducted at the ophthalmology outpatient department of three hospitals in rural South Africa (Mopani District) and is a sub-analysis of data collected in Anova's Mopani Eye Project. Briefly, this project aimed to improve eye care through a combination of clinical research and health systems strengthening activities. For this

analyses, cases were selected from three ongoing clinical studies initiated with the following objectives: to determine the (1) aetiology of uveitis, (2) aetiology of infectious keratitis and (3) impact of HIV infection and antiretroviral therapy (ART) on the eye (Schafteenaar E, Mopani Eye Project 2015, unpublished data). Adults ( $\geq 18$  years old) with a clinical diagnosis of uveitis or infectious keratitis were included in the first two studies and adults with documented HIV infection, regardless presence of eye complaints, were included in the third study. Individuals presenting in either of these studies with active or healed HZO were included in the current analysis.

HZO diagnosis was defined as presence of a primary vesiculomacular and dysesthetic skin rash or typical scar (with matching clinical history of HZO) within the ophthalmic dermatome [7, 16]. Demographic and clinical data were collected at enrolment in all three studies. Each participant had a full ophthalmic examination, including measurement of visual acuity, slit-lamp examination and dilated indirect ophthalmoscopy. Visual acuity testing was performed using an "illiterate E" Snellen chart at a distance of 6 meter and visual acuity was defined as the lowest line value where at least half the letters were correctly identified by the participant without correction of the affected eye. If visual acuity was  $< 6/60$ , the distance between the Snellen chart and patient was reduced to 3 or 1 meter. If visual acuity was  $< 1/60$ , "hand movements", "light perception" or "no light perception" was recorded. Visual impairment was defined according to the International Classification of Diseases (ICD-10, version 2010) on basis of the individual's visual acuity [17]. The studies were approved by the Human Research Ethics Committee (University of the Witwatersrand; Johannesburg, South Africa) and written informed consent (including ocular photography) was obtained from all participants.

### **Classification of early and late ocular complications**

Ocular complications were classified as "early" or "late" based on stage of disease progression and (potential) restoration of normal vision. The following manifestations were classified as early stage: eyelid oedema, (blepharo-)conjunctivitis, (epi-)scleritis, punctate epithelial keratitis, pseudodendritic or dendritic keratitis, nummular keratitis and/or anterior uveitis [7]. Late stage ocular complications were in case of eyelid scarring, trichiasis, entropion, ptosis, deep stromal keratitis, disciform keratitis, corneal ulceration, neurotrophic keratopathy, necrotising retinitis, retinal detachment and optic neuritis. Although necrotising retinitis and optic neuritis may also occur in the early phase, we decided to include both as late stage ocular complications due to their devastating effect on visual acuity [7].

### **Data analysis**

Data were double-entered and validated using EPI-INFO version 3.5.4 (Centers for Disease Control; Atlanta, GA) and analysed using IBM SPSS Statistics version 22 (IBM; New

Clinical stage	Early corneal involvement	Conjunctival involvement	Conjunctival involvement	Conjunctival involvement	Conjunctival involvement	Conjunctival involvement
<b>Clinical signs</b>	<p>Cutaneous macular rash and vesicles with oedema of the superior eyelid</p> <p>Cutaneous macular rash and vesicles and blepharconjunctivitis</p>	<p>Punctate epithelial keratitis: multiple, focal swollen corneal surface epithelial cells</p> <p>(Pseudodendritic keratitis: elevated plaques of swollen epithelial cells that form a branching pattern)</p>	<p>Nummular keratitis: multiple fine infiltrates immediately beneath corneal surface</p> <p>Stromal keratitis: deep stromal inflammation with lipid infiltrates</p>	<p>Eyelid scarring and neurotrophic keratopathy: generalised corneal epithelial erosions with or without ulceration, calcareous plaque formation, and corneal neovascularisation</p> <p>Severe upper eyelid scarring and corneal opacification due to neurotrophic keratopathy</p>	<p>Anterior keratouveitis: localized stromal oedema, keratic precipitates, cells and flare in the anterior chamber, and posterior synechiae</p> <p>Necrotizing retinitis: vitreous inflammation, necrotizing retinitis, and occlusive vasculitis</p>	<p>Anterior and posterior segment involvement</p>

Figure 1. Spectrum of ocular complications of herpes zoster ophthalmicus.

York City, NY). Description of study population, clinical and laboratory findings were performed using number with proportion and median with range. Comparison was done by Chi-squared tests with Fisher's Exact if appropriate for categorical variables and Mann-Whitney for continuous variables. Data are presented as odds ratio (OR) with 95% confidence interval (CI), mean with standard deviation (SD) or as median with range.

## RESULTS

The study sample (n=48) consisted of 10 (21%) men and 38 (79%) women with a median age of 40 years (range 18-72 years). Thirty-nine (81%) individuals were HIV-infected, with a median CD4 count of 260 cells/mm<sup>3</sup> (range 43-813 cells/mm<sup>3</sup>), of which 25 (64%) received ART. Most cases (n=39; 81%) presented with healed (no active skin lesions) and 9 patients (19%) with active HZO. HZO was unilateral except for two cases. Median days between reported onset of eye complaints and first presentation to the ophthalmology outpatient department was 35 days (range 1-2500 days).

Poor vision (94%) was the most common ocular symptom, followed by a painful eye (79%) and photophobia (63%). A diverse spectrum of ocular HZO complications was observed (**Figure 1**), with corneal inflammation and opacification (77%) as the most common ocular complication followed by anterior uveitis (65%) (**Table 1**). Intraocular complications were more common among HIV-infected than HIV-uninfected individuals (OR=5.8; 95% CI: 1.2–27.6, P<0.05). Scleritis, cranial nerve palsy and optic neuritis was not observed. The majority (n=31; 65%) of patients presented with late stage ocular complications. These patients reported longer time between onset of eye symptoms and presentation to the ophthalmology outpatient department (median of 18 vs. 46 days; P=0.02) and presented more frequently with healed than active HZO (OR=5.1; 95% CI: 1.1–24.0, P=0.05) than those with early stage complications (**Table 2**). However, among individuals presenting with healed HZO, early ocular complications were observed in only 11 (28%) patients and late stage ocular complications were observed in three (33%) patients with active HZO. Visual impairment (81%), including blindness (23 of 39 individuals; 59%), was common and late stage ocular complications were associated with blindness of the affected eye (OR=15.8; 95% CI: 3.0–82.5, P<0.001).

## DISCUSSION

This study reports on the early and late stage ocular complications of HZO patients presenting to the ophthalmology outpatient department of three hospitals in rural South

**Table 1.** Distribution of ocular complications of herpes zoster ophthalmicus by HIV status.

	HIV-infected (n=39)	HIV-uninfected (n=9)	Total (n=48)
<b>Eyelid and conjunctiva</b>			
Eyelid oedema	7 (18)	3 (33)	10 (21)
Eyelid scarring	10 (26)	0 (0)	10 (21)
Eyelid trichiasis	2 (5)	0 (0)	2 (4)
Entropion	1 (3)	0 (0)	1 (2)
Ptosis	8 (21)	0 (0)	8 (17)
Blepharoconjunctivitis	5 (13)	2 (22)	7 (15)
Conjunctivitis	13 (33)	3 (33)	16 (33)
<b>Episclera and sclera</b>			
Episcleritis	3 (8)	0 (0)	3 (6)
Scleritis	0 (0)	0 (0)	0 (0)
<b>Cornea</b>			
Corneal inflammation and opacification	29 (74)	8 (89)	37 (77)
Punctate epithelial keratitis	8 (21)	7 (78)	15 (31)
Pseudo dendritic keratitis	3 (8)	0 (0)	3 (6)
Dendritic keratitis	2 (5)	3 (33)	5 (10)
Nummular keratitis	4 (10)	0 (0)	4 (8)
Stromal keratitis	7 (18)	3 (33)	10 (21)
Disciform keratitis	3 (8)	1 (11)	4 (8)
Corneal ulceration	4 (10)	2 (22)	6 (13)
Neurotrophic keratopathy	14 (36)	3 (33)	17 (35)
Abnormal corneal sensation	12 (31)	2 (22)	14 (29)
<b>Anterior chamber</b>			
Anterior uveitis	28 (72)	3 (33)	31 (65)
Keratouveitis	17 (44)	2 (22)	19 (40)
Posterior synechiae	11 (28)	2 (22)	13 (27)
<b>Posterior segment</b>			
Posterior involvement	4 (10)	0 (0)	4 (8)
Necrotising retinitis	3 (8)	0 (0)	3 (6)
Retinal detachment	2 (5)	0 (0)	2 (4)
Optic neuritis	0 (0)	0 (0)	0 (0)

Data are shown as numbers (%). HIV, human immunodeficiency virus.

Africa. A diverse spectrum of ocular HZO complications was observed. Most patients had late stage ocular complications, which was associated with blindness of the affected eye.

Corneal inflammation and opacification were the most common complication followed by anterior uveitis. This observation is in line with previous studies from Africa and the United States [9, 11-12]. Intraocular complications were more common among

**Table 2.** Early versus late stage ocular complications of herpes zoster ophthalmicus.

	Early stage ocular complications (n=17)	Late stage ocular complications (n=31)	Crude odds Ratio (95% CI)	P-value
Age in years	40 (24-72)	40 (18-71)	na	0.470
Gender				
Male	4 (40)	6 (60)	1.3 (0.3–5.4)	0.727
Female	13 (34)	25 (66)		
HIV-status				
HIV-infected	14 (36)	25 (64)	1.1 (0.2–5.2)	1.000
HIV-uninfected	3 (33)	6 (67)		
CD4 cell count in cells/mm <sup>3</sup>	301 (32-813)	244 (52-670)	Na	0.598
HZO				
Active HZO	6 (67)	3 (33)	5.1 (1.1–24.0) <sup>a</sup>	0.051
HIV-infected	3	3		
HIV-uninfected	3	0		
Healed HZO	11 (28)	28 (72)		
HIV-infected	11	22		
HIV-uninfected	0	6		
Time between onset of eye complaints and presentation to the ophthalmology outpatient department	18 (1-131)	46 (2-2500)	Na	0.016
Reported ocular symptom				
Poor vision	14 (82%)	31 (100%)	–	0.039
Painful eye	17 (100%)	21 (68%)	–	0.009
Photophobia	15 (48%)	15 (88%)	8.0 (1.6–41.0)	0.006
Visual acuity of the affected eye				
≥ 6/18	9 (100)	0 (0)	15.8 (3.0–82.5) <sup>b</sup>	<0.001
< 6/18 but ≥ 6/60	5 (36)	9 (64)		
< 6/60 but ≥ 3/60	1 (50)	1 (50)		
< 3/60	2 (9)	21 (91)		

Data are shown as numbers (%) or median (range). HIV, human immunodeficiency virus; HZO, herpes zoster ophthalmicus; CI, Confidence interval; P-value, Pearson Chi-square or Mann–Whitney *U* test; na, not applicable.

<sup>a</sup>Crude odds ratio and P-value were calculated for active HZO vs. healed HZO between early and late stage ocular complications.

<sup>b</sup>Crude odds ratio and P-value were calculated for visual acuity ≥ 3/60 vs. < 3/60 between early and late stage ocular complications.

HIV-infected than HIV-uninfected individuals. HIV-related immunodeficiency might lead to rapid breach of the corneal defence mechanisms resulting in intraocular inflammation in case of VZV-infection, which is in line with previous studies in which HIV infection was associated with more severe ocular disease in HZO [1, 3, 6, 8]. At enrolment we

observed a significant rate of visual disability and blindness (81%). Although we did not report on visual acuity after HZO-specific treatment, we expect the final rate of visual disability and blindness to be high since the majority presented with late stage manifestations associated with often irreversible visual impairment and blindness [1, 3, 7]. The observed high rate of visual disability was similar to two previous studies from Africa twenty years ago [9, 15].

There was a considerable delay (median time of 35 days) between onset of symptoms and first presentation to the ophthalmology outpatient department; such delay was associated with late stage ocular complications. The association between delay to the ophthalmology outpatient department and late stage complications might be due to delayed initiation of antiviral treatment as early initiation thereof ( $\leq 72$  hours after onset of rash) reduces the risk of progression to late stage ocular complications [3, 18]. The delay observed in our study is long and much higher than reported by a similar study conducted at the ophthalmology outpatient department of the Groote Schuur Hospital (Cape Town, South Africa) in which a median delay of 5 days was reported [14]. Both patient- and healthcare system-associated factors may have contributed to this discrepancy. First, patient delays are generally more common in rural (e.g. Mopani District) than urban (e.g. Cape Town) South African settings. To our knowledge no studies have reported on patient delay in case of HZO or eye complaints, but substantial delays have been reported for other conditions between such settings [19-20]. Second, healthcare system delays are likely to occur, especially in rural settings where ophthalmological expertise and resources are limited and the referral process for ophthalmologic examination is complicated. Unfortunately, we did not record if individuals visited primary healthcare facilities before presenting to our ophthalmology outpatient departments.

Healed HZO was associated with late stage ocular complications. However, seemingly contradictory, early ocular complications were observed in 11 (28%) patients, all of whom were HIV-infected, presenting with healed HZO. Although no demographic and clinical characteristics, including CD4 count, were associated with these 11 patients, the early stage ocular complications observed in these healed HZO patients may be due to higher frequency of local (e.g. corneal) recrudescence of VZV due to HIV-induced immune senescence [5-8]. Also, late stage ocular complications were observed in three (33%) HIV-infected patients with active HZO. Since HIV infection is associated with more severe ocular disease in HZO, these three patients may have developed late stage ocular complications early after onset of disease [1, 3, 6, 8]. Most HZO patients included in our study were HIV infected and were significantly younger than HIV-uninfected individuals. This is in agreement with previous HZO studies from sub-Saharan Africa [9, 12, 14]. Among the HIV-infected individuals, four (10%) HZO patients were tested reactive for HIV for the first time as they were offered provided-initiated HIV testing based on their

clinical presentation. This highlights the importance of providing HIV testing to individuals presenting with HZO as advocated in previous studies [1, 8, 10, 21-22].

A potential limitation is the study design whereby potential HZO patients were selected from three different clinical studies. However, selection bias is unlikely, because any individual with HZO presenting with ocular complaints was eligible for participation in one of our studies. Due to selection of individuals with ocular HZO complications, no inferences could be made about the prevalence of ocular HZO complications in the general population of the Mopani District. Finally, because diagnosis was solely based on the patient's history and clinical characteristics, not all observed ocular HZO complications may be caused directly by VZV as involvement of other viruses or even an ocular bacterial superinfection are optional. However, the latter is unlikely because the sensitivity and specificity of the clinical characteristics in combination with active or healed HZO lesions are very disease-specific [16, 23].

In this study, we demonstrated that HZO patients presenting to the ophthalmology outpatient department of three hospitals in rural South Africa have relatively late stage ocular complications and that this is associated with serious visual impairment and blindness. This emphasizes the importance of early recognition of ocular involvement in HZO and subsequent initiation of appropriate antiviral treatment at primary healthcare level with prompt referral to hospitals with ophthalmology departments to reduce these sight-threatening ocular complications. As such, appropriate antiviral treatment should be available at primary healthcare level, even in rural settings. Furthermore, to prevent HZO-associated ocular morbidity, development of clinical guidelines and training programmes for healthcare workers as well as health system strengthening and community awareness are of paramount importance. These efforts will improve prevention and clinical management of ocular HZO complications and reduce the burden of avoidable visual impairment and blindness in South Africa.

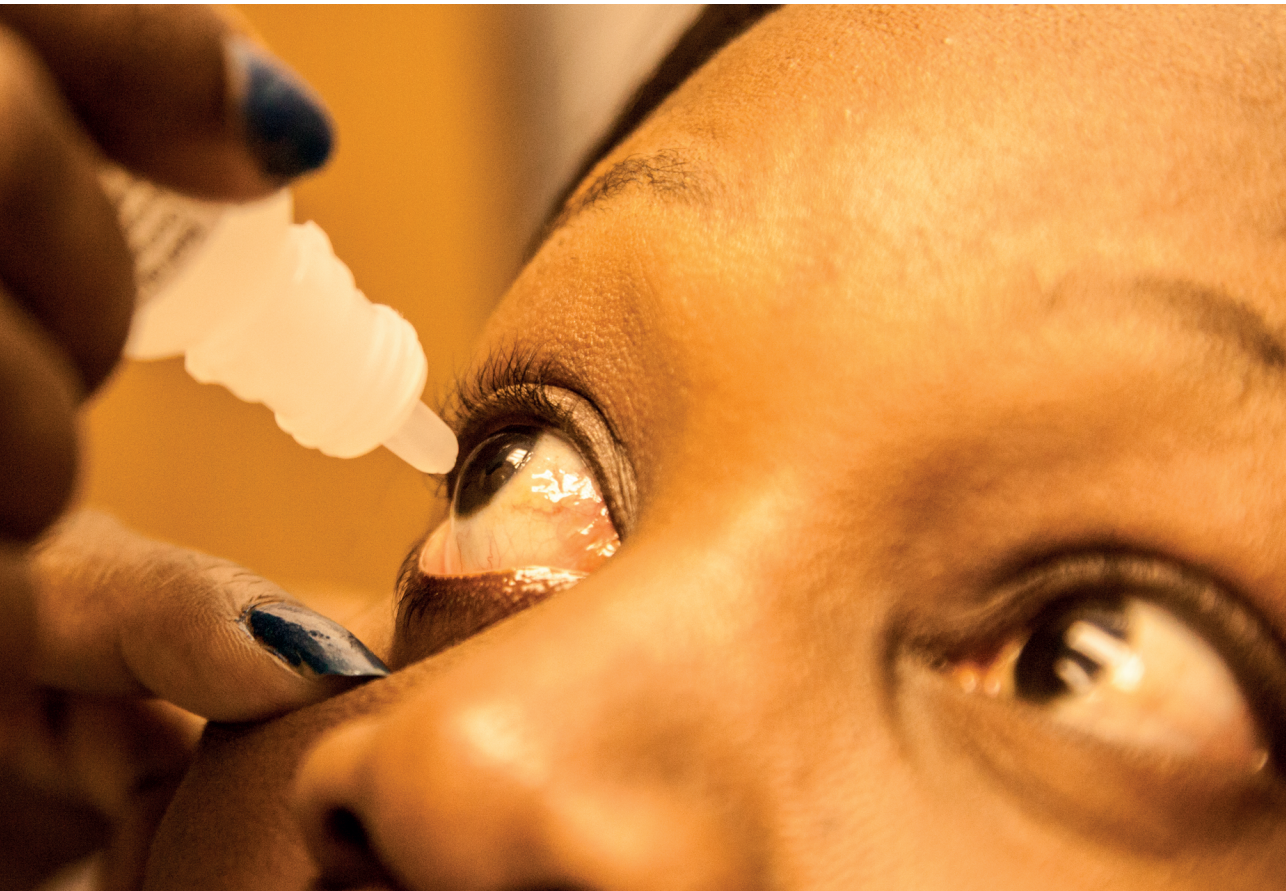## **ACKNOWLEDGEMENTS**

We thank all patients who participated in this study. Our further gratitude goes to the staff of Anova Health Institute (Johannesburg and Tzaneen, South Africa) and the staff of the ophthalmology outpatient department of the three hospitals in the Mopani District that participated in this study for their invaluable contribution, efforts and support. We also thank Vincent Schaftenaar for refining the figure included in this manuscript.



## REFERENCES

1. Vafai A and Berger M. Zoster in patients infected with HIV: a review. *Am J Med Sci* 2001; **321**: 372-80.
2. Marsh RJ and Cooper M. Ophthalmic herpes zoster. *Eye (Lond)* 1993; **7**: 350-70.
3. Liesegang TJ. Herpes zoster virus infection. *Curr Opin Ophthalmol* 2004; **15**: 531-6.
4. Kaufman SC. Anterior segment complications of herpes zoster ophthalmicus. *Ophthalmology* 2008; **115**: S24-32.
5. Buchbinder SP, Katz MH, Hessel NA, et al. Herpes zoster and human immunodeficiency virus infection. *J Infect Dis* 1992; **166**: 1153-6.
6. Hodge WG, Seiff SR and Margolis TP. Ocular opportunistic infection incidences among patients who are HIV positive compared to patients who are HIV negative. *Ophthalmology* 1998; **105**: 895-900.
7. Shaikh S and Ta CN. Evaluation and management of herpes zoster ophthalmicus. *Am Fam Physician* 2002; **66**: 1723-30.
8. Veenstra J, Krol A, Van Pragg RM, et al. Herpes zoster immunological deterioration and disease progression in HIV-1 infection. *AIDS* 1995; **9**: 1153-8.
9. Bayu S and Alemayehu W. Clinical profile of herpes zoster ophthalmicus in Ethiopians. *Clin Infect Dis* 1997; **24**: 1256-60.
10. Ritterband DC and Friedberg DN. Virus infections of the eye. *Rev Med Virol* 1998; **8**: 187-201.
11. Womack LW and Liesegang TJ. Complications of herpes zoster ophthalmicus. *Arch Ophthalmol* 1983; **101**: 42-5.
12. Kestelyn P, Stevens AM, Bakkens E, et al. Severe herpes zoster ophthalmicus in young African adults: a marker for HTLV-III seropositivity. *Br J Ophthalmol* 1987; **71**: 806-9.
13. Harding SP, Lipton JR and Wells JC. Natural history of herpes zoster ophthalmicus: predictors of postherpetic neuralgia and ocular involvement. *Br J Ophthalmol* 1987; **71**: 353-8.
14. Richards JC, Maartens G and Davidse AJ. Course and complications of varicella zoster ophthalmicus in a high HIV seroprevalence population (Cape Town, South Africa). *Eye (Lond)* 2009; **23**: 376-81.
15. Lewallen S. Herpes zoster ophthalmicus in Malawi. *Ophthalmology* 1994; **101**: 1801-4.
16. Liesegang TJ. Herpes zoster ophthalmicus natural history, risk factors, clinical presentation, and morbidity. *Ophthalmology* 2008; **115**: S3-12.
17. World Health Organisation. ICD-10 Classifications of Mental and Behavioural Disorder: Clinical Descriptions and Diagnostic Guidelines. Geneva: World Health Organisation; 2015.
18. Nithyanandam S, Joseph M and Stephen J. Ocular complications and loss of vision due to herpes zoster ophthalmicus in patients with HIV infection and a comparison with HIV-negative patients. *Int J STD AIDS* 2013; **24**: 106-9.
19. Otjombe KN, Variava E, Holmes CB, et al. Predictors of delay in the diagnosis and treatment of suspected tuberculosis in HIV co-infected patients in South Africa. *Int J Tuberc Lung Dis* 2013; **17**: 1199-205.
20. Kong VY, Van der Linde S, Aldous C, et al. Quantifying the disparity in outcome between urban and rural patients with acute appendicitis in South Africa. *S Afr Med J* 2013; **103**: 742-5.
21. Nasoodi A, Lim LT, Al-Ani A, et al. What you can see in your patient's eyes? Review of ocular manifestations of HIV in HAART era. *Int J STD AIDS* 2008; **19**: 4-11.
22. Cunningham ET Jr and Margolis TP. Ocular manifestations of HIV infection. *N Engl J Med* 1998; **339**: 236-44.
23. Takase H, Kubono R, Terada Y, et al. Comparison of the ocular characteristics of anterior uveitis caused by herpes simplex virus, varicella-zoster virus, and cytomegalovirus. *Jpn J Ophthalmol* 2014; **58**: 473-82.



# Chapter 5

**Uveitis is predominantly of infectious origin in a high HIV and TB prevalence setting in rural South Africa.**

Erik Schaftenaar, Christina Meenken, G. Seerp Baarsma, N. Sellina Khosa, Ad Lujendijk, James A. McIntyre, Albert D.M.E. Osterhaus, Georges M.G.M. Verjans and Remco P.H. Peters.

*Br J Ophthalmol*, 2016. In press.

## ABSTRACT

**Aims.** To determine the burden of disease in a unique sample of uveitis patients from a rural South African setting

**Methods.** Data in this cross-sectional study were collected from patients presenting with uveitis (n=103) at the ophthalmology outpatient department of three hospitals in rural South Africa. Demographic and clinical data were collected and laboratory analysis of aqueous humour, serological evaluation and routine diagnostics for tuberculosis were performed.

**Results.** Sixty-six (64%) participants were HIV-infected. Uveitis was predominantly of infectious origin (72%) followed by idiopathic (16%) and autoimmune (12%). Infectious uveitis was attributed to herpesvirus (51%), *Mycobacterium tuberculosis* (24%) and *Treponema pallidum* (7%) infection. HIV-infected individuals were more likely to have infectious aetiology of uveitis compared to HIV-uninfected individuals (83 vs. 51%; P=0.001).

**Conclusion.** Microbial aetiology of uveitis is common in areas where HIV and TB are endemic. In these settings, a high index of suspicion for infectious origin of uveitis is warranted.

## INTRODUCTION

Uveitis is a potential sight-threatening eye condition responsible for up to 25% of all blindness in the developing world [1]. Aetiology is diverse, includes infectious and non-infectious disorders (e.g. autoimmune uveitis), and differs geographically due to host and environmental factors [1-2]. In developed countries uveitis is mostly attributed to non-infectious causes. Data from the African continent are limited, but suggest that infectious diseases play an important role in uveitis [1]. The human immunodeficiency virus (HIV) epidemic impacts greatly on the burden of uveitis in this region. HIV-infected individuals have an increased risk of uveitis, in particular of infectious aetiology, and experience more severe disease [1, 3-4]. Furthermore, the influence of the high tuberculosis (TB) prevalence in this region on uveitis aetiology is unknown.

Early diagnosis and initiation of treatment of uveitis is crucial for good visual outcome, especially in infectious uveitis, and poses a challenge in resource- and ophthalmic skills-constrained settings [3]. Hence, identification of the most likely aetiology and risk factors associated with aetiology are of paramount importance to diagnose and treat uveitis effectively. Available data of uveitis aetiology obtained in developed countries cannot be extrapolated to an African setting due to differences in population age distribution, immunogenetic make-up and ongoing HIV and TB epidemics. Herein, we characterized the burden of uveitis in a rural South African setting with a high HIV and TB prevalence.

## MATERIAL AND METHODS

### Study population and setting

This cross-sectional study was conducted at the ophthalmology outpatient department of three hospitals in rural South Africa (Mopani District) from September 2013 to May 2015. Criteria for participation were adult age ( $\geq 18$  years old), no recent history of ocular surgery or trauma and a diagnosis of uveitis based on observations during slit-lamp and funduscopic examination: keratic precipitates, flare and/or cells in the anterior chamber, flare/haze and/or cells in the vitreous and/or signs of choroiditis, retinitis or retinal vasculitis [2]. Participants had to be willing to test for HIV. This study was approved prospectively by the Human Research Ethics Committee (University of the Witwatersrand; Johannesburg, South Africa; M130202). Written informed consent was obtained from all participants.

### Study procedures

Demographic and clinical data were collected from 103 uveitis patients and full ophthalmic examination performed, including visual acuity using an "illiterate E" Snellen chart at

a distance of 6 meters, slit lamp examination, intraocular pressure using the Icare TA01i (Icare Finland Oy; Helsinki, Finland) and dilated indirect funduscopy. Photographs were taken of the anterior and posterior segment using an Apple I-phone 4S on a slit-lamp adapter and an Optomed Smartscope M5, respectively. Visual impairment was defined according to the International Classification of Diseases [5].

Blood was drawn for serological analysis for *Treponema pallidum* by Treponemal (automated *T. pallidum*-specific chemi-luminescence immunoassay and fluorescent treponemal antibody absorption test) and non-Treponemal (Venereal Disease Research Laboratory) tests. Sputum examination for *Mycobacterium tuberculosis* was conducted using the Xpert MTB/RIF assay (Cepheid Inc.; Sunnyvale, CA) in individuals with productive cough and chest X-ray was done in participants suspected of TB. In participants with severe visual impairment diagnostic aspiration of aqueous humour (AH) was performed. Goldmann-Witmer coefficient (GWC) for the detection of pathogen-specific intraocular antibody production and PCR detection of viral DNA in ocular fluid was performed for herpes simplex virus type 1 (HSV-1) and 2 (HSV-2), varicella zoster virus (VZV), Epstein-Barr virus (EBV) and cytomegalovirus (CMV) to support diagnosis. A virus-specific GWC >3 of AH samples was considered indicative for intra-ocular local antibody production [6-7].

### **Data analysis**

Data were double-entered using EPI-INFO version 3.5.4 (Centers for Disease Control; Atlanta, GA) and analysed using IBM SPSS Statistics version 22 (IBM; New York City, NY). Presumptive aetiology of uveitis, including infectious vs. non-infectious origin, was based on the combination of patient's history, clinical characteristics and laboratory data including analysis of ocular fluid, serological evaluation and sputum and chest X-ray examination. All clinical findings observed during slit-lamp and funduscopic examination were reviewed by a team of uveitis specialists (ES, CM, SB) using the photographs of anterior and posterior segment of the eye. Data were compared between participants with infectious and non-infectious uveitis by Chi-squared test, with Fisher's Exact if appropriate, for categorical variables and Mann-Whitney-Wilcoxon U test for continuous variables. Variables with P-values <0.10 in univariate analysis and age as potential confounder were included in multivariate analysis using logistic regression (forward Likelihood Ratio).

## RESULTS

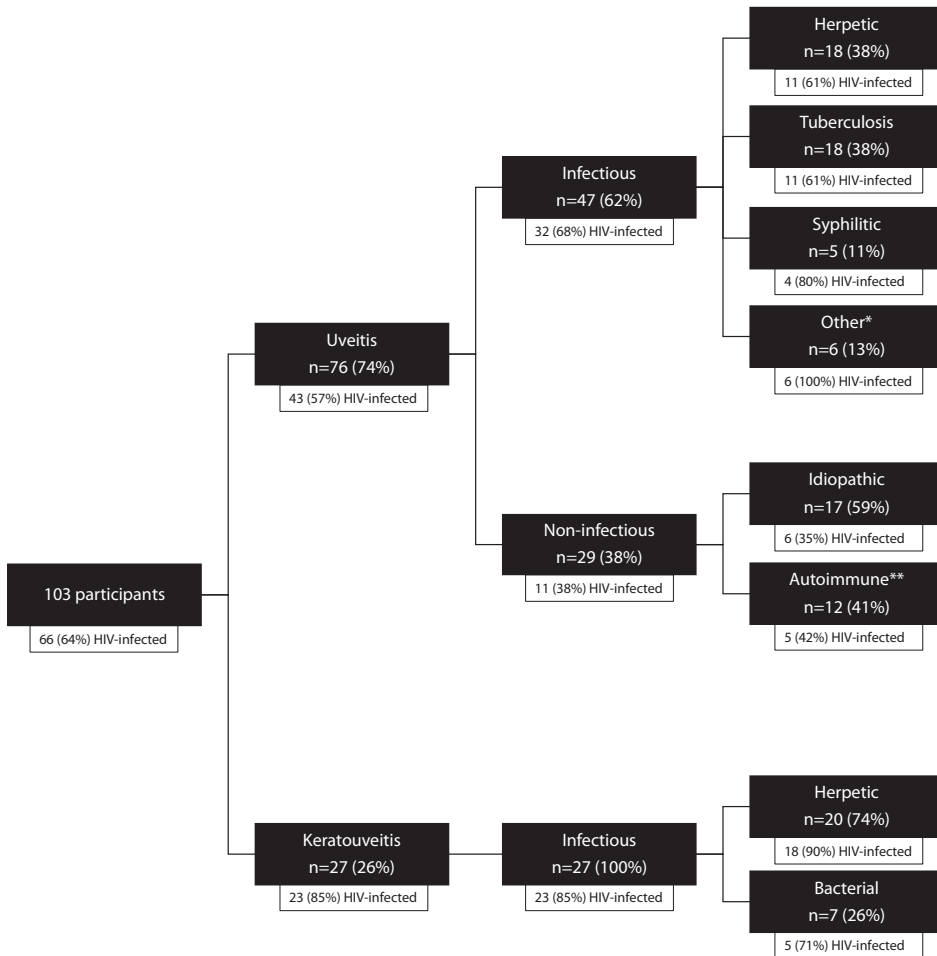
### Demographics and clinical presentation of study population

We recruited 103 uveitis patients with median age of 42 (range 19–83) years including 66 (64%) women. Sixty-six (64%) patients were HIV-infected of which 41 (62%) received antiretroviral therapy (ART). In the latter group and ART-naïve patients the median CD4 count was 226 (range 9–831) and 260 (range 52–813) CD4 T-cells/mm<sup>3</sup>, respectively. The most common symptoms reported were eye pain (91%), poor vision (86%), photophobia (86%) and tearing (61%). Median disease duration was 14 (range 1–296) days. Seventy-two (71%) patients presented with anterior uveitis, 15 (15%) with intermediate uveitis and 13 (13%) with posterior uveitis. Panuveitis was observed in only two patients.

### Aetiology of uveitis

Uveitis was diagnosed as infectious in 74 (72%, 95% CI: 63–82%), idiopathic in 17 (16%, 95% CI: 10–24%) and autoimmune in 12 patients (12%, 95% CI: 6–18%). The group of autoimmune uveitis includes 2 patients (17%) with presumed sarcoidosis-associated uveitis, 2 (17%) patients with Fuchs' heterochromic uveitis and 1 (8%) patient with scleritis-associated uveitis (**Figure 1**). Infectious uveitis was predominantly associated with herpesviruses (51%, 95% CI: 41–64%), followed by *M. tuberculosis* (24%, 95% CI: 15–35%) and *T. pallidum* (7%, 95% CI: 1–14%). The group of other infectious aetiology of uveitis included 8 (61%) patients with presumed bacterial aetiology, 1 (8%) patient of suspected cryptococcal uveitis and 4 (30%) patients with infectious uveitis of unknown origin. Majority of patients (n=76; 74%) presented with uveitis only and 27 (26%) presented with accompanying keratitis, defined as keratouveitis. Infectious uveitis was more common among HIV-infected (83%) compared to HIV-uninfected individuals (51%) (OR=4.7, 95% CI: 1.9–11.8, P=0.001).

AH samples were obtained from 20 (53%) herpetic uveitis patients. VZV-induced uveitis was supported by PCR in 10 (50%) patients (median VZV PCR cycle threshold value of 24.5, range 17.5–34.5) of which 2 also had elevated intra-ocular VZV-specific IgG levels (data not shown) and by GWC alone in 2 patients. Ocular CMV infection was supported by PCR in only one patient. Clinical or laboratory evidence of HSV or EBV as cause of uveitis was not observed. Active *M. tuberculosis* infection was confirmed by chest X-ray examination in 8 of 15 (53%) TB-associated uveitis patients and by Xpert testing of sputum in 3 of 5 with concurrent productive cough. All TB-associated uveitis cases responded to standard TB treatment. *T. pallidum* serology was consistent with syphilitic-associated uveitis in 5 patients; all of whom were positive in three syphilitic tests.



**Figure 1.** Aetiology of uveitis and HIV infection in study participants (n=103)

Uveitis and keratouveitis are shown separately as pathogenesis differs substantially.

\*Including one case of suspected cryptococcal and one case of presumed bacterial uveitis.

\*\*Including two patients with presumed sarcoidosis-associated uveitis, two patients with Fuchs' heterochromic uveitis and one patient with scleritis-associated uveitis.

### Factors associated with uveitis aetiology

The following factors were associated with infectious uveitis (excluding keratouveitis as the pathogenesis thereof is substantially different): history of herpes zoster infection ( $P=0.05$ ), history of TB ( $P=0.02$ ), positive symptom screen for TB ( $P=0.05$ ), HIV infection ( $P=0.017$ ), severe visual impairment at presentation ( $P=0.003$ ), elevated intra-ocular pressure ( $P=0.01$ ) and poster location of uveitis ( $P<0.001$ ) (**Table 1**). By multivariate analysis, HIV infection ( $P=0.02$ ) and severe visual impairment at presentation ( $P=0.002$ ) were independently associated with infectious uveitis.



Among infectious uveitis patients, individuals with TB-associated uveitis were older (median age of 53 vs. 36 years,  $P=0.05$ ) than patients with herpetic uveitis, but other factors were not associated with specific aetiology (data not shown).

**Table 1.** Demographic and clinical characteristics stratified by infectious and non-infectious uveitis.

	Infectious uveitis (n=47)	Non-infectious uveitis (n=29)	Total (n=76)	Crude odds ratio (95% CI)	P-value
<b>Demographics and clinical history</b>					
Gender (male)	19 (40)	9 (31)	28 (37)	1.5 (0.6–4.0)	0.5
Age in years	42 (20–64)	46 (23–69)	43 (20–69)	na	1.0
HIV-status					
HIV-infected on ART	20 (43)	8 (28)	28 (37)	3.5 (1.3–9.2) <sup>a</sup>	0.02
HIV-infected ART naïve	12 (26)	3 (10)	15 (20)		
HIV-uninfected	15 (32)	18 (62)	33 (43)		
CD4 cell count in cells/mm <sup>3</sup>	256 (9–813)	229 (62–831)	235 (9–831)	na	0.5
Positive history of herpes zoster	14 (30)	3 (10)	17 (22)	3.7 (1.0–14.2)	0.05
Positive history of tuberculosis	14 (30)	2 (7)	16 (21)	5.7 (1.2–27.4)	0.02
Screening symptoms of tuberculosis present	23 (49)	7 (24)	30 (40)	3.0 (1.1–8.4)	0.05
Duration of ocular complaints in days	20 (1–296)	7 (2–63)	13 (1–296)	na	<0.0001
<b>Clinical characteristics</b>					
Visual acuity of the affected eye at enrolment					
≥6/18	10 (21)	16 (55)	26 (34)	6.0 (1.8–19.9) <sup>b</sup>	0.003
<6/18 but ≥6/60	14 (30)	9 (31)	23 (30)		
<6/60 but ≥3/60	6 (13)	0 (0)	6 (8)		
<3/60	17 (36)	4 (14)	21 (28)		
Intraocular pressure					
Elevated intra ocular pressure	8 (19)	0 (0)	8 (11)	na	0.01
Normal intra ocular pressure	34 (81)	29 (100)	63 (89)		
Localization of uveitis					
Anterior uveitis	24 (51)	22 (79)	46 (61)	na	<0.0001 <sup>c</sup>
Intermediate uveitis	9 (19)	6 (21)	15 (20)		
Posterior uveitis	13 (28)	0 (0)	13 (17)		
Panuveitis	1 (2)	0 (0)	1 (1)		

Data are shown as number (%) or median (range). CI, Confidence interval; P-value, Pearson Chi-square or Mann-Whitney-Wilcoxon U test; HIV, human immunodeficiency virus; ART, antiretroviral therapy; na, not applicable.

<sup>a</sup>Crude odds ratio and P-value were calculated for HIV-infected vs. HIV-uninfected.

<sup>b</sup>Crude odds ratio and P-value were calculated for patients with visual acuity of < 6/60 (severe visual impairment or blindness) vs. patients with visual acuity of ≥ 6/60 (no to moderate visual impairment).

<sup>c</sup>P-value was calculated for patients in which the posterior segment was affected vs. patients in which the posterior segment was not affected.

## DISCUSSION

This study reports on the aetiology of uveitis in a unique sample of uveitis patients living in rural South Africa. We report that uveitis of infectious aetiology is more common among HIV-infected individuals, in particular uveitis caused by herpesviruses, *M. tuberculosis* and *T. pallidum*. Furthermore, it is not unlikely that some of the patients classified as idiopathic uveitis in this study also had an infectious aetiology of uveitis but could not be detected by the currently available laboratory resources.

The data implicate that infectious uveitis is considerably more common in rural South Africa than reported from other regions of the world, including from other resource-poor settings such as rural India [1, 8]. Given the significant association observed here between HIV infection and infectious uveitis, the difference is most likely due to the high HIV prevalence in the Mopani region [1, 9]. Among HIV-infected individuals, ART did not significantly decrease the risk of infectious uveitis, but this might have been due to the relatively low median CD4 count in HIV-infected uveitis patients on ART. In addition to HIV, other factors such as geographic differences in prevalence of pathogens, infection pressure and socioeconomic factors may also have contributed to higher frequency of infectious uveitis observed [1].

Few studies, all from more than 10 years ago, have reported on the distribution of uveitogenic pathogens in sub-Saharan Africa, mainly diagnosed on clinical rather than on laboratory data [10-13]. Whereas *Toxoplasma gondii* was reported earlier as major uveitis-inducing pathogen, we report on the predominant role of herpesviruses. Notably, none of our participants presented with clinical characteristics suggestive for ocular toxoplasmosis. The high prevalence of herpetic uveitis, mainly VZV, is most likely due to the high herpesvirus infection rate in the Mopani district [13-14]. Congruent with an earlier study from Congo, demonstrating that 38 of 89 uveitis cases among HIV-infected individuals were VZV-induced, VZV was the most common viral cause of infectious uveitis in our study [13]. Despite a CMV seroprevalence of 100% among HIV-infected ART-naïve individuals in the Mopani district, we observed only a single case of CMV retinitis. This confirms previous reports describing CMV as rare cause of uveitis in sub-Saharan Africa, which contrasts studies on uveitis patients from developed countries describing CMV as the most important uveitogenic pathogen among HIV-infected individuals [14-16]. Indeed, a study from Tanzania demonstrated that only 2 of 150 HIV-infected uveitis patients with CD4 counts  $\leq 100$  cells/mm<sup>3</sup> had CMV retinitis, suggesting that factors of virus or host origin contribute to the geographic differences in CMV uveitis prevalence [15].

In addition to herpesviruses, *M. tuberculosis* was a common cause of uveitis in our study confirming previous reports from other TB endemic settings that show an increasing aetiological role of *M. tuberculosis* in uveitis [17]. Indeed, TB uveitis was also the most common cause of infectious uveitis in India [18]. We were able to confirm TB disease by

routine diagnostics in about half of our TB uveitis patients, whereas ocular characteristics observed in eye examination including fundoscopy (e.g. chronic granulomatous uveitis with mutton-fat keratic precipitates or chorioretinal granuloma) were the only evidence of TB in the remaining group. Recognition of *M. tuberculosis* infection as cause of uveitis is of great importance as there is paucity of data and limited awareness of ocular TB involvement. The national TB guidelines of South Africa, one of the countries with highest TB burden globally, does not include any information on diagnosis and management of ocular TB [19].

The contribution of *T. pallidum* infection as cause of infectious uveitis in sub-Saharan Africa is largely unknown. The relative high number of syphilitic uveitis cases reported here is in line with recent observations from non-African countries describing an increasing incidence of ocular syphilis [20-21]. Recognition is important as diagnosis of syphilitic uveitis is difficult as clinical characteristics of syphilitic uveitis are diverse and can simulate any form of uveitis. As such, serological evaluation for syphilis is indicated in uveitis patients from high *T. pallidum* incidence populations.

A potential limitation of our study is that it was conducted at hospital and not at primary healthcare level. This may have resulted in selection bias due to ineffective referral of uveitis cases from primary healthcare facilities to hospitals. It is also likely that mild uveitis cases were missed at primary healthcare level and therefore not presented to the hospital, including cases of immune recovery uveitis as this condition is usually asymptomatic or self-limiting if symptomatic [22]. Another limitation of our study is that diagnostic aspiration of AH was not obtained from all study participants. This may have resulted in underdiagnoses of human herpesvirus induced uveitis.

In conclusion, uveitis confers a complex disease entity with predominantly infectious aetiology in areas where HIV and TB are endemic. In these settings, a high index of suspicion for an infectious origin of uveitis is warranted as guided by clinical and ophthalmological findings and preferably supported by laboratory evaluations. Additionally, HIV counselling and testing should be performed in all patients with uveitis considering the strong association between these two conditions.

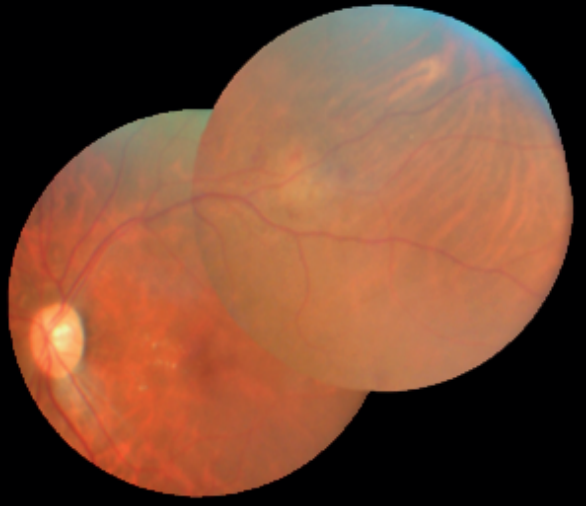
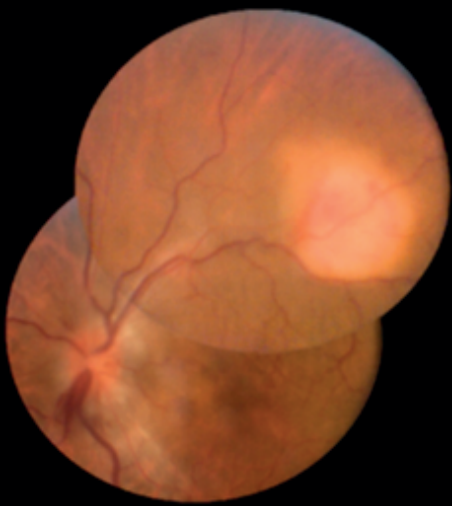## ACKNOWLEDGEMENTS

We thank all patients who participated in this study. Our further gratitude goes to the staff of Anova Health Institute (Johannesburg and Tzaneen, South Africa) and the staff of the ophthalmology outpatient department of the three hospitals in the Mopani District that participated in this study for their invaluable contribution, efforts and support. We also thank Lancet Laboratories in Tzaneen (Tzaneen, South Africa) for providing the workspace to perform serum separation and for providing storage capacity of the serum samples.

**REFERENCES**

1. London NJ, Rathinam SR and Cunningham ET Jr. The epidemiology of uveitis in developing countries. *Int Ophthalmol Clin* 2010; **50**: 1-17.
2. Jabs DA, Nussenblatt RB and Rosenbaum JT; Standardization of Uveitis Nomenclature (SUN) Working Group. Standardization of uveitis nomenclature for reporting clinical data. Results of the First International Workshop. *Am J Ophthalmol* 2005; **140**: 509-16.
3. Schaftenaar E, van Gorp EC, Meenken C, et al. Ocular infections in sub-Saharan Africa in the context of high HIV prevalence. *Trop Med Int Health* 2014; **19**: 1003-14.
4. Wells JM and Smith JR. Uveitis in human immunodeficiency virus-infected individuals. *Int Ophthalmol Clin* 2015; **55**: 11-8.
5. World Health Organisation. ICD-10 Classifications of Mental and Behavioural Disorder: Clinical Descriptions and Diagnostic Guidelines. World Health Organisation, Geneva, 2015.
6. Luyendijk L, vd Horn GJ, Visser OH, et al. Detection of locally produced antibodies to herpes viruses in the aqueous of patients with acquired immune deficiency syndrome (AIDS) or acute retinal necrosis syndrome (ARN). *Curr Eye Res* 1990; **9**: 7-11.
7. De Groot-Mijnes JD, Rothova A, Van Loon AM, et al. Polymerase chain reaction and Goldmann-Witmer coefficient analysis are complimentary for the diagnosis of infectious uveitis. *Am J Ophthalmol* 2006; **141**: 313-8.
8. Miserocchi E, Fogliato G, Modorati G, et al. Review on the worldwide epidemiology of uveitis. *Eur J Ophthalmol* 2013; **23**: 705-17.
9. Jabs DA. Ocular manifestations of HIV infection. *Trans Am Ophthalmol Soc* 1995; **93**: 623-83.
10. Runday MJ, Stilma JS, Barbe RF, et al. Aetiology of uveitis in Sierra Leone, west Africa. *Br J Ophthalmol* 1996; **80**: 956-61.
11. Kaimbo Wa Kimbo D, Bifuko A, Dernouchamps JP, et al. Chronic uveitis in Kinshasa (D R Congo). *Bull Soc Belge Ophthalmol* 1998; **270**: 95-100.
12. Ayanru JO. The problem of uveitis in Bendel State of Nigeria: experience in Benin City. *Br J Ophthalmol* 1977; **61**: 655-9.
13. Mwanza JC and Kayembe DL. Uveitis in HIV-infected patients. *Eur J Ophthalmol* 2001; **11**: 53-6.
14. Schaftenaar E, Verjans GM, Getu S, et al. High seroprevalence of human herpesviruses in HIV-infected individuals attending primary healthcare facilities in rural South Africa. *PLoS One* 2014; **9**: e99243.
15. Nirwoth JP, Hall AB and Lewallen S. Prevalence of cytomegalovirus retinitis in Tanzanians with low CD4 levels. *Br J Ophthalmol* 2011; **95**: 460-2.
16. Jabs DA. Cytomegalovirus retinitis and the acquired immunodeficiency syndrome--bench to bedside: LXVII Edward Jackson Memorial Lecture. *Am J Ophthalmol* 2011; **151**: 198-216.
17. Abu El-Asrar AM, Abouammoh M and Al-Mezaine HS. Tuberculous uveitis. *Int Ophthalmol Clin* 2010; **50**: 19-39.
18. Singh R, Gupta V and Gupta A. Pattern of uveitis in a referral eye clinic in north India. *Indian J Ophthalmol* 2004; **52**: 121-5.
19. Department of Health, Republic of South Africa. National Tuberculosis Management Guidelines 2014. Department of Health, Republic of South Africa, Pretoria, 2014.
20. Fonollosa A, Giralt J, Pelegrín L, et al. Ocular syphilis--back again: understanding recent increases in the incidence of ocular syphilitic disease. *Ocul Immunol Inflamm* 2009; **17**: 207-12.

21. Rose-Nussbaumer J, Goldstein DA, Thorne JE, et al. Uveitis in human immunodeficiency virus-infected persons with CD4+ T-lymphocyte count over 200 cells/mL. *Clin Experiment Ophthalmol* 2014; **42**: 118-25.
22. Oti-Sengeri J, Meenken C, van den Horn GJ, et al. Ocular immune reconstitution inflammatory syndromes. *Curr Opin HIV AIDS* 2008; **3**: 432-7.



# Chapter 6

## **Good visual outcome of tuberculous chorioretinitis after ART initiation in a HIV-infected patient.**

Erik Schaftenaar, Christina Meenken, G. Seerp Baarsma, Georges M.G.M. Verjans and Remco P.H. Peters.

*Int Ophthalmol* 2014; **34**: 1263-5.

## **ABSTRACT**

*Mycobacterium tuberculosis* infection is an important cause of sight-threatening chorioretinitis in HIV-infected individuals living in *M. tuberculosis* endemic areas. We present a case of tuberculous chorioretinitis in a HIV-infected man after recent initiation of antiretroviral therapy in rural South Africa, who had nearly complete resolution of clinical signs and symptoms after standard tuberculosis treatment. His presentation was most likely associated with immune reconstitution inflammatory syndrome.



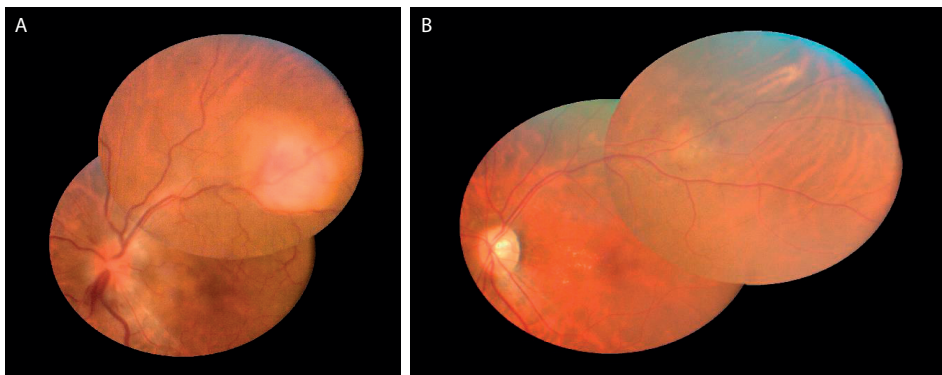
## INTRODUCTION

Ocular tuberculosis (TB), including tuberculous chorioretinitis, is an important and sight-threatening condition in human immunodeficiency virus (HIV)-infected individuals [1-3]. TB associated with immune reconstitution inflammatory syndrome (IRIS) after antiretroviral therapy (ART) initiation is a specific condition that is well-documented for pulmonary disease, but not for ocular presentation.

## CASE

A 57-year-old HIV-infected man presented at the eye clinic of a hospital in rural South Africa. The patient complained of an acute loss of vision, ocular pain and photophobia of the left eye for two weeks without any other systemic complaints. Three months earlier he had initiated ART at low CD4 count (135 cells/ $\mu$ L). He was successfully treated for pulmonary tuberculosis more than a decade ago.

On examination, visual acuity in the left eye was only 'hand motion' and vision in the right eye was normal. Slit-lamp examination of the left eye showed mild anterior-chamber inflammation without posterior synechiae. At fundoscopic examination a chorioretinal granuloma was observed in the superotemporal quadrant of the retina accompanied by papilledema, retinal vasculitis and minimal vitritis (binocular indirect ophthalmoscope score of 1) (**Figure 1A**). There were no other signs of active TB and chest X-ray was consistent with past TB. Unfortunately, valuable additional investigations like optical coherence tomography and interferon gamma release assays are not available in rural South Africa.



**Figure 1.** (A) Fundus photograph of the left eye at presentation showing a chorioretinal granuloma, papilledema, retinal vasculitis and minimal vitritis. (B) Fundus photograph of the left eye after two months, on standard *Mycobacterium tuberculosis* treatment and topical corticosteroid eye drops, showing an almost completely resolved granuloma, no papilledema and hard exudates within the macula.

Based on the typical retinal abnormalities a diagnosis of TB chorioretinitis, most likely associated with immune reconstitution inflammatory syndrome (IRIS), was established. TB treatment and topical corticosteroid eye drops were given. Two months later the ocular granuloma had almost completely resolved, and the papilledema and retinal vasculitis had normalised (**Figure 1B**). Post-infectious hard exudates within the macula remained. Visual acuity had improved dramatically to nearly normal vision (6/7,5).

## **COMMENT**

Ocular TB is an important infectious ocular disease among HIV-infected individuals and may involve the anterior and posterior segment of the eye [1-3]. Although introduction of ART has led to a decrease in ocular infections, ocular IRIS is a serious complication of HIV-infected individuals who are initiated on ART, particular those with a low CD4 cell count [1, 4]. Unlike pulmonary infection, tuberculous chorioretinitis without other signs has rarely been described as ocular manifestation of IRIS [5]. TB-IRIS may result from paradoxical worsening of previously treated infection or from unmasking of a subclinical or unrecognised infection after the initiation of ART [1, 4]. Treatment options of ocular TB, including TB chorioretinitis, are identical to other extra-pulmonary types of TB and may be supplemented with topical steroids [3, 6]. Visual outcome is usually good if recognised promptly and treated adequately [2-3, 6].

## **ACKNOWLEDGEMENTS**

We thank Gerard de Graaf and Fabienne Wink from the Rotterdam Eye Hospital (Rotterdam, The Netherlands) for refining the pictures included in this manuscript.

**REFERENCES**

1. Schaftenaar E, van Gorp EC, Meenken C, et al. Ocular infections in sub-Saharan Africa in the context of high HIV prevalence. *Trop Med Int Health* 2014; **19**: 1003-14.
2. Basu S, Monira S, Modi RR, et al. Degree, duration, and causes of visual impairment in eyes affected with ocular tuberculosis. *J Ophthalmic Inflamm Infect* 2014; **4**: 3.
3. Thompson MJ and Albert DM. Ocular tuberculosis. *Arch Ophthalmol* 2005; **123**: 844-9.
4. Oti-Sengeri J, Meenken C, van den Horn GJ, et al. Ocular immune reconstitution inflammatory syndromes. *Curr Opin HIV AIDS* 2008; **3**: 432-7.
5. Lawn SD, Myer L, Bekker LG and Wood R. Tuberculosis-associated immune reconstitution disease: incidence, risk factors and impact in an antiretroviral treatment service in South Africa. *AIDS* 2007; **21**: 335-41.
6. Abu El-Asrar AM and Al-Mezaine HS. Anti-tuberculous therapy combined with systemic corticosteroids improves retinal sensitivity in patients with active presumed tuberculous choroiditis. *Int Ophthalmol* 2010; **30**: 567-76.



# Chapter 7

**HIV-infected individuals on long-term antiretroviral therapy are at higher risk for ocular disease.**

Erik Schaftenaar, N. Sellina Khosa, G. Seerp Baarsma, Christina Meenken, James A. McIntyre, Albert D.M.E. Osterhaus, Georges M.G.M. Verjans and Remco P.H. Peters.

Submitted, 2016.





# Chapter 8

## Summarizing discussion

In part based on:

Anterior chamber paracentesis to improve diagnosis and treatment of infectious uveitis in South Africa.

Erik Schaftenaar, Karin A. Lecuona, G. Seerp Baarsma, Christina Meenken, Georges M.G.M. Verjans, James A. McIntyre and Remco P.H. Peters.

*S Afr Med J* 2015; **105**: 628-30.





Ocular diseases are a significant health problem worldwide that impact greatly on quality of life of individuals affected as well as their families and communities [1-4]. The prevalence of visual impairment is unequivocal distributed worldwide and the burden of visual disability is disproportionately high in low-resource countries with up to ninety percent of visually impaired individuals living in these settings [5-7]. Although there is a paucity of local epidemiological and clinical data on visual impairment and ocular disease from sub-Saharan African countries, the coinciding high human immunodeficiency virus (HIV) prevalence most likely contributes not only to the burden of visual impairment, but also increases the role of serious and sight-threatening ocular infections because HIV-infected individuals are at increased risk of developing ocular (infectious) disease [8-13]. For South Africa, 6.8 million individuals are living with HIV, all of whom are at risk of suffering from HIV-related sight-threatening ocular disease due to immunodeficiency [14-16]. However, data on the local epidemiology, aetiology and burden of ocular disease from settings with high HIV prevalence like South Africa are practically unavailable, but highly warranted to improve management of ocular disease and to guide ophthalmological prevention programs [5-6].

The main aim of the studies presented in this thesis was to provide novel insight into ocular diseases in a high HIV prevalence and low-resource setting in rural South Africa. We determined the seroprevalence of human herpesviruses (HHVs), known for their major role in HIV-related ocular disease, in HIV-infected antiretroviral therapy (ART)-naïve individuals (**Chapter 2**). Furthermore, we focused on two major causes of significant ocular morbidity, infectious keratitis and uveitis, by determining the cause and clinical manifestations and present a unique case of tuberculous uveitis in a HIV-infected man shortly after initiation of antiretroviral therapy (ART) (**Chapter 3, Chapter 5 and Chapter 6**). During our studies we identified a public health challenge among HIV-infected individuals with herpes zoster ophthalmicus (HZO), which often resulted in visual impairment. We studied the spectrum of ocular complications of varicella-zoster virus (VZV) infection to provide clinical data to improve management and outcome of individuals with HZO (**Chapter 4**). Finally, the introduction of ART in South Africa has resulted in prolonged survival of HIV-infected individuals and to a shift in the spectrum of ocular disease [17-19]. It is thought that HIV-infected individuals on ART are at increased risk of age-related morbidity and mortality such as cardiovascular disease and diabetes compared with HIV-uninfected individuals [18, 20-21]. However, the long-term effects of ART and chronic HIV infection on the prevalence of ocular disease are largely unknown. We described the distribution of ocular disease and manifestations among HIV-infected individuals with and without ART in rural South Africa (**Chapter 7**).

All studies presented in this thesis were conducted in the rural Mopani District of the Limpopo Province (South Africa). Mopani District is one of South Africa's national priority districts based on poor quality of healthcare and high poverty rates, illiteracy and

unemployment and it has one the highest HIV prevalence rates (24.6% among pregnant women in 2013) in South Africa [22].

## **HUMAN HERPESVIRUSES IN RURAL SOUTH AFRICA**

HHVs are a major cause of ocular morbidity as they frequently cause sight-threatening ocular conditions such as keratitis and uveitis. Among the eight known HHVs, cytomegalovirus (CMV) and particularly the human alphaherpesviruses ( $\alpha$ HHVs) herpes simplex virus type 1 (HSV-1) and VZV are the main keratogenic and uveitogenic HHVs [23]. Seroprevalence of HHVs among the human population is high. However, data from sub-Saharan African countries are limited and seroprevalence rates are known to vary from region to region [24]. The hallmark of HHVs is their ability to establish lifelong latency and reactivate intermittently, which is commonly asymptomatic [25]. HIV-infected individuals are at increased risk for HHV-related disease compared to HIV-uninfected individuals due to an increased risk of symptomatic reactivation as a result of HIV-induced immunodeficiency [26-28]. Available data on HHV-associated ocular disease in HIV-infected individuals are mainly from Western countries such as the United States of America (USA) where CMV retinitis affected up to 40% of HIV-infected individuals in the pre-ART era leading to severe visual impairment [15-16, 29]. CMV retinitis was predominantly observed in individuals with severe immunodeficiency, typically when CD4 cell counts were below 50 cells/mm<sup>3</sup> [15-16]. As ART became widely available, the incidence of CMV retinitis in Western countries decreased significantly as shown by a study from France describing a decreased incidence of newly diagnosed CMV retinitis from 6% before the wide spread use of ART to 1% in the ART era [18, 30]. However, even after the initiation of ART, though to a far lesser extent than in the pre-ART era, HIV-infected individuals are at increased risk of developing HHV-related ocular disease as a result of ART-induced recovery of the host's adaptive immunity potentially leading to debilitating Immune reconstitution inflammatory syndrome (IRIS), also known as immune restoration disease, that may be accompanied with intra-ocular HHV-specific cellular immune responses like immune recovery uveitis due to CMV reactivation [31-32].

Sub-Saharan African countries are hit hardest by the HIV epidemic, but data on the seroprevalence of HHVs among HIV-infected individuals are limited [33]. We addressed this important issue by determining the seroprevalence of HSV-1, HSV-2, VZV, CMV and Epstein-Barr virus (EBV) in a cohort of HIV-infected ART-naïve individuals in rural South Africa. We described that HHV seroprevalence in this population is very high: HSV-1 (98%), HSV-2 (87%), VZV (89%), and 100% for EBV and CMV (**Chapter 2**) [34]. This finding is of paramount importance as limited attention is given to these infections in the clinical management of HIV-infected individuals in South Africa, despite their increased

risk of developing HHV-related ocular disease. Our results warrant increased awareness among healthcare providers in these settings for early clinical signs of HHV-related (ocular) disease to initiate prompt antiviral treatment to prevent (ocular) morbidity. Also, increased awareness among and education of HIV-infected individuals on early signs and symptoms of HHV infections is of great importance to ensure early presentation to healthcare facilities for diagnosis and management as many individuals in resource-limited settings present to healthcare facilities with an extended patient delay [35-37]. For example, a substantial delay (median of 5 days) in healthcare seeking for signs and symptoms suspected for HZO due to VZV was observed among individuals in South Africa as few sought care within the optimal time frame ( $\leq 72$  h after onset of rash) for antiviral treatment [38]. Similarly, a significant delay for genital ulcer disease was observed among men in South Africa as few sought care within 24 hours, the optimal time frame for acyclovir initiation [35]. The high HHV seroprevalence observed in our study also warrants the need for enhanced HHV-related disease control as they clinically interact with HIV and particular HHVs may even facilitate HIV-transmission [39-41]. For example, HSV-2 infection increases both susceptibility to HIV and transmissibility of HIV infection [41]. As such, the high seroprevalence of HSV-2 in our population most likely contributes to the transmission of HIV which poses a serious challenge and warrants implementation of intervention strategies to reduce HSV-2 related HIV transmission. One strategy could be "treatment as prevention" for HIV/HSV-2 co-infected individuals in which ART is initiated regardless to the CD4 cell count to reduce HIV transmission to their sexual partners [42].

We identified several factors associated with HHV serostatus such as low socioeconomic status (for HSV-1), Shangaan ethnicity (for HSV-2) and low educational status (for VZV) (**Chapter 2**) [34]. However, these results should be interpreted with caution. Overall HHV seroprevalence was very high resulting in a relative small group of seronegative individuals. No association was observed between the individual's seropositive HHV status and a history of corresponding HHV-specific clinical symptoms. Finally, we observed a negative association between EBV and CMV IgG titres with CD4 cell count. A possible reason for this negative association is that decreasing CD4 cell count due to HIV replication is associated with activation of CMV- and EBV-specific CD4 cells as part of chronic immune activation, which may subsequently stimulate humoral responses and produce higher IgG titres. This is an important finding and emphasises the importance of early ART initiation to prevent advanced HIV-related immunodeficiency and subsequently limit HHV related disease.

## INFECTIOUS KERATITIS

The aetiology of infectious keratitis is diverse and includes infections with viruses, bacteria and fungi [43-44]. Although HIV-infected individuals have an increased risk of viral keratitis, especially VZV related keratitis, clinical practice in South Africa predominantly emphasizes on a bacterial aetiology of keratitis [45]. As a result, pre-emptive antibiotic treatment are commonly provided to patients presenting with clinical signs of infectious keratitis. Because the latter dogma is largely based on clinical data, we performed a study aimed to compare the clinical and corneal microbial profile of infectious keratitis patients (n=46) in a high HIV prevalence setting to set priority in the development of clinical guidelines for infectious keratitis in rural South Africa (**Chapter 3**). This cross-sectional study showed that aHHVs, especially VZV and in part complicated by bacterial infections, play a major role in infectious keratitis and lead to pronounced visual morbidity [46]. The important role for viral aetiology of infectious keratitis has not been observed in previous studies from sub-Saharan African countries and might be related to the high HIV prevalence in our setting as we observed a statistical trend between HIV infection and viral keratitis (**Chapter 3**) [46-48]. Unfortunately, previous studies on infectious keratitis from sub-Saharan Africa do not report on the patient's HIV status [47-48]. We included patients at the outpatient department of hospitals and not at primary healthcare (PHC) facilities. This might have resulted in some degree of bias towards viral keratitis as potential bacterial cases are more likely treated successfully at PHC level as pre-emptive treatment of infectious keratitis in South Africa consists of topical antibiotics (e.g. chloramphenicol) only. We identified VZV as the most prevalent viral cause of infectious keratitis in our study population, which is in contrast to previous studies from other sub-Saharan African countries and high-resource Western countries where HSV-1 was identified as the most prevalent keratogenic pathogen [28, 47-48]. One reason for the important role of VZV in our study might be the high HIV prevalence. The increased risk of VZV keratitis for HIV-infected individuals is well studied, but data on the association between HIV infection and HSV-1 keratitis are limited [45, 49-52]. Although available data shows that the recurrence rate of HSV-1 keratitis is increased among HIV-infected individuals compared to uninfected individuals, the incidence of HSV-1 keratitis seems to be similar [52]. Another reason for the important role of VZV in our study might be due to some degree of selection bias. VZV keratitis is usually associated with cutaneous HZO, which makes it relatively easy to identify for non-ophthalmic trained healthcare providers that work at PHC facilities. As such, referral of these patients to the ophthalmology outpatient department of hospitals is likely. In contrast, HSV-1 keratitis is more difficult to diagnose for non-ophthalmic trained healthcare providers due to a lack of concomitant clinical characteristics. These cases might not be recognized as keratitis and subsequently not referred to hospitals as frequent as VZV keratitis cases. We noticed

that there is even among ophthalmic nurses working at the ophthalmology outpatient department of hospitals an extensive lack of knowledge about viral HSV-1 keratitis [Schaftenaar E; unpublished data]. For example, when we retrospectively reviewed patient files of patients diagnosed with keratitis, topical antivirals were prescribed exclusively to patients presenting with cutaneous HZO [Schaftenaar E; unpublished data].

In our study, we demonstrated that polymerase chain reaction (PCR) analysis of corneal swabs is a valuable diagnostic platform to detect viral DNA and supports clinical observations of herpetic keratitis in cases with epithelial inflammation (**Chapter 3**) [46]. We consider PCR analysis of corneal swabs of significant diagnostic value and propose that this methodology should be introduced in the routine management of patients in rural South Africa presenting with epithelial keratitis of potential viral aetiology. However, in cases with subepithelial inflammation, PCR results of corneal swabs were often negative, even though the clinical presentation and response to antiviral treatment was suggestive for herpetic keratitis (**Chapter 3**) [46]. Consequently, determination of the pathogen involved using PCR analysis of corneal swabs in keratitis patients remains challenging. As ophthalmological expertise in these settings is very limited, correct diagnosis solely based on clinical characteristics is highly unlikely. Corneal scraping might be an alternative to corneal swabbing in cases with subepithelial inflammation and will improve aetiological diagnosis [53]. However, corneal scraping bears higher risks (e.g. bacterial superinfection) as the procedure is more invasive than corneal swabbing. Future studies to elucidate the diagnostic value and potential complications of corneal scraping in high HIV prevalent settings with limited ophthalmological expertise is warranted. In our study, bacteria were detected in almost half of the viral keratitis cases, but unlike other studies bacterial superinfection of the cornea was not associated with poorer visual outcome (**Chapter 3**) [46, 54]. However, we do advocate to perform microbial examination of corneal swabs because bacterial superinfections are common and might lead to poorer outcomes if left untreated. Fortunately, microbial analysis, including Gram-stain microscopy and culture, of corneal swabs for bacteria and fungi is available in most hospitals in South Africa. However, to be cost-effective in resource-limited settings, we consider that laboratory analyses of corneal swabs (PCR analysis and microbial examination) should be performed at District level hospitals only. A fungus was detected in only one keratitis case, which is in contrast to a study from Tanzania that reports fungi as a common causative pathogen among culture positive cases of microbial keratitis [55]. The low number of fungal keratitis cases observed in our study may be due to the exclusion of traumatic keratitis as most fungal keratitis cases are trauma related [56]. Furthermore, this may also be correlated to geographical differences as fungal keratitis is more likely to occur toward tropical latitudes [44, 56]. Anterior uveitis was an important complication of infectious keratitis and was significantly more common among HIV-infected than HIV-uninfected individuals (**Chapter 3**) [46]. Thus,

concomitant anterior uveitis in patients presenting with infectious keratitis may point at undiagnosed HIV infection, which warrants subsequent HIV counselling and testing.

Early diagnosis of infectious keratitis and consequently initiation of targeted antimicrobial treatment is of paramount importance to prevent ocular morbidity because poorer visual outcome was associated with increased time between onset of symptoms and first presentation at the ophthalmology department of hospitals (**Chapter 3**) [46]. This remains challenging, especially in resource- and skills-constrained settings (**Chapter 3**) [44, 46, 56]. Current management of infectious keratitis in rural South Africa emphasizes (presumptive) antibacterial treatment rather than identifying the triggering pathogen [57]. In addition, topical antivirals (e.g. acyclovir) are unavailable at PHC facilities and were hardly used in the ophthalmology outpatient department of hospitals before the study [Schaftenaar E; unpublished data]. Our results suggest that current management leads to significant under-treatment and possible preventable blindness as viral aetiology is very common (**Chapter 3**) [46]. Therefore, we advocate that presumptive treatment of patients presenting with infectious keratitis to PHC facilities should include both topical antibiotic and antiviral treatment to prevent ocular morbidity. To improve diagnosis, microbial examination and PCR analysis, in cases with epithelial inflammation, of corneal swabs should be performed in patients presenting with infectious keratitis. In addition, training of PHC nurses on basic ophthalmology skills including eye examination is warranted to ensure early identification of keratitis, initiation of appropriate treatment and reinforce prompt referral to ophthalmology outpatient departments of hospitals to prevent further delay.

## **HERPES ZOSTER OPHTHALMICUS**

HZO is the clinical manifestation of reactivation of latent VZV infection in the ophthalmic branch of the trigeminal ganglion [58]. Ocular involvement occurs in more than half of patients with untreated cutaneous HZO, leading to ocular morbidity [49-50, 59-60]. Relative mild acute ocular complications of HZO may progress to chronic disease, which are associated with severe visual impairment if left untreated [49-50]. HIV-infected individuals are at increased risk of developing HZO, but limited data are available on the ocular manifestations of HZO in high HIV prevalence settings in sub-Saharan Africa [45, 51, 61].

In our study on HZO, ocular complications were classified as “early” or “late” based on stage of disease progression and (potential) restoration of normal vision, which resulted in a unique clinical classification system of ocular complications of HZO (**Chapter 4**) [62]. Our study revealed that the spectrum of ocular complications of HZO among patients presenting to the ophthalmology outpatient department in a high HIV prevalence setting is diverse and that late-stage ocular complications are common and associated

with blindness (**Chapter 4**) [62]. Increased time interval between onset of symptoms and first presentation to the facility was associated with late-stage ocular complications (**Chapter 4**) [62]. This is most likely due to delayed initiation of antiviral treatment as early initiation thereof ( $\leq 72$  hours after onset of rash) reduces the risk of progression of early- to late-stage ocular complications [50, 63]. Specific reasons for this delay remain unclear and requires further investigation. Most likely, both patient- and healthcare system-associated factors like referral delay have played a role. Our results emphasize the importance of early recognition of cutaneous HZO and ocular involvement, prompt initiation of appropriate antiviral treatment even at PHC level with swift referral to hospitals with ophthalmology departments to reduce sight-threatening ocular complications. Appropriate antiviral treatment should be available at PHC level, even in rural and resource-limited settings (**Chapter 4**) [62]. To achieve early recognition of cutaneous HZO and ocular involvement, training of healthcare providers at both PHC facilities and hospitals is of paramount importance and should include basic ophthalmological training and training around prescription and instalment of topical and oral antiviral treatment. Moreover, these efforts should result in the development of clinical guidelines and standardized training programs to prevent ocular morbidity among patients with HZO. Also to reduce delay in patients seeking medical care, community campaigns should be initiated to increase awareness among HIV-infected individuals and prevent visual impairment.

In our study, HIV infection was common among patients presenting with HZO and intraocular complications were more common among HIV-infected than HIV naïve individuals which is in line with previous studies [45, 49-51]. Even though several studies have advocated that HZO can be a HIV presenting clinical disease, 4/39 (10%) of HIV-infected individuals presenting with HZO were tested reactive for HIV for the first time at the ophthalmology outpatient department [45, 49, 64-65]. We therefore advocate that HIV testing and counselling should be standard practice in patients presenting with HZO in high HIV prevalence settings and encourage discussion among healthcare providers about the introduction of HIV testing and counselling in all patients presenting with HZO (**Chapter 4**) [62].

## UVEITIS

Uveitis is a sight-threatening eye condition that is a common cause of visual impairment in low-resource settings [66]. The aetiology of uveitis is diverse and includes infectious and non-infectious disorders [66-67]. Data from sub-Saharan African countries are limited, but suggest that infectious diseases play an important role in uveitis [66]. The high HIV prevalence in these countries most likely contributes to the role of infectious



diseases in uveitis as HIV-infected individuals are at increased risk of developing infectious uveitis [66, 68-69].

In this thesis we conducted a cross-sectional study among patients presenting with uveitis (n=103) and found that infectious uveitis is common in our population, especially among HIV-infected individuals. The most prevalent uveitogenic pathogens identified were HHVs (51%), *Mycobacterium tuberculosis* (24%) and *Treponema pallidum* (7%) (**Chapter 5**) [70]. The data implicate that infectious uveitis is considerably more common in the setting studied, than reported in other regions of the world [66]. For example, infectious uveitis only accounts for about 10-20% of uveitis cases in high-resource countries like the USA, Portugal, United Kingdom and the Netherlands [66]. Herpetic uveitis, mainly VZV, was the major cause of infectious uveitis in our South African patient cohort and is most likely due to the high HIV prevalence and high HHV seroprevalence in our setting [34, 71]. The predominant role for VZV is in line with a study from Congo that reported VZV infection as the most common associated condition among HIV-infected uveitis patients, but in contrast to studies from high-resource settings like the USA that report a predominant role for CMV, especially in the pre-ART era [71-74]. Despite of a CMV seroprevalence of 100% among HIV-infected ART-naïve individuals in our setting, we observed only a single case of CMV uveitis [34]. A possible reason for the observed low prevalence of CMV uveitis and high prevalence of VZV uveitis in our study is the relative high CD4 cell count among HIV-infected individuals at inclusion (**Chapter 5**) [70]. CMV uveitis typically occurs in patients with CD4 cells  $\leq 50$  cells/mm<sup>3</sup>, whereas herpes zoster ophthalmicus and associated VZV uveitis already occurs in patients with CD4 cells  $\leq 500$  cells/mm<sup>3</sup> [13, 72, 75]. In our study, only 3 (5%) HIV-infected uveitis patients presented with CD4 cells  $\leq 50$  cell/mm<sup>3</sup>, making them at risk of CMV uveitis (**Chapter 5**) [70]. In contrast, 54 (82%) HIV-infected uveitis patients presented with CD4 cell counts between 50 and 500 cells/mm<sup>3</sup>. However, other factors like virus or host origin factors might contribute to the geographic differences in CMV uveitis prevalence as a study from Tanzania reported low prevalence of CMV uveitis (1.3%) even among HIV-infected uveitis patients with CD4 cells  $\leq 100$  cells/mm<sup>3</sup> [76].

In addition to HHVs, *M. tuberculosis* was a common cause of uveitis in our study confirming previous reports from other low-resource settings like India that showed an increasing uveitogenic role of *M. tuberculosis* (**Chapter 5**) [70, 77-78]. However, available data on ocular tuberculosis (TB) is predominantly from non-sub-Saharan African countries where the TB epidemic differs substantially from the TB epidemic of South Africa [79]. In South Africa, the TB epidemic is fuelled by the high HIV prevalence and HIV-infected individuals are at increased risk of developing ocular TB [79-81]. Our results are of great importance and warrant recognition of *M. tuberculosis* infection as cause of uveitis in South Africa. Currently, there is a paucity of data and limited awareness among policy makers and healthcare providers, even among those working at the

TB wards, of ocular involvement of TB in South Africa. The South African national TB guideline for example does not include any information on diagnosis and management of ocular TB [82]. With the significant role of TB observed in our study, renewal of clinical guidelines and education of healthcare providers on ocular involvement of TB are of great importance (**Chapter 5**) [70]. This thesis also presents an interesting case history of TB chorioretinitis in a HIV-infected man early after ART treatment, which was most likely associated with the immune reconstitution inflammatory syndrome (**Chapter 6**) [83]. This case highlights the importance of screening for (ocular) TB and basic ophthalmological examination (e.g. visual acuity testing) after ART initiation as part of the routine follow-up visits after ART initiation of HIV-infected individuals. It also highlights that ocular immune reconstitution inflammatory syndrome can be of other origin than CMV retinitis, which is predominantly advocated in available literature [31-32, 84].

Whereas *T. pallidum* is a known uveitogenic pathogen, its contribution as cause of infectious uveitis in sub-Saharan Africa is largely unknown and diagnosis remains a major clinical challenge [85]. Here, we report on a relative high number of syphilitic uveitis cases, which is in line with recent observations from non-African countries suggest an increasing incidence of ocular syphilis (**Chapter 5**) [70, 86-88]. In our study, all clinical findings observed during slit-lamp and funduscopic examination were reviewed by a team of uveitis specialists using the photographs of anterior and posterior segment of the eye and diagnosis of ocular syphilis was based on clinical characteristics consistent with ocular syphilis in individuals with laboratory confirmed syphilis [88-90]. Although few studies have reported possible contribution of PCR testing or Goldmann-Witmer coefficient determination on intraocular fluid in the diagnosis of ocular syphilis, the usefulness of these assays remains to be determined [91-92]. Recognition of the high number of syphilitic uveitis cases is important as diagnosis is difficult because clinical characteristics of syphilitic uveitis are diverse and mimics other uveitis entities [85].

Early diagnosis and prompt initiation of targeted antimicrobial treatment is of paramount importance for good visual outcome of infectious uveitis [93-95]. Accurate diagnosis of uveitis cases, especially in resource-limited settings and in HIV-infected individuals, is challenging for multiple reasons [68, 96]. First, uveitis is generally clinically underdiagnosed due to lack of ophthalmological expertise [68]. Significant visual impairment was reported due to unrecognised uveitis among Ugandan HIV-infected individuals. Visual impairment in these cases could possibly have been prevented if recognised at early onset of disease [96]. Second, if uveitis is diagnosed clinically, the presumption of aetiology may be incorrect as this is based on the patient's history, clinical and ophthalmological characteristics. Clinical characteristics in uveitis have poor predictive value for its aetiology. They do not distinguish well between infectious and non-infectious origin and, in case of infectious uveitis, are poorly predictive for the causative pathogen because different pathogens may present with similar clinical characteristics

[93-94]. For example, the initial clinical diagnosis was adjusted and treatment altered based on diagnostic testing in almost a quarter of patients presenting with uveitis in studies from the Netherlands and South Africa [93-94]. One exception might be uveitis caused by *M. tuberculosis*: the patient's history (e.g. recent history of pulmonary TB) or specific retinal findings (e.g. granuloma) are strongly indicative for ocular TB. However tuberculosis cannot always be ruled-out solely on clinical symptoms [97]. For example, in our uveitis study, we were able to confirm TB by routine diagnostics in about half of our TB uveitis patients (**Chapter 5**) [70]. In the other half, ocular characteristics suggestive of ocular TB like chronic granulomatous uveitis with mutton-fat keratic precipitates or a chorioretinal granuloma were the only evidence of TB. Isolation of *M. tuberculosis* from the ocular tissues is the cornerstone for diagnosis, but rarely achievable as ocular specimens are usually too small and culture takes long [98]. Detection of mycobacterial DNA through PCR strongly supports diagnosis of ocular TB, but is currently not widely used and its additional diagnostic value remains largely unclear [98-99]. Third, empirical treatment of infectious uveitis is difficult because of the wide range of potential uveitogenic pathogens that require targeted treatment. Finally, HIV infection and its associated immunosuppression affect the differential diagnosis as HIV-infected individuals have an increased risk for specific HIV-associated ocular opportunistic infections [68]. In addition, disease manifestation of infectious uveitis in HIV-infected individuals is usually atypical (e.g. lower degree of inflammation; even in advanced uveitis) compared to persons without HIV infection. This challenges the clinical identification of the triggering pathogen in this patient group [68].

Presumed clinical diagnosis of infectious uveitis is increasingly supported in Western countries by analysis of ocular fluid, especially aqueous humour (AH) [100]. Ocular fluid is obtained through diagnostic anterior chamber paracentesis and AH aspiration. This is a well-documented procedure that is routinely performed in other aspects of ophthalmologic care, e.g. for management of acute elevation of intraocular pressure and for diagnosis of suspected intraocular infections, metastasis and lymphoma [94-95]. The two key diagnostic tests include pathogen-specific serology of paired ocular fluid and serum samples and PCR on the ocular fluid sample. In serology, intra-ocular pathogen-specific IgG is measured and compared to serum IgG levels (Goldmann-Witmer coefficient) to differentiate between intra-ocular production of antibody and passive leakage from the blood as proxy for infection, whereas PCR identifies pathogen-specific nucleic acids [101]. In infectious uveitis, pathogen-specific nucleic acids and IgG production are commonly detectable at different times after onset of disease. During the early phase, nucleic acids are detectable (within days after onset disease) followed by detection of intra-ocular IgG levels. Whereas pathogen nucleic acids commonly become undetectable two weeks after onset of disease, specific antibodies remain detectable for multiple weeks in AH [101]. Thus, both assays are complimentary and contribute considerably

to the differential diagnosis of infectious uveitis [93-95, 101-102]. Identification of the triggering pathogen was established by serology and PCR in 60% of HIV-infected individuals presenting with undefined posterior uveitis in a study from Italy, whereas PCR provided a final diagnosis in 39% of cases where the initial diagnosis of causative pathogen was uncertain in a study from South Africa [93, 102]. Furthermore, treatment was altered on basis of PCR results in 20% of patients with posterior uveitis of suspected infectious origin in a study from USA [95]. In our study, AH samples were only obtained from participants with severe visual impairment as this procedure is not part of standard clinical practice in South Africa (**Chapter 5**) [70]. In case of herpetic uveitis patients, AH was obtained from 20 (53%) patients and specific diagnosis based on analysis of aqueous humour was established in the majority (65%) of patients (**Chapter 5**) [70]. Clinical or laboratory evidence of HSV-1, HSV-2 or EBV as cause of uveitis was not observed (**Chapter 5**) [70].

Anterior chamber paracentesis is a safe procedure that can be performed in a consultation room at the slit-lamp [103-104]. Three studies reported on safety of this procedure to diagnose uveitis [103-105]. There were only a few, non-serious, complications reported: traumatic hyphaemia (5 cases per 1,000 procedures) and injection of air into the anterior chamber (4 cases per 1,000 procedures) as the most important. Hyphaemia refers to bleeding in the anterior chamber that may cause blurred vision, but this will usually resolve spontaneously or is easily treatable with topical drops (e.g. topical steroids). Similarly, injection of air into the anterior chamber may cause blurred vision but is usually self-limiting [103-105].

Uveitis is a serious condition resulting in severe visual impairment and even blindness if not treated promptly and adequately. In South Africa, referral from lower levels of healthcare to a regional ophthalmology unit for further management and initiation of (empirical) treatment is indicated. However, even at these units, treatment outcomes may be poor due to the low predictive value of the patient's history and clinical characteristics for aetiology of uveitis. Anterior chamber paracentesis, aspiration and analysis of AH will provide a valuable diagnostic procedure that optimizes treatment and subsequent prognosis at a very limited risk. This procedure can be performed in most clinical settings, because a well-trained ophthalmic nurse could safely perform anterior chamber paracentesis in situations when qualified ophthalmologists are not available. Paracentesis is easier to perform than cataract surgery for which ophthalmic nurses are trained in some African countries (e.g. Malawi) in the absence of ophthalmologists [106]. In addition to skills development, strengthening laboratory infrastructure is warranted. Validation of existing diagnostic assays and provision of other resources required to analyse aqueous humour for the most common uveitogenic pathogens should be considered across South Africa. Furthermore, logistic systems, e.g. cold sample transport chain, would require optimisation to ensure short turnaround time and maximum clini-

cal impact of this diagnostic test. Providing such diagnostic service will be cost-effective due to reduction of unnecessary use of expensive antimicrobial drugs and aversion of blindness and associated socioeconomic costs [107].

Collectively, increased awareness about the unmet need for valuable diagnostic platforms for uveitis is needed. Moreover, discussion among healthcare providers about the introduction thereof in routine work-up of uveitis patients in South Africa is highly warranted. Ultimately, these efforts should result in the development of clinical guidelines and a training program that includes combined clinical and laboratory evaluation for infectious aetiology, including AH sampling to detect the triggering pathogen, chest X-ray and sputum evaluation for *M. tuberculosis* and serological evaluation for syphilis.

## **OCULAR CONDITIONS ASSOCIATED WITH HIV INFECTION AND ART**

Currently there is no cure for HIV, but the mass introduction of ART has resulted in prolonged survival even to a normal life expectancy in high-resource countries [108-109]. In Western countries, the introduction of ART resulted in a substantial reduction in infectious ocular conditions associated with severe immunodeficiency, but data from the African continent are largely unavailable [18-19, 21]. In South Africa, especially in rural settings, ART coverage is still low and individuals still present to healthcare facilities for the first time with moderate to severe immunodeficiency. New strategies to achieve HIV epidemic control, such as the Joint United Nations Programme on HIV/AIDS (UNAIDS) 90-90-90 campaign, aim to diagnose 90% of all HIV-infected individuals, provide ART for 90% of those diagnosed with HIV infection and achieve undetectable HIV viral loads for 90% of those on treatment by the year 2020 [110]. These efforts will most likely result in decreasing numbers of HIV-infected individuals with severe immunodeficiency and possibly in a decrease in the incidence of infectious ocular conditions as observed in Western countries [18-19]. However, available data from Western countries also suggest that metabolic and vascular changes associated with extended use of ART may affect the eye, manifesting for example as retinopathy [18]. Also, accelerated ageing and frailty among HIV-infected individuals on ART may also affect ocular structures such as the lens [21]. Finally, persistent immune activation in individuals on ART could predispose to ocular conditions like age-related macular degeneration [111]. ART is lifelong, but long-term effects of ART and chronic HIV infection on the prevalence of ocular disease are largely unknown, especially from sub-Saharan African settings with high HIV prevalence. Such impact, may greatly affect HIV-infected individuals' quality of life [3]. As the number of HIV-infected individuals on ART will increase, it is crucial to obtain insight in the distribution of ocular disease and manifestations among HIV-infected individuals with and without ART in rural South Africa to identify preventive measures.

In this thesis, we described a retrospective cohort study where we recruited four groups of adult individuals: (1) individuals without HIV infection (n=105), (2) HIV-infected individuals naïve for ART (n=16), (3) HIV-infected individuals on ART for <12 months (defined as short-term ART) (n=56) and (4) HIV-infected individuals on ART for >36 months (defined as long-term ART) (n=165) (**Chapter 7**). We showed that ocular disease is more common among HIV-infected individuals, especially those on long-term ART, and causes substantial morbidity in our setting.

Eye complaints were significantly more often reported by HIV-infected participants than those without HIV infection (**Chapter 7**). Moreover, the external eye and anterior segment were more often affected among HIV-infected than uninfected individuals, with blepharitis, pterygium, keratoconjunctivitis sicca and cataract formation were the main conditions in our HIV-infected population. Limited data on the mechanisms that lead to non-infectious ocular conditions among HIV-infected individuals are available, but several mechanisms may be involved. First, HIV-induced immunosuppression may lead to a reduced ability to control normal flora and to changes in cutaneous glands of the eyelids resulting in blepharitis [112-113]. Second, HIV-mediated immune activation and lymphocytic infiltration may cause destruction of lacrimal glands and damage the conjunctiva, which might play a role in the development of keratoconjunctivitis sicca and pterygium formation [113-114]. Finally, accelerated senescence due to HIV infection may result in accelerated formation of cataract [21]. The posterior segment, especially HIV-retinopathy, was more often affected among HIV-infected individuals on ART for long-term than those on short-term ART (**Chapter 7**). Moreover, HIV-retinopathy was associated with ART use for longer period of time. These observations are surprising as available data from Western countries observed a decrease in frequency of HIV-retinopathy among HIV-infected individuals on ART compared to those who were ART-naïve, suggesting that ART decreases the risk of HIV-retinopathy [18]. In our study, a trend for low nadir CD4 cell count of <50 cells/mm<sup>3</sup> and the occurrence of HIV retinopathy was observed, which could in part explain the high frequency of HIV-retinopathy observed in our study as nadir CD4 cell count was generally low, especially among participants on long-term ART. In line with our observations, lower nadir CD4 cell count and more prolonged ART use have been associated as risk factors for non-infectious HIV related conditions such as cardiovascular disease or diabetes mellitus in other studies [115-116]. This suggests that the nadir CD4 cell count is likely to be an important risk factor of non-infectious ocular conditions and stresses the importance of the UNAIDS 90-90-90 campaign [110]. In line with HIV-retinopathy, clinical detectable cataract was also associated with long-term ART use in our study (**Chapter 7**). This finding is in line with a Danish nationwide population-based cohort study that reported introduction of ART as a risk factor for cataract and cataract surgery [117]. The increased risk for cataract surgery observed in this Danish study is of great importance as it suggests that participants

on ART in our population are at high risk of developing cataract that requires surgical management over time [117]. This would have major consequences for the South African healthcare system, as the cataract surgical rate in South Africa is already low and the number of individuals on ART will only increase [118].

In conclusion, HIV-infected individuals, even after ART initiation and especially those on long-term ART, are at risk of developing ocular disease compared to HIV-uninfected individuals. As such, these individuals are at risk of suffering from ocular morbidity, including visual disability. Increased awareness among healthcare providers working in the HIV/ART programmes for symptoms and early clinical signs of ocular disease in order to initiate prompt treatment or referral to the relevant level of care is therefore of paramount importance. Furthermore, implementation of a regular ophthalmologic screening programme for HIV-infected individuals is warranted to prevent ocular morbidity and possible future visual impairment.

## **FUTURE PERSPECTIVES**

In this thesis, we described that HIV-infected individuals are at risk of developing two important infectious ocular conditions namely keratitis and uveitis and that even after ART initiations, non-infectious ocular conditions remain common. In our high HIV prevalence setting, viral keratitis and uveitis were mainly caused by HHVs. Additionally, mixed infection in viral keratitis due to an infection with a bacterial pathogen, is prominent for infectious keratitis. Viral aetiology of these ocular conditions is more common among HIV-infected individuals who are at increased risk for developing ocular infections with poorer visual outcome compared to HIV-uninfected individuals. In our setting, VZV is the predominant aetiological pathogen in both keratitis and uveitis, which is in contrast to available studies from high-resource settings [28, 66]. Additionally, ocular TB and to a lesser extent ocular syphilis play an important role in uveitis patients in our setting. As such, infectious ocular disease are a major healthcare challenge in our setting. Available data on ocular disease, which predominantly come from high-resource settings from Western countries, cannot be extrapolated to a rural, low-resource and high HIV prevalence setting in South Africa. Development of “tailor-made” clinical guidelines for eye care in sub-Saharan Africa, including South Africa, is therefore of paramount importance to improve clinical management and prevent visual impairment. Current management of ocular infectious conditions, especially infectious keratitis and uveitis, commonly leads to misdiagnosis, under-treatment and preventable visual impairment. Therefore, these “tailor-made” clinical guidelines for eye care should include laboratory analysis of corneal swabs in case of infectious keratitis and aqueous humour in case of uveitis to support presumed diagnosis. This thesis seeks to draw attention to the unmet need for

these valuable diagnostic analyses and to encourage discussion among healthcare providers about the introduction thereof in routine work-up of patients with these ocular conditions in rural South Africa.

Apart from infectious keratitis and uveitis, non-infectious ocular conditions remain common among HIV-infected individuals after ART initiation which warrants the need for regular routine ophthalmological screening for ocular disease among HIV-infected individuals. However, currently eye care is not incorporated in existing clinical guidelines for HIV-infected individuals in the (pre)ART program of South Africa. As such, eye care should become part of standard clinical care for HIV-infected individuals in the (pre)ART program and development of regular routine ophthalmological screening guidelines is highly needed. Also, increased awareness among healthcare providers in the field of HIV in rural South Africa is highly warranted for early recognition, diagnosis and initiation of treatment or prompt referral to the adequate level of care.

Theoretically, today's eye care in South Africa should be provided at all healthcare levels with primary eye care, rendered by professional, non-ophthalmic or ophthalmic and rural healthcare providers, as its cornerstone [119]. However, during the course of our studies we observed a significant delay in presentation to hospitals suggesting that eye care receives limited attention in PHC facilities in rural settings. Although ophthalmic nurses are trained in these settings, their deployment to provide eye care and ophthalmological screening after completion of their training is limited and in practice they predominantly work as general nurses covering all clinical fields. Moreover, ophthalmologists are unavailable since they are concentrated in urban areas only, leaving rural communities devoid of the highest quality of eye care professionals [120]. As a result, individuals in rural settings are at increased risk of suffering from ocular morbidity. Eye care therefore needs to be prioritized at local and national health level in South Africa. Effective eye care depends on many factors including the availability of budget, essential resources and drugs, human resources and referral and mobility options as most important. Lack of ophthalmological expertise and skills, essential resources, ophthalmic drugs and referral systems are major challenges in rural settings. This stresses the need for further studies to obtain insight in determinants, barriers and challenges of ophthalmology services in South Africa in order to provide urgent in-depth health system strengthening that will improve eye care and reduce preventable visual impairment.



**REFERENCES**

1. Rosenberg EA and Sperazza LC. The visually impaired patient. *Am Fam Physician* 2008; **77**: 1431-6.
2. Evans TG. Socioeconomic consequences of blinding onchocerciasis in west Africa. *Bull World Health Organ* 1995; **73**: 495-506.
3. Langelaan M, de Boer MR, van Nispen RM, et al. Impact of visual impairment on quality of life: a comparison with quality of life in the general population and with other chronic conditions. *Ophthalmic Epidemiol* 2007; **14**: 119-26.
4. Taylor HR, Katala S, Muñoz B, et al. Increase in mortality associated with blindness in rural Africa. *Bull World Health Organ* 1991; **69**: 335-8.
5. Pascolini D and Mariotti SP. Global estimates of visual impairment: 2010. *Br J Ophthalmol* 2012; **96**: 614-8.
6. Dandona R and Dandona L. Socioeconomic status and blindness. *Br J Ophthalmol* 2001; **85**: 1484-8.
7. Freeman EE, Roy-Gagnon MH, Samson E, et al. The global burden of visual difficulty in low, middle, and high income countries. *PLoS One* 2013; **8**: e63315.
8. Cook C. Glaucoma in Africa: size of the problem and possible solutions. *J Glaucoma* 2009; **18**: 124-8.
9. Congdon NG, Friedman DS and Lietman T. Important causes of visual impairment in the world today. *JAMA* 2003; **290**: 2057-60.
10. Poole TR. Causes of blindness in Northern Tanzania: a hospital and rural health centre based study. *Int Ophthalmol* 2001; **24**: 195-8.
11. Ronday MJ, Stilma JS, Barbe RF, et al. Blindness from uveitis in a hospital population in Sierra Leone. *Br J Ophthalmol* 1994; **78**: 690-3.
12. Human Sciences Research Council. South African National HIV Prevalence, Incidence and Behaviour Survey. Human Sciences Research Council, Cape Town, South Africa; 2012.
13. Shukla D, Rathinam SR and Cunningham ET Jr. Contribution of HIV/AIDS to global blindness. *Int Ophthalmol Clin* 2007; **47**: 27-43.
14. Joint United Nations Programme on HIV/AIDS (UNAIDS). AIDSinfo. Available at: <http://aidsinfo.unaids.org/>.
15. Cunningham ET Jr and Margolis TP. Ocular manifestations of HIV infection. *N Engl J Med* 1998; **339**: 236-44.
16. Holland GN. AIDS and ophthalmology: the first quarter century. *Am J Ophthalmol* 2008; **145**: 397-408.
17. Ray M, Logan R, Sterne JA, et al. The effect of combined antiretroviral therapy on the overall mortality of HIV-infected individuals. *AIDS* 2010; **24**: 123-37.
18. Accorinti M, Pirraglia MP, Corradi R, et al. Changing patterns of ocular manifestations in HIV seropositive patients treated with HAART. *Eur J Ophthalmol* 2006; **16**: 728-32.
19. Salzberger B, Hartmann P, Hanses F, et al. Incidence and prognosis of CMV disease in HIV-infected patients before and after introduction of combination antiretroviral therapy. *Infection* 2005; **33**: 345-9.
20. Mills EJ, Bärnighausen T and Negin J. HIV and aging--preparing for the challenges ahead. *N Engl J Med* 2012; **366**: 1270-3.
21. Pathai S, Lawn SD, Weiss HA, et al. Increased ocular lens density in HIV-infected individuals with low nadir CD4 counts in South Africa: evidence of accelerated aging. *J Acquir Immune Defic Syndr* 2013; **63**: 307-14.
22. Department of Health, Republic of South Africa. The 2013 National antenatal sentinel HIV prevalence survey South Africa. Department of Health, Republic of South Africa, Pretoria, 2015.


23. Newman H and Gooding C. Viral ocular manifestations: a broad overview. *Rev Med Virol* 2013; **23**: 281-94.
24. Miller CS, Berger JR, Mootoor Y, et al. High prevalence of multiple human herpesviruses in saliva from human immunodeficiency virus-infected persons in the era of highly active antiretroviral therapy. *J Clin Microbiol* 2006; **44**: 2409-15.
25. Pellett PE and Roizman B. The Family of Herpesviridae: A brief introduction. In: Knipe DM, Howley PM, Griffin DE, et al., eds. *Fields Virology*. 5th ed. Vol. 2. Philadelphia: Lippincott-Williams and Wilkins, 2007: 2479-99.
26. Chakraborty N, Bhattacharyya S, De C, et al. Incidence of multiple Herpesvirus infection in HIV seropositive patients, a big concern for Eastern Indian scenario. *Virol J* 2010; **7**: 147-53.
27. Jansen K, Haastert B, Michalik C, et al. Incidence and risk factors of herpes zoster among hiv-positive patients in the german competence network for HIV/AIDS (KompNet): a cohort study analysis. *BMC Infect Dis* 2013; **13**: 372-81.
28. Liesegang TJ. Herpes simplex virus epidemiology and ocular importance. *Cornea* 2001; **20**: 1-13.
29. Freeman WR, Lerner CW, Mines JA, et al. A prospective study of the ophthalmologic findings in the acquired immune deficiency syndrome. *Am J Ophthalmol* 1984; **97**: 133-42.
30. Doan S, Cochereau I, Guvenisik N, et al. Cytomegalovirus retinitis in HIV-infected patients with and without highly active antiretroviral therapy. *Am J Ophthalmol* 1999; **128**: 250-1.
31. Otiti-Sengeri J, Meenken C, van den Horn GJ, et al. Ocular immune reconstitution inflammatory syndromes. *Curr Opin HIV AIDS* 2008; **3**: 432-7.
32. Robinson MR, Reed G, Csaky KG, et al. Immune-recovery uveitis in patients with cytomegalovirus retinitis taking highly active antiretroviral therapy. *Am J Ophthalmol* 2000; **130**: 49-56.
33. Joint United Nations Programme on HIV/AIDS (UNAIDS). Fact sheet 2015. Geneva: UNAIDS; 2015.
34. Schaftenaar E, Verjans GM, Getu S, et al. High seroprevalence of human herpesviruses in HIV-infected individuals attending primary healthcare facilities in rural South Africa. *PLoS One* 2014; **9**: e99243.
35. Leichliter JS, Lewis DA, Sternberg M, et al. Health care seeking among men with genital ulcer disease in South Africa: correlates and relationship to human immunodeficiency virus-1 and herpes simplex virus type 2 detection and shedding. *Sex Transm Dis* 2011; **38**: 865-70.
36. Otwombe KN, Variava E, Holmes CB, et al. Predictors of delay in the diagnosis and treatment of suspected tuberculosis in HIV co-infected patients in South Africa. *Int J Tuberc Lung Dis* 2013; **17**: 1199-205.
37. Kong VY, Van der Linde S, Aldous C, et al. Quantifying the disparity in outcome between urban and rural patients with acute appendicitis in South Africa. *S Afr Med J* 2013; **103**: 742-5.
38. Richards JC, Maartens G and Davidse AJ. Course and complications of varicella zoster ophthalmicus in a high HIV seroprevalence population (Cape Town, South Africa). *Eye (Lond)* 2009; **23**: 376-81.
39. Patel P, Bush T, Mayer KH, et al. Prevalence and risk factors associated with herpes simplex virus-2 infection in a contemporary cohort of HIV-infected persons in the United States. *Sex Transm Dis* 2012; **39**: 154-60.
40. Munawwar A and Singh S. Human Herpesviruses as Copathogens of HIV Infection, Their Role in HIV Transmission, and Disease Progression. *J Lab Physicians* 2016; **8**: 5-18.
41. Des Jarlais DC, Arasteh K, McKnight C, et al. HSV-2 co-infection as a driver of HIV transmission among heterosexual non-injecting drug users in New York City. *PLoS One* 2014; **9**: e87993.
42. Cohen MS and Gay CL. Treatment to prevent transmission of HIV-1. *Clin Infect Dis* 2010; **50**: S85-95.
43. Upadhyay MP, Srinivasan M and Whitcher JP. Microbial keratitis in the developing world: does prevention work? *Int Ophthalmol Clin* 2007; **47**: 17-25.

44. Keay L, Edwards K, Naduvilath T, et al. Microbial keratitis predisposing factors and morbidity. *Ophthalmology* 2006; **113**: 109-16.
45. Hodge WG, Seiff SR and Margolis TP. Ocular opportunistic infection incidences among patients who are HIV positive compared to patients who are HIV negative. *Ophthalmology* 1998; **105**: 895-900.
46. Schaftenaar E, Peters RPH, Baarsma GS, et al. Clinical and corneal microbial profile of infectious keratitis in a high HIV prevalence setting in rural South Africa. Accepted for publication. *Eur J Clin Microbiol Infect Dis* 2016.
47. Yorston D and Foster A. Herpetic keratitis in Tanzania: association with malaria. *Br J Ophthalmol* 1992; **76**: 582-5.
48. Ashaye A and Aimola A. Keratitis in children as seen in a tertiary hospital in Africa. *J Natl Med Assoc* 2008; **100**: 386-90.
49. Vafai A and Berger M. Zoster in patients infected with HIV: a review. *Am J Med Sci* 2001; **321**: 372-80.
50. Liesegang TJ. Herpes zoster virus infection. *Curr Opin Ophthalmol* 2004; **15**: 531-6.
51. Veenstra J, Krol A, Van Pragg RM, et al. Herpes zoster immunological deterioration and disease progression in HIV-1 infection. *AIDS* 1995; **9**: 1153-8.
52. Hodge WG and Margolis TP. Herpes simplex virus keratitis among patients who are positive or negative for human immunodeficiency virus: an epidemiologic study. *Ophthalmology* 1997; **104**: 120-4.
53. Sharma S. Diagnosis of infectious diseases of the eye. *Eye* 2012; **26**: 177-84.
54. Boisjoly HM, Pavan-Langston D, Kenyon KR, et al. Superinfections in herpes simplex keratitis. *Am J Ophthalmol* 1983; **96**: 354-61.
55. Poole TR, Hunter DL, Maliwa EM, et al. Aetiology of microbial keratitis in northern Tanzania. *Br J Ophthalmol* 2002; **86**: 941-2.
56. Thomas PA and Geraldine P. Infectious keratitis. *Curr Opin Infect Dis* 2007; **20**: 129-41
57. Burton MJ, Pithuwa J, Okello E, et al. Microbial keratitis in East Africa: why are the outcomes so poor? *Ophthalmic Epidemiol* 2011; **18**: 158-63.
58. Kaufman SC. Anterior segment complications of herpes zoster ophthalmicus. *Ophthalmology* 2008; **115**: S24-32.
59. Marsh RJ and Cooper M. Ophthalmic herpes zoster. *Eye (Lond)* 1993; **7**: 350-70.
60. Bayu S and Alemayehu W. Clinical profile of herpes zoster ophthalmicus in Ethiopians. *Clin Infect Dis* 1997; **24**: 1256-60.
61. Buchbinder SP, Katz MH, Hessol NA, et al. Herpes zoster and human immunodeficiency virus infection. *J Infect Dis* 1992; **166**: 1153-6.
62. Schaftenaar E, Meenken C, Baarsma GS et al. Early- and late-stage ocular complications of herpes zoster ophthalmicus in rural South Africa. *Trop Med Int Health* 2016; **21**: 334-9.
63. Nithyanandam S, Joseph M and Stephen J. Ocular complications and loss of vision due to herpes zoster ophthalmicus in patients with HIV infection and a comparison with HIV-negative patients. *Int J STD AIDS* 2013; **24**: 106-9.
64. Ritterband DC and Friedberg DN. Virus infections of the eye. *Rev Med Virol* 1998; **8**: 187-201.
65. Nasoodi A, Lim LT, Al-Ani A, et al. What you can see in your patient's eyes? Review of ocular manifestations of HIV in HAART era. *Int J STD AIDS* 2008; **19**: 4-11.
66. London NJ, Rathinam SR and Cunningham ET Jr. The epidemiology of uveitis in developing countries. *Int Ophthalmol Clin* 2010; **50**: 1-17.
67. Jabs DA, Nussenblatt RB and Rosenbaum JT; Standardization of Uveitis Nomenclature (SUN) Working Group. Standardization of uveitis nomenclature for reporting clinical data. Results of the First International Workshop. *Am J Ophthalmol* 2005; **140**: 509-16.

68. Schaftenaar E, van Gorp EC, Meenken C, et al. Ocular infections in sub-Saharan Africa in the context of high HIV prevalence. *Trop Med Int Health* 2014; **19**: 1003-14.
69. Wells JM and Smith JR. Uveitis in human immunodeficiency virus-infected individuals. *Int Ophthalmol Clin* 2015; **55**: 11-8.
70. Schaftenaar E, Meenken C, Baarsma GS, et al. Uveitis is predominantly of infectious origin in a high HIV and TB prevalence setting in rural South Africa. *Br J Ophthalmol* 2016.
71. Mwanza JC and Kayembe DL. Uveitis in HIV-infected patients. *Eur J Ophthalmol* 2001; **11**: 53-6.
72. Jabs DA. Ocular manifestations of HIV infection. *Trans Am Ophthalmol Soc* 1995; **93**: 623-83.
73. Pertel P, Hirschstick RE, Phair J, et al. Risk of developing cytomegalovirus retinitis in persons infected with the human immunodeficiency virus. *J Acquir Immune Defic Syndr* 1992; **5**: 1069-74.
74. Hoover DR, Peng Y, Saah A, et al. Occurrence of cytomegalovirus retinitis after human immunodeficiency virus immunosuppression. *Arch Ophthalmol* 1996; **114**: 821-7.
75. Moraes HV Jr. Ocular manifestations of HIV/AIDS. *Curr Opin Ophthalmol* 2002; **13**: 397-403.
76. Nirwoth JP, Hall AB and Lewallen S. Prevalence of cytomegalovirus retinitis in Tanzanians with low CD4 levels. *Br J Ophthalmol* 2011; **95**: 460-2.
77. Basu S, Monira S, Modi RR, et al. Degree, duration, and causes of visual impairment in eyes affected with ocular tuberculosis. *J Ophthalmic Inflamm Infect* 2014; **4**: 3.
78. Bodaghi B and LeHoang P. Ocular tuberculosis. *Curr Opin Ophthalmol* 2000; **11**: 443-8.
79. Harper C. Tuberculosis, a neglected opportunity? *Nat Med* 2007; **13**: 309-12.
80. Tabbara KF. Ocular tuberculosis: anterior segment. *Int Ophthalmol Clin* 2005; **45**: 57-69.
81. Gupta V, Gupta A and Rao NA. Intraocular tuberculosis—an update. *Surv Ophthalmol* 2007; **52**: 561-87.
82. Department of Health, Republic of South Africa, Pretoria, South Africa. National Tuberculosis Management Guidelines 2014. May 27, 2014. Available at: [http://www.sahivsoc.org/upload/documents/NTCPAdult\\_TB%20Guidelines%2027.5.2014.pdf](http://www.sahivsoc.org/upload/documents/NTCPAdult_TB%20Guidelines%2027.5.2014.pdf).
83. Schaftenaar E, Meenken C, Baarsma GS, et al. Good visual outcome of tuberculous chorioretinitis after ART initiation in a HIV-infected patient. *Int Ophthalmol* 2014; **34**: 1263-5.
84. Robinson MR, Ross ML and Whitcup SM. Ocular manifestations of HIV infection. *Curr Opin Ophthalmol* 1999; **10**: 431-7.
85. Kiss S, Damico FM and Young LH. Ocular manifestations and treatment of syphilis. *Semin Ophthalmol* 2005; **20**: 161-7.
86. Fonollosa A, Giralt J, Pelegrín L, et al. Ocular syphilis—back again: understanding recent increases in the incidence of ocular syphilitic disease. *Ocul Immunol Inflamm* 2009; **17**: 207-12.
87. Rose-Nussbaumer J, Goldstein DA, Thorne JE, et al. Uveitis in human immunodeficiency virus-infected persons with CD4+ T-lymphocyte count over 200 cells/mL. *Clin Experiment Ophthalmol* 2014; **42**: 118-25.
88. Woolston S, Cohen SE, Fanfair RN et al. A Cluster of Ocular Syphilis Cases – Seattle, Washington, and San Francisco, California, 2014-2015. *MMWR Morb Mortal Wkly Rep* 2015; **64**: 1150-1.
89. Sahin O and Ziaei A. Clinical and laboratory characteristics of ocular syphilis, co-infection, and therapy response. *Clin Ophthalmol* 2015; **10**: 13-28.
90. Margo CE and Hamed LM. Ocular syphilis. *Surv Ophthalmol* 1992; **37**: 203-20.
91. Troutbeck R, Chhabra R and Jones NP. Polymerase chain reaction testing of vitreous in atypical ocular syphilis. *Ocul Immunol Inflamm* 2013; **21**: 227-30.
92. Cornut PL, Sobas CR, Perard L, et al. Detection of *Treponema pallidum* in aqueous humor by real-time polymerase chain reaction. *Ocul Immunol Inflamm* 2011; **19**: 127-8.

93. Scheepers MA, Lecuona KA, Rogers G, et al. The value of routine polymerase chain reaction analysis of intraocular fluid specimens in the diagnosis of infectious posterior uveitis. *ScientificWorldJournal* 2013; **2013**: 545149.
94. Rothova A, de Boer JH, Ten Dam-van Loon NH, et al. Usefulness of aqueous humor analysis for the diagnosis of posterior uveitis. *Ophthalmology* 2008; **115**: 306-11.
95. Harper TW, Miller D, Schiffman JC, et al. Polymerase chain reaction analysis of aqueous and vitreous specimens in the diagnosis of posterior segment infectious uveitis. *Am J Ophthalmol* 2009; **147**: 140-7.
96. Otiti-Sengeri J, Colebunders R, Kempen JH, et al. The Prevalence and Causes of Visual Loss Among HIV-Infected Individuals With Visual Loss in Uganda. *J Acquir Immune Defic Syndr* 2010; **53**: 95-101.
97. Abu El-Asrar AM, Abouammoh M and Al-Mezaine HS. Tuberculous uveitis. *Int Ophthalmol Clin* 2010; **50**: 19-39.
98. Vasconcelos-Santos DV, Zierhut M and Rao NA. Strengths and weaknesses of diagnostic tools for tuberculous uveitis. *Ocul Immunol Inflamm* 2009; **17**: 351-5.
99. Wroblewski KJ, Hidayat AA, Neafie RC, et al. Ocular tuberculosis: a clinicopathologic and molecular study. *Ophthalmology* 2011; **118**: 772-7.
100. Hunter RS and Lobo AM. Current diagnostic approaches to infectious anterior uveitis. *Int Ophthalmol Clin* 2011; **51**: 145-56.
101. De Groot-Mijnes JD, Rothova A, Van Loon AM, et al. Polymerase chain reaction and Goldmann-Witmer coefficient analysis are complimentary for the diagnosis of infectious uveitis. *Am J Ophthalmol* 2006; **141**: 313-8.
102. Danise A, Cinque P, Vergani S, et al. Use of polymerase chain reaction assays of aqueous humor in the differential diagnosis of retinitis in patients infected with human immunodeficiency virus. *Clin Infect Dis* 1997; **24**: 1100-6.
103. Cheung CM, Durrani OM and Murray PI. The safety of anterior chamber paracentesis in patients with uveitis. *Br J Ophthalmol* 2004; **88**: 582-3.
104. Trivedi D, Denniston AK and Murray PI. Safety profile of anterior chamber paracentesis performed at the slit lamp. *Clin Experiment Ophthalmol* 2011; **39**: 725-8.
105. Van der Lelij A and Rothova A. Diagnostic anterior chamber paracentesis in uveitis: a safe procedure? *Br J Ophthalmol* 1997; **81**: 976-9.
106. Palmer JJ, Chinanayi F, Gilbert A, et al. Trends and implications for achieving VISION 2020 human resources for eye health targets in 16 countries of sub-Saharan Africa by the year 2020. *Hum Resour Health* 2014; **12**: 45.
107. De Smet MD, Taylor SRJ, Bodaghi B, et al. Understanding uveitis: the impact of research on visual outcomes. *Prog Retin Eye Res* 2011; **30**: 452-70.
108. Palella FJ Jr, Baker RK, Moorman AC, et al. Mortality in the highly active antiretroviral therapy era: changing causes of death and disease in the HIV outpatient study. *J Acquir Immune Defic Syndr* 2006; **43**: 27-34.
109. Johnson LF, Mossong J, Dorrington RE, et al. Life expectancies of South African adults starting antiretroviral treatment: collaborative analysis of cohort studies. *PLoS Med* 2013; **10**: e1001418.
110. Joint United Nations Programme on HIV/AIDS (UNAIDS). 90-90-90: An ambitious treatment target to help end the AIDS epidemic. UNAIDS; 2014.
111. Jabs DA, Van Natta ML, Sezgün E, et al. Prevalence of intermediate-stage age-related macular degeneration in patients with acquired immunodeficiency syndrome. *Am J Ophthalmol* 2015; **159**: 1115-22.

112. Jeng BH, Holland GN, Lowder CY, et al. Anterior segment and external ocular disorders associated with human immunodeficiency virus disease. *Surv Ophthalmol* 2007; **52**: 329-68.
113. Biswas J and Sudharshan S. Anterior segment manifestations of human immunodeficiency virus/acquired immune deficiency syndrome. *Indian J Ophthalmol* 2008; **56**: 363-75.
114. Engstrom RE Jr, Holland GN, Hardy WD, et al. Hemorheologic abnormalities in patients with human immunodeficiency virus infection and ophthalmic microvasculopathy. *Am J Ophthalmol* 1990; **109**: 153-61.
115. Guaraldi G, Orlando G, Zona S, et al. Premature age-related comorbidities among HIV-infected persons compared with the general population. *Clin Infect Dis* 2011; **53**: 1120-6.
116. Phillips AN, Neaton J and Lundgren JD. The role of HIV in serious diseases other than AIDS. *AIDS* 2008; **22**: 2409-18.
117. Rasmussen LD, Kessel L, Molander LD, et al. Risk of cataract surgery in HIV-infected individuals: a Danish Nationwide Population-based cohort study. *Clin Infect Dis* 2011; **53**: 1156-63.
118. Lecuona K and Cook C. South Africa's cataract surgery rates: why are we not meeting our targets? *S Afr Med J* 2011; **101**: 510-2.
119. Courtright P, Seneadza A, Mathenge W, et al. Primary eye care in sub-Saharan African: do we have the evidence needed to scale up training and service delivery? *Ann Trop Med Parasitol* 2010; **104**: 361-7.
120. Onakpoya OH, Adeoye AO, Adegbehingbe BO, et al. Assessment of human and material resources available for primary eye-care delivery in rural communities of southwestern Nigeria. *West Indian Med J* 2009; **58**: 472-5.



# Chapter 9

**Nederlandse samenvatting**





Oogziekten vormen een belangrijk, wereldwijd gezondheidsprobleem. Wanneer ze leiden tot slechtiendheid of blindheid heeft dat grote gevolgen voor de kwaliteit van leven van mensen die er door getroffen worden. Het vóórkomen van slechtiendheid en blindheid is ongelijk verdeeld over de wereld: ongeveer 90% van alle slechtienden leeft in een ontwikkelingsland. Op het Afrikaanse continent wordt dit mede veroorzaakt door de hoge prevalentie van het humaan immunodeficiëntievirus type 1 (HIV). Doordat dit virus specifieke cellen van het immuunsysteem aantast, neemt de weerstand van de patiënt tegen infecties af. Micro-organismen krijgen daardoor de kans om de ogen te infecteren, wat op den duur tot blindheid kan leiden. Alleen al in Zuid-Afrika zijn 6.8 miljoen mensen besmet met HIV. Er zijn helaas geen goede gegevens beschikbaar over de meest voorkomende oogziekten in Afrika, inclusief Zuid-Afrika. Beter inzicht hierin is van essentieel belang om de huidige oogheekundige zorg in deze regio te verbeteren en effectievere oogheekundige preventieprogramma's te ontwikkelen, waardoor blindheid voorkomen kan worden.

Dit proefschrift beschrijft onderzoek naar het vóórkomen van infectieuze en niet-infectieuze oogziekten in een ruraal gebied in Zuid-Afrika met een hoge HIV-prevalentie. Alle studies in dit proefschrift zijn uitgevoerd in het district Mopani in de provincie Limpopo. De gezondheidszorg in dit district heeft prioriteit binnen de Zuid-Afrikaanse regering vanwege de huidige slechte kwaliteit, de grote armoede onder de bevolking, de hoge graad van analfabetisme en werkloosheid en de zeer hoge prevalentie van HIV in dit gebied.

Allereerst werd de seroprevalentie bestudeerd van humane herpesvirussen (HHV) in Mopani. Van de in totaal acht bekende HHV zijn het herpes simplex virus type 1 (HSV-1), het varicella-zoster virus (VZV) en het cytomegalovirus (CMV) de belangrijkste veroorzakers van ooginfecties. Wereldwijd komen deze virussen veel voor. Gegevens over het Afrikaanse continent zijn echter schaars. Omdat de seroprevalentie van HHV verschilt per regio, kunnen infectiegegevens uit het ene land niet zomaar worden overgenomen voor het andere land. Kenmerkend voor HHV is de eigenschap dat deze virussen na primaire infectie latent aanwezig blijven in het lichaam, veelal zonder waarneembare schade aan te richten. Als gevolg van een afname van de weerstand kunnen ze echter na verloop van tijd weer actief worden. Deze reactivatie gaat doorgaans gepaard met ernstige ziekteverschijnselen waaronder ooginfecties. Vanwege de verminderde functie van hun immuunsysteem hebben HIV-geïnfecteerde personen een verhoogde kans op reactivatie van HHV. Onderzoek hiernaar is voornamelijk in westerse landen uitgevoerd. Daaruit blijkt dat CMV een grote rol speelt: toen er nog geen behandeling mogelijk was tegen HIV, kreeg ongeveer 40% van alle HIV-dragers te kampen met CMV-retinitis, een infectie van het netvlies die leidt tot blindheid. De introductie van antiretrovirale middelen tegen HIV heeft in de geïndustrialiseerde wereld geleid tot het vrijwel geheel

verdwijnen van deze ooginfectie bij deze groep patiënten. Dergelijke gegevens over de situatie in Afrika ontbreken vrijwel volledig, ondanks het feit dat dit continent het hardst getroffen is door de HIV-epidemie. Daarom werd in ons onderzoeksgebied allereerst gestart met het vaststellen van de seroprevalentie van HSV-1, HSV-2, VZV, CMV en het Epstein-Barr virus (EBV) in een groep van HIV-geïnfecteerde personen. In **hoofdstuk 2** laten wij zien dat de seroprevalentie van deze virussen in Mopani zeer hoog is: 98% voor HSV-1, 87% voor HSV-2, 89% voor VZV en 100% voor EBV en CMV. Ondanks deze zeer hoge besmettingsgraad wordt er in de zorg voor HIV patiënten in Zuid-Afrika vrijwel geen aandacht besteed aan deze virale infecties. Omdat HIV-geïnfecteerde personen een verhoogd risico lopen op het ontwikkelen van HHV-gerelateerde ziekten is het belangrijk dat deze mensen en hun zorgverleners zich daarvan beter bewust worden. Als de symptomen in een vroeg stadium herkend worden, zal er eerder hulp worden gezocht en kan er tijdig met behandelen worden gestart. Dit laatste is vooral belangrijk omdat vroegtijdige behandeling in de meeste gevallen blindheid kan voorkomen. Daarnaast spelen HHV (met name HSV-2) ook een rol in de verspreiding van HIV. Interventiestrategieën om bijvoorbeeld HSV-2 gerelateerde overdracht van HIV te verminderen, zouden dan ook een grotere aandacht moeten krijgen binnen het HIV-programma in Zuid-Afrika.

In **hoofdstuk 3** wordt onderzoek beschreven naar het vóórkomen en het klinisch beeld van infectieuze keratitis (infectie van het hoornvlies) in Mopani. Deze aandoening is een belangrijke veroorzaker van blindheid. Infectieuze keratitis kan veroorzaakt worden door zowel virussen, bacteriën alsook schimmels. Hoewel HIV-dragers een verhoogd risico hebben op virale keratitis, richten de huidige klinische richtlijnen in Zuid-Afrika zich voornamelijk op bacteriële verwekkers. Dit heeft tot gevolg dat mensen die zich bij rurale klinieken en ziekenhuizen melden met verschijnselen van een infectieuze keratitis op dit moment uitsluitend worden behandeld met antibiotica. Uit ons onderzoek blijkt echter dat HHV (voornamelijk VZV) in Mopani belangrijke veroorzakers van deze aandoening zijn, al dan niet gecompliceerd door secundaire bacteriële infecties. Dit is nog niet eerder beschreven en vooral belangrijk omdat de behandeling van een infectieuze keratitis bepaald wordt door de aard van de verwekker. De huidige richtlijn die uitsluitend antibacteriële middelen voorschrijft, is dus niet afdoende en leidt tot onderbehandeling. Anders dan in westerse landen waar HSV-1 de belangrijkste verwekker is van infectieuze keratitis, geldt voor de populatie in Mopani dat VZV de meest voorkomende oorzaak is. Hoogstwaarschijnlijk speelt de hoge HIV-prevalentie in dit gebied hierbij een belangrijke rol, omdat HIV-geïnfecteerde personen een sterk verhoogd risico hebben op het ontwikkelen van VZV-gerelateerde ziekten. Dit verhoogde risico is veel minder duidelijk aanwezig voor HSV-1. In **hoofdstuk 3** wordt de belangrijke rol besproken van de polymerasekettingreactie (PCR) en het kweken van bacteriën en schimmels

uitgevoerd op hoornvliesuitstrijkjes. Een PCR-analyse geeft voornamelijk informatie wanneer de ontsteking zich in het buitenste laagje van het hoornvlies (epitheel) bevindt. Bij ontstekingen dieper in het hoornvlies is de toegevoegde waarde van PCR-analyse minder groot. In ongeveer de helft van alle virale keratitiden werd ook een bacteriële superinfectie aangetroffen. Hoewel dit niet met een slechtere prognose was geassocieerd, is het aannemelijk dat dergelijke keratitiden wel gebaat zijn bij zowel een antibacteriële alsook een antivirale therapie. Naast de juiste keuze is ook het vroegtijdig behandelen van een infectieuze keratitis van groot belang om complicaties te voorkomen. Dit werd bevestigd in onze studie: naarmate de patiënten langer wachtten voordat ze naar de kliniek kwamen, nam de ernst van de slechtheid toe. Dit benadrukt het belang van snelle en adequate behandeling van patiënten met een infectieuze keratitis. Omdat de meeste patiënten in de bestudeerde populatie zich in eerste instantie wendden tot klinieken in de eerstelijns gezondheidszorg, is het van groot belang dat antivirale therapie voor infectieuze keratitis ook beschikbaar komt binnen de basisgezondheidszorg in ruraal Zuid-Afrika.

**Hoofdstuk 4** beschrijft de oogheelkundige complicaties bij herpes zoster ophthalmicus (HZO). Dit is de klinische manifestatie die op kan treden na reactivatie van een latente VZV-infectie in de vijfde hersenzenuw (de nervus trigeminus). Een dergelijk reactie begint met huidveranderingen in het gelaat, die gevolgd kunnen worden door oogproblemen. Het onderzoek toont aan dat het spectrum van de oogheelkundige complicaties van HZO divers is en dat de complicaties die leiden tot blindheid veel vóórkomen in de onderzochte populatie. Net als voor infectieuze keratitis geldt voor HZO dat de ernst van de aandoening sterk bepaald wordt door de tijd die verstreken is voordat de patiënt de juiste medische zorg krijgt. Wanneer binnen 72 uur na het ontstaan van de huidafwijkingen gestart wordt met behandeling kunnen oogcomplicaties worden voorkomen. Dit onderstreept opnieuw de noodzaak om antivirale therapie beschikbaar te stellen voor de eerstelijns gezondheidszorg in ruraal Zuid-Afrika. Geen specifieke redenen voor het (te) laat zoeken van medische hulp werden gevonden. Het is echter duidelijk dat er voor deze patiënten veel winst valt te behalen wanneer het ziektebeeld van HZO vroegtijdig wordt herkend door de zorgverleners maar vooral ook door de patiënten zelf. Goede voorlichting over de risico's van ooginfecties bij HIV-dragers kan daartoe bijdragen. Daarnaast geldt ook het omgekeerde: wanneer patiënten met HZO worden aangetroffen, dient de zorgverlener bedacht te zijn op een onderliggende HIV-infectie.

In **hoofdstuk 5 en 6** wordt het klinisch beeld en de etiologie van uveïtis beschreven, een potentieel agressief ziektebeeld dat een veel voorkomende oorzaak is van blindheid in ontwikkelingslanden. Uveïtis kan zowel infectieus van aard zijn als niet-infectieus (bijvoorbeeld veroorzaakt door een auto-immuunaandoening). Hoewel de hoge HIV-pre-

valentie in Zuid-Afrika waarschijnlijk de kans op het krijgen van een infectieuze uveïtis vergroot, is er nog maar weinig bekend over de oorzaken van uveïtis in deze regio. Een dergelijk inzicht is van groot belang omdat adequate behandeling van uveïtis bepalend is voor de prognose. In **hoofdstuk 5** wordt onderzoek beschreven naar de oorzaken van uveïtis in onze onderzoekspopulatie en wordt aangetoond dat de infectieuze vorm van uveïtis de belangrijkste vorm van uveïtis is met HHV, *Mycobacterium tuberculosis* (de veroorzaker van tuberculose) en *Treponema pallidum* (de veroorzaker van syfilis) als belangrijkste verwekkers. HHV-gerelateerde uveïtis werd voornamelijk veroorzaakt door VZV. Onze bevindingen wijken daarmee af van de beschikbare gegevens uit westerse landen, waar CMV de belangrijkste verwekker is van uveïtis bij HIV-geïnfecteerde personen. Dit onderstreept het belang van regio-specifieke klinische richtlijnen voor uveïtis. Naast HHV als veroorzaker van uveïtis is er een belangrijke rol weggelegd voor *M. tuberculosis*. Dit is zeer relevant omdat er momenteel in Zuid-Afrika geen aandacht wordt besteed aan *M. tuberculosis* als verwekker van deze aandoening. Zo bevat de Zuid-Afrikaanse tuberculoserichtlijn geen informatie over de oogheelkundige ziekteverschijnselen bij tuberculose en wordt er niets geschreven over de noodzakelijke oogheelkundige zorg.

De diagnostiek van uveïtis vormt een groot probleem in ontwikkelingslanden. Hoewel een snelle diagnose en snelle start van specifieke therapie van groot belang zijn om blindheid te voorkomen, is dit hier veelal niet haalbaar. Dit komt onder meer door het gebrek aan oogheelkundige expertise, waardoor diagnose op basis van klinische verschijnselen vrijwel volledig ontbreekt. In **hoofdstuk 5** wordt aangetoond dat de huidige diagnostiek van uveïtis in Zuid-Afrika kan worden verbeterd door deze uit te breiden met laboratoriumdiagnostiek van het voorste oogkamervocht (in verband met HHV) en een thoraxfoto (in verband met tuberculose).

In **hoofdstuk 6** wordt een casus van een infectieuze uveïtis beschreven, die wordt veroorzaakt door *M. tuberculosis* bij een HIV-geïnfecteerde patiënt vlak na het starten van de behandeling met antiretrovirale medicijnen. Dit ziektebeeld was hoogstwaarschijnlijk onderdeel van een zogenaamd “immune reconstitution inflammatory syndrome”, een syndroom dat kan optreden als gevolg van een (gedeeltelijk) herstel van de immuunfunctie na succesvolle behandeling met antiretrovirale medicijnen. Deze casus benadrukt het belang van screening op (oculaire) tuberculose en basaal oogheelkundig onderzoek in 2 fases van behandeling met antivirale middelen: voordat gestart wordt met medicatie en tijdens routinematige vervolgbezoeken.

In **hoofdstuk 7** wordt het effect beschreven van de antiretrovirale therapie op het vóórkomen van oogziekten in Mopani. Vanaf het moment dat medicamenteuze behandeling met antiretrovirale medicijnen voor HIV mogelijk werd, is de levensverwachting van HIV-geïnfecteerden sterk verbeterd. In westerse landen werd tevens een daling van het aantal ooginfecties gezien, voornamelijk als gevolg van de verbetering van de

immuunstatus dankzij deze medicijnen. De invloed van deze middelen in Afrikaanse landen op het vóórkomen van oogziekten is echter onbekend. In Zuid-Afrika is de dekkingsgraad van antiretrovirale medicijnen nog altijd laag. Daarnaast zoeken HIV-geïnficeerden vaak pas in een laat stadium van de ziekte medische hulp, waardoor het immuunsysteem inmiddels al ernstig is aangetast. Nieuwe strategieën van zowel de Zuid-Afrikaanse overheid en organisaties als Joint United Nations Programme on HIV/AIDS (UNAIDS) zullen hopelijk leiden tot een afname van het aantal patiënten met een ernstige immuundeficiëntie en daarmee wellicht ook tot een afname van het aantal infectieuze oogziekten. Aangezien deze medicijnen levenslang ingenomen moeten worden, zijn de effecten op het vóórkomen van oogziekten echter nog grotendeels ongewis. Enkele studies uit westerse landen (onder andere in de Verenigde Staten van Amerika en Italië) rapporteren dat mensen die antiretrovirale medicijnen gebruiken een verhoogd risico hebben op niet-infectieuze oogziekten zoals diverse vormen van retinopathie en staar. In **hoofdstuk 7** wordt de verdeling en manifestatie beschreven van oogziekten bij HIV-geïnficeerde personen in Mopani die wel of niet antiretrovirale medicijnen gebruikten. In deze studie tonen wij aan dat oogklachten en oogziekten meer voorkomen bij HIV-geïnficeerden dan bij niet HIV-geïnficeerde personen, waarbij het voornamelijk gaat om uitwendige oogziekten (vooral ontsteking van de ooglidrand) en ziekten van het voorste segment van het oog (vooral pterygium, droge ogen en staar). Daarnaast kwamen er bij HIV-geïnficeerde personen die langer dan drie jaar antiretrovirale medicijnen gebruikten meer oogziekten voor van het achterste oogsegment (vooral HIV-geassocieerde retinopathie) dan bij personen die deze medicijnen minder dan één jaar gebruikten. Een HIV-geassocieerde retinopathie is zowel geassocieerd met de duur van het gebruik van deze medicatie als met de mate waarin het immuunsysteem is aangetast bij de start van deze therapie. Ook staar komt in Mopani meer voor bij personen die langer dan drie jaar antiretrovirale medicijnen gebruikten en de kans om staar te krijgen nam toe bij toename van de periode waarin deze medicatie werd gebruikt.

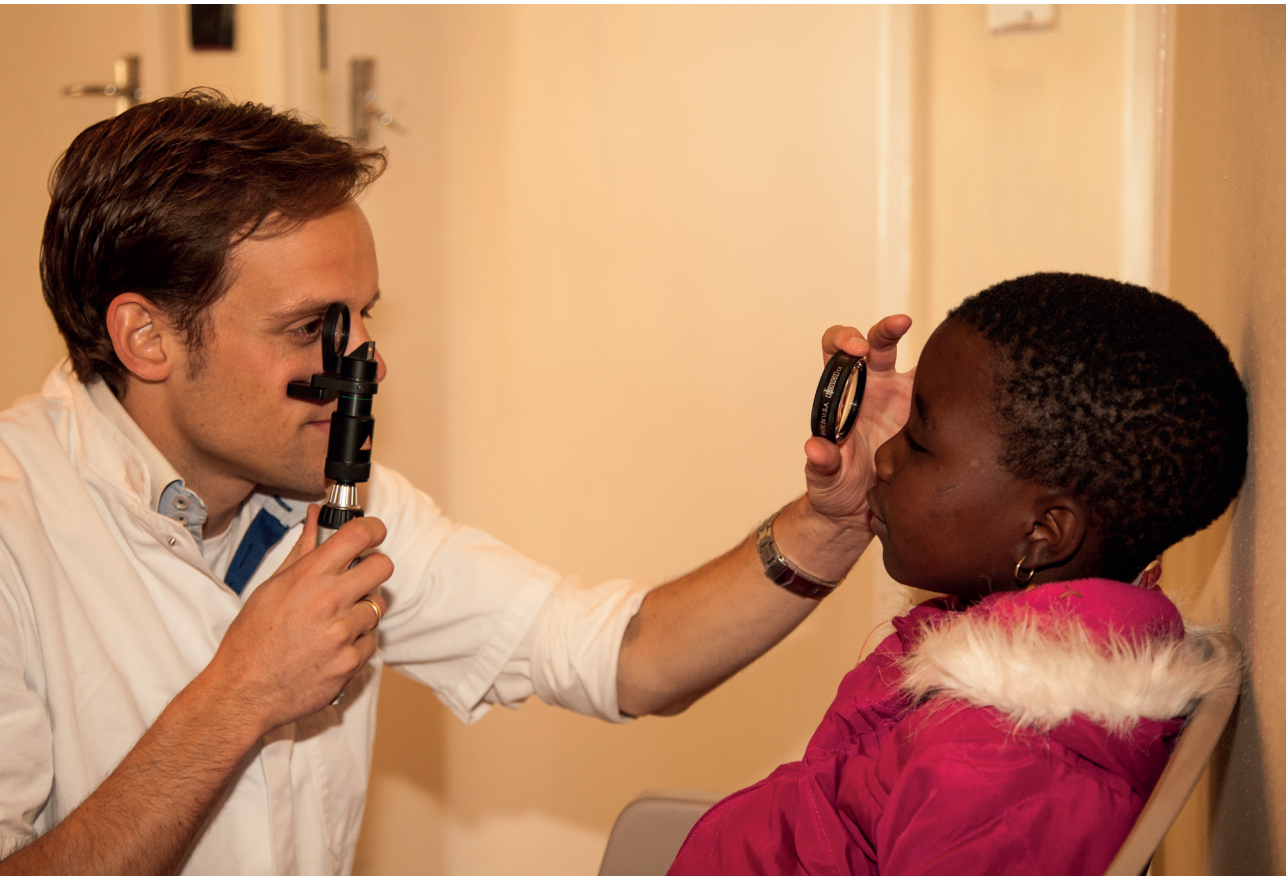Verschillende mechanismen kunnen bijdragen aan de verhoogde kans op oogziekten bij HIV-geïnficeerde personen. Zo lijkt bijvoorbeeld de status van het immuunsysteem bij de aanvang van de behandeling met antiretrovirale medicijnen een rol te spelen. Hierop kunnen HIV programma's inspelen door een vroegtijdige start met deze medicijnen te bevorderen. In het huidige HIV-programma van Zuid-Afrika wordt nauwelijks aandacht aan oogziekten geschonken. De resultaten van ons onderzoek laten zien dat oogziekten veel vóórkomen in de onderzochte bevolkingsgroep. Wanneer zorgverleners in Zuid-Afrika zich hier meer van bewust worden, zal dit zeker bijdragen aan het tijdig onderkennen van de symptomen waardoor sneller met behandelen kan worden begonnen. Daarnaast zou ontwikkeling en implementatie van reguliere oogheelkundige screeningsprogramma's voor HIV-geïnficeerde personen – ook na het starten van

antiretrovirale therapie – kunnen bijdragen aan het vroegtijdig opsporen van oogziekten, waardoor behandeling tijdig kan worden ingezet.

Samenvattend heeft onderzoek beschreven in dit proefschrift geleid tot nieuwe inzichten in de oorzaken en verschijningsvormen van oogziekten bij mensen die met HIV zijn geïnfecteerd in een Afrikaans gebied met een zeer hoge HIV-prevalentie. Deze inzichten wijken op bepaalde gebieden af van het bestaande beeld dat voornamelijk gebaseerd is op westerse studies en zijn daar een belangrijke aanvulling op. Het onderzoek laat zien dat er dringend nieuwe klinische richtlijnen en preventiestrategieën moeten worden ingevoerd in Zuid-Afrika, die gericht zijn op het vroegtijdig opsporen en behandelen van oogziekten bij mensen die met HIV zijn geïnfecteerd.







# Chapter 10

**About the author**

Curriculum vitae

PhD portfolio

List of publications



## **CURRICULUM VITAE**

The author of this thesis, Erik Schaftenaar, was born on the 31th of May 1984 in Wageningen, the Netherlands. He passed his pre-university secondary education exam at the Melanchthon College Rotterdam in 2002 after which he started the study Biomedical Sciences at the University of Antwerp, Belgium. In 2003 Erik switched to Medicine at the Radboud University Nijmegen, the Netherlands.

Born in an expat family his passion for Africa started at an early age. In 2005 his wish to work in Africa was fulfilled for the first time when he worked in Ghana as a medical student in a variety of healthcare facilities (Free and Fair Pharmacy, Berecum Clinic, and SDA Hospital). During that period he also conducted a public health oriented study on the quality of healthcare in different rural settings (prof. dr. E. Roscam Abbing). In 2007 Erik conducted a retrospective study on maxillofacial trauma at the department of maxillofacial surgery of the Muhimbili Medical Centre in Dar es Salaam, Tanzania (prof. dr. M.A. Merckx and prof. dr. E.N. Simon). From 2007 he was the treasurer of the student organisation of the Nijmegen Institute for International Health. In 2009 Erik followed an internship in Tropical Medicine in northern Tanzania (dr. M. Keuter). In the meantime, he conducted a malaria study in three district hospitals (dr. T. Bousema and dr. S.A. Shekalaghe).

In 2010 Erik obtained his medical degree and started working as a resident in the department of General Surgery of the Slingeland Hospital, Doetinchem, the Netherlands, as part of a Tropical Medicine training program. In 2011 he started his residency in Ophthalmology at the Rotterdam Eye Hospital which was interrupted in 2012 when he started his PhD program at the department of Viroscience at the Erasmus MC under supervision of prof. dr. A.D.M.E. Osterhaus, prof. dr. G.M.G.M. Verjans, and prof. dr. R.P.H. Peters. His PhD studies were conducted in the rural Mopani District of the Limpopo Province in South Africa and provide novel insight into the clinical field of ophthalmology in this high HIV prevalence setting. In December 2015 Erik returned to the Netherlands.

Erik is married to Tanja Weyer. Together they have two daughters, Sarah and Eveline.



---

## PhD PORTFOLIO

**Name:** Erik Schaftenaar

**Research group:** Erasmus MC, department of Viroscience

**PhD period:** 2012-2016

**First promotor:** Prof.dr. Albert D.M.E. Osterhaus

**Second promotor:** Prof.dr. Georges M.G.M. Verjans

**Third promotor:** Prof.dr. Remco P.H. Peters

### Poster presentations:

- 7th South African AIDS Conference (Durban, South Africa) 2015

### Oral presentations:

- Eye Symposium (Tzaneen, South Africa) 2015
- Health science Café Johannesburg (Johannesburg, South Africa) 2013

### Attended conferences, symposia and meetings:

- Eye Symposium (Tzaneen, South Africa) 2015
- 7th South African AIDS Conference (Durban, South Africa) 2015
- PMTCT symposium (Tzaneen, South Africa) 2013
- Health System Strengthening symposium (Tzaneen, South Africa) 2013
- Sexual Health and Contraception in the ERA of HIV (Tzaneen, South Africa) 2012

### Supervision and teaching activities:

- Co-supervisor of the Ophthalmology technical advisor at Anova Health Institute 2013-2015
- Co-supervisor of the Research nurse at Anova Health Institute 2013-2015



## LIST OF PUBLICATIONS

HIV-infected individuals on long-term antiretroviral therapy are at higher risk for ocular disease.

**Erik Schaftenaar**, N. Sellina Khosa, G. Seerp Baarsma, Christina Meenken, James A. McIntyre, Albert D.M.E. Osterhaus, Georges M.G.M. Verjans and Remco P.H. Peters.  
Submitted, 2016.

Uveitis is predominantly of infectious origin in a high HIV and TB prevalence setting in rural South Africa.

**Erik Schaftenaar**, Christina Meenken, G. Seerp Baarsma, N. Sellina Khosa, Ad Luijendijk, James A. McIntyre, Albert D.M.E. Osterhaus, Georges M.G.M. Verjans and Remco P.H. Peters.  
Br J Ophthalmol. 2016; in press.

Clinical and corneal microbial profile of infectious keratitis in a high HIV prevalence setting in rural South Africa.

**Erik Schaftenaar**, Remco P.H. Peters, G. Seerp Baarsma, Christina Meenken, N. Sellina Khosa, Sarah Getu, James A. McIntyre, Albert D.M.E. Osterhaus and Georges M.G.M. Verjans.  
Eur J Clin Microbiol Infect Dis. 2016; in press.

Gonococcal conjunctivitis despite successful treatment of male urethritis syndrome.

Remco P.H. Peters, Stephan P. Verweij, James A. McIntyre and **Erik Schaftenaar**.  
Sex Transm Dis. 2016;43(2):120-1.

Early- and late-stage ocular complications of herpes zoster ophthalmicus in rural South Africa.

**Erik Schaftenaar**, Christina Meenken, G. Seerp Baarsma, James A. McIntyre, Georges M.G.M. Verjans and Remco P.H. Peters.  
Trop Med Int Health. 2016;21(3):334-9.

Anterior chamber paracentesis to improve diagnosis and treatment of infectious uveitis in South Africa.

**Erik Schaftenaar**, Karin Lecuona, G. Seerp Baarsma, Christina Meenken, Georges M.G.M. Verjans, James A. McIntyre and Remco P.H. Peters.  
S Afr Med J. 2015;105(8):628-30.



Bilateral dislocation of the ocular lens in an African child.

**Erik Schaftenaar**, G. Seerp Baarsma and Remco P.H. Peters.

Arch Dis Child. 2015;100(8):732.

Ocular infections in sub-Saharan Africa in the context of high HIV prevalence.

**Erik Schaftenaar**, Eric C.M. van Gorp, Christina Meenken, Albert D.M.E. Osterhaus, Lies Remeijer, Helen E. Struthers, James A. McIntyre, G. Seerp Baarsma, Georges M.G.M. Verjans and Remco P.H. Peters.

Trop Med Int Health. 2014;19(9):1003-14.

Good visual outcome of tuberculous chorioretinitis after ART initiation in a HIV-infected patient.

**Erik Schaftenaar**, Christina Meenken, G. Seerp Baarsma, Georges M.G.M. Verjans and Remco P.H. Peters.

Int Ophthalmol. 2014;34(6):1263-5.

High seroprevalence of human herpesviruses in HIV-infected individuals attending primary healthcare facilities in rural South Africa.

**Erik Schaftenaar**, Georges M.G.M. Verjans, Sarah Getu, James A. McIntyre, Helen E. Struthers, Albert D.M.E. Osterhaus and Remco P.H. Peters.

PLoS One. 2014;9(6):e99243.

Malaria diagnostic testing and treatment practices in three different Plasmodium falciparum transmission settings in Tanzania: before and after a government policy change. Guido J.H. Bastiaens\*, **Erik Schaftenaar**\*, Arnold Ndaro, Monique Keuter, Teun Bousema and Seif A. Shekalaghe.

Malar J. 2011;10:76.

Presentation and management of maxillofacial trauma in Dar es Salaam, Tanzania.

**Erik Schaftenaar**\*, Guido J.H. Bastiaens\*, Elison N. Simon and Matthias A.W. Merckx.

East Afr Med J. 2009;86(6):254-8.

\* Both authors contributed equally.





# Chapter 11

Dankwoord



"The journey is the destination." Dan Eldon.

Mijn journey is gevormd door alle inspirerende mensen die ik heb ontmoet en met wie ik de afgelopen vier jaar heb mogen samenwerken. Hen allen wil ik enorm bedanken.

Allereerst gaat mijn dank uit naar al mijn patiënten en hun naasten voor hun medewerking aan mijn studies. Dankzij hen is dit proefschrift tot stand gekomen waarmee we de challenges van Mopani op de kaart hebben gezet. "I know a change is gonna come, oh yes it will." Earl Simmons (DMX).

"Daar heb je die Schaftenaar weer...". Ab Osterhaus.

Beste **Ab**, na een kleine omweg kwam ik met een projectvoorstel bij je in Rotterdam terecht. Vanaf dat moment heb ik onze samenwerking als prettig ervaren. Al was het op afstand, je was altijd goed te bereiken voor mijn vragen. Ik wil je hartelijk bedanken voor de mogelijkheid die je me hebt gegeven mijn promotieonderzoek uit te kunnen voeren in Zuid-Afrika.

"One paper a day keeps the promotor away". Georges Verjans.

**Georges**, bedankt voor de sturing, suggesties en adviezen. Je commentaar op manuscripten leidde altijd tot een verbetering en een significant heldere boodschap.

"Stress is een keuze". Remco Peters.

**Remco**, waar begin ik... Het was in 2011 dat ik samen met Tanja bij jou, **Femke** en **Stijn** op bezoek kwam om na te gaan of een promotietraject in "jouw" setting mogelijk was en of we ons als gezin thuis konden voelen in het rurale Zuid-Afrika. Het klikte direct en een volle werkweek volgde. In die week hebben we diverse klinieken en ziekenhuizen bezocht en hebben we de basis gelegd voor het proefschrift dat hier nu voor je ligt. Jij zag en ziet mogelijkheden die andere niet zagen en zien. De meest levendige herinnering aan die week is uiteraard onze meeting in het Dr. C.N. Phatudi Hospital, waar de autobanden in brand stonden en de bakstenen over ons hoofd vlogen. Het schrikte ons niet af. Die ene week in 2011 heeft mijn leven op een zeer positieve manier veranderd, dank daarvoor. Naast die eerste week hebben we ongelofelijk veel meegemaakt, je zou er een thesis van kunnen schrijven: whisky, vleermuizen, koffieperikelen, METc aanvragen, Mankweng, klimgordels, ..., etc. Je bent daarnaast één van de weinige die de volgende stelling echt begrijpt: "Mopani? Never a dull moment!". Ook de momenten buiten werk, samen met onze families, zijn zeer waardevol. Een whiskyfles hoort in een avond leeg te gaan! Je bent een prettige promotor geweest en je blijft, naast een collega, een vriend. Onze samenwerking zal zeker een vervolg hebben. Dus: tot snel in Zuid-Afrika.

“En wat was de CD4 count?” Ina Meenken.

**Ina**, eigenlijk begint alles, via de werkgroep tropische oogheelkunde, bij jou. Ik kwam bij jou met een zeer open vraag: ik wil promoveren in Afrika op het onderwerp infectieuze oogziekten. Je hebt me altijd gesteund, verdedigd en geholpen. Jij bracht mij in contact met Remco en bent altijd aan boord gebleven, ook al ging het project uiteindelijk naar Rotterdam. Je input is altijd van grote waarde geweest.

“Tot ziens!”. Seerp Baarsma.

**Seerp**, eerst vanuit het ROI, samen met **Netty Dorrestijn**, ondersteunde je mijn projecten, later vooral in de rol als expert opinion en medeauteur. Je commentaar op klinische vragen is gewoonweg fantastisch: geen woord teveel en glashelder. Je bezoek, samen met **Jan Pameijer**, was meer dan waardevol. Het was een gezellige week waarbij de ondersteuning en waardering die ik van jullie kreeg geweldig was. De verhalen over vroeger en hoe alles anders was, zullen me nog lang bijblijven.

**Jan van Meurs** en **Dion Paridaens**, graag wil ik jullie bedanken voor de mogelijkheid die jullie me hebben gegeven mijn promotieonderzoek te verrichten in Zuid-Afrika. Op mijn sollicitatiegesprek kwam ik met veel plannen en ideeën die stuk voor stuk, mede door de ondersteuning vanuit Het Oogziekenhuis Rotterdam, uitgevoerd zijn.

Graag wil ik ook de (ex-)leden van de Herpesgroep Rotterdam bedanken. In 2011 kwam ik na een hectisch jaar Chirurgie ineens te werken op een laboratorium. Dat was een immens verschil waarbij jullie, **Monique, Werner, Gijs, Freek**, met jullie humor hebben bijgedragen aan een fijne tijd. Daarnaast wil ik graag het secretariaat van de afdeling bedanken, in het bijzonder **Simone** en **Loubna**, voor de geweldige hulp die jullie me gaven bij vragen vanuit Zuid-Afrika en voor de gezellige gesprekken tijdens het wachten op een vrij plekje in Ab's overvolle agenda. Beste **Wim** en **Avinash**, dank voor jullie geduld en uitleg bij alle financiële aspecten.

“E bitswa Africa, Go nna ke gae! (They call it Africa, I call it home!)”. Author unknown.

All my projects have been conducted in the beautiful country South Africa. I owe everything to the great people of this country that welcomed me and my family since 2011.

Dear **Helen** and **James**, how can I ever thank you and **Anova Health Institute** enough?! The freedom, support, hospitality, and kindness I received as a foreigner is amazing. Partnering with you has been a pleasure and I do hope we will continue to work together to improve healthcare and especially eye care in South Africa. **Jean**, from a senior doctor to program manager: a big step, but you killed it! It was great to have a leader in Tzaneen

again and it was great that this leader was you. The trips to Johannesburg and Durban were valuable and our discussions about the history of South Africa, the South African healthcare system, the HPCSA, the way forward, and many other topics were inspiring.

“Ntshuxeka, aku na xilo lexinga ta lungha (Relax, nothing is under control)”. Sellina Khosa. **Sellina**, mutirhi kuloni, nakulobye, kokwana wanga. Na khensa eka ku tirha hiku ti nyiketa na rirhandzu. Eka mbhurisano wa matimu na vumundzuku bya tiko raka nwina ro xonga swi ta tshama eka mina. Umu tiyisisi wa leswaku malembe aya vuli nchumu!

**Babra**, we share the passion for the eye. Your enthusiasm and dedication to improve the quality of eye care is heart-warming, keep up the good work!

I would like to thank all other employees of Anova Health Institute that I have worked with, our journey was epic. Special thanks go to Khutso Kurhula: **Dikeledi Arvinah, Mutasa Barry, Maluleke Christina, Olga Daswa, Magdeline Kekana, Kgomotso Khoza, Emmanuel Maakana, Fridah Maake, Peter Maake, Maimiele Makgoba, Siyani Marima, Vincent Matome, Ntemby Mbambazela, Eddy Miyeni, Pinky Mnetwa, Aubrey Moagi, Mokgadi Moagi, Moshape Isaac Modiba, Raymond Mohale, Mmathabo Mosue, Nathaniel Muditambi, Mary Muhlari, Lighty Mushwanaa, Nkateko Nkuna, Mathilda Ralephenya, Lucy Ranoto, Sylvester Rasekgotoma, Godfrey Sekgololo, Buhle Sibuyi and Queen Xivambu. Jarieke**, dank voor je gezelligheid in de laatste maanden van mijn verblijf in Zuid-Afrika. Het was gezellig en goed dat ik “mijn” office en mijn challenges (waaronder never ending koffie perikelen) met je kon delen!

In addition to the Khutso Kurhula team I would like to thank the Soweto and Cape Wineland Anova teams for their endless patience, approval does not come in one day, and their participation in the baseline study. Special thanks go to: **Nelis Grobbelaar, Theunis Hurter, Moyahabo Mabitsi, Hanlie Myburgh and Bongwiwe Vilakazi.**

Without the **Department of Health**, none of the studies would have been conducted. I would like to thank the entire Department of Health from the Mopani District, in particular **dr. Bogale** and **dr. Marincowitz**. The ophthalmology outpatient department staff of “my” three hospitals deserve special thanks: **S. Letsoalo, K. Mahowa, M. Ngwenya Mosima, Jacky Makgahlela, Pretty Mametsa, Becky Talani and Angy Mohale** from **Kgapane hospital**; **dr. Nhangwana, S. Khwashu, M. Malembe, M. Diale, B. Marokana, S. Nkhwashu, M. Rabotha** from **Dr. C.N. Phatudi hospital** and **B. Baloyi, R. Mashele, M. Maswakhomu, M. Ramoadi, S. Mokgehle** and **T. Mehlaphe** from **Letaba hospital**. Also, I would like to thank all the **primary and community healthcare facilities** that participated in my studies with special thanks to **Tintswalo Nkwinika** from



**Nkowankowa Health Centre**. And last but not least **Mankweng hospital**, especially **dr. Moabelo Monareng**, for the cooperation during my stay in Mopani.

The laboratory work of my Thesis is partially done at the **Lancet Laboratory** at Tzaneen. I would like to thank all the staff for the good time I had at your laboratory. Special thanks go to **Anneke Botha** and **Caroline Ramushu Maluleke** for their help and kindness.

I would also like to thank **Peter Braker** and **prof. Roscam Abbing** for my time in Tamale, Ghana; **prof. Merkx** and **prof. Simon** for my time in Dar es Salaam, Tanzania; **dr. Seif**, **dr. Bousema** and **dr. Keuters** for my time in Rubya, Biharamulo and Sumve, Tanzania.

Terug naar Nederland. Vrienden en vriendinnen, dank dat jullie er voor me zijn. **Gui. de**, Guido, in je eigen proefschrift vroeg je je af waar je was geweest zonder mij. Dat geldt net zo hard voor mij. Sinds de eerste werkgroep zijn we matties en in onze top-10 levensgebeurtenissen komen we veelal samen voor. Je bezoek hier, samen met **Else**, was fantastisch: Mozambique, het strand en het bier! Dat we **Liselot** konden ontmoeten tijdens ons korte bezoek aan Nederland was zeer waardevol. Paul maak het khapot! zoals je in onze familie heet, oftewel **Tuup**. Wat een toptijd was dat met jou en **Saar** in Zuid-Afrika. Momenten als deze maakten ons leven daar compleet. **Dr. Stone**, Sjoerd, samen met **Sandra** en **Emma** ben je in een moeilijke periode toch bij ons gekomen in Zuid-Afrika. Jullie bezoek gaf veel rust en je open en positieve blik gaven me hoop in een zeer lastige periode van mijn promotie. **Macho bv**, Roddy, nuchter, scherp en als het moet hard! Uiteraard ook mijn respect voor de rest van de **TTT**. Lieve **Mark**, **Jet**, **Ymke** en **Olaf**. Anders dan op een vakantie, waar het vreselijk is Nederlanders tegen te komen, was het heerlijk Nederlandse vrienden te hebben in een land zo ver weg van Nederland. De tijd die we met elkaar hebben doorgebracht was erg waardevol en de keizersnede die ik met Mark kon meedoen, blijft een bijzondere ervaring voor een promovendus. **Alex**, je nuchtere blik en bijna anti-wetenschap houding geeft me veel ammunisie!

Collegae van Het Oogziekenhuis Rotterdam, zonder jullie indirecte hulp was het me niet gelukt mijn proefschrift af te ronden in 2016. Al ga ik jullie verlaten als AIOS, ik hoop dat ik nog steeds welkom ben bij de gezellige OZR borrels!

Dan mijn paranimfen, **Willem** en **Christiaan**. Jullie zijn oude rotten in het vak en ik vertrouw volledig op jullie als mijn paranimfen. **Willem**, er is maar één Bwana voor mij. **Christiaan**, je kennis en rust maken het geweldig om met je te filosoferen. Je vakantie bij ons in Zuid-Afrika is memorabel.

Ten slotte familie. **Jacqueline, Willem, Marjolein, Thomas** en **Vincent**, bedankt voor jullie steun, betrokkenheid en interesse in mijn onderzoek. Jullie vakanties in Zuid-Afrika waren geweldig. **Vincent**, jij verdient een extra vermelding vanwege onze geweldige tijd samen in Zuid-Afrika, ruim vier maanden in drie en een half jaar, dat is toch wel een record?

“Het is nooit op”. Tanja Schaftenaar.

**Tanja**, waar was ik geweest zonder je? Nergens. Je steun is onvoorwaardelijk, net als je liefde. Ook al deel ik die liefde tegenwoordig met onze kabouters **Sarah** en **Eveline**, zij neemt nooit af! Je bent mijn rots in de branding en daarnaast ben je mijn persoonlijke data-expert ;-)

**In every end, there is also a beginning**

The burden of ocular disease in sub-Saharan African countries is disproportionately high, especially among HIV-infected individuals. This thesis presents the results of studies that provide novel insight into the clinical field of ophthalmology in a high HIV prevalence setting in rural South Africa (Mopani District, Limpopo Province). This insight opens the door for further improvement of the clinical care for individuals affected by HIV-associated ocular diseases.