


Provided for non-commercial research and education use.
Not for reproduction, distribution or commercial use.



This is an open access article which appeared in a journal published by Elsevier. This article is free for everyone to access, download and read.

Any restrictions on use, including any restrictions on further reproduction and distribution, selling or licensing copies, or posting to personal, institutional or third party websites are defined by the user license specified on the article.

For more information regarding Elsevier's open access licenses please visit:

<http://www.elsevier.com/openaccesslicenses>



ELSEVIER

Contents lists available at ScienceDirect

JPRAS Open

journal homepage: <http://www.journals.elsevier.com/jpras-open>

Original article

Acute changes in clinical breast measurements following bra removal: Implications for surgical practice

Joanna Scurr^{a,*}, Amy Loveridge^a, Nicola Brown^b, Chris Mills^a^a Research Group in Breast Health, University of Portsmouth, Cambridge Road, Portsmouth, Hampshire, UK^b School of Sport, Health and Applied Science, St Mary's University, Waldegrave Road, Twickenham, Surrey, UK

ARTICLE INFO

Article history:

Received 9 January 2015

Accepted 13 January 2015

Available online 28 January 2015

Keywords:

Breast

Biomechanics

Displacement

Strain

ABSTRACT

Background: Stable measurement of breast position is crucial for objective pre-operative planning and post-operative evaluation. In clinical practice, breast measures are often taken immediately following bra removal. However, research shows that restrictive clothing (such as a bra) can cause acute anatomical changes, leading to the hypothesis that clinical breast measures may change over time following bra removal. This cross-sectional observational study aimed to provide simple clinical guidelines for the measurement of breast position which account for any acute changes in breast position following bra removal.

Methods: Thirteen participants of varying breast sizes had markers attached to their thorax and nipples to determine clinical measures of sternal notch to nipple distance, internipple distance, breast projection, and vertical nipple position. The positions of these landmarks were recorded using a motion capture system during 10 min of controlled sitting following bra removal.

Results: Internipple distance and breast projection remained unchanged over 10 min, while the resultant sternal notch to nipple distance extended by 2.8 mm in 299 s (right) and 3.7 mm in 348 s (left). The greatest change occurred in the vertical nipple position, which migrated an average of 4.1 mm in 365 s (right) and 6.6 mm in 272 s (left), however, for one participant vertical migration was up to 20 mm.

* Corresponding author. Tel.: +44 2392 845161; fax: +44 2392 843680.

E-mail address: Joanna.scurr@port.ac.uk (J. Scurr).

Conclusions: Internipple distance and breast projection can be measured first following bra removal, followed by sternal notch to nipple distance, any measures associated with the vertical nipple position should be made more than 6 min after bra removal. These guidelines have implications for breast surgery, particularly for unilateral reconstruction based on the residual breast position.

© 2015 The Authors. Published by Elsevier Ltd on behalf of British Association of Plastic, Reconstructive and Aesthetic Surgeons. This is an open access article under the CC BY license (<http://creativecommons.org/licenses/by/4.0/>).

Introduction

Breast surgery has been reported to lack accuracy and reproducibility,¹ highlighting the need for objective breast measurements that are accurate and repeatable. Breast measurement techniques include manual positional measurement such as sternal notch to nipple distance, internipple distance, breast projection, and vertical nipple position.

Whilst patient orientation during breast measurement has been investigated, no research has considered the stability of clinical breast measures. Typically, these measurements occur shortly after patients remove their bra and it is assumed that these measures remain stable over time. This assumption has implications for unilateral breast surgery, when the residual breast position informs the reconstructed breast position. The assumption that breast position remains stable is challenged by previous literature which shows restrictive clothing causing acute anatomical changes. Previous research has reported bras causing chronic shoulder furrows of 3 cm², decreased chest girth, decreased vertical nipple position, increased breast circumference and increased internipple distance.³ While other research has reported that skin takes time to recover from compression.⁴ These studies suggest that bras may cause acute changes in breast tissue position, which may affect clinical breast measures. Therefore, this study hypothesized that the following clinical breast measures would significantly change over 10 min after bra removal; sternal notch to nipple distance, internipple distance, nipple projection, and inferior nipple migration.

Materials/patients and methods

Following ethical approval, thirteen females (eligibility criteria: no surgical or clinical breast treatment, nulligravida) provided informed consent and breast sizes were established (Table 1). In a private area, participants removed their upper body clothing and were seated in a control chair. Markers were attached to the sternal notch, left and right anteroinferior tenth rib and nipples.⁵ Participants remained as still as possible for 10 min as marker coordinates were recorded using motion capture cameras (50 Hz, Qualisys, Sweden). Markers were identified with 0.6 mm accuracy. Coordinate systems were established and multiplanar nipple coordinates, independent to thorax position, were calculated every sample.⁵ Relative nipple position data were filtered with 0.09 Hz cut-off frequency to eliminate breathing artefacts.

The following clinical measures were calculated every sample; 1. resultant distance from sternal notch to nipples, 2. internipple distance; resultant distance between left and right nipple, 3. nipple projection; sagittal plane, perpendicular distance from thorax plane (defined by sternal notch and rib markers) to nipple, 4. inferior or superior migration; vertical change in nipple position (in the local coordinate system, relative to the sternal notch).

To determine changes in measures across the trial, start and end nipple positions were statistically compared. Measures where significant changes occurred ($P < 0.05$) demonstrated exponential change (supporting previous stress/strain literature for skin). Magnitude (c) and rate of change (b), and time (t) at which steady state occurred were investigated (Equation (1)).

Table 1

Participant characteristics, direction of breast movement and change in vertical position of the right (R) and left (L) nipple over the 10 min trial following bra removal.

Breast size	Age (yrs)	Direction of change						Vertical nipple position (mm)	
		Vertical (Inferior migration)		Mediolateral (Internipple distance)		Anteroposterior (Nipple projection)		Magnitude of change	
		↑ Superior	↓ Inferior	← R lateral	→ R medial	↙ Anterior	↗ Posterior	x No change	x No change
		R	L	R	L	R	L	R	L
34C	20	↓	↓	←	x	↗	↙	-0.8	-2.0
34D	21	↓	↓	←	←	↗	↗	-0.8	-2.4
32D	24	↓	↓	→	→	↙	↙	-3.9	-2.8
34D	36	↓	↓	x	←	↗	↙	-3.1	-10.4
34D	25	↑	↓	←	←	↙	↙	1.1	-2.8
34D	25	↓	↓	→	→	↙	↗	-1.3	-0.4
34D	21	↓	↓	←	→	↙	↙	-4.5	-5.7
34D	39	↓	↓	→	←	↙	↗	-4.7	-7.8
34DD	27	↓	↓	→	←	↗	↗	-13.2	-12.2
32DD	22	↓	↓	→	←	↗	x	-7.0	-17.0
34DD	25	↓	↓	x	←	x	x	-7.2	-19.9
32DD	29	↓	↓	←	x	↙	x	-2.7	-5.6
34E	28	↓	x	→	←	↙	↙	-3.7	-7.1
Mean	26							-4.0	-7.4
SD	5.7							3.7	6.0

$$f(t) = c(1 - e^{-bt}) \tag{1}$$

Results

Resultant distance from sternal notch to right and left nipples showed significant increases of 2.7 mm and 3.9 mm from the first to last 2 s of the trial ($t = 4.803_{(12)}, P < 0.001$; $t = 7.138_{(12)}, P < 0.001$). Internipple distance and nipple projection remained unchanged over the trial (Table 1).

Twelve of thirteen participants demonstrated inferior nipple migration over the trial (Table 1) from -176 mm (right) and -179 mm (left) below the sternal notch to -180 mm (right; $t = 3.67_{(12)}, P = 0.003$) and -186 mm (left; $t = 4.44_{(12)}, P = 0.001$) 10 min later. The right and left nipples reached steady state at 365 s and 272 s after bra removal (Figure 1).

Discussion

This study found that resultant sternal notch to nipple distances increased by 2.7 mm (right) and 3.9 mm (left) over 10 min, accepting the hypothesis. Although statistically significant, this change is small and unlike to affect clinical measurements. Internipple distance and nipple projection did not change, rejecting the hypothesis. However, vertical nipple position demonstrated the greatest change following bra removal, accepting the hypothesis for this measure. This change was ~20 mm in one participant, averaging 7.4 mm across the group for the left nipple. These magnitudes of change are likely to be clinically significant. Modelling data established that the right and left nipples reached steady state within 365 s and 272 s following bra removal.

From these results it is suggested that measures of vertical nipple position should be completed at least 6 min after bra removal. This presents an easy to follow clinical recommendation that could be incorporated into existing practice without increasing consultation time, whilst ensuring a stable breast position.

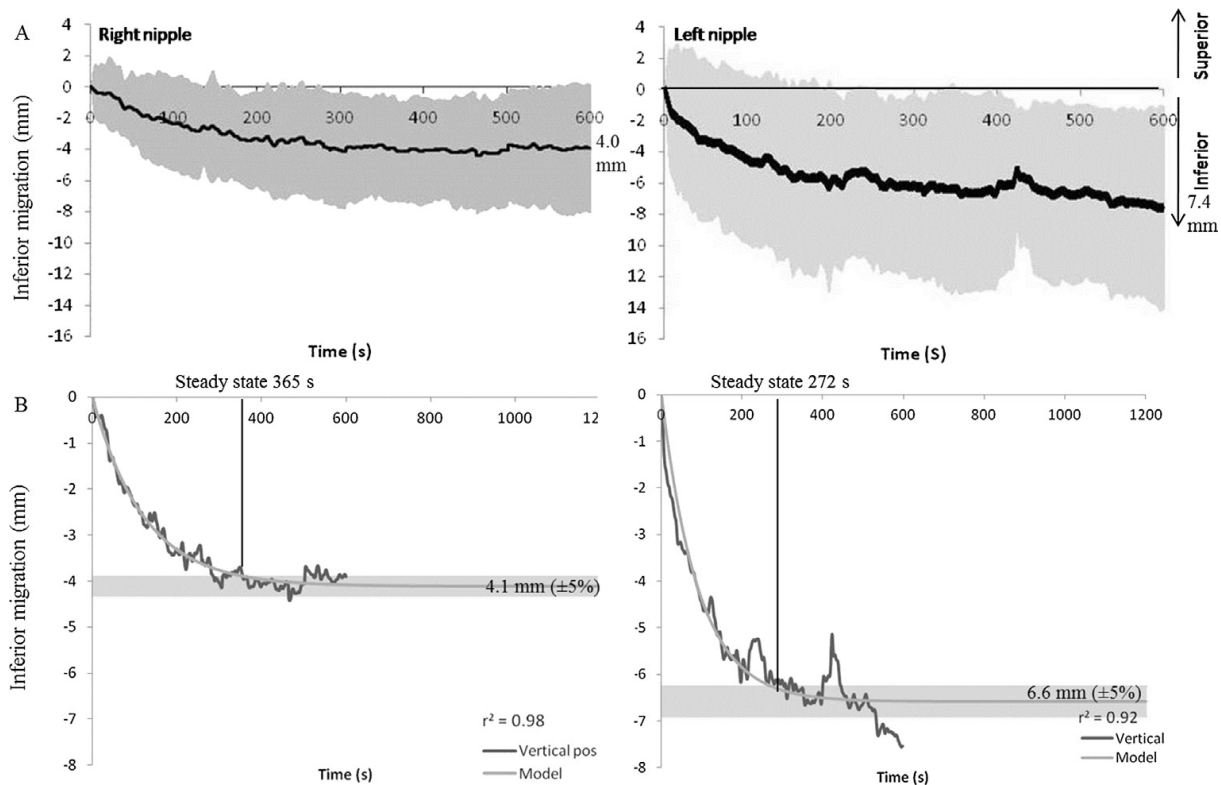


Figure 1. A) Mean (grey error bars display standard deviations) inferior migration (mm) of the left and right nipple over the 10 min trial following bra removal. B) Optimized models of inferior migration extended to 20 min; grey panel shows $\pm 5\%$ steady state boundaries ($n = 13$).

In conclusion, this is the first study to identify that clinical measures of breast position are influenced by bra use prior to their assessment. To reduce this confounding variable clinicians are recommended to measure vertical nipple position at least 6 min after bra removal. With one participant experiencing ~ 20 mm inferior nipple migration, these results have implications for breast surgery, particularly when residual breast position informs reconstructed breast position.

Ethical approval

This study received Ethical Approval from the Science Faculty Ethics Committee at the University of Portsmouth. Ethics Approval number: BSREC12/059.

Conflicts of interest statement

None.

Acknowledgements

No external funding was received for this study.

References

1. Henseler H, Smith J, Bowman A, et al. Subjective versus objective assessment of breast reconstruction. *J Plast Reconstr Aesthet Surg.* 2013;66:634–639.
2. Mentz H, Ruiz-Razura A, Miniell L. Correction of the bra strap shoulder groove deformity in women. *Plast Reconstr Surg.* 2007; 120:2122–2123.
3. Ashizawa K, Sugana A, Gunji T. Breast form changes resulting from a certain brassiere. *J Hum Ergol.* 1999;19:53–62.
4. Daly CH, Odland GF. Age-related changes in the mechanical properties of human skin. *J Invest Dermatol.* 1979;73:84–87.
5. Scurr J, White J, Hedger W. The effect of breast support on the kinematics of the breast during the running gait cycle. *J Sports Sci.* 2010;28:1103–1109.