

Renovascular hypertension in a 12 month old boy: what can the radiologist do?

Alexandre Mota¹; Paulo Donato¹; Maria José Noruegas¹;
Vítor Carvalheiro¹; Ângela Moreira¹

ABSTRACT

We report a clinical case of renovascular disease, probably linked to fibromuscular dysplasia, in a 12 months old boy with severe arterial hypertension with target-organ damage, highlighting the radiological approach.

Initial investigation included renal ultrasound that showed normal sized kidneys, with normal cortical echogenicity on the right and focally increased echogenicity of the posterior aspect of the left kidney, forming a mass-like lesion. Magnetic resonance imaging excluded renal tumor, which was confirmed by ultrasound guided biopsy. A doppler ultrasonography was also performed suggesting a right renal artery stenosis and decreased flow to the posterior aspect of the left kidney. Angiography with diagnostic and therapeutic intention was performed: right renal artery stenosis was detected and transluminal ballon dilation was performed; the left renal artery bifurcated precociously and the branch that irrigated the posterior part of the kidney had a stenosis which was also successfully dilated. After the intervention good blood pressure control with antihypertensive drugs was achieved, which was not possible before the angiographic procedure.

The authors underline various methods of imaging used to accurately diagnose renovascular disease and the usefulness of interventional radiology treatment for this disease in very young children.

Keywords: Hypertension; renovascular; Percutaneous transluminal angioplasty; ultrasonography; Doppler.

HIPERTENSÃO RENOVASCULAR NUM RAPAZ COM 12 MESES: O QUE PODE O RADIOLOGISTA FAZER?

RESUMO

Apresentamos um caso clínico de doença renovascular, provavelmente relacionada com displasia fibromuscular, num lactente do sexo masculino de 12 meses de idade com hipertensão arterial grave associada a lesões de órgãos-alvo, destacando a abordagem radiológica.

A avaliação inicial incluiu ecografia renal, que mostrou rins de tamanho normal, com ecogenicidade cortical normal à direita e aumento focal da ecogenicidade na vertente posterior do rim esquerdo, simulando uma massa. Na avaliação por ressonância magnética foi excluída lesão de natureza tumoral, o que foi confirmado por biópsia renal ecoguiada. Foi efetuada ecografia Doppler que sugeriu a presença de estenose da artéria renal direita e diminuição do fluxo para a vertente posterior do rim esquerdo. Efetuou-se angiografia com intenção diagnóstica e terapêutica em que foram detetadas estenoses da artéria renal direita, sendo efetuada dilatação transluminal por balão; a artéria renal esquerda bifurcava precocemente e o ramo que irrigava a vertente posterior do rim apresentava estenose que também foi dilatada com sucesso.

Após a intervenção, foi obtido controlo tensional com medicamentos anti hipertensores, o que não tinha sido possível antes do procedimento angiográfico.

Os autores realçam os vários métodos de imagem utilizados para diagnosticar com precisão a doença renovascular e a utilidade do tratamento por radiologia de intervenção para esta doença em crianças muito jovens.

Palavras-chave: Hipertensão renovascular; angioplastia transluminal percutânea; ecografia Doppler.

Nascer e Crescer 2016; 25(2): 99-103

¹ S. de Imagiologia, Centro Hospitalar Tondela-Viseu. 3504-509 Viseu, Portugal.

alexandremota85@gmail.com

¹ S. de Imagiologia, Centro Hospitalar Universitário de Coimbra.

3000-075 Coimbra, Portugal.

donato.pj@gmail.com; mjtnoruegas@gmail.com; vcarvalheiro@netca-bo.pt; angela.moreira@sapo.pt

INTRODUCTION

Arterial hypertension occurs in 1%-2% of children.¹ Unlike in adults where arterial hypertension is usually idiopathic, in young children hypertension is more often a consequence of an underlying anomaly or disease.^{2,3} Renovascular disease (RVD) is responsible for about 10% of secondary childhood hypertension. Its detection is important since it may be amenable to treatment.¹⁻⁴ In adults atherosclerosis is the most common cause of RVD, mostly affecting the main renal arteries.⁵ The diagnostic spectrum is different in children, with the most common reported diagnosis being fibromuscular dysplasia (FMD) - it is, however, unusual for histological confirmation to be obtained and as such it is usually an exclusion diagnosis.⁵ In eastern countries Takayasu's arteritis is more common than FMD. Neurofibromatosis type 1, Williams syndrome and tuberous sclerosis are other causes of pediatric RVD.^{3,4}

FMD is a noninflammatory, nonatherosclerotic disorder, that leads to arterial stenosis. It has been linked to genetic mechanisms and hormonal factors, but the pathogenesis of this disease remains unknown.⁵

The authors describe the case of a child with severe hypertension secondary to RVD, probably linked to FMD, underlining the imaging pathway for the diagnosis and interventional radiology therapeutic procedures for RVD.

CASE REPORT

A 12 month old caucasian boy with failure to thrive and motor development regression was admitted to our hospital with severe arterial hypertension that was uncontrollable with antihypertensive medication (four drug association). He had the following target-organ damage: sub-cortical atrophy on

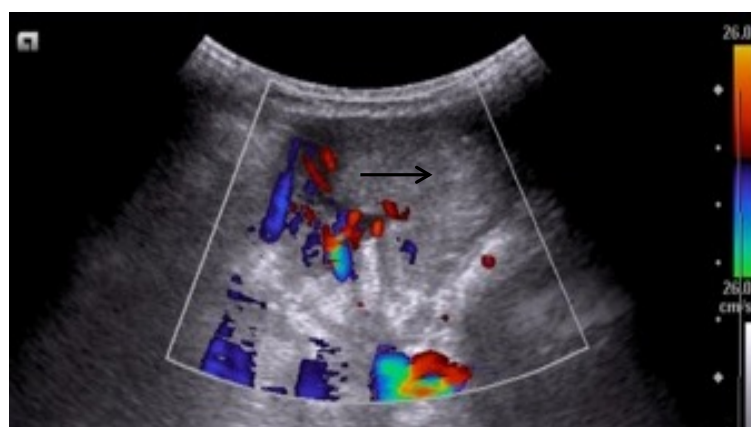
brain magnetic resonance imaging, concentric left ventricular hypertrophy, proteinuria with normal renal function and hypertensive retinopathy.

The pathway to diagnosis included the following imaging procedures:

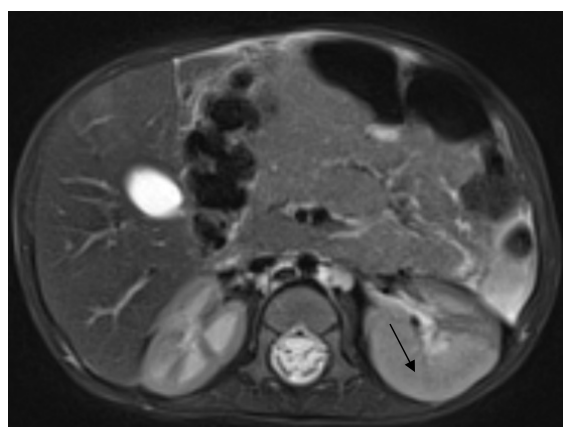
-Renal ultrasound: Normal sized kidneys, with normal cortical echogenicity on the right and focally increased echogenicity of the posterior portion of the left kidney, forming a mass-like lesion (Fig.1-A).

-Abdominal magnetic resonance imaging (MRI) was performed to exclude neoplastic etiology: globally augmented left kidney with increased parenchymal thickness, especially on its posterior aspect and increased cortical signal while maintaining corticomedullary differentiation (Fig.1-B). Renal artery and vein could not be accessed. MRI findings did not support tumoral etiology, which was confirmed by ultrasound guided biopsy (histology revealed nephroangiosclerosis).

- Renal ultrasound with Doppler study was performed to exclude vascular anomalies: preserved vascularization on the anterior portion of the left kidney and heterogeneity of its posterior portion with decreased vascularization of this area (Fig. 2-A). There was increased peak systolic velocity (PSV) and turbulence at the left renal artery and increased intrarenal resistive index (RI) (near 1), as shown in Fig. 2-B. There was reduced intrarenal RI on the right kidney (0,56) with increased systolic ascension time ("parvus tardus" morphology), as shown in Fig. 3-A. On the proximal one third of the renal artery there was increased peak systolic velocity and increased turbulence (Fig. 3-B). These changes suggested decreased flow to the posterior aspect of the left kidney and right renal artery stenosis. Additionally there was small volume pleural effusion and moderate volume peritoneal effusion.



A



B

Figura 1 – A- Ultrasound and color Doppler, slightly oblique axial section: focally increased echogenicity of the posterior aspect of the left kidney, forming a mass-like lesion (arrow). Reduced vascularization at posterior renal aspect. B- MRI (transverse section, T2 weighted image) shows a globally augmented left kidney with increased parenchymal thickness, especially on its posterior aspect (arrow) with increased cortical signal while maintaining corticomedullary differentiation.

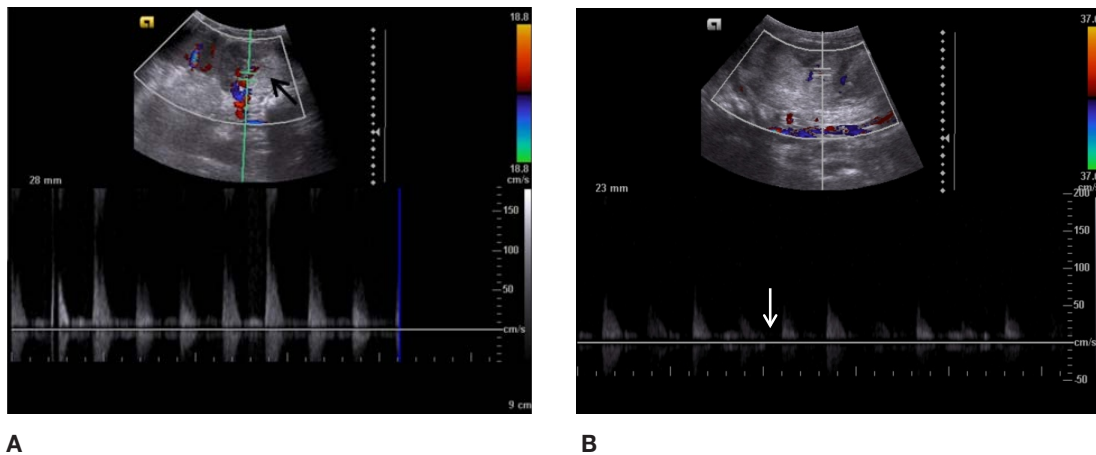


Figura 2 – A – Doppler US: heterogeneity of the posterior aspect of the left kidney (arrow) with decreased vascularization of this area, preserved on the anterior aspect of the kidney. B- Doppler US: intrarenal resistive index (RI) was increased (near 1 – note the diastolic velocity near the baseline - arrow).

- Angiography with diagnostic and therapeutic intention was performed: two right renal artery stenosis were detected; the left renal artery bifurcated precociously and there were no changes in one of these branches while on the inferior one there was a stenosis (Figs. 4-A and 4-B). Transluminal ballon dilation of these stenosis was performed. During the left renal artery angioplasty a small hemorrhage occurred which was solved with micro coil placement.

OUTCOME AND FOLLOW-UP

Transluminal dilatation allowed a good blood pressure control with antihypertensive drugs, which could not be achieved before the procedure.

A control renal Doppler was performed: on the proximal one third of the right renal artery there was still increased peak systolic velocity and increased turbulence. On the left there was normal peak systolic velocity. Intrarenal RI was increased on both sides (right kidney- 0,72M left kidney- 0,78). Intrarenal increased RI was considered related to prior parenchymal changes. Control angiography was suggested. Control angiography showed no stenosis greater than 50% bilaterally (Figs. 5-A and 5-B).

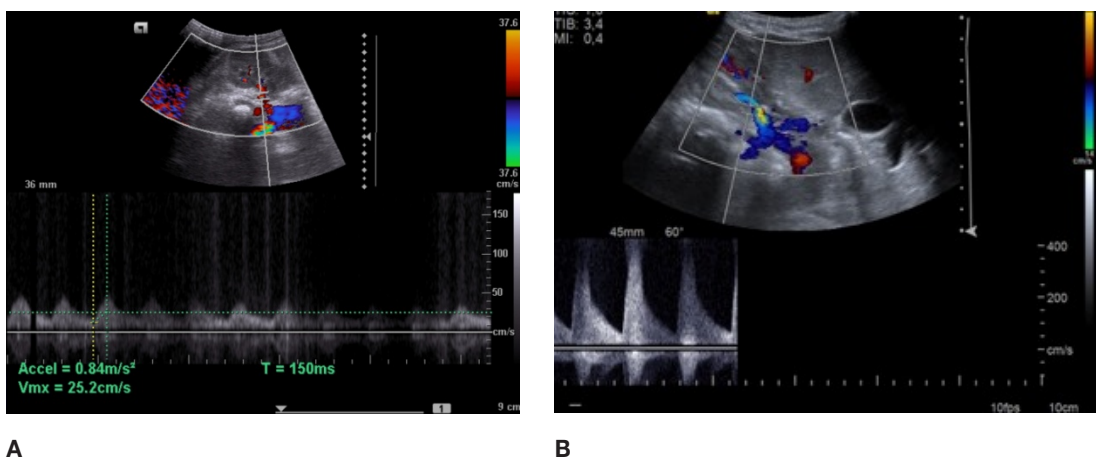


Figura 3 – A- Doppler US: reduced intrarenal RI on the right kidney (0,56) with increased systolic ascension time (“parvus tardus” morphology). B- Doppler US: There was increased peak systolic velocity (note the aliasing effect on the image despite the scale being adjusted for 200 cm/s) and increased turbulence at the renal artery.

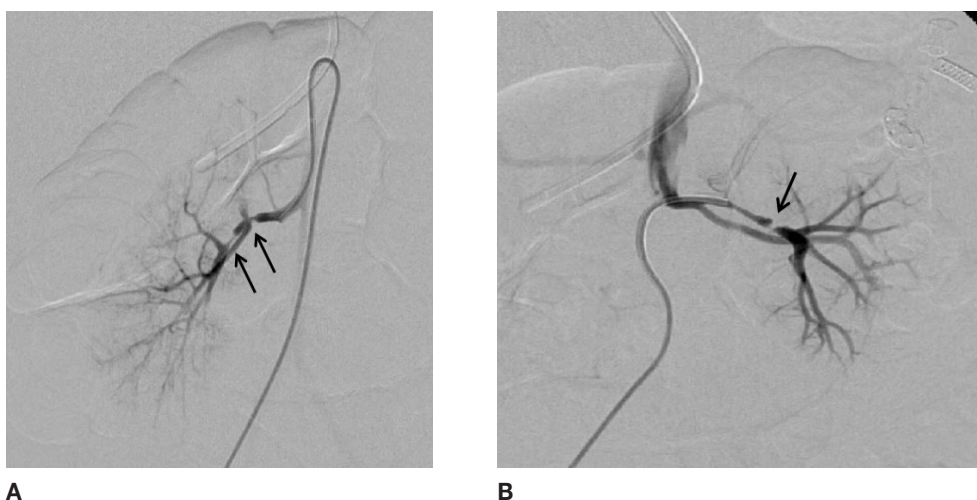


Figura 4 – A- Digital subtraction angiography: two right renal artery stenosis (arrows); B- Digital subtraction angiography: the left renal artery bifurcated precociously and there were no changes in one of these branches and there was a stenosis on the branch to the inferior and posterior aspects of the kidney (arrow).

DISCUSSION

Renovascular disease in children is frequently widespread, often with bilateral involvement of the renal arteries and their branches as our patient. Bilateral occurrence is quite frequent, occurring in 60% of cases in FMD.⁵

The gold standard for diagnosing RVD is renal angiography with digital subtraction.^{3,4} However a variety of noninvasive imaging modalities can also be used to evaluate RVD, such as magnetic resonance angiography (MRI-A), computed tomography angiography (CTA) and Doppler ultrasound. However, sensitivity is much lower than with digital subtraction renal angiography, although the specificity is very high.¹⁻⁴

The noninvasive imaging method of choice should be based upon institutional experience.

MRI-A imaging with gadolinium administration is being increasingly used as a screening test for patients considered likely to have atherosclerotic RVD. FMD, however, typically affects the middle and distal portions of the renal artery and is therefore less likely to be visualized by MRI-A with a high percentage of false negative test. Inadequate spatial resolution and movement artifacts are other limitations in MRI-A.^{3,4}

Spiral CT scan with intravenous contrast injection (CT angiography – CTA) is another highly accurate noninvasive test. CTA offers better spatial resolution than does MRI-A, but at the

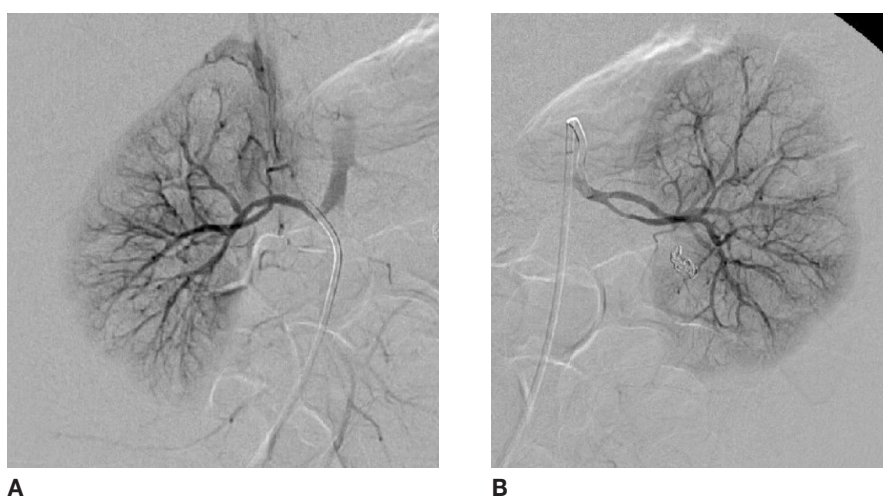


Figura – 5. Digital subtraction angiography: Right (A) and left (B) kidneys on control angiography showed no stenosis greater than 50%.

price of the patient's exposure to ionizing radiation, which is a particularly important limitation to its use in children.^{3,4}

Our patient had an early branch of the left renal artery with a severe stenosis that irrigated the posterior part of the kidney. The initial ultrasound image had revealed a focal increased echogenicity of the posterior aspect of the left kidney which raised the possibility of a tumoral mass (nephroblastoma includes hypertension as a clinical manifestation). This fact dictated the sequence of exams performed. Abdominal MRI did not support the tumoral etiology, which ultrasound guided biopsy definitely excluded. As such, a Doppler ultrasonography was performed and was essential to the diagnosis of RVD in our patient. It is a safe technique, the equipment is widely available and the procedure is painless and well tolerated by children. However it is technically difficult and is highly operator-dependent. If technical expertise is available, it is a very useful test for RVD.⁷

Direct visualization of renal artery stenosis is usually not possible in children when gray-scale ultrasound imaging is used. However, the use of color Doppler together with pulsed-wave Doppler allows a real-time trace of flow velocity.

At the intrarenal level when the acceleration time is increased and the PSV is low a characteristic flattened waveform (*tardus et parvus* phenomenon) is observed, as happened on the right kidney of our patient. This may be seen unilaterally, distal to a severe renal artery stenosis, or bilaterally in mid-aortic syndrome (MAS) or coarctation or in bilateral severe main renal artery stenosis.³ At the main renal artery level, a stenosis of the renal artery may lead to a loss of laminar flow and increased PSV, as happened on the right renal artery in our patient.

Percutaneous angioplasty (PTA) is a less invasive procedure than surgery, involves less hospitalization time and can be repeated if necessary.⁸⁻¹⁴ PTA with stent placement has gained acceptance as first line therapy in adults FMD compared with PTA alone.¹⁰ In children PTA with balloon angioplasty is still the most widely accepted method. PTA for pediatric RVD related to FMD and neurofibromatosis type 1 is a clinically feasible procedure (although rates of benefit from percutaneous angioplasty are less than those demonstrated in adults).¹¹⁻¹³

In the present case, percutaneous angioplasty with balloon dilation allowed a good control of hypertension not previously possible with antihypertensive drugs alone. Follow-up is however mandatory since FMD is a potentially progressive disease.⁵

With this case the authors highlight various methods of imaging used to accurately identify renovascular disease and reveal the usefulness of interventional radiology in treating very young children, like this 12-month old baby boy with bilateral disease.

REFERENCES

1. Srinivasan A, Krishnamurthy G, Fontalvo-Herazo L, Nijs E, Keller MS, Meyers K, Kaplan B *et al*. Angioplasty for renal artery stenosis in pediatric patients: an 11-year retrospective experience. *J Vasc Interv Radiol*. 2010;21: 1672-80.
2. Giavroglou C, Tsifountoudis I, Boutzetis T, Kiskinis D. Failure and success of percutaneous angioplasty in a hypertensive child with bilateral renal artery stenosis. *C Cardiovasc Intervent Radiol*. 2009;32: 150-4.
3. Marks SD, Tullus K. Update on imaging for suspected renovascular hypertension in children and adolescents. *Curr Hypertens Rep*. 2012;14: 591-5.
4. Tullus K, Roebuck DJ, McLaren CA, Marks SD. Imaging in the evaluation of renovascular disease. *Pediatr Nephrol*. 2010;25: 1049-56.
5. Slovut DP, Olin JW. Fibromuscular dysplasia. *N Engl J Med*. 2004; 350: 1862-71.
6. Burnei G, Burnei A, Hodoroagea D, Gavrilu S, Georgescu I, Vlad C *et al*. Reno-ureteral diseases inducing hypertension in children. *Rom J Intern Med*. 2008;46: 367-74.
7. Chhadia S, Cohn RA, Vural G, Donaldson JS. Renal Doppler evaluation in the child with hypertension: a reasonable screening discriminator? *Pediatr Radiol*. 2013;43: 1549-56.
8. Zhu G, He F, Gu Y, Yu H, Chen B, Hu Z *et al*. Angioplasty for pediatric renovascular hypertension: a 13-year experience. *Diagn Interv Radiol*. 2014;20: 285-92.
9. Alfonzo JP, Ugarte C, Banasco J, Fraxedas R, Gutiérrez F, Lahera J. Renovascular hypertension in children and adolescents: diagnosis and treatment over 19 years. *Nefrologia*. 2006;26: 573-80.
10. Dworkin LD, Cooper CJ. Clinical practice. Renal-artery stenosis. *N Engl J Med*. 2009;12;361: 1972-8.
11. Alhadad A, Mattiasson I, Ivancev K, Gottsäter A, Lindblad B. Revascularisation of renal artery stenosis caused by fibromuscular dysplasia: effects on blood pressure during 7-year follow-up are influenced by duration of hypertension and branch artery stenosis. *J Hum Hypertens*. 2005;19: 761-7.
12. Kari JA, Roebuck DJ, McLaren CA, Davis M, Dillon MJ, Hamilton G *et al*. Angioplasty for renovascular hypertension in 78 children. *Arch Dis Child*. 2015;100: 474-8.
13. Niimura F, Matsuda S, Okamoto S, Suganuma E, Takakura H, Sugiyama Y *et al*. Renovascular hypertension due to bilateral renal artery stenosis treated with stent implantation in a 12-year old girl. *Tokai J Exp Clin Med*. 2008;20;33: 78-83.
14. Geavlete O, Călin C, Croitoru M, Lupescu I, Ginghină C. Fibromuscular dysplasia-a rare cause of renovascular hypertension. Case study and overview of the literature data. *J Med Life*. 2012;15;5: 316-20.

ENDEREÇO PARA CORRESPONDÊNCIA

Alexandre Mota
Serviço de Imagiologia
Centro Hospitalar Tondela-Viseu
Av. Rei Dom Duarte, 3504-509 Viseu.
Email: alexandremota85@gmail.com

Recebido a 26.11.2015 | Aceite a 18.12.2015