

Recurrent focal myositis: a rare inflammatory myopathy

Teixeira F¹, Peixoto D¹, Costa JA¹, Bogas M¹, Taipa R², Melo Pires M², Afonso C¹, Araújo D¹

ACTA REUMATOL PORT. 2014;39;172-175

ABSTRACT

Focal myositis is an acute and localized muscle inflammation of unknown aetiology. The clinical diagnosis is often difficult to obtain, since it can be confused with infections, vascular thrombosis or muscle tumours such as sarcomas. This leads to a significant delay in the diagnosis, resulting in the administration of inappropriate and potentially harmful treatments. We report here a case of recurrent focal myositis in a woman where the diagnosis was only obtained after 6 years, despite multiple hospital admissions. This case reinforces the importance of clinical knowledge and experience to tackle challenging medical scenarios.

Keywords: Focal myositis; Muscle biopsy

INTRODUCTION

Focal myositis (FM) is a rare inflammatory myopathy of unknown aetiology. It is characterized by an inflammatory pseudotumour located in the skeletal muscle, most commonly from the thigh or calf region without features of systemic involvement. It can also rarely involve the muscles from the upper limbs¹.

The clinical diagnosis is often difficult to make because of a clinical overlap with infections, deep vein thrombosis and muscle tumours such as sarcomas. This leads to significant delay in the diagnosis, resulting in the administration of inappropriate and potentially harmful treatments².

Blood tests do not usually detect special findings, and the histological examination usually shows severe myopathy with inflammatory infiltration, necrosis, variations in the fiber diameter and regeneration. Magnetic resonance imaging (MRI) is a non-invasive tech-

nique which has been used as a major evaluation tool³.

Despite spontaneous improvement, focal myositis presents during the acute phase with pain and complications can be prevented by conservative treatments such as analgesia, anti-inflammatory drugs and physiotherapy. Treatment with corticosteroids and immunomodulators such as methotrexate should be considered in recurrent disease⁴.

We report a case of recurrent focal myositis in a woman where the diagnosis was obtained only after 6 years, despite the typical presentation and multiple hospital admissions. This delay in the diagnosis may be explained by the fact that this is a rare disease and unknown for most physicians.

CASE REPORT

A 35 years-old caucasian woman was admitted to the hospital with severe pain, swelling and redness in the left thigh and right arm. The pain got progressively worse, and she was unable to walk on admission. There were no other symptoms and no history of immobility, recent surgery or trauma was noticed.

This patient had three previous admissions in another hospital. In the first one she presented with acutely painful and swollen left thigh. In the second event, symptoms were localized to the right arm and the third was similar to the first one.

Infections, vascular causes and neoplasia were excluded, since *Borrelia*, *Campylobacter*, *Chlamydia*, *Salmonella*, *Yersinia*, HIV, Hepatitis B and C tests were negative, and radiologic studies such as computed tomography (CT) angiography and MRI showed no alterations.

An open muscle biopsy was performed and it showed monocyctic and lymphocytic infiltration with areas of myocyte degeneration suggesting myositis ossificans (MO). In all the episodes, symptoms resolved spontaneously without any specific therapeutic intervention. The patient was discharged from hospital with the diagnosis of MO and in-between these episodes, she re-

1. Serviço de Reumatologia do Hospital de Ponte de Lima, Unidade Local de Saúde do Alto Minho

2. Serviço de Neuropatologia, Hospital de Santo António, Centro Hospitalar do Porto

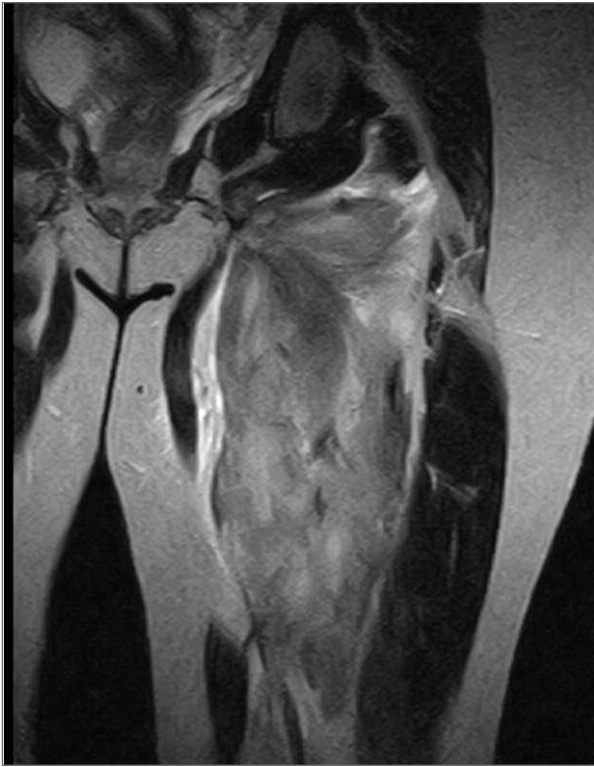


FIGURE 1. A T2 weighted magnetic resonance imaging – high signal intensity in *adductor magnus* and *adductor brevis* suggestive of local muscle inflammation

mained asymptomatic. This diagnosis was made despite the absence of heterotopic muscle calcification/os-sification.

Further detailed history failed to identify any specific cause for the current presentation. There was no history of fever, rash, generalized muscle pain or weakness.

On examination, the patient was afebrile, with painful and swollen left thigh and right arm, in the middle third of the inner side. The overlying skin was very red and felt warm. Muscle strength was preserved and deep tendon reflexes were symmetrical.

Blood investigations showed raised creatine-kinase (CK) of 511 U/L, C-reactive protein (CRP) of 7.3 mg/dL and erythrocyte sedimentation rate (ESR) of 80 mm/h with negative infection screen for HIV hepatitis B and C and *Borrelia*. The antinuclear antibodies, anti-JO1 anti-U1-RNP, anti-SRP anti-Mi-2, anti-SSa and anti-SSB were negative.

Plain X-ray of the humerus and femur showed soft tissues swelling and no bony lesion. A T2 –weighted MRI scan of the left thigh and right arm showed high

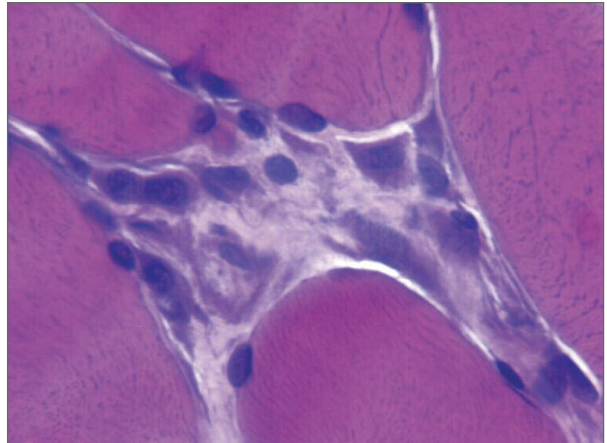


FIGURE 2. Fiber necrosis

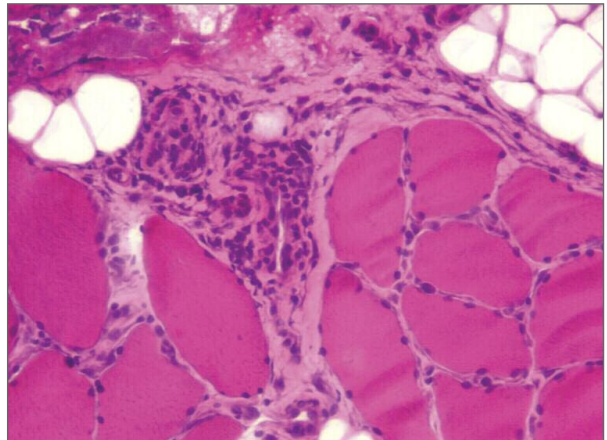


FIGURE 3. Alterations of muscle fibers with loss of striation, variation in fiber diameter and mononuclear infiltrate in the perivascular spaces.

signal intensity in the biceps short head, triceps lateral head, adductor magnus and adductor brevis suggestive of focal muscle inflammation (Figure 1).

Electromyography (EMG) of the upper and lower limb was performed, and all nerve conduction results were within normal ranges. Needle EMG in the right biceps short head, triceps lateral head, left adductor magnus and adductor brevis muscles revealed abnormal spontaneous activities and small amplitude motor unit action potentials.

We then performed a muscle biopsy under ultrasound guidance in the short head of the right biceps where the pathology was located. Neuropathology showed alterations of muscle fibers with loss of periodic striation, variation in fiber diameter, necrosis and lymphocytic infiltrate in the perivascular spaces, con-

firming inflammatory myositis (Figures 2 and 3). Infiltration of lymphocytes in vital, non necrotic muscle fibers, as typically seen in polymyositis, was not documented. The immunocytochemical studies with a panel of T- and B-cell markers showed that the cellular infiltrate was mainly composed by T-lymphocytes and variable numbers of macrophages. Expression of MHC class 1 and 2 antigens was only detected in occasional positive inflammatory cells.

After one month of non-steroidal anti-inflammatory medication (diclofenac 50 mg TDS) and a low dose of corticosteroids (prednisolone 20mg/day), the symptoms settled down. Twelve months after discharge, the patient was symptoms-free with no evidence of focal myositis.

DISCUSSION

Focal myositis is a rare, benign inflammatory pseudotumor of skeletal muscle presenting as localized, painful swelling within the soft tissues. First described in 1977 by Heffner *et al*, it must be differentiated from neoplasms, particularly soft-tissue sarcomas, infection, ischaemia, trauma and vasculitis^{1,2}.

Focal myositis typically occurs in the skeletal muscles of the lower extremities, but other locations including the head and neck region have been reported in the literature. It rarely occurs in the upper limbs, and only two cases were previously reported³.

MRI scan remains the best imaging modality for localized muscle inflammation.

EMG cannot be used to make a diagnosis of myositis. It may suggest a myopathic process and it can be very useful in differentiating neuropathic from myopathic conditions, but a myositis diagnosis cannot be made based on an EMG. Biopsy is the gold-standard to make a diagnosis of myositis^{4,5}.

Although this patient presented with a typical case of focal myositis, we highlight in this case report the involvement of muscles in the upper limb in two different occasions and the involvement of more than one muscle. We reinforce the need of an early diagnosis, since the diagnosis in this patient was made 6 years after symptoms onset. The reasons for this delay were the lack of recognition of this disease and a mistake in the result of the initial biopsy, which suggested myositis ossificans. Myositis ossificans is a disease whose main feature is the formation of heterotopic bone involving muscle or any other soft tissue. Its pathogene-

sis is not totally clear, but trauma is universally recognized as a triggering event in this setting. Myositis ossificans can be divided into two subgroups, myositis ossificans progressive and myositis ossificans traumatica⁶.

It was unlikely that this case had a diagnosis of myositis ossificans since no traumatic events were reported, symptoms resolved spontaneously and the patient had a complete remission.

Opposite to tumors, focal myositis appears not to invade the fascia, tendons, or adjacent skin². In this case, the MRI did not show involvement of these structures, decreasing the likelihood of a tumour.

The absence of significant systemic manifestations, including fever, weight loss and general muscle weakness also supported the exclusion of infections as well as the possibility of polymyositis. However, focal lesions may progress to a more generalized polymyositis and some authors feel that focal lesions should not be seen as separate entity, but as part of the spectrum of a single disease.

In focal myositis can be differentiated from polymyositis, because in the former lymphocytes never attack vital muscle fibres. Moreover, polymyositis characteristically involves more than one muscle^{3,7}. The presence of inflammatory features and the absence of features specific of other myositis suggest the diagnosis of focal myositis.

Lesions likely to progress to a more generalized polymyositis are associated with the involvement of more than one muscle/sites, early rise in ESR, CPR or CK and early recurrence after the first episode^{7,8}.

Patients with focal myositis should, therefore, be reviewed to ensure that progression to a less benign disease is diagnosed and treated early⁸.

In the present case, the likelihood of progression to polymyositis is high, because it has more than one muscle region involved and has increased ESR, CPR and CK. However, so far no systemic syndrome was observed no progression was detected during 12 months of follow-up. Nonetheless, in the future, long-term follow-up for the possible development of polymyositis may be required.

CORRESPONDENCE TO

Filipa Daniela Dias Teixeira

Serviço de Reumatologia do Hospital de Ponte de Lima, Unidade

Local de Saúde do Alto Minho. Largo Conde de Bertiandos

4990-041 - Ponte de Lima

E-mail: filipadteixeira@gmail.com

REFERENCES

1. Kisielinski K, Miltner O, Sellhaus B, Kru`ger S, Goost H, Siebert CH. Recurrent focal myositis of the peroneal muscles. *Rheumatology* 2002; 41:1318–1322.
2. Heffner RR, Armbrustmacher VW, Earle KM. Focal myositis. *Cancer* 1977; 40:301–306.
3. Auerbach A, Fanburg-Smith JC, Wang G, Rushing EJ. Focal myositis: a clinicopathologic study of 115 cases of an intramuscular mass-like reactive process. *Am J Surg Pathol* 2009; 33:1016–1024.
4. Nair J.R; Nijjar M, Chiphang A, Binymin K A. Ultrasound-guided closed muscle biopsy: a useful tool for rheumatologists. *Rheumatol Int* 2009; 11:2228-2229.
5. Smith AG, Urbanits S, Blaivas M, Grisold W, Russel JW. Clinical and pathologic features of focal myositis. *Muscle Nerve* 2000; 23:1569–1575.
6. Sirvanci M, Ganiyusufoglu AK, Karaman K, Tezer M, Hamzaoglu A. Myositis ossificans of psoas muscle: magnetic resonance imaging findings. *Acta Radiol* 2004; 45:523-525.
7. Garcia-Consuegra J, Morales C, Gonzalez J, Merino R. Relapsing focal myositis: a case report. *Clin Exp Rheumatol* 1995; 13: 395-397.
8. Maynie M, Robert H, Eloit S, Arnal C, Dolet C. Focal myositis in children. Apropos of a case. *Rev Chir Orthop Reparatrice Appar Mot* 1997; 83: 382-386.

XXII JORNADAS INTERNACIONAIS DO INSTITUTO PORTUGUÊS DE REUMATOLOGIA

Lisboa, Portugal
27 a 28 de Novembro de 2014