
Asymmetric Elevation of the Eyes

João Nascimento, MD¹, and Fátima Pinto, MD¹

¹Universidade do Porto, Porto, Portugal / Centro Hospitalar Porto

Corresponding Author:

João Nascimento, Rua da Igreja nº 93, Lamações, Braga 4710-085, Portugal.
Email: nascimentojoao10744@gmail.com

Publicado em : Clinical Pediatrics, 2014, Vol. 53(9), 911-913.

DOI: 10.1177/0009922814533415

Case Presentation

A 26-month-old girl presented with a transient head-posturing to the left that the mother reported since early months. She had a normal growth and psychomotor development, and her parents reported a notion of good vision. The mother denied pain complaints, previous traumatic events, or systemic diseases. Her family history is unremarkable for any history of ophthalmologic problems.

On ophthalmologic examination, head-posturing was evident, chin up and a face turn to the left side when asked to look at a symbol of the LEA Vision Chart Test (Figure 1). In the primary position, a minimal right hypotropia was present, and during ocular motricity examination, a limited elevation in adduction of the right eye was present (Figure 2). An audible but painless superior nasal click was elicited, on ocular rotations up and nasalward. The children had a 10/20 visual acuity of both eyes but had a bad performance during the evaluation of stereoscopic vision, with Lang Test 2. Laboratory exams, which included screening for systemic lupus and juvenile rheumatoid arthritis, were normal. Orbit high-resolution magnetic resonance imaging did not detect any muscular atrophies, signs of inflammation, or orbital tumors.

Final Diagnosis

Congenital Brown syndrome.

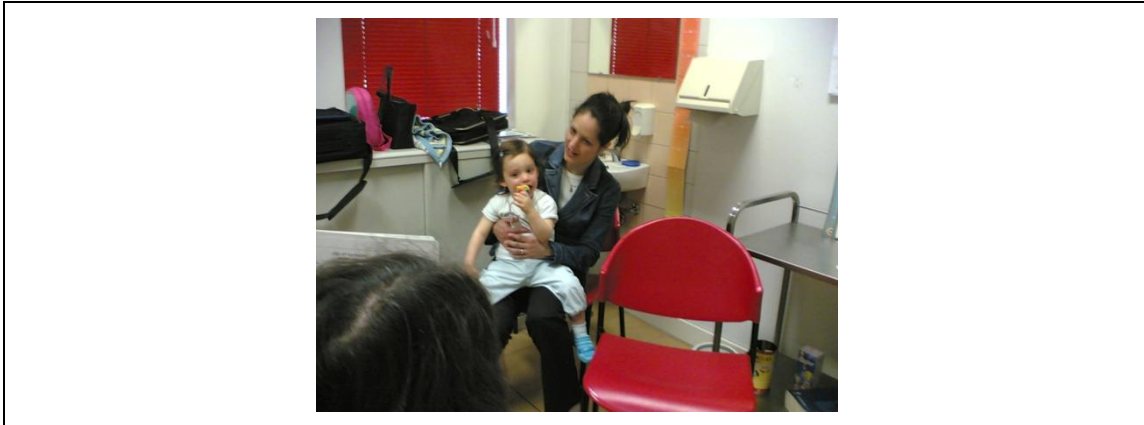


Figure 1. Compensatory head-posturing with contralateral face turn.

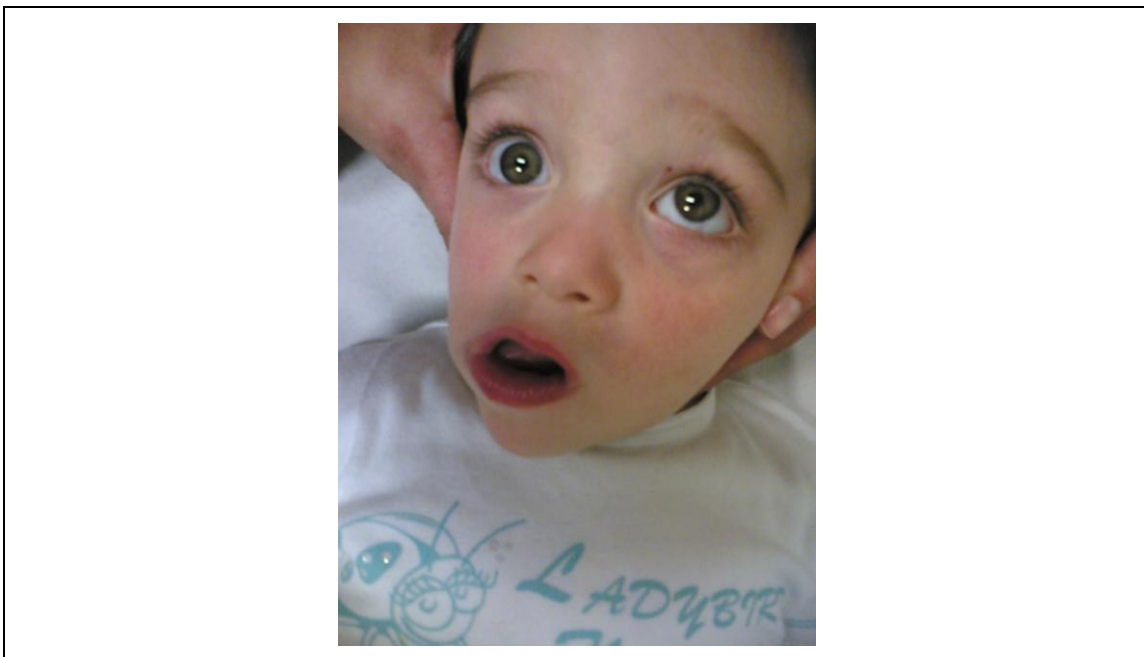


Figure 2. Limited right eye elevation in adduction.

Discussion

Over the past 3 decades, many congenital ocular motility disorders that were formerly considered to result from primary abnormalities of extraocular muscle or orbital tissue development seem to result from innervation disorders of these structures or abnormal neuronal development.¹⁻⁴ Absent or deficient innervation results in extraocular muscle hypoplasia and fibrosis causing limitation and restriction of ocular rotations. Another problem is that neuronal misinnervation frequently develops and induces distinctive combinations of synkinetic eye movements.^{3,4}

In 2003, Gutowski et al assigned the term *congenital cranial dysinnervation disorders* (CCDDs) to the conditions that share common features of dysinnervation to the ocular and facial musculature.⁴ In clinical practice, sometimes, it is difficult to achieve a correct diagnosis of these disorders, because a conserved partial innervation of the muscles persists or an anomalous paradoxical one exists, resulting in different combinations of involuntary eye

movements.⁴⁻⁶ In addition, it is also important to consider that a muscular palsy of one of these muscles leads to a hyperaction of the homolateral antagonist.⁶

In this case, the affected muscle is the right superior oblique muscle that is innervated by the fourth cranial nerve and ends in a tendon that passes through a fibrous loop, named trochlea, located anteriorly on the medial aspect of the orbit.⁷ The body of the superior oblique muscle is located behind the eyeball but the tendon approaches the eyeball from the front and attaches to its superior aspect.⁷ Muscle contraction pulls the tendon and a forward component tends to pull the eyeball downward (depression) and a medial component tends to rotate the top of the eyeball toward the nose (intorsion).⁷ The relative strength of these 2 forces depends on which way the eye is looking. When the eye is in primary position, contraction of the superior oblique muscle produces depression and intorsion in roughly equal amounts, but when the eye is adducted the force of depression is bigger and the opposite occurs when the eye is abducted with increasing force of intorsion.^{7,8}

The girl has an obvious limited active and passive elevation of the right eye, which is maximal in adduction. This elevation of the eye in adduction is possible due to contraction of the inferior oblique muscle and concomitant relaxation of homolateral superior oblique muscle.

Since inflammatory and traumatic events were excluded, the differential diagnoses were between congenital fourth nerve palsy, also known as superior oblique muscle palsy, and congenital Brown syndrome.

The distinction between the 2 entities is difficult, since they represent 2 interrelated CCDDs.⁸

Congenital fourth nerve palsy probably comprises a number of different etiologies that primarily include neurogenic cases with congenital absence of the trochlear nerve or anomalous innervation that leads to secondary hypoplasia or atrophy of the superior oblique muscle with laxity or aplasia of its tendon.^{5,6,8} In clinical practice, this situation is particularly common due to the small size of the fourth cranial nerve and long anatomical course.⁸

Congenital Brown syndrome has long been attributed to structural abnormalities of the superior oblique muscle, tendon, or trochlea, which can explain the restricted elevation in adduction on forced duction test.⁸ An innervational etiology for some cases of congenital Brown syndrome is now also supported since some electromyographic studies revealed paradoxical innervation of superior oblique muscle in some patients with absence of trochlear nerve but non hypoplastic or atrophic superior oblique muscle.^{8,9} The size of the muscle remained constant during vertical eye movements, suggesting no relaxation of it in upgaze. This finding can be explained by the existence of anomalous innervation of the superior oblique muscle by fibers of the third cranial nerve intended either for the medial rectus or inferior oblique muscle.⁸ Co-contraction of the superior oblique, medial rectus, or inferior oblique muscles can explain the findings seen in some patients with Brown syndrome.^{4,6,8}

The electromyographic exam performed in our patient did not detect existence of paradoxical innervation. This and the complete spontaneous resolution that occurred in our patient after a 3-year follow-up lead us to the final diagnosis of congenital Brown syndrome related to primary structural abnormalities of the complex superior oblique muscle–tendon–trochlea.

The spontaneous improvement could be related either to natural growth or to the compensatory repetitive elevation of the eye induced by the contraction of the superior rectus muscle.⁸⁻¹⁰ Otherwise, a dysinnervational Brown syndrome would be expected to persist throughout life.

However, many intriguing questions remain about the pathogenesis of CCDDs, and the adherence to a structural etiology for some of these cases may only be due to the incomplete elucidation of their neurodevelopmental etiology.⁸⁻¹⁰

Declaration of Conflicting Interests

The author(s) declared no potential conflicts of interest with respect to the research, authorship, and/or publication of this article.

Funding

The author(s) received no financial support for the research, authorship, and/or publication of this article.

References

1. Helveston EM, Krach D, Plager DA, Ellis FD. A new classification of superior oblique palsy based on congenital variations in the tendon. *Ophthalmology*. 1992;99:1609-1615.
2. Wright KW. Brown's syndrome: diagnosis and management. *Trans Am Ophthalmol Soc*. 1999;97:1023-1109.
3. Traboulsi EI. Congenital abnormalities of cranial nerve development: overview, molecular mechanisms, and further evidence of heterogeneity and complexity of syndromes with congenital limitation of eye movements. *Trans Am Ophthalmol Soc*. 2004;102:373-389.
4. Gutowski NJ, Bosley TM, Engle EC. 110th ENMC International Workshop: the congenital cranial dysinnervation disorders (CCDDs). Naarden, The Netherlands, 25-27 October, 2002. *Neuromuscul Disord*. 2003;13:573-578.
5. Oystreck DT, Engle EC, Bosley TM. Recent progress in understanding congenital cranial dysinnervation disorders. *J Neuroophthalmol*. 2011;31:69-77.
6. Brodsky MC. Ocular motor nerve palsies in children. In: *Pediatric Neuro-Ophthalmology*. 2nd ed. New York, NY: Springer; 2010:253-308.
7. Sevel D. The origins and insertions of the extraocular muscles: development, histologic features, and clinical significance. *Trans Am Ophthalmol Strabismus*. 1981;18:26-31.
8. Kaeser PF, Brodsky MC. Fourth cranial nerve palsy and Brown syndrome: two interrelated congenital cranial dysinnervation disorders? *Curr Neurol Neurosci Rep*. 2013;13:352.
9. Kaeser PF, Kress B, Rohde S, Kolling G. Absence of the fourth cranial nerve in congenital Brown syndrome. *Acta Ophthalmol*. 2012;90:e310-e313.
10. Dawson E, Barry J, Lee J. Spontaneous resolutions in patients with congenital Brown syndrome. *J AAPOS*. 2012;16:558-564.