

Drug package as a cause of gastric outlet obstruction

A 42-year-old man – a former drug addict with human immunodeficiency virus (HIV) infection and hepatitis C virus hepatic cirrhosis Child–Pugh B – reported voluntary intake of a packet of hashish for concealment 3 years earlier while he was detained in prison. He was asymptomatic until 4 months before presentation, when he began complaining of halitosis, belching, bloating, nausea and food vomiting which relieved the symptoms. These episodes were sporadic, but with increasing frequency in recent weeks. Four days before admission, vomiting became more intense and the patient complained of a single episode of hematemesis. At hospital admission he was hemodynamically stable, without ascites or peritoneal signs. Upper gastrointestinal endoscopy revealed small esophageal varices and severe portal hypertensive gastropathy, assumed as the cause of bleeding. It detected the presence of a gastric foreign body of about 10 cm with a hard consistency (● Fig. 1). Upper gastrointestinal endoscopy was repeated under sedation on

the following day, during which the foreign body was removed without complications (● Fig. 2). During hospitalization, the patient remained hemodynamically stable, without blood loss. He was asymptomatic when discharged.

Endoscopic removal of drug packages is not recommended except when only one packet fails to pass the pylorus. Hashish overdose causes depression of consciousness that isn't generally life threatening, unlike overdose of heroin or cocaine [1–3]. In this case, we assumed that the package was causing obstructive symptoms, that its spontaneous progression would be unlikely, that the surgical risk would be high, and that a possible overdose would not threaten the patient's life, and we therefore decided to perform its endoscopic removal.

Endoscopy_UCTN_Code_TTT_1AO_2AL

Competing interests: None

R. Küttner Magalhães, T. Moreira, R. Pimentel, C. Caetano, I. Pedroto

Department of Gastroenterology, Hospital Santo António, Porto, Portugal

References

- 1 American Society for Gastrointestinal Endoscopy. Management of ingested foreign bodies and food impactions. *Gastrointest Endosc* 2011; 73: 1085–1091
- 2 Traub S, Hoffman RS, Nelson LS. Body packing – the internal concealment of illicit drugs. *N Engl J Med* 2003; 349; 26: 2519–2526
- 3 Cotton P, Williams C. Therapeutic upper endoscopy. In: *Practical gastrointestinal endoscopy: the fundamentals*. 6th edn. Wiley–Blackwell; 2008: 61–86

Bibliography

DOI <http://dx.doi.org/10.1055/s-0031-1291696>
Endoscopy 2012; 44: E421
 © Georg Thieme Verlag KG
 Stuttgart · New York
 ISSN 0013-726X

Corresponding author

R. Küttner Magalhães, MD
 Department of Gastroenterology
 Hospital Santo António
 59 Rua Dr Eduardo Santos Silva
 4200-282 Porto
 Portugal
 Fax: +351-22-3320318
 rkuttner@gmail.com

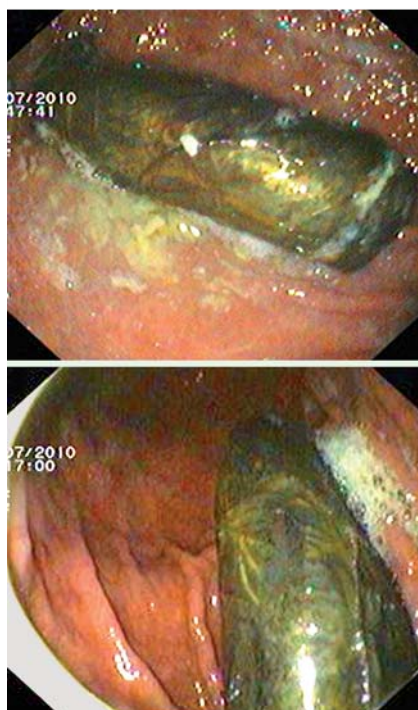


Fig. 1 Endoscopic images of the foreign body.



Fig. 2 Packet of hashish after removal.