

Langerhans cell histiocytosis: Two clinical presentations in the same patient

Ana Oliveira MD, Teresa Pinto de Almeida MD, Inês Lobo MD, Susana Machado MD, Manuela Selores MD

Dermatology Online Journal 18 (1): 8

Hospital de Santo António, Centro Hospitalar do Porto, Porto, Portugal

Abstract

Langerhans cell histiocytosis (LCH) is a heterogeneous group of diseases characterized by a pathological proliferation of cells phenotypically similar to Langerhans cells. The disease course is variable, alternating between resolving and potentially fatal forms. The diagnosis is based on clinical appearance and confirmed by CD1a positivity and / or immunohistochemistry. We report the case of a male child of 3 months with two different presentations of Langerhans cell-histiocytosis (LCH) at different times. The first presentation was classified as a self-healing LCH (formerly known as Hashimoto-Pritzker). The last presentation, although clinically suggestive of Letterer-Siwe (former designation), was not associated with systemic disease. This emphasizes that LCH cannot be compartmentalized into four groups, but considered a single disease with a wide spectrum of clinical presentations. This case underscores the importance of frequent and long-term follow-up of these patients.

Introduction

Langerhans cell histiocytosis (LCH) is a heterogeneous group of diseases characterized by the proliferation of pathological cells phenotypically similar to Langerhans cells [1]. It is a rare disease, with an annual incidence of 4 cases per million in children [2].

Langerhans cell histiocytosis is a multisystemic disease with an unpredictable and variable course, that encompasses a spectrum of self-healing and potentially fatal forms. These diseases were formerly known as histiocytosis X, which comprised four well defined entities (a self-healing congenital disease named Hashimoto-Pritzker; a multifocal form with diabetes insipidus, exophthalmos and bony defects called Hand-Schüller-Christian; Letterer-Siwe, the most severe form of LCH, presenting clinically as intertriginous involvement; and eosinophilic granuloma, a unifocal form). Histiocytosis X was reclassified into Langerhans cell histiocytosis, a single entity with a wide clinical spectrum [3]. The diagnosis is based on clinical features and confirmed by positivity for CD1a, confirmatory immunohistochemistry, or by the presence of Birbeck granules on electron microscopy [1]. The prognosis is related to the age at onset, the progression of disease, and the presence of systemic involvement. Organ dysfunction (liver, bone marrow, lungs) occurs in 15 percent of HCL and is the most important factor leading to a poor prognosis [4].

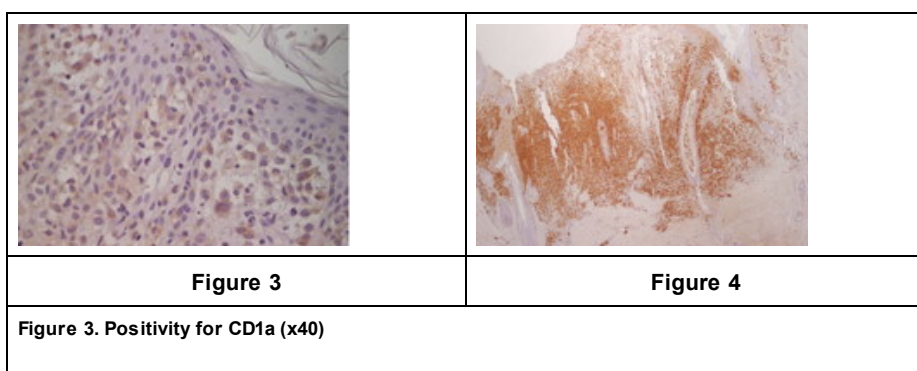
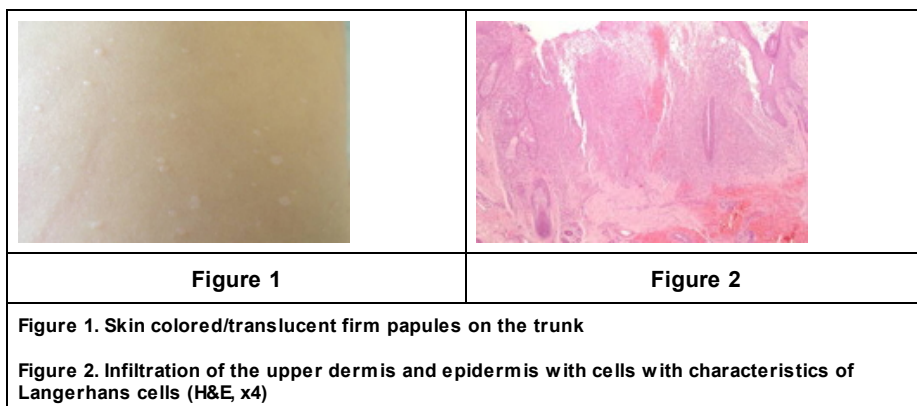
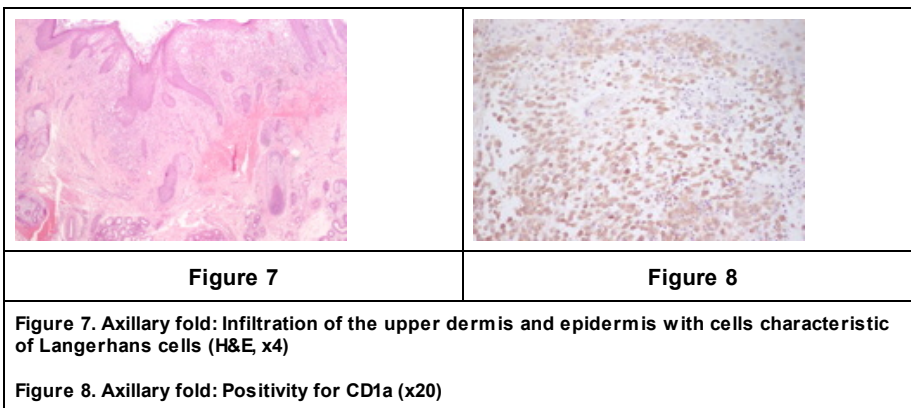
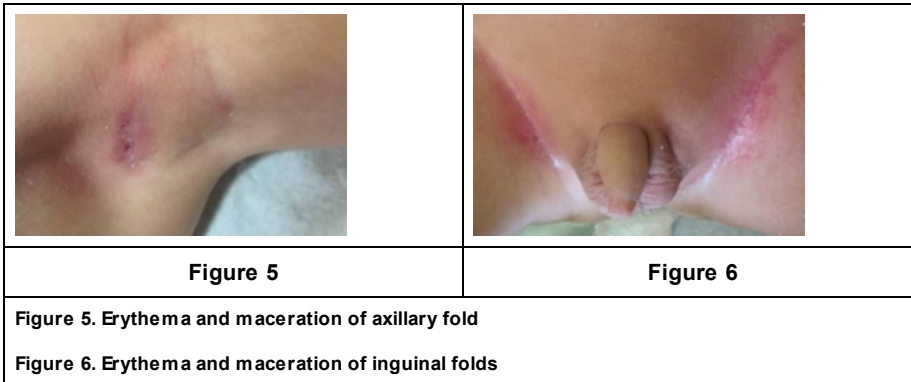


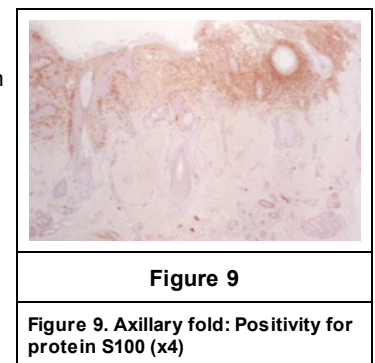
Figure 4. Positivity for protein S100 (x4)

A 2-month-old male was observed in our department because of a 3-week-history of asymptomatic papules on the trunk. On physical examination, skin colored/translucent, firm papules on the trunk were noted (Figure 1). The remaining physical examination was normal. There was no history of failure to thrive, fever, or vomiting and there was no palpable lymphadenopathy or hepatosplenomegaly.

A skin biopsy revealed an infiltration of the upper dermis and epidermis with cells characteristic of Langerhans cells (Figure 2) and positive for CD1a (Figure 3) and S-100 protein (Figure 4).



The lesions regressed spontaneously in two months, leading to the diagnosis of self-healing histiocytosis (formerly known as Hashimoto-Pritzker). However, three months later, he developed erythema and maceration of both axillary (Figure 5) and inguinal folds (Figure 6). The second skin biopsy showed the same features as the first one, compatible with Langerhans cell histiocytosis (Figures 7, 8, and 9). A complete workup, including full blood count, chemistry profile, chest and skeleton X-ray was performed, showing no involvement of other organs beyond the skin. Laboratory and radiographic studies have been performed every 6 months. Now, 14 months later, the child exhibits the same skin lesions without any signs of disease progression or systemic involvement.



Discussion

Langerhans cell histiocytosis is a rare proliferative disorder of unknown etiology. An ongoing debate exists over whether LCH is a reactive or a neoplastic process [5]. This entity was described in 1953 and was called histiocytosis X, reflecting its unknown cause. It was reclassified in 1985 by the working group of the Histiocyte Society and the term, histiocytosis X, was replaced by Langerhans cell histiocytosis, which is now the preferred terminology of any disorder caused by proliferation of Langerhans cells [6]. Clinically, LCH is a polymorphic disease that can affect one or several organs. The clinical spectrum is broad and depends on the location and extent of the disease.

Our patient's initial cutaneous findings resolved spontaneously over a few weeks and on the basis of this initial presentation he was diagnosed with probable self-healing histiocytosis. Although the lesions of the disease formerly named Hashimoto-Pritzker are typically reddish-brown and distributed mainly on the face, we believe that our patient's presentation corresponds to this entity, taking into account the onset soon after birth and the spontaneous resolution. We do not consider the first presentation as a form fruste of Letterer-Siwe, because of the already mentioned self-resolution and the non-typical, non-seborrheic distributed lesions, as would be expected in this subtype of Langerhans cell histiocytosis.

The reappearance of the skin lesions in an intertriginous distribution could fit with Letterer-Siwe type of LCH, but our patient has continued to be without systemic involvement. This emphasizes that LCH cannot be compartmentalized into four groups, but must be considered a single disease to have a wide spectrum of clinical presentations. This case underscores the importance of frequent and

long-term follow-up of these patients.

References

1. Satter EK, High WA. Langerhans cell histiocytosis: a review of the current recommendations of the Histiocyte Society. *Pediatr Dermatol* 2008;25(3):291-5. [**PubMed**]
2. Salotti JA, Nanduri V, Pearce MS, Parker L, Lynn R, Windebank KP. Incidence and clinical features of Langerhans cell histiocytosis in the UK and Ireland. *Arch Dis Child* 2009;94(5):376-80. [**PubMed**]
3. Nezelof C, Basset F. Langerhans cell histiocytosis research: past, present, and future. *Hematol Oncol Clin North Am* 1998;12(2):385-406. [**PubMed**]
4. Braier J, Chantada G, Rosso D, Bernaldez P, Amaral D, Latella A, Balancini B, Masautis A, Goldberg J. Langerhans cell histiocytosis: retrospective evaluation of 123 patients at a single institution. *Pediatr Hematol Oncol* 1999;16(5):377-85. [**PubMed**]
5. Degar BA, Rollins BJ. Langerhans cell histiocytosis: malignancy or inflammatory disorder doing a great job of imitating one? *Dis Model Mech* 2009;2(9-10):436-9. [**PubMed**]
6. Histiocytosis syndromes in children. Writing Group of the Histiocyte Society. *Lancet* 1987;24;1(8526):208-9. [**PubMed**]

© 2012 Dermatology Online Journal