

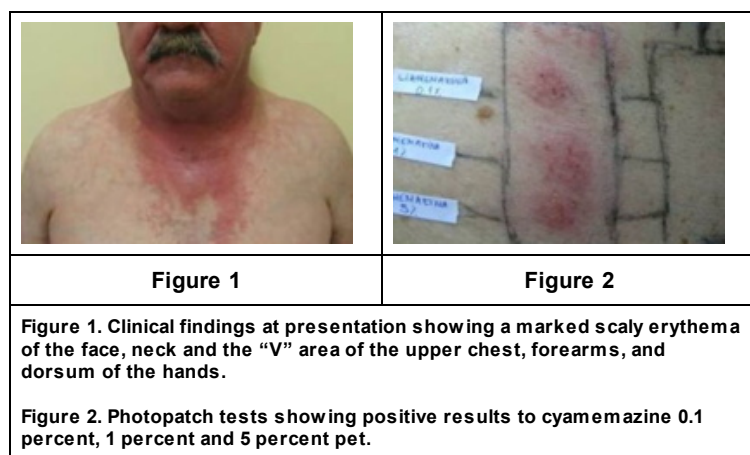
Photoallergic reaction to cyamemazine

Iolanda Conde Fernandes, Susana Vilaça, Inês Lobo, Madalena Sanches, Virgílio Costa, Manuela Selores
Dermatology Online Journal 19 (2): 15

Dermatology Department, Centro Hospitalar do Porto, EPE - Hospital de Santo António (CHP-HSA), Porto, Portugal

Abstract

A 50-year-old man presented with a scaly erythema of the face, upper chest, forearms, and dorsum of the hands. He has been treated with cyamemazine for 6 months. Photopatch tests were performed and the patient was diagnosed with photoallergic reaction to cyamemazine. The drug was discontinued and a course of oral steroids was prescribed. The patient was advised to avoid light exposure. There has been no evidence of recurrence during a six-month follow-up period. Photoallergic reactions are much less frequent than phototoxic disorders. It is well known that several drugs including neuroleptics of the phenothiazine family may produce a skin eruption on light-exposed areas by dose-dependent (phototoxic) or photoallergic mechanisms. It is believed that photopatch testing, which is the clinical investigation of choice for suspected photoallergic reactions, is significantly underused in Europe and probably world-wide.



thema of the face, neck and the "V" area of unk were also affected. The patient complained of intense pruritus and the clinical picture started 4 months prior to presentation.

The patient had been treated with cyamemazine 120 mg/day, risperidone 4 mg/day, and alprazolam 2 mg/day for 6 months because of his condition of alcohol withdrawal.

The skin biopsy performed on the dorsum of his right hand showed the presence of irregular acanthosis of the epidermis, parakeratotic hyperkeratosis, spongiosis, and exocytosis of inflammatory cells. In the upper dermis the presence of an inflammatory infiltrate with abundant eosinophils was evident. Based on the clinical and histological findings we have hypothesized the diagnosis of a photoallergic reaction to cyamemazine.

Photopatch testing with the drug (Tercian[®], oral drops, Vitória Laboratories, Lisbon, Portugal) "as is" was positive (+++).

The patient also showed positive photopatch tests (+++) to cyamemazine tested at 0.1 percent, 1 percent and 5 percent petrolatum (pet.). Patch tests using the Portuguese standard series and photopatch tests with a photoallergen series that included phenothiazines (promethazine 0.1% pet. and chlorpromazine 0.1% pet.) were also performed. All tests from these two were negative.

According to the results, the patient was diagnosed with photoallergic reaction to cyamemazine. The drug was discontinued and a course of oral steroids (prednisolone 40 mg daily) was prescribed. The patient was advised to avoid light exposure. The skin lesions improved within a few weeks and the dosage of Prednisolone was slowly tapered and then stopped without recurrence of the eruption.

There has been no evidence of recurrence during a six month follow-up period.

Cutaneous photosensitivity diseases may be produced by exogenous agents (drug-induced photosensitivity). It is well known that several drugs including neuroleptics of the phenothiazine family may produce a skin eruption on light-exposed areas by dose-dependent (phototoxic) or photoallergic mechanisms. Cyamemazine belongs to this class of drugs and is still commonly

prescribed by practitioners in several European countries. Photoallergic reactions to cyamemazine have been rarely described and only one case has been reported in the literature [1].

Photoallergic reactions are believed to be a special type of cell-mediated hypersensitivity in which radiant energy is required to produce a photoantigen [2]. The predominant pattern in photoallergic reactions is eczematous (acute, subacute or chronic). It is usually confined to exposed sites but may extend to other areas. Although pigmentary changes as a consequence of photoallergic reactions are rare, they have been described in association with some drugs [3]. Usually the skin returns to normal after discontinuation of the offending agent but in some cases a persistent light reaction (PLR) may develop, as previously reported [4, 5, 6]. In our case the patient did not develop PLR. Histopathologic features of photoallergic reactions include epidermal spongiosis, exocytosis, and dermal mononuclear cell infiltrate similar to that seen in delayed cell-mediated hypersensitivity response in general [7].

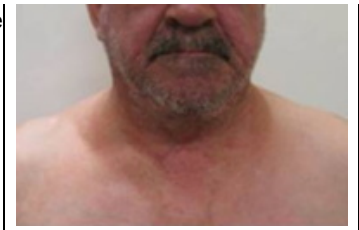


Figure 3

Figure 3. Clinical features after cyamemazine discontinuation

On the other hand, phototoxic disorders are much more common than photoallergic reactions and theoretically they can occur in any individual who receives enough concomitant drug and ultraviolet radiation. There is no requirement for immunization and it occurs promptly after exposure to photosensitizer and light. On physical examination the characteristic presentation resembles a sunburn on exposed skin only and there is no development of PLR. Photopatch testing is more valuable when a photoallergy is suspected and determination of the minimal erythema dose is a more useful test for the diagnosis of phototoxic reactions. Thus, the latter has not been performed. Photopatch tests were performed according to the recommendations of the European Task Force on photopatch testing [8]: 1. allergens in Finn Chambers® were applied in duplicate on the mid upper back skin for 24 h (after which both were removed); 2. one set was covered with an ultraviolet opaque material and the other was irradiated with a 5J/cm² ultraviolet A source. Readings were recorded using the International Contact Dermatitis Research Group (ICDRG) scoring system [8], pre-irradiation, immediately postirradiation, 24 h and 48 h after irradiation.

Photo-cross-sensitivity has been reported among phenothiazines. Barbaud et al reported cross-photoreactions between chlorpromazine and chlorproethazine in 5 patients [5]. This might be explained by the formation of a common photosensitizing metabolite. Therefore patients should be photopatch tested to other phenothiazines. In this case, photo-cross-sensitization was not observed either with promethazine (0.1% pet.) or with chlorpromazine (0.1% pet.).

It is believed that photopatch testing, which is the clinical investigation of choice for suspected photoallergic reactions, is significantly underused in Europe and probably world-wide. The primary indication for photopatch testing should be dermatitis predominantly affecting exposed sites and should also be considered in any individual with a photosensitive eruption for which there is no obvious diagnosis.

References

1. Conilleau V, Dompmartin A, Michel M, Verneuil L, Leroy D. Photoscratch testing in systemic drug-induced photosensitivity. *Photodermatol Photoimmunol Photomed*. 2000 Apr;16:62-6. [PubMed]
2. Gould JW, Mercurio MG, Elmetts CA. Cutaneous photosensitivity diseases induced by exogenous agents. *J Am Acad Dermatol* 1995 Oct;33:551-573. [PubMed]
3. Gonçalves S, Gil J, Gonçalves, Baptista AP. Pigmented photoallergic contact dermatitis from musk ambrette. *Contact Dermatitis* 1991 Mar;24:229-31. [PubMed]
4. Lim HW, Buchness MR, Ashinoff R, Soter NA. Chronic actinic dermatitis. Study of the spectrum of chronic photosensitivity in 12 patients. *Arch Dermatol*. 1990 Mar;126:317-23. [PubMed]
5. Barbaud A, Collet E, Martin S, Granel F, Trechot P, Lambert D, Schmutz JL. Contact sensitization to chlorproethazine can induce persistent light reaction and cross-photoreactions to other phenothiazines. *Contact dermatitis* 2001 Jun;44:373. [PubMed]
6. Jeanmougin M, Sigal-Nahum M, Manciet JR, Petit A, Flageul B, Dubertret L. Photosensibilité rémanente induite par la chlorproéthazine. *Ann Dermatol Venerol* 1993;120(11):840-843. [PubMed]
7. Epstein JH. Phototoxicity and Photoallergy. *Semin Cutan Med Surg* 1999 Dec;18:74-284. [PubMed]
8. Bruynzeel DP, Ferguson J, Andersen K, Gonçalves M, English J, Goossens A, Holzle E, Ibbotson SH, Lecha M, Lehmann P, Leonard F, Moseley H, Pigatto P, Tanew A; European Taskforce for Photopatch Testing. Photopatch testing: a consensus methodology for Europe. *J Eur Acad Dermatol Venerol*. 2004 Nov;18(6):679-82. [PubMed]