

## Leukemia cutis resembling a flare-up of psoriasis

Márcia Ferreira, Mónica Caetano, Isabel Amorim, and Manuela Selores  
 Dermatology Online Journal 12 (3): 13

Service of Dermatology, Hospital Geral de Santo António, Porto, Portugal. marcia\_ferreira@hotmail.com

### Abstract

Leukemia cutis represents a skin infiltration by leukemic cells. Clinically it can mimic a wide variety of dermatoses. We describe the case of a 64-year-old man with psoriasis who presented with a 4-day history of erythematous, slightly scaly, asymptomatic plaques distributed on the trunk and upper-extremities, and associated asthenia, myalgias, and anorexia. A skin biopsy revealed a leukemic infiltrate. Studies of peripheral blood and bone marrow provided a diagnosis of acute monocytic leukemia. This case report shows the importance of the clinical suspicion for the diagnosis of leukemia.

### Introduction

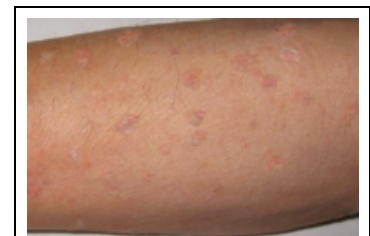Leukemia is a systemic hematologic malignancy primarily involving the bone marrow and peripheral blood. It can be divided into acute and chronic forms of either lymphoid or myeloid lineage. Leukemia may present a wide variety of cutaneous manifestations. These can be divided in specific lesions containing leukemic cells (leukemia cutis), and non-specific skin lesions, which occur much more frequently.

### Clinical synopsis

A 64-year-old man presented with a 4-day history of asthenia, myalgias, and anorexia. Simultaneously there was an appearance of multiple erythematous, slightly scaly, asymptomatic papules and plaques localized to the trunk and extremities, with progressive increase in number. The patient denied fever, pruritus, or weight loss.

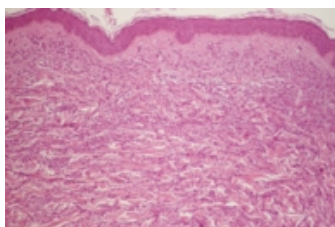
On physical examination there were multiple various sized, skin-colored to erythematous, psoriasis-like papules and plaques over the anterior trunk, abdominal wall and upper extremities (Fig. 1). The patient complained of tenderness on muscle palpation and had loss of muscular strength. There was no palpable lymph node enlargement, hepatosplenomegaly, or gingival hyperplasia.

Past medical history included psoriasis vulgaris since age 14, ischemic heart disease with myocardial infarction in 2001, and a bypass revascularization in 2003. He was medicated with amiodarone, furosemide, ticlopidine, and omeprazole.



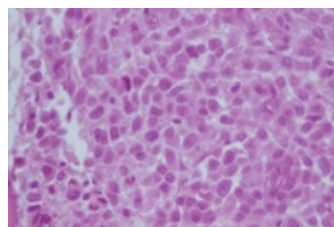
**Figure 1**

**Erythematous, slightly scaly papules and plaques on the forearm**



**Figure 2**

**Figure 2. Hematoxylin-eosin staining (× 2) showing a normal epidermis and a diffuse cellular infiltration involving the dermis and subcutis, arising between collagen bundles**



**Figure 3**

**Figure 3. Bone marrow biopsy (× 40) is hypercellular with monotonous cells that replace the normal marrow elements.**

Because of the clinical suspicion of a leukemic skin infiltrate, a punch biopsy was performed. Hematoxylin-eosin stained sections showed a diffuse infiltration involving the dermis and subcutis, with perivascular and periadnexal accentuation composed of monomorphous cells with homogeneous oval nuclei. The epidermis was not involved (Fig. 2). Immunoperoxidase studies of the

infiltrate showed strong staining with lysozyme. The patient was diagnosed as leukemia cutis, and further exams were performed. The erythrocyte sedimentation rate was 24 mm/h. A complete blood cell count revealed microcytic hypochromic anemia (hemoglobin: 11.9 g/dl), 5140 leukocytes/mm<sup>3</sup> with normal differentiation and a normal peripheral blood smear. Serum chemistry profile showed a lactic dehydrogenase (LDH) of 2792 U/l, with renal and hepatic values within normal ranges. Computed tomography demonstrated a homogeneous hepatosplenomegaly. Bone marrow aspiration and biopsy revealed hypercellularity with 79 percent blasts. The infiltrate was characterized by cells with a kidney-shaped or oval nucleoli, small nucleoli, homogeneous chromatin, and abundant, slightly-eosinophilic cytoplasm (Fig. 3). Immunohistochemical study was strongly positive for lysozyme, had some expression of CD68, and was negative for myeloperoxidase. A cytogenetic analysis revealed no chromosomal abnormalities.

He was diagnosed with acute myelogenous leukemia, French-American-British (FAB) classification M5a. The treatment consisted of a regimen of induction chemotherapy with cytarabine, daunorubicin, and cyclosporin. After 1 month, the results were disappointing—without remission of the disease. A palliative chemotherapy with hydroxyurea and 6-mercaptopurine was then administered. Death occurred 3 months after the first cutaneous symptoms.

## Discussion

Leukemia cutis is a specific lesion of leukemia in which malignant hematopoietic cells invade the skin. It is a rare manifestation with unknown incidence. The lesions usually appear at the time of diagnosis of systemic disease or thereafter, but occasionally can occur before peripheral blood or bone marrow involvement (aleukemic leukemia cutis) [1]. Nonspecific cutaneous lesions occur more often and should be differentiated from specific lesions.

The incidence of leukemia cutis varies depending on the type of leukemia. It is most frequently associated with acute myeloblastic leukemia, with higher incidences in the monocytic (AML5) [2, 3] and myelomonocytic (AML4) subtypes. The clinical appearance is variable with erythematous to violaceous papules or nodules being the most frequent lesions, followed by infiltrated plaques, to a generalized cutaneous eruption and erythroderma. They are frequently asymptomatic. Solitary lesions of AML may present as an ulcerating greenish tumor termed *chloroma*. Gingival hyperplasia is observed in 42 percent of AML5 and 55 percent of AML [4]. Leukemic cell infiltration of scratched wounds and scars of trauma has been reported [4].

Cutaneous histology usually shows a diffuse infiltration of the dermis and subcutis by leukemic cells, with variable changes between different types of leukemia, and even in different patients with the same type of leukemia [5]. Differentiation from inflammatory skin conditions may be challenging. The diagnosis depends in large part on the recognition of myeloblasts. In most cases, immunohistochemical study is necessary to characterize immunophenotype of tumor cells. Lysozyme is a sensitive marker of myeloid lineage. Detailed examination of the peripheral blood and bone marrow is crucial for the diagnosis of the specific type of leukemia, allowing a correct treatment of these patients. There are some gene abnormalities described associated with leukemia cutis, including numerical abnormalities of chromosome 8, translocation (8;21)(q22;q22), and inversion (16)(p13;q22) [6, 7].

Retrospective studies show that cutaneous involvement of leukemia is associated with poor long-term survival. Despite aggressive therapy, most patients die within a few months [8]. Leukemia cutis appears to be associated with a higher percentage of extramedullary leukemic involvement at other sites. Central nervous localization of acute monocytic leukemia occurs more frequently in patients with leukemia cutis (17 % versus 5-7 %) [9]. LDH seems to be higher in patients with leukemia cutis, and may be an additional sign of poor prognosis [6].

Current treatment involves chemotherapy. Radiotherapy is considered to be beneficial in widespread skin involvement; a high incidence of skin relapses suggest that the skin can act as a sanctuary for leukemic cells [9]. The use of whole-body electron-beam radiation seems to be a valuable alternative for conventional irradiation, avoiding systemic toxicity. The radiosensitizing properties of anthracyclines should be kept in mind when used prior to or in conjunction with electron-beam irradiation [10]. However, no effect was observed on bone marrow, therefore it should be used in association with chemotherapy [2]. For small skin lesions surgical removal or localized radiotherapy may be successful.

In conclusion, disseminated skin eruptions may be a sign of leukemia, even when the patient has a past history of cutaneous disease and the changes in peripheral blood are minimal. A clinical suspicion and the performance of a skin biopsy with immunochemistry might allow the early detection of underlying hematologic malignancy. This must be followed by a complete study for classification and staging of the disease, possibly improving chances for cure.

## References

1. Ohno S, Yokoo T, Ohta M, et al. Aleukemic leukemia cutis. *J Am Acad Dermatol* 22:374-7, 1990.
2. Baer MR, Barcos M, Farrel H, et al. Acute myelogenous leukemia with leukemia cutis. Eighteen cases seen between 1969 and 1986. *Cancer* 63:2192-200, 1989.
3. Ratman KV, Khor CJ, Su WP. Leukemia cutis. *Dermatol Clin* 12:419-431, 1994.
4. Koizumi H, Kumakiri M, Ishizuka M, et al. Leukemia cutis in acute myelomonocytic leukemia: infiltration to minor traumas and scars. *J Dermatol*. May;18(5):281-5, 1991.
5. Kaddu S, Zenahlik P, Beham-Schmid C, et al. Specific cutaneous infiltrates in patients with myelogenous leukemia: A clinicopathologic study of 26 patients with assessment of diagnostic criteria. *J Am Acad Dermatol* 40 (6, Suppl 1):966-978, 1999.
6. Agis H, Weltermann A, Fonatsch C, et al. A comparative study on demographic, haematological, and cytogenetic findings and prognosis in acute myeloid leukemia with and without leukemia cutis. *Ann Hematol*. Feb; 81 Suppl 2:90-5, 2002.
7. Kubonishi I, Seto M, Murata N, et al. Translocation (10;11) (p13;q13) and MLL rearrangement in a case of AML (M5a) with aggressive leukemia cutis. *Cancer Genet Cytogenet*. Jul; 104 Suppl 1:28-31, 1998.
8. Gambichler T, Herde M, Hoffman K, et al. Poor prognosis of acute myeloid leukemia associated with leukemia cutis. *J Eur Acad Dermatol Venereol* Mar; 16 (Suppl 2):177-8, 2002.

9. Zweegman S, Vermeer MH, Bekkink MW, et al. Leukemia cutis: clinical features and treatment strategies. *Haematologica* 87:(04) ECR13, 2002.

10. Solberg LA, Wick MR, Bruckman JE. Doxorubicin enhances skin reaction after whole body electron-beam irradiation for leukemia cutis. *Mayo Clinic Proc.* 55:711-5, 1980.

© 2006 Dermatology Online Journal