

A CASE OF LATE-DIAGNOSED OVOTESTICULAR DISORDER OF SEX DEVELOPMENT

Maria Knoblich¹, Vanda Pratas Vital¹, Dinorah Cardoso¹, Fátima Alves¹, Filipe Catela Mota¹, Lurdes Lopes²,
Teresa Kay³, Paolo Casella¹

¹Pediatric Surgery Department, Hospital de Dona Estefânia, Centro Hospitalar de Lisboa Central, Lisbon, Portugal

²Pediatric Endocrinology Department, Hospital de Dona Estefânia, Centro Hospitalar de Lisboa Central, Lisbon, Portugal

³Genetics Department, Hospital de Dona Estefânia, Centro Hospitalar de Lisboa Central, Lisbon, Portugal

Abstract

We report a case of ovotesticular disorder of sex development (DSD) with ambiguous genitalia, 46XX presenting the clinical, laboratory, imaging and operative findings and highlighting the pertinent features of this case. Results of hormonal, genetic testing and histopathology findings are reviewed. Diagnosis of true hermaphroditism is well defined and the condition can be recognized even prenatally. Conservative gonadal surgery is the procedure of choice after the diagnosis of true hermaphroditism, if the risk of a gonadal malignancy is low. Continued follow-up is necessary because of the multiple psychological, gynecological and urological problems encountered postpubertally by these patients.

Keywords: disorder of sex development, ovotestis, true hermaphroditism, disorder of sex development, ambiguous genitalia

Introduction

Disorders of sex development (DSD) are a group of sexual differentiation disorders resulting in genital anomalies with defects in gonadal hormone synthesis and/or incomplete genital development. These conditions result in issues concerning the sex assignment of the child.

Ovotesticular disorder of sex development (OT-DSD) is a rare disorder in which both ovarian and testicular tissues are present. Diagnosis is most frequently made in the early postnatal period, but can be delayed until puberty, or suspected before birth with improved prenatal imaging and knowledge.

Case report

We present a case of a female patient, 11 years old transferred to Hospital de Dona Estefânia in Lisbon from a regional hospital in Angola with ambiguous genitalia. At birth was assigned as female, an accurate diagnosis being delayed for many years in spite of ambiguous genitalia detected early in life. Prior history was unavailable.

On general examination, she was a normal statured phenotypic female with Tanner stage 1, no breast development and no pubic hair. Genitalia consisted of 7 cm phallic structure and labio-scrotal folds with non-palpable testes (Fig. 1).

Correspondence

Maria Knoblich
Hospital Dona Estefânia
Rua Jacinta Marto, 1169-045 Lisboa
Tel: +351916085745
E-mail: mknoblich@gmail.com

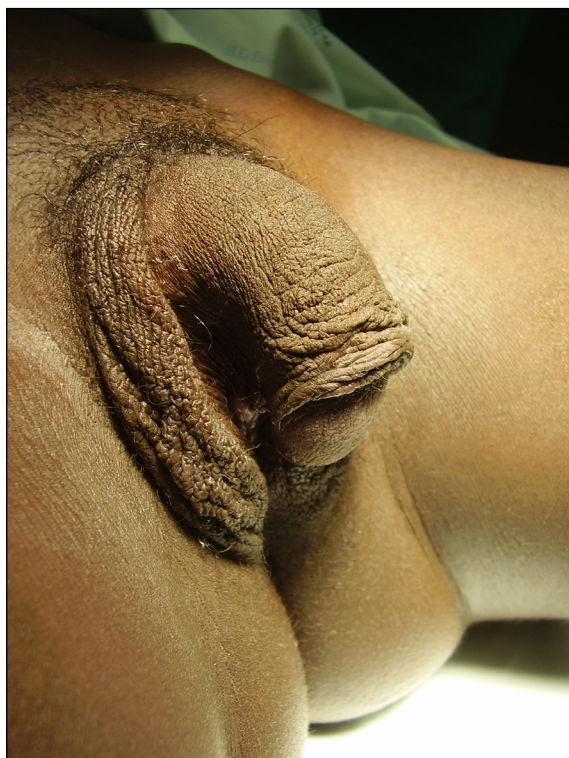

Figure 1: External genital organs aspect on physical exam

Karyotype analysis revealed 46,XX without SRY gene. The levels of follicle stimulating hormone 75,66mUI/ml (0,2-8mUI/ml), luteinizing hormone 19,19 mUI/ml (0,5-9mUI/ml) and estradiol 47pg/ml (0,3-20,6pg/ml) were abnormal. Levels of testosterone were 406,36 ng/dl for a normal value of 30ng/d.

Abdominal and pelvic ultrasound showed a small uterus pre-pubertalde 50x 13 x 10 mm with no endometrial development, and small ovaries with one or two milimetric follicular cysts.

On Magnetic Resonance Imaging, a small uterus 57 x 11 x 15 mm was identified, with regular thin endometrial tissue, small ovaries, and 2/3 of (superior e middle) vagina with normal morphology that ended near urethra suggesting urogenital sinus (Fig. 2).

Subsequently, she underwent cystoscopy, vaginoscopy and laparoscopy for evaluation of DSD.

Diagnostic laparoscopy demonstrated the presence of an intra-abdominal left testis and of a rudimentary right ovary, instead of the two ovaries identified in the MRI. A rudimentary uterus and a right fallopian tube were also identified. Biopsies were done.

Cystoscopy showed a normal urethra, normal bladder neck, with both ureters draining

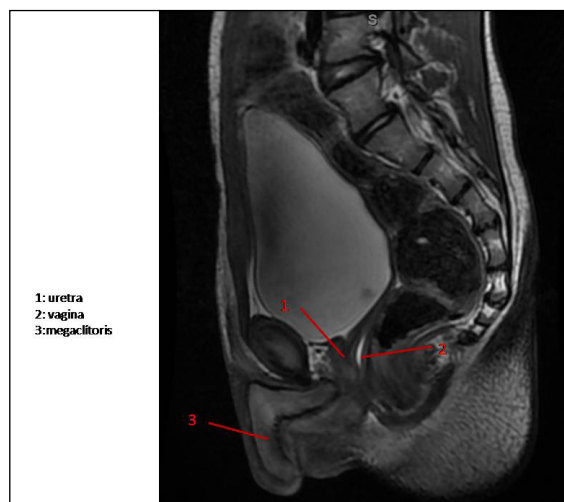


Figure 2: MRI image

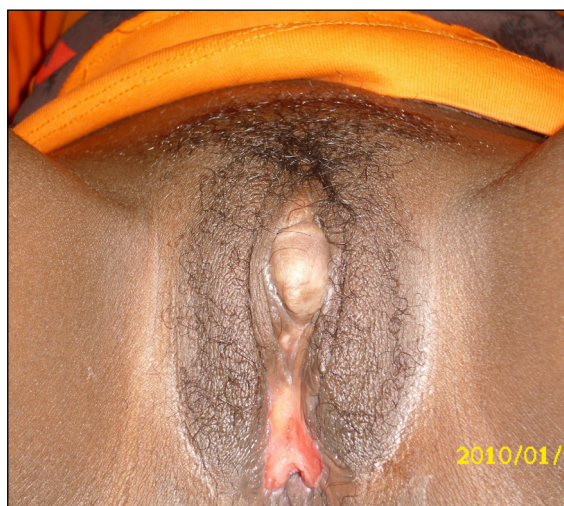

Figure 3: Postoperative external genitalia aspect

on the trigone. Vaginoscopy revealed a vaginal orifice very closed to the urethra, vaginal length seemed to correspond to the MRI.

Histological analysis confirmed normal parenchima on both the left testis and ovary. Karyotype and histological analysis confirmed that she had ovotesticular DSD.

Psychiatric evaluation revealed no gender identity disorder, hence it was decided that the patient would be continued to be raised as a female.

One month later laparoscopic orhidectomy was performed and feminizing genitoplasty was done (monsplasty, clitoroplasty and vaginoplasty). There were no postoperative complications.

At 12 year of age she required hormonal replacement and vaginal dilations (Fig. 3). Patient appears healthy on follow-up after 2 years.

Discussion

OT-DSD replaced the term "true hermaphrodite" in 2006[1]. It constitutes between 3 and 10% of the total DSD and presents significant diagnostic and management challenges [2,3].

Epidemiologically, the geographical distribution of OT-DSD shows a higher prevalence in the African continent, especially among South African blacks, with the number of published cases being 17 per 100 million people [4].

Typically, both Mullerian and Wolffian duct derivatives are seen, and most affected individuals present with ambiguous external genitalia as neonates or infants.

The phenotype covers the entire spectrum, with ambiguity and asymmetry being the rule, but with a tendency toward masculinization. Fertility has been described in those raised as female, but testicular fibrosis makes this unlikely in those raised as male.

The ovotestis is usually the most common gonad in individuals with OT-DSD, followed by ovaries and testis.

It can be associated with a variety of karyotypes, approximately 60% of children with ovotesticular DSD have a 46, XX karyotype; 33% are mosaics with a second cell line containing a chromosome (46, XX/46, XY; 46, XX/46, XXY), and 7% are 46, XY [5,6].

The diagnosis of ovotesticular DSD is suggested by a mosaic karyotype or ductal structures, but is confirmed by the presence of ovarian and testicular tissue by biopsy.

Gender assignment is done based on the functional potential of genitalia and gonads

and the gender identity of the patient. All contradictory gonadal tissue is removed early by surgical exploration. A 1% to 10% incidence of testicular tumor development is found in males, predominantly gonadoblastomas and dysgerminomas, so long-term surveillance is needed [7].

Retained testicular tissue will cause virilization in the females. In males, the testicular tissue is preserved and orchiopexy is performed.

Hypospadias repair also is required in the males, and feminizing genitoplasty is performed in the females.

Another important management issue in patients with sexual ambiguity is the decision regarding sex assignment, particularly when the genital appearance is not compatible with the karyotype [8,9].

The most important factors that influence sex assignment include the definite diagnosis, genital appearance, surgical options, potential for fertility, risks of gonadalmalignancy, cultural issues and finally, the perception of the patient [10]. A multidisciplinary approach is needed.

In this patient, proper investigations and accurate diagnosis had been delayed for many years in spite of ambiguous genitalia being detected early in life.

This could have led to clinical and psychological problems in the adult life. Continued follow-up is necessary because of the multiple psychological, gynecological and urological problems encountered postpubertally by these patients [11].

REFERENCES

- Hughes IA, Houk C, Ahmed SF, Lee PA. Consensus statement on management of intersex disorders. *Arch Dis Child* 2006;91:554-63.
- Krob G, Braun A, Kuhnle U. True hermaphroditism: geographical distribution, clinical findings, chromosomes and gonadal histology. *Eur J Pediatr* 1994;153:2-10.
- Bhansali A, Mahadevan S, Singh R, Rao KL, Garewal G. True hermaphroditism: clinical profile and management of six patients from North India. *J Obstet Gynaecol* 2006;26:348-50.
- Vilain E. The genetics of ovotesticular disorders of sex development. *Adv Exp Med Biol* 2011;707:105-6.
- Diamond DA, Yu RN. Sexual differentiation: normal and abnormal. In: Wein AJ, Kavoussi LR, Novick AC, Partin AW, Peters CA (eds). *Campbell-Walsh Urology*, 10th edn. 2012, Saunders Elsevier, Philadelphia, pp 3613-4.
- Bouvattier C. Disorders of sex development: endocrine aspects. In: Gearhart JP, Rink RC, Mouriquand P (eds). *Pediatric Urology*, 2nd edn. 2010, Saunders Elsevier, Philadelphia, pp 468-9.
- Verp MS, Simpson JL. Abnormal sexual differentiation and neoplasia. *Cancer Genet Cytogenet* 1987;25:191-218.
- Reiner WG. Gender identity and sex-of-rearing in children with disorders of sexual differentiation. *J Pediatr Endocrinol Metab* 2005;18:549-553.
- Parisi MA, Ramsdell LA, Burns MW, Carr MC, Grady RE, Gunther DF, et al. A Gender Assessment Team: experience with 250 patients over a period of 25 years. *Genet Med* 2007;9:348-357.
- Jaruratanasirikul S, Engchaun V. Management of children with disorders of sex development: 20-year experience in southern Thailand. *World J Pediatr*. 2014 May;10(2):168-74. doi: 10.1007/s12519-013-0418-0. Epub 2013 Jun 17
- Verkauskas G1, Jaubert F, Lortat-Jacob S, Malan V, Thibaud E, Nihoul-Fékété C. The long-term followup of 33 cases of true hermaphroditism: a 40-year experience with conservative gonadal surgery. *J Urol*. 2007 Feb;177(2):726-31; discussion 731.