

5. Varga EA, Kerlin BA, Wurster MW. Social and ethical controversies in thrombophilia testing and update on genetic risk factors for venous thromboembolism. *Semin Thromb Hemost* 2008; 34: 549-61.

6. Ibbotson SH, Layton AM, Davies JA, Goodfield MJ. The effect of aspirin on haemostatic activity in the treatment of chronic venous leg ulceration. *Br J Dermatol* 1995; 132: 422-6.

doi:10.1684/ejd.2011.1287

Rituximab in pemphigus foliaceus with autoantibodies against both Desmoglein 1 and Desmoglein 3

Pemphigus foliaceus (PF) is generally a benign autoimmune blistering disease, but in some patients lesions are severe with serious implications in life quality. We report a case of severe PF refractory to standard treatment options successfully treated with rituximab.

A 26-year-old black male with a 1-year history of PF was treated with systemic prednisolone (up to 80 mg/day) and azathioprine (100 mg/day) for 9 months. Despite the immunosuppressant therapy, he still presented a high severity index [1], with numerous scaly, crusted erosions localized on the face and trunk (*figure 1A*). No lesions were found on mucosal surfaces. A skin biopsy showed clefting in the upper spinous layer. Direct immunofluorescence showed immunoglobulin G deposits in intercellular space, mainly in the spinous layer. Circulating levels of anti-Dsg1 and anti-Dsg3 IgG antibodies were measured in serum samples by a commercially available enzyme-linked immunosorbent assay (ELISA) and elevated levels of both were found. The patient was then treated with one cycle of four weekly infusions of rituximab at a dose of 375 mg/m² of body surface area on days 1, 8, 15 and 22. Azathioprine was stopped after the first infusion. The prednisolone dosage was tapered. The patient experienced clinical improvement that was evident immediately after the last infusion, with healing of all lesions after 2 months. With a 12 month follow-up period completed, dramatic clinical improvement was sustained (*figure 1B*). Changes in

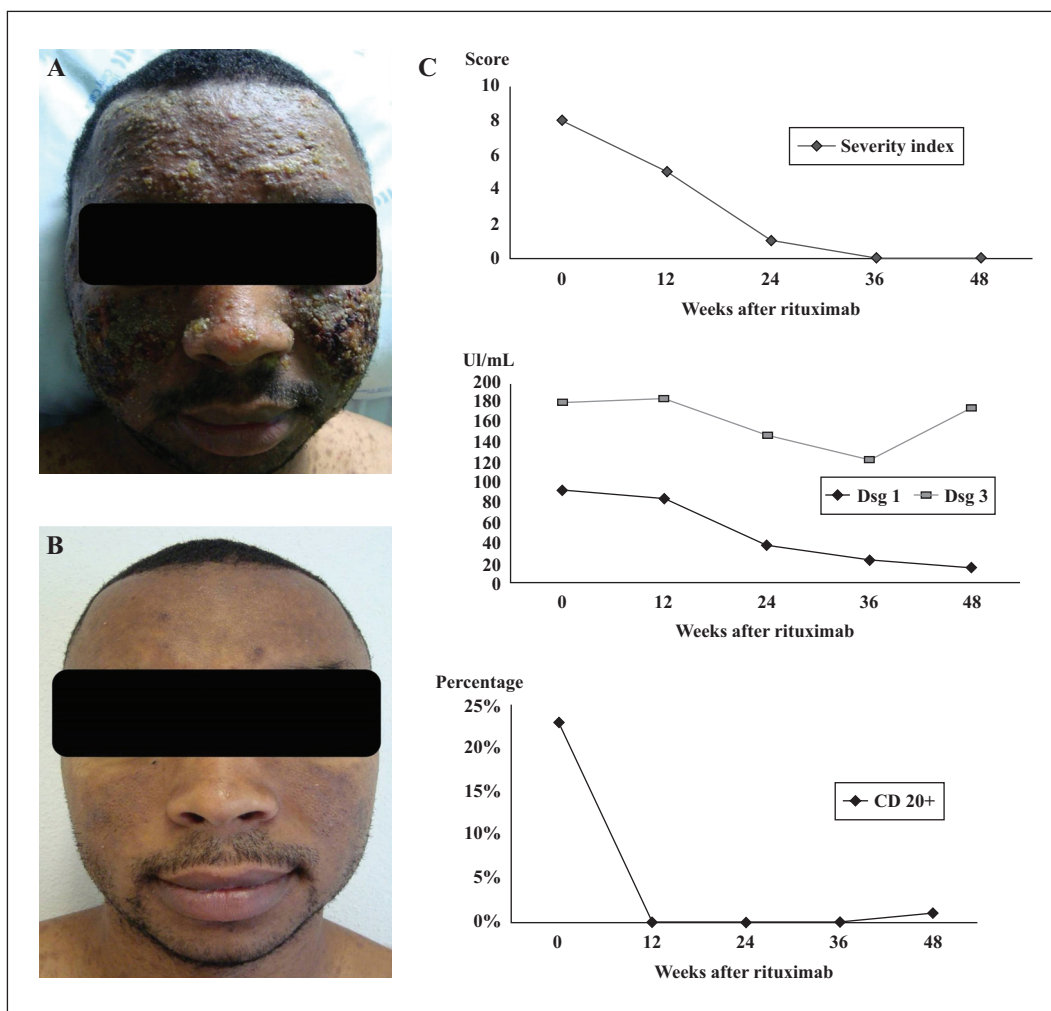


Figure 1. A) Numerous scaly, crusted erosions localized on the face. B) Complete remission sustained after a 12 month follow-up period. C) Time evolution of patient severity index (mild if less than 5, moderate if 5 to 7, and severe if higher than 7) [1], levels of antibodies to desmoglein 1 and desmoglein 3 (normal value < 20 UI/mL), and percentage of circulating CD20+ B cells.

anti-Dsg1 levels were consistent with the clinical response, with a progressive decline over the time. Persistent high titers in anti-Dsg3 were detected (figure 1C). The B-cell count in peripheral blood dropped to levels below 1% and remained that way during the follow-up. During this time no complications were detected.

The unequivocal diagnosis of PF was made according to clinical, histopathologic and immunofluorescence data. In general, patients with PF have anti-Dsg1 antibodies but not anti-Dsg3. The correlation between anti-Dsg profile and clinical subtype is well established, but does not hold true when the auto antibodies are non-pathogenic. In this patient, although elevated levels of anti-Dsg3 were found, there was no clinical phenotype for mucosal involvement. Recently, researchers have found elevated anti-Dsg3 levels by ELISA in a subset of patients with PF or its endemic variant *fogo selvagem* with no mucosal involvement [2]. The non-pathogenic state could be explained by a decreased affinity of the autoantibodies and epitope shift against different domains of desmoglein molecules [3].

The clinical response to rituximab was closely related to the evolution of anti-Dsg1, dramatically decreased over the time. However, in this patient persistently high levels of non-pathogenic anti-Dsg3 were found. Indeed, persistent high titers of anti-Dsg3 antibodies have been observed in patients with clinically complete remission of pemphigus vulgaris, treated with rituximab [4]. Some authors explain this phenomenon by a rituximab affinity for auto-reactive B cell clones [5]. Also, compelling evidence demonstrates that epitopes bound by anti-Dsg autoantibodies determine their pathogenic activities and disease activity in pemphigus patients [3]. It has been demonstrated that sera from pemphigus patients in complete remission after rituximab, with persistent high levels of anti-Dsg3 antibodies, no longer recognized the pathogenic epitopes that were targeted during the active phase of the disease [4].

Rituximab is a monoclonal chimeric IgG antibody targeting the B-cell specific cell surface antigen CD20. From its first use in PF, several case reports and small series have been published. A search of English, German and French literature found 20 PF patients treated with rituximab, with partial or complete response in 95% (19/20) patients [6]. However, prospective controlled trials are needed with longer follow-up to assess the long-term efficacy and risks of this treatment. ■

Disclosure. Financial support: none. Conflict of interest: none.

¹ Department of Dermatology and Venereology, Curry Cabral Hospital, Lisbon, Portugal

² Department of Pathology, Curry Cabral Hospital, Lisbon, Portugal

<rodrigoaraujocarvalho@gmail.com>

Rodrigo CARVALHO¹
Paula MAIO¹
Daniela CUNHA¹
Isabel FREITAS¹
Ana AFONSO²
Jorge CARDOSO¹

1. Ikeda S, Imamura S, Hashimoto I, et al. History of the establishment and revision of diagnostic criteria, severity index and therapeutic guidelines for pemphigus in Japan. *Arch Dermatol Res* 2003; 295: S12-6.

2. Amagai M. Non-pathogenic Anti-Desmoglein 3 IgG Autoantibodies in Fogo Selvagem. *J Invest Dermatol* 2006; 126: 1931-2.

3. Li N, Aoki V, Hans-Filho G, Rivitti EA, Diaz LA. The role of intramolecular epitope spreading in the pathogenesis of endemic pemphigus foliaceus (fogo selvagem). *J Exp Med* 2003; 197: 1501-10.

4. Joly P, Mouquet H, Roujeau JC, et al. A single cycle of rituximab for the treatment of severe pemphigus. *N Engl J Med* 2007; 357: 545-52.

5. Smith MR. Rituximab (monoclonal anti-CD20 antibody): mechanism of action and resistance. *Oncogene* 2003; 22: 7359-68.

6. Schmidt E, Goebeler M, Zillikens D. Rituximab in Severe Pemphigus. *Ann N Y Acad Sci* 2009; 1173: 683-91.

doi:10.1684/ejd.2011.1288

Porokeratosis ptychotropica

Porokeratosis is characterized by the proliferation of keratinocytes, which are responsible for annular lesions that exhibit an elevated hyperkeratotic ridge-like peripheral border and an atrophic centre [1]. The characteristic histological feature of porokeratosis is the presence of the cornoid lamella that is represented by a compact column of parakeratosis, whose cells originate from the stratum corneum and superior epidermis and are formed at the boundary between normal and abnormal epidermal cells at the ridge of the plaque [1].

Six types of porokeratosis are distinguished, notably classical porokeratosis of Mibelli, linear porokeratosis, punctate porokeratosis, disseminated superficial porokeratosis, disseminated superficial actinic porokeratosis, porokeratosis palmaris et plantaris disseminata. However, several other clinical forms have been reported. Porokeratosis ptychotropica (PP) belongs to these rare types and is characterized by symmetrically distributed reddish-brown papules and plaques, mainly localized on the buttock and the genital area [2]. Lesions tend to coalesce involving large areas. PP may show a hyperkeratotic, verrucous or psoriasisiform appearance. Unlike porokeratosis of Mibelli, which is generally asymptomatic, pruritus is often present in PP. Moreover, all reported cases have been described in male patients.

Here, we describe a 49-year-old man with a 2-year history of erythematous papules on the genital area. Lesions involved the buttocks with a marked affinity to the fold between the buttocks and thighs. New satellite lesions could be observed at the edges of the involved areas. The patient complained of pruritus and pain. There was no personal or familial history of skin diseases. Routine hematological and chemical evaluations were negative. Screening for HIV-1, HIV-2 and syphilis were negative. PCR detection of HPV DNA in skin lesions was negative. The possibility of fungal infection was excluded with PAS staining. Physical examination revealed bilateral and symmetrical well-demarcated hyperkeratotic, erythematous, brownish plaques involving buttocks, genitals, top of the thighs and groin (figures 1A, B). Histopathological examination of a biopsy showed multiple compact columns of hyperkeratotic cells, the cornoid lamellae (figure 1C). The granular layer was absent or poorly