

Collapsing glomerulopathy – a treatable disease?

Ana Carina Ferreira, Dulce Carvalho, Fernanda Carvalho, Fernando Nolasco, João Ribeiro dos Santos

Department of Nephrology, Hospital de Curry Cabral. Lisbon, Portugal.

Received for publication: 20/01/2008

Accepted in revised form: 06/03/2008

■ ABSTRACT

Renal disease is a relatively common complication in human immunodeficiency virus (HIV) infected patients and has become the fourth leading cause of death in AIDS individuals, immediately following septicaemia, pneumonia and hepatic disease. HIV associated nephropathy, HIV associated immune complex renal disease and HIV associated thrombotic microangiopathy are the main causes of chronic renal failure in this population.

The authors report a case of a 44 year-old black male, HIV 1 infected with low CD4 count, admitted to the nephrology department with non nephrotic proteinuria and renal failure. Renal biopsy revealed a focal segmental glomerulosclerosis collapsing variant. The patient was treated with highly active antiretroviral therapy and an ACE inhibitor and, at 3 months of follow-up, has recovered his renal function.

This case illustrates the efficacy of highly active antiretroviral therapy (HAART) on HIV associated nephropathy. Prospective studies are needed to evaluate HAART in the treatment of HIV associated nephropathies.

Key-Words:

Human immunodeficiency virus (HIV); HIV associated nephropathy (HIVAN); renal failure.

■ INTRODUCTION

HIV associated nephropathy (HIVAN) is the third leading cause of end stage renal disease (ESRD) in African Americans aged 20 to 64 and is the leading cause of ESRD in HIV1 infected patients¹. It is a distinct form of focal segmental glomerulosclerosis, recognised in 1984, affecting young patients and having a marked racial predilection for black people². HIVAN has been reported in all stages of the HIV infection, but affects particularly patients with low CD4 counts or with AIDS³. Patients usually present with proteinuria, often in the nephrotic range, moderate to severe renal insufficiency and enlarged, hyperechogenic kidneys on ultrasonography evaluation³. Oedema and haematuria are infrequent findings. Hypertension is usually absent, in contrast to the renal failure of other causes in black patients, where hypertension occurs in 90% of cases⁴. If left untreated, patients with HIVAN may progress rapidly to ESRD within 1 to 6 months⁵. Although there are no prospective randomised controlled studies evaluating the efficacy of highly active antiretroviral therapy (HAART) on HIVAN, the incidence of ESRD due to HIVAN has decreased, suggesting that the use of HAART, available since 1996, slows down or may cause remission of HIVAN⁶. In fact, since 1995, while the number of HIV infected persons has risen steadily, the number of incident cases of ESRD due to HIVAN has remained relatively constant^{1,6}.

In this report, we describe a case of a black male HIV positive patient with renal insufficiency and proteinuria. Renal biopsy showed HIVAN. There was a rapid reversal of renal insufficiency within three months of starting HAART.

■ CASE REPORT

A 44 year-old black male with no past medical history was admitted to the hospital with community acquired pneumonia. HIV1 infection was diagnosed at this time. He was referred to an infectiology appointment upon leaving the hospital. Three months later he was readmitted because of renal insufficiency, detected in routine examination, and referred to our nephrology unit. He was under no regular medication and there was no reported intravenous drug abuse.

His physical examination revealed a normal blood pressure, pulse and body temperature. There were no signs of volume expansion.

The laboratory data revealed a normochromic, normocytic anaemia, serum creatinine 3.2 mg/dl and a creatinine clearance (CrCl) of 33 ml/min. Serum bicarbonates were 18mmol/L. A 24 hours urine collection revealed a non nephrotic proteinuria (1.9g), serum albumin 3.5g/dl and analysis of urinary sediment demonstrated absent haematuria and leucocyturia. He was on AIDS definition: CD4 lymphocyte count = 35 cells/mm; plasma HIV-1 RNA level (b-DNA assay) 530000 copies/ml (Table I).

Tests for hepatitis B and C virus were negative. The VDRL test was negative. Complement C3 and C4 were within normal levels.

Renal ultrasonography showed large, well defined and hyperechogenic kidneys (RK 127 mm; LK 120 mm), with no obstruction.

A renal biopsy was performed and the findings were consistent with HIVAN, exhibiting glomerulosclerosis, with collapsing features (3 of 14 glomerulae were collapsed), dilated proliferative microcystic tubules, interstitial oedema and lymphocyte infiltration (Figure 1). Immunofluorescence was positive for C3, in a segmental pattern.

He started therapy with abacavir (Ziagen[®], 300 mg, twice a day), lamivudine (Epivir[®], 150 mg/day) and lopinavir/ ritonavir (Kaletra[®], 400mg/100 mg, 2 pills, twice a day) and with Enalapril (20mg/day).

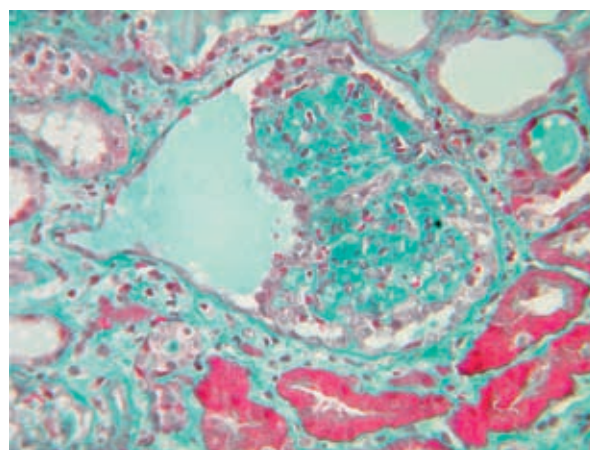


Figure 1

A collapsed, solidified glomerulus, covered by hypertrophic and hyperplastic visceral epithelium (TVF x160).

Table I

Laboratory data before and after starting HAART

	January 2007	March 2007	September 2007
Haemoglobin	9.7 g/dl	11.1 g/dl	13 g/dl
Serum urea	87 mg/dl	24 mg/dl	23 mg/dl
Serum creatinine	3.2 mg/dl	1.3 mg/dl	1.3 mg/dl
Creatinine Clearance	33 ml/min	66 ml/min	67 ml/min
Proteinuria	1.9 g/ 24 hours	1.0 g/24 hours	600 mg/24 hours
Serum albumin	3.5 g/dl	3.5 g/dl	4.4 g/dl
Serum bicarbonates	18 mmol/L	23 mmol/L	-
CD4 lymphocyte count	35 cells/mm	250 cells/mm	400 cells/mm
Plasma HIV1 RNA level (b-DNA assay)	530.920 copies/ml	-	-

Three months later he was re-evaluated. He remained normotensive and without peripheral oedema. His serum urea and creatinine levels fell to 24 mg/dl and 1.3 mg/dl respectively, 24 hours urine proteins fell to 1.0 g and CD4 increased to 250/mm³.

Presently, after 9 months of follow up, his renal function remains unchanged, with CrCl of 67 ml/min and 24 hours proteinuria fallen to 600 mg. His serum albumin is 4.4 g/dl and haemoglobin 13 g/dl.

DISCUSSION

HIV infected patients are at risk of developing a variety of renal insults⁵. Acute and reversible causes of renal failure must be excluded on initial evaluation, as they are for non infected HIV patients. After excluding acute causes of renal failure, HIVAN is found in about 30 to 50% of suspected cases^{7,8}. A renal biopsy is therefore essential in establishing the diagnosis in patients suspected of having HIVAN.

HIVAN is characterised by severe glomerulosclerosis, marked podocyte proliferation, microcystic dilatation of tubules and interstitial lymphocyte infiltration⁹. The pathogenesis is unclear but viral infection of renal cells may play a central role^{9,10}. Even in patients with no viral load detected the renal epithelial cells can act as a reservoir for the HIV virus¹⁰.

The treatment for HIVAN is not established. Some retrospective studies before the advent of HAART therapy showed that the protease inhibitor zidovudin may play a role in slowing the progression of renal disease^{6,11-14}.

There are no trials or prospective studies of HAART in preventing or treating HIVAN. Case reports of biopsy proven HIVAN presenting with proteinuria and renal insufficiency showed marked improvement after HAART^{10,15-19}. It should be pointed out that a case report demonstrated acute renal failure with spontaneous resolution in a biopsy-proven HIVAN without the use of HAART²⁰. On the other hand, Wali *et al.*¹⁵ and Winston *et al.*¹⁰ have clearly shown reversal of glomerular, tubular and interstitial lesions after HAART.

In addition, some authors claim that prednisolone is an alternative, in a dose of 60 mg per day, 2 to 11 weeks. Nonetheless, there are no controlled studies and this treatment is commonly associated with opportunistic infections^{19,20}.

We present a case of renal insufficiency, with 9 months evolution, as the patient had been discharged from hospital 3 months earlier and there was no evidence of renal failure at that point. The biopsy was crucial for a definite diagnosis. Chronic renal failure in an HIV infected patient is mostly due to HIVAN, HIV associated immune complex renal disease or to thrombotic microangiopathies⁵. This last diagnosis was obviously excluded as no signs of haemolytic anaemia were evident. In spite of HIVAN being highly likely (young black male, AIDS stage with low CD4 counts, enlarged and hyperechogenic kidneys in the context of chronic renal failure, isolated proteinuria), we could not exclude HIV associated immune complex renal disease. Two recent retrospective studies on HIV related nephropathy point out that HIV associated immune complex renal disease is highly prevalent, suggesting that it could be treated as HIV nephropathy^{7,8}.

In this patient, we tried to halt the progression to end stage renal failure with antiretroviral treatment, choosing the least nephrotoxic ones. Following three months of therapy, his serum creatinine declined to 1.3mg/dl and his CrCl increased to 66 ml/min. After nine months, his CrCl is 67 ml/min.

We describe an HIV infected patient with a biopsy proven HIVAN with non-nephrotic proteinuria and renal insufficiency whose renal function improved after beginning HAART. There are not many reported cases of improvement and non progressive renal failure in HIVAN with HAART, but we know that early treatment is required for a good outcome in this particular disease.

While future studies are needed to address the efficacy of HIVAN on HIV nephropathy, it is interesting to speculate that nephrotoxicity may become the major cause of HIV related nephropathy.

Acknowledgements

We thank Dr Joaquim Calado, PhD for assistance in the preparation of the manuscript.

References

- ¹ Mandayam S, Ahuja TS. Dialysing a patient with human immunodeficiency virus infection: what a nephrologist needs to know. *Am J Nephrol* 2004;24:511-521
- ² Rao TK, Friedman EA, Nicastri AD. The types of renal disease in the acquired immunodeficiency syndrome. *N Engl J Med* 1987;316:1062-1068
- ³ Ross MJ, Klotman PE. Recent progress in HIV associated nephropathy. *J Am Soc Nephrol* 2002;13:2997-3004
- ⁴ Coresh J, Jaar B. Further trends in the etiology of end-stage renal disease in African-Americans. *Curr Opin Nephrol Hypertens* 1997;6:243-249
- ⁵ Weiner NJ, Goodman JW, Kimmel PL. The HIV associated renal diseases: current insight into pathogenesis and treatment. *Kidney Int* 2003;63:1618-1631
- ⁶ Schwartz EJ, Szczech LA, Ross MJ, *et al.* Highly active antiretroviral therapy and the epidemic of HIV+ end stage renal disease. *J Am Soc Nephrol* 2005;16:2412-2420
- ⁷ Szczech LA, Gupta SK, Habash R, *et al.* The clinical epidemiology and course of the spectrum of renal diseases associated with HIV infection. *Kidney Int* 2004;66:1145-1152
- ⁸ Gernholtz TE, Goetsch SJW, Katz I. HIV-related nephropathy: a south african perspective. *Kidney Int* 2006;69:1885-1891
- ⁹ Lu T-C, Ross M. HIV associated nephropathy: a brief review. *The Mount Sinai J Medicine* 2005;72:193-199
- ¹⁰ Winston J, Bruggeman LA, Ross MD, *et al.* Nephropathy and establishment of a renal reservoir of HIV type 1 during primary infection. *N Engl J Med* 2001;344:1979-1984
- ¹¹ Lucas GM, Eustace JA, Sozio S, *et al.* Highly active antiretroviral therapy and the incidence of HIV 1 – associated nephropathy: a 12 year cohort study. *AIDS* 2004;18:541-546
- ¹² Ifudu O, Rao TK, Tan CC, *et al.* Zidovudine is beneficial in human immunodeficiency virus associated nephropathy. *Am J Nephrol* 1995;15:217-221
- ¹³ Michel C, Dosquet P, Ronco P, *et al.* Nephropathy associated with infection by human immunodeficiency virus: a report on 11 cases including 6 treated with zidovudine. *Nephron* 1992;62:434-440
- ¹⁴ Szczech LA, Edwards LJ, Sanders LL, *et al.* Protease inhibitors are associated with slowed progression of HIV-related renal diseases. *Clin Nephrol* 2002;57:336-341
- ¹⁵ Wali RK, Drachenberg CI, Papadimitriou JC, *et al.* HIV 1 associated nephropathy and response to highly active antiretroviral therapy. *Lancet* 1998;352:783-784
- ¹⁶ Kirchner JT. Resolution of renal failure after initiation of HAART: 3 cases and a discussion of the literature. *AIDS Read* 2002;12:103-105, 110-102
- ¹⁷ Chemal K, Nochy D, Kenouch S, *et al.* Dramatic improvement of renal dysfunction in a human immunodeficiency virus-infected woman treated with highly active retroviral therapy. *Clin Infect Dis* 2000;31:805-806
- ¹⁸ Betjes MG, Verhagen DW. Stable improvement of renal function after initiation of highly active anti-retroviral therapy in patients with HIV 1 – associated nephropathy. *Nephrol Dial Transplant* 2002;17:1836-1839
- ¹⁹ Renal failure reversed in first documented case. *AIDS alert* 1998;13:141-142
- ²⁰ Morales E, Martinez A, Sanchez-Ayuso J, *et al.* Spontaneous improvement of the renal function in a patient with HIV associated focal glomerulosclerosis. *Am J Nephrol* 2002;22:369-371
- ²¹ Smith MC, Austen JL, Carey JT, *et al.* Prednisone improves renal function and proteinuria in human immunodeficiency virus-associated nephropathy. *Am J Med* 1996;101:41-48
- ²² Eustace JA, Nuernberger E, Choi M, *et al.* Cohort study of the treatment of severe HIV-associated nephropathy with corticosteroids. *Kidney Int* 2000;58:1253-1260

Conflict of interest statement. None declared.

Correspondence to:

Dr Ana Carina Ferreira
 Serviço de Nefrologia. Hospital Curry Cabral
 Rua de Beneficência, 8
 1050 Lisbon, Portugal
 karinadacostafer@hotmail.com