

Leg ulcers in antiphospholipid syndrome secondary to systemic lupus erythematosus treated with intravenous immunoglobulin

Guida Santos¹, Alexandre João¹, Lourdes Sousa²

1. Department of Dermatology and Venereology, Hospital Santo António dos Capuchos, Centro Hospitalar de Lisboa Central, Portugal;

2. Department of Dermatology and Venereology, Hospital São Bernardo, Setúbal, Portugal.

Corresponding author:

Guida Santos

Department of Dermatology and Venereology of Hospital Santo António dos Capuchos

Alameda Santo António dos Capuchos, 1169-050 Lisbon

E-mail: guidadossantos@gmail.com

Key words:

antiphospholipid syndrome, intravenous immunoglobulin, lupus, ulcer

Abstract

Background: Despite encouraging reports on the efficacy of intravenous immunoglobulin (IVIg) in antiphospholipid syndrome, the clinical value of this treatment is not well established, and most of the data are based on case reports and small series of patients.

Observation: We describe the significant improvement of leg ulcers with IVIg in a 61-year-old female, with diabetes mellitus, venous peripheral insufficiency and secondary antiphospholipid syndrome to systemic lupus erythematosus.

Conclusion: This case illustrates a rare cause of leg ulcers and documents that IVIg may be an effective adjuvant treatment in the management of selected patients with antiphospholipid syndrome when conventional strategies using subcutaneous heparin and low-dose aspirin are insufficient. (*J Dermatol Case Rep.* 2014; 8(2): 38-41)

Introduction

Lower extremity ulcers are an infrequent but disabling complication of long-standing connective tissue diseases. They occur more commonly in patients with these diseases than in general population.¹ Although these lesions have historically been attributed to vasculitis, it is now recognized that inflammatory vessel injury accounts for fewer than 20% of ulcers in connective tissue disease.¹ The pathogenesis still remains incompletely understood. It is known that inflammation serves as a necessary link between the observed procoagulant phenotype and actual thrombus development.² In systemic lupus erythematosus, ulcers were seen in 5,6% of patients.¹

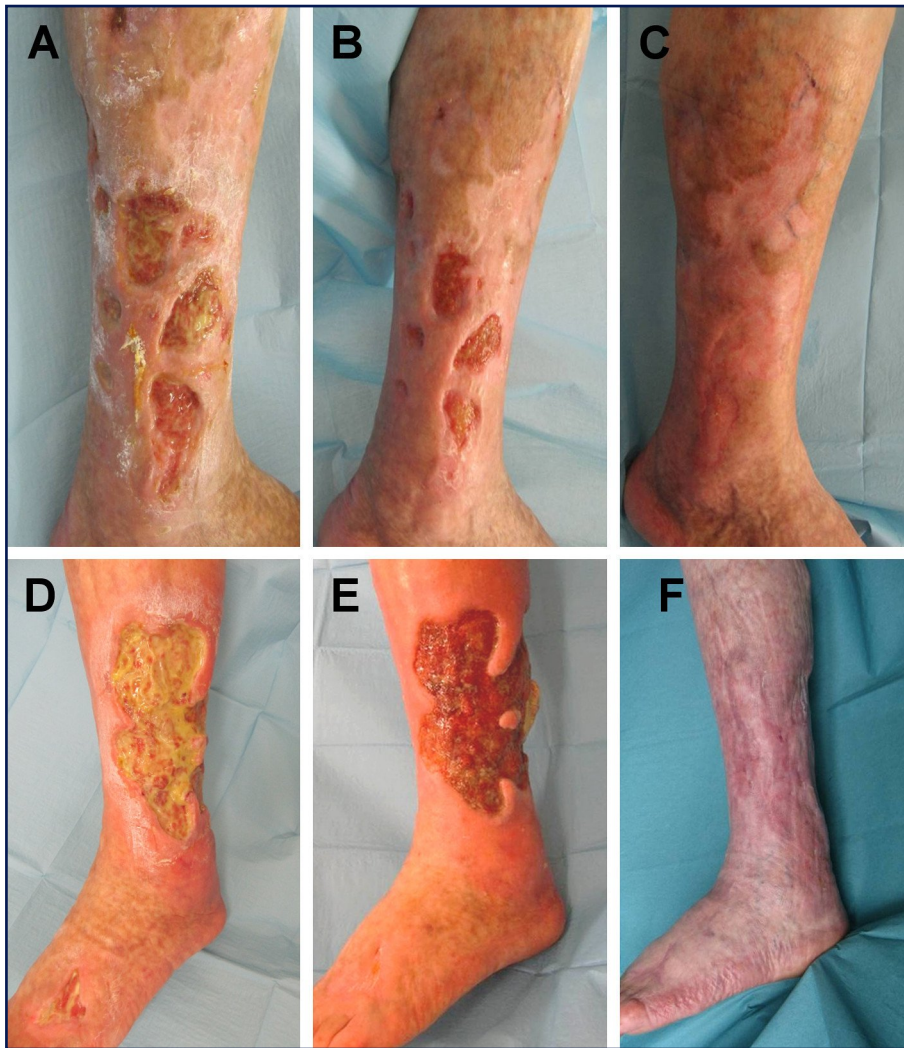Antiphospholipid syndrome (APS) is an acquired autoimmune thrombophilia that produces significant morbidity and mortality.^{1,3,4} Its diagnosis requires the presence of antiphospholipid antibodies (aPL) and clinical manifestations that include thrombotic phenomena and/or recurrent miscarriages.^{1,3,4} It can be either primary or secondary to an underlying condition, most commonly systemic lupus erythematosus (SLE).⁴ Clinical manifestations are varied.^{1,3,4,5} The most

frequent skin lesions in patients with APS are livedo reticularis and skin ulcers.^{3,4,5,6}

The authors describe the resolution of leg ulcers in APS secondary to SLE treated with intravenous immunoglobulin (IVIg).

Case report

Female, 61-year-old, presented with spontaneous, sudden onset, painful, rapidly enlarging leg ulcers, lasting for few days. The patient had one spontaneous abortion. Systemic erythematosus lupus were diagnosed 18 years before, based on cutaneous, hematologic and immunologic disorders. She had a medical history of polyarthralgia, with early morning stiffness, of the cervical, knee and shoulder joints, with intermittent arthritis of the interphalangeal joints and less frequently of the feet, not documented in radiological exams. She had recurrent epistaxis and hematomas due to thrombocytopenia for several years, with a minimum platelet count of $44.10^9/L$ (normal levels superior to $150.10^9/L$), leucopenia $3.8.10^9/L$ (in 1994, normal levels superior to $4.5.10^9/L$). The patient also had in the past ANAs 1/100 (speckled pattern),

**Figure 1**

Right leg ulcer A) before IVIG, B) after the first infusion and C) completely healed.

Left leg ulcer D) before IVIG, E) after the fifth infusion and F) completely healed.

anti-SSA positive, anti-DNA 776UI/ml (superior to 300 UI/ml), anticardiolipin antibody (aCL)-IgG: 17,68 GPL/ml (≥ 12 GPL/ml) and aCL-IgM negative. The patient presented photosensitivity, malar erythema, due to lupus erythematosus confirmed by punch biopsy and non-scarring diffuse alopecia. There were no others systemic involvement. The patient was treated with NSAIDs, cycles of systemic corticosteroids, resorcin and posteriorly hydroxychloroquine during the exacerbations of the arthralgias and the cutaneous changes. The patient also presented diabetes mellitus for 21 years, treated with insulin since 8 years, high blood pressure for 21 years treated initially with captopril and actually with bisoprolol and, venous peripheral insufficiency with right saphenectomy.

When she came to our department, she presented extensive, deep and sharply marginated, with noninflammatory periphery skin ulcers of both legs. She had a 25 cm-longest diameter on the lateral face of the right leg, a smaller ulcer on the lateral and posterior face of the left leg, and the smallest one in the dorsum of the foot (Fig. 1).

Complete blood analyses were performed: antinuclear antibodies (ANA): 1/160, speckled pattern, aCL-IgM: 43,7 MPL/ml (≥ 12 GPL/ml), aCL-IgG: 98,1 GPL/ml (≥ 12 GPL/ml) with no others laboratory changes. A punch biopsy was performed

and showed an ulcer with a mixed inflammatory infiltrate with microthrombus in dermal vessels adjacent to the area of ulceration with no inflammatory component in the vascular wall. These findings, supported by clinical features, were consistent with APS (Fig. 2). Doppler sonography was done and revealed parietal arterial calcifications, with no significant stenosis. Venous Doppler sonography revealed relapse of the right sapheno-femoral junction, varicoses in the internal face of the right thigh and leg.

Concomitantly to hydroxychloroquine (400 mg daily) and high dosis of corticosteroids (60 mg of prednisolone), the patient began low-weight-heparin (enoxaparin 60mg subcutaneously initially, tapered to 40mg/day), switched after to warfarin (5 to 6,25 mg/day). There was initially poor compliance of the patient, namely in taking regularly the anticoagulation drugs because she referred occasional bleeding of the legs ulcers that led to uncontrolled INR (between 1-2) and clinical aggravation. Despite 4 months of treatment and several local treatments (charcoal alginate dressings, sodium carboxymethyl cellulose, activated charcoal dressing, collagenase and povidone-iodine polymer), the results were unsatisfactory.

Then, the patient started treatment with IVIg 1 g/kg daily, every four weeks in two consecutive days. A marked improvement

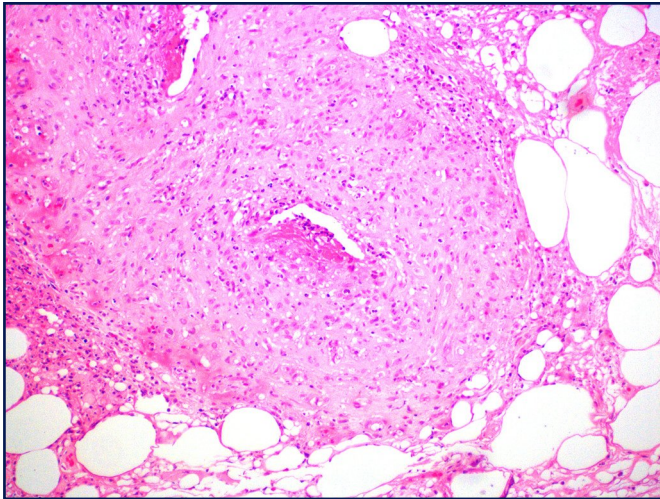


Figure 2
Histopathology of the ulcer area. Microthrombus without inflammatory component of the vascular wall (HEx100).

was noticed promptly after the first infusion leading to smaller and more superficial ulcers. Three months after, the right leg ulcer closed and the left leg ulcer had a significant improvement (Fig. 1).

The patient also began concomitantly with the third administration of IVIg, azathioprin (50 mg/day up to 150 mg/day) in order to accelerate the repitelizing of the ulcers. She completed eight cycles of IVIg and continued hydroxychloroquine, the anticoagulation treatment and lower dosage of immunosuppressive treatment (systemic steroids progressively tapered to 20 mg/day and azathioprin tapered until stopping it. After 3 years of hydroxychloroquine, cycles of corticosteroids (between 20-40 mg/day), hyperbaric oxygen therapy in 2010 (60 sessions of 90 minutes, 2,5 atmosphere absolute), a better compliance with anticoagulation treatment (but frequently with infra-therapeutic levels with INR under values of 2), and local wound care (mainly povidone-iodine polymer and activated charcoal dressing), the ulcers healed completely. The patient is still under hydroxychloroquine and warfarin.

Discussion

The dermatologic manifestations of APS are frequently the presenting feature of the syndrome^{3,6} and leg ulcers are considered to be among their most frequent manifestations with characteristically poor response to treatment.^{7,8} It is known that 30 to 50% of the patients with systemic lupus erythematosus will develop APS. Our patient has developed APS after 18 years of the diagnosis of SLE. The precise mechanisms responsible for thrombosis in these patients remains unclear.⁹

Therapy for dermatologic lesions due to APS remains empirical due to the scarcity of cases.⁶ The management of these lesions depends on their clinical aggressiveness but the overall clinical situation must be considered.⁶ The therapeutic decisions must consider laboratory profile, the presence

of associated autoimmune diseases and other risk factors for venous or arterial thrombosis.¹⁰

The antiplatelet therapy such as low-aspirin plus prophylactic unfractionated and/or low-molecular-weight heparin (LMWH) is usually chosen as first-line treatment.^{3,6,11} Widespread cutaneous lesions are considered to be major thrombotic events and their recommended treatment is long-term-high-intensity warfarin (INR \geq 3).^{6,10,11,13} Currently, new generations of anticoagulants like dabigatran etexilate (pradaxa) and rivaroxaban (xarelto) are available.¹²

Major bleeding associated with oral anticoagulant therapy is low.¹³ However, in patients with risk for bleeding, as the ulcers of our patient or patients with severe thrombocytopenia, which is a common laboratory manifestation of APS (frequently due to the presence of aPL), IVIg can be an adjuvant option.¹¹

Several immunosuppressive treatments are effective in improving platelet count as rituximab and more recently belimumab.¹¹ Therapy with sildenafil, cyclosporine A, plasmapheresis, were also tried with good results but are only limited to anecdotal cases.^{13,14,15} Hydroxychloroquine and low-dose prednisolone appear to be useful when added to standard therapy in refractory APS. Because hydroxychloroquine has also antiplatelet effects and reduce the risk of thrombosis, it is useful in APS especially in APS secondary to SLE as the case of our patient.⁹ However, long-term anticoagulation is frequently required.^{6,14}

Of patients with skin involvement, 40% will develop multisystemic thrombotic events.

Recurrence remains frequent despite the use of oral anticoagulants. Patients with APS and triple positivity for aPL are at high risk of developing future thromboembolic events.¹⁰

IVIg is beneficial and carries a good safety profile in treatment of SLE^{11,18,19,20} and other autoimmune diseases as APS. IVIG is usually safer than immunosuppressive agents¹⁹ but it should be noted that a few complications may accompany its use, among the most frequent are rash, headache and arthralgia. The beneficial effects of IVIG on overall APS activity are usually prompt within a few days, but they are often of limited duration.¹⁹ In our patient, we observed that the quicker and bigger improvement of the ulcers was always promptly (days) after the administration of Immunoglobulin. IVIG has the advantage to both inhibits the antiphospholipid antibodies, and probably decreases their further production.¹ The report by Sherer *et al* contributes to understand that in certain patient subgroups IVIG might have an additive effect to anticoagulation.¹⁹ The detrimental effects of aPL should also be attributes to mechanisms other than thrombosis. The advantage of using IVIG over conventional therapies or in combination is that IVIG has not been found to increase the risk of opportunistic infections and hence, can spare steroids or other immunosuppressive treatments.²⁰ This advantage was also particularly appreciated in this patient due to her immunodeficiency. This adjuvant therapeutical option also avoids bleeding risks.

Although experience remains limited and uncontrolled, intravenous immunoglobulin (IVIg) therapy probably has a place in the management of selected patients with APS when conventional strategies using subcutaneous heparin

and low-dose aspirin have failed.¹¹ This case documented that IVIg may be an effective adjuvant treatment of leg ulcers due to secondary APS.

Preventing the recurrence of skin lesions in APS depends not only on their severity, but also on the features of the disease. There are no data concerning the frequency of recurrence of skin vessels thrombosis.⁶ Duration of anticoagulation therapy is controversial and some authors recommend lifelong anticoagulation therapy.¹³ It is important to remove or reduce risk factors as stop smoking and avoid estrogen-containing-pills.

More data should be obtained in order to decide the optimal treatment of this syndrome which is still unclear.

References

1. Shanmugam VK, Steen VD, Cupps TR. Lower extremity ulcers in connective tissue disease. *Isr Med Assoc J.* 2008; 10: 534-536. PMID: 18751636.
2. Willis R, Harris EN, Pierangeli SS. Pathogenesis of the antiphospholipid syndrome. *Semin Thromb Hemost.* 2012; 38: 305-321. PMID: 22510982.
3. Miyakis S, Lockshin MD, Atsumi T, Branch DW, Brey RL, Cervera R, Derksen RH, DE Groot PG, Koike T, Meroni PL, Reber G, Shoenfeld Y, Tincani A, Vlachoyiannopoulos PG, Kriklis SA. International consensus statement on an update of the classification criteria for definite antiphospholipid syndrome (APS). *J Thromb Haemost.* 2006; 4: 295-306. PMID: 16420554.
4. García-García C. Antiphospholipid antibodies and antiphospholipid syndrome: diagnosis and management. *Actas Dermosifiliogr.* 2007; 98: 16-23. PMID: 17374329.
5. Asherson RA, Cervera R, Merrill JT, Erkan D. Antiphospholipid antibodies and the antiphospholipid syndrome: clinical significance and treatment. *Semin Thromb Hemost.* 2008; 34: 256-266. PMID: 18720305.
6. Frances C. Dermatological manifestations of Hughes' antiphospholipid antibody syndrome. *Lupus.* 2010; 19: 1071-1077. PMID: 20693200.
7. Panuncialman J, Falanga V. Basic approach to inflammatory ulcers. *Dermatol Ther.* 2006; 19: 365-376. PMID: 17199679.
8. Cañas CA, Durán CE, Bravo JC, Castaño DE, Tobón GJ. Leg ulcers in the anti-phospholipid syndrome may be considered as a form of pyoderma gangrenosum and they respond favorably to treatment with immunosuppression and anticoagulation. *Rheumatol Int.* 2010; 30: 1253-1257. PMID: 20349240.
9. Al-Homood IA. Thrombosis in systemic lupus erythematosus: a review article. *ISRN Rheumatol.* 2012; 2012: 428269. PMID: 22900201.
10. Pengo V. APS-controversies in diagnosis and management, critical overview of current guidelines. *Thromb Res.* 2011; 127 Suppl 3: S51-52. PMID: 21262441.
11. Hughes GR. Hughes syndrome (the antiphospholipid syndrome): a disease of our time. *Inflammopharmacology.* 2011; 19: 69-73. PMID: 21132565.
12. Cohen H, Machin SJ. Antithrombotic treatment failures in antiphospholipid syndrome: the new anticoagulants? *Lupus.* 2010; 19: 486-491. PMID: 20353992.
13. Pengo V, Denas G, Banzato A, Bison E, Bracco A, Facchinetti M, Hoxha A, Ruffatti A. Secondary prevention in thrombotic antiphospholipid syndrome. *Lupus.* 2012; 21: 734-735. PMID: 22635217.
14. Pengo V, Ruffatti A, Legnani C, Gesele P, Barcellona D, Erba N, Testa S, Marongiu F, Bison E, Denas G, Banzato A, Padayattil Jose S, Iliceto S. Clinical course of high-risk patients diagnosed with antiphospholipid syndrome. *J Thromb Haemost.* 2010; 8: 237-242. PMID: 19874470.
15. Gertner E. Treatment with sildenafil for the healing of refractory skin ulcerations in the antiphospholipid syndrome. *Lupus.* 2003; 12: 133-135. PMID: 12630758.
16. Erre GL, Pardini S, Faedda R, Passiu G. Effect of rituximab on clinical and laboratory features of antiphospholipid syndrome: a case report and a review of literature. *Lupus.* 2008; 17: 50-55. PMID: 18089684.
17. Bontadi A, Ruffatti A, Marson P, Tison T, Tonello M, Hoxha A, De Silvestro G, Punzi L. Plasma exchange and immunoadsorption effectively remove antiphospholipid antibodies in pregnant patients with antiphospholipid syndrome. *J Clin Apher.* 2012; 27: 200-204. PMID: 22532158.
18. Konova E. Intravenous immunoglobulin therapy in antiphospholipid syndrome. *Clin Rev Allergy Immunol.* 2005; 29: 229-236. PMID: 16391398.
19. Levy Y, Sherer Y, Ahmed A, Langevitz P, George J, Fabbri F, Terryberry J, Meissner M, Lorber M, Peter JB, Shoenfeld Y. A study of 20 SLE patients with intravenous immunoglobulin--clinical and serologic response. *Lupus.* 1999; 8: 705-712. PMID: 10602441.
20. Toubi E, Kessel A, Shoenfeld Y. High-dose intravenous immunoglobulins: an option in the treatment of systemic lupus erythematosus. *Hum Immunol.* 2005; 66: 395-402. PMID: 15866703.