

Original Paper

Ophthalmologica

Ophthalmologica
DOI: 10.1159/000369478Received: August 10, 2014
Accepted after revision: October 28, 2014
Published online: March 13, 2015

Intraocular Pressure in Eyes Receiving Intravitreal Antivascular Endothelial Growth Factor Injections

Vanessa Lemos Ana Cabugueira Manuel Noronha Luís Abegão Pinto
Maria Reina João Branco Teresa Gomes

Centro Hospitalar de Lisboa Central, Lisbon, Portugal

Key Words

Intraocular pressure · Risk factors · Intravitreal injection · Antivascular endothelial growth factor

Abstract

Purpose: The aim of this study was to determine the effect of intravitreal antivascular endothelial growth factor injections on intraocular pressure (IOP) and identify possible risk factors for the development of increased IOP. **Materials and Methods:** This prospective study included a total of 106 eyes receiving intravitreal injection of bevacizumab as treatment for macular edema or active choroidal neovascularization. IOP was measured by Goldmann applanation tonometry immediately before the intravitreal injection and 5 min, 1 h and 15 days after the procedure. The records of the study patients were reviewed for age, gender, history of glaucoma, diabetes mellitus, phakic status, systemic and topical medication and number of previous injections. Subconjunctival reflux was registered. IOP elevation was defined as IOP ≥ 21 mm Hg and/or a change from baseline of ≥ 5 mm Hg recorded at least on two or more measurements on the same visit. **Results:** Mean preoperative IOP was 15.31 ± 3.90 mm Hg and postoperative IOP values were 27.27 ± 11.87 mm Hg (after 5 min), 17.59 ± 6.24 mm Hg (after 1 h) and 16.86 ± 3.62 mm Hg (after 15 days). The IOP variation was statistically significant

between pre- and postoperative measurements ($p < 0.05$). Subconjunctival reflux was recorded in 11.3%, and in this subgroup the IOP at 5 min and at 1 h was lower than preoperative IOP ($p < 0.05$). **Conclusions:** More than one third of the eyes achieved IOPs >30 mm Hg 5 min after injection. Subconjunctival reflux contributed to a lower mean postoperative IOP ($p < 0.05$). Considerations for the management include prophylactic IOP lowering with medical therapy and/or preinjection ocular decompression for patients with a history of glaucoma or ocular hypertension and switching to an as-needed injection protocol in patients suffering a marked IOP rise in previous injections.

© 2015 S. Karger AG, Basel

Introduction

Intravitreal antivascular endothelial growth factor (anti-VEGF) agents are currently used for the treatment of neovascular age-related macular degeneration (AMD), diabetic retinopathy and retinal vein occlusion.

Although ranibizumab is the licensed drug for intravitreal treatment of neovascular AMD, bevacizumab has been widely used as an off-label treatment because of its lower cost [1].

The CATT study reported a very low rate of ocular complications, such as endophthalmitis, uveitis, retinal detachment or tear, vitreous hemorrhage and retinal vascular events (all <1%) [2]. That study, however, did not address the issue of intraocular pressure (IOP) elevation following repeated intravitreal anti-VEGF injections, which has previously been described with a prevalence between 2.9% [3], 11% [1] and 27.6% [4].

The MARINA and ANCHOR trials both found transient increases in IOP after injection in the respective treatment groups, but with very few patients experiencing a rise of ≥ 40 mm Hg. However, the injection protocol did not mandate IOP measurement within 1 h of injection, and thus an IOP rise during this time frame was not reported [5–7].

Good et al. [8] reviewed the charts of 215 eyes receiving one or more bevacizumab and/or ranibizumab injections for exudative AMD (101 eyes with bevacizumab). About 6% of the eyes experienced sustained IOP elevation and required medical or surgical therapy. This rate was significantly higher in patients with a history of pre-existing glaucoma than in those without a glaucoma history (33 vs. 3.1%; $p < 0.001$). When comparing the frequency of injections and the total number of injections received between the group experiencing sustained IOP rise and those that remained ocular normotensive, no difference was found [8].

Other series investigating short-term IOP changes also found that IOP tended to return to a safe level in the majority of patients by 10–30 min following injection but did not investigate immediate postinjection IOP [5].

In order to investigate the immediate short-term effects of anti-VEGF injection on IOP, Gismondi et al. [9] performed a prospective study of 54 eyes with intravitreal ranibizumab. In that study, the IOP was measured immediately before as well as 5 s and 5, 10, 15, 30 and 60 min and 1 day after injection. They found a considerable increase in IOP within 30 min of intravitreal injection. The difference between the IOP before and that after injection was statistically significant after 5 s as well as after 5, 10, 15 and 30 min ($p = 0.0001$); however, it was not significant after 1 h ($p = 0.064$) and after 1 day ($p = 0.449$). About 90% of the study participants experienced an IOP rise of >30 mm Hg at 5 s after injection [9].

A retrospective series performed by Kim et al. [10] revealed similar findings in 120 eyes of 112 patients receiving intravitreal injections of ranibizumab, bevacizumab, pegaptanib and triamcinolone acetonide. The mean IOP immediately after injection was 44 mm Hg (range 4–87), with 36% of the eyes experiencing a rise to ≥ 50 mm Hg.

Although the IOP was reduced to <30 mm Hg in 96% of the eyes by 15 min, the eyes with a history of glaucoma took significantly longer to reach this level ($p = 0.002$) [10].

Short-term increases in IOP occurring after intravitreal anti-VEGF injection therapy may take longer to normalize in patients with preexisting glaucoma or ocular hypertension [5].

The pathogenesis of short-term IOP elevation after anti-VEGF injection most directly relates to an increase in intraocular fluid volume [3–5, 10, 11]. Other potential variables influencing IOP rise include axial length, scleral thickness, scleral rigidity and ocular outflow facility [5]. The pathogenesis of sustained elevation of intraocular pressure after intravitreal injections remains unknown. Several theories have been proposed, including a permanent decrease in outflow facility due to repeated IOP spikes with each injection and subsequent damage to the trabecular meshwork, direct pharmacological toxicity and chronic trabeculitis [5].

The acute increase in IOP is associated with a decreased papillary and juxtapapillary blood supply [12]. Thus, an IOP elevation after intravitreal injection could result in damage of ganglion cells, which, if not identified and treated, can cause permanent visual loss, explaining the clinical importance of this study.

The aim of this study was to determine the effect of intravitreal anti-VEGF injections on IOP 5 min, 1 h and 15 days after the procedure and to investigate possible risks factors associated with elevated IOP.

Materials and Methods

This prospective study included 106 eyes of 79 patients treated with intravitreal bevacizumab (1.25 mg/0.05 ml) in an operating room of the Centro Hospitalar de Lisboa Central by 3 retina specialists between March 1 and August 31, 2013.

Eyes were included if IOP measurements were recorded immediately before the intravitreal injection and 5 min, 1 h and 15 days after the procedure. Patients were excluded if they had a history of previous ocular surgeries (other than phacoemulsification), were aged <18 years, received topical corticosteroids, had had an intravitreal injection of corticosteroids in the last 6 months, had anterior chamber paracentesis or were administered prophylactic antiglaucomatous drops on the perioperative period. Informed consent was obtained from each patient.

Patients were uniformly sterilely prepped, which included a topical antibiotic (fourth-generation fluoroquinolone) as well as instillation of topical anesthesia using oxybuprocaine (4 mg/ml), insertion of a lid speculum and a 5% povidone iodine flush, followed by a rinse with balanced salt solution. Injections of 0.05 ml of bevacizumab (1.25 mg/0.05 ml) were done using a superotem-

Table 1. Demographics and baseline characteristics

Eyes, n	106
Age of the patients	
Mean \pm SD	70.61 \pm 10.77
Range	35–91
Females	64 (60.4%)
Diabetes mellitus	64 (60.4%)
Glaucoma	22 (20.8%)
Phakic	79 (74.5%)
Pseudophakic	27 (25.5%)
Aphakic	0
Previous injections	
Mean \pm SD	3.93 \pm 3.06
Range	1–18

poral (76 eyes) or infratemporal (30 eyes) approach at a distance of 3.5–4.0 mm away from the limbus with a 30-gauge needle. After this procedure, the injection site was occluded temporarily and massaged with a sterile cotton-tipped applicator as the needle was withdrawn from the eye. Subconjunctival reflux was recorded. Additional instillation of 5% povidone iodine and fourth-generation fluoroquinolone drops was performed. No anterior chamber puncture was done after the injection. After each injection, the patients were instructed to use antibiotic drops 4 times daily for 5 days.

IOP measurement was performed with a Goldmann tonometer by an ophthalmologist and was obtained at the beginning of the treatment before the first injection (baseline IOP) and 5 min, 1 h and 15 days after the injection. The tonometer prism was disinfected with 0.5% hypochlorite for 10 min before each measurement.

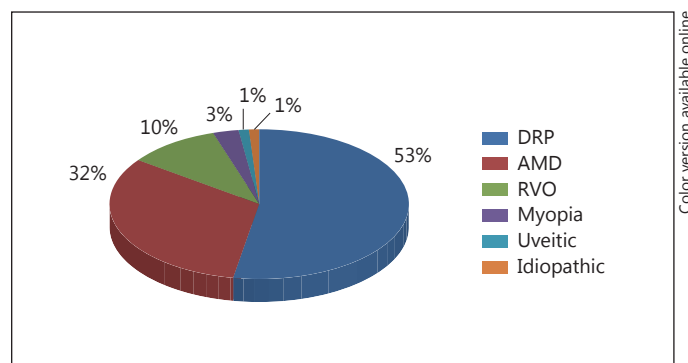
IOP elevation was defined as an IOP >21 mm Hg recorded on two measurements at the same visit to confirm the value, and if the difference between the measurements was >2 mm Hg, another ophthalmologist measured a third time so we could avoid a measurement error. IOP elevation was also defined as a change from baseline of ≥ 5 mm Hg.

Patients were classified as having glaucoma based on optic disk damage and visual field defect. All these glaucoma patients had previously been under antiglaucoma medication. Patient data that were collected included age, gender, history of glaucoma and diabetes, systemic and topical medication, phakic status, subconjunctival reflux and total number of injections. A total of 30 eyes of 22 patients did not attend to the visit 15 days after the injection.

Statistical Analysis

Data analysis was performed using the software Statistical Package for the Social Sciences (SPSS) version 20.0 for Windows. The t test for paired samples was performed to compare the IOP before injection with the IOP 5 min, 1 h and 15 days after treatment.

Analysis of subconjunctival reflux occurrence, glaucoma, diabetes and phakic status and its relation with increased IOP 5 min, 1 h and 15 days after the injection was performed with the t test for independent samples. The assumptions of these tests, including the assumption of normality of distribution and the assumption of homogeneity of variance, were analyzed with the Kolmogorov-

**Fig. 1.** Disease rates. DRP = Diabetic retinopathy; RVO = retinal vein occlusion.

Smirnov and Levene's test. When these assumptions were not satisfied, the t test was replaced by the Mann-Whitney test for independent samples and by the Wilcoxon test for paired samples. In situations where the samples were >30 , according to the central limit theorem, the normal distribution of values was accepted. The relation between the presence of subconjunctival reflux and glaucoma, diabetes and phakic status was tested using Fisher's exact test. The correlation between the number of previous injections and increased IOP 5 min, 1 h and 15 days after injection was studied using the Pearson correlation coefficient. All p values were two-sided, and statistical significance was defined as $p < 0.05$.

Results

A total of 106 consecutive eyes of 79 patients (60.4% females) who received ≥ 1 intravitreal bevacizumab (1.25 mg/0.05 ml) injections were included in this study. Demographics and baseline characteristics for all patients receiving bevacizumab injections are presented in table 1. The patients' mean age was 70.61 ± 10.77 years (median 72.50), 20.8% had a history of glaucoma and 60.8% of type 2 diabetes, and 25.5% were pseudophakic. The mean number of total injections was 3.98 ± 3.06 (median 3).

Diabetic retinopathy was the most frequent disease in our study (fig. 1). IOP reached values ≥ 30 mm Hg in 40 eyes at 5 min following injection (37.8% of the sample) (fig. 2). IOP elevation occurred in 78.3% of the eyes at 5 min, in 29.2% at 1 h and in 21.1% at 15 days following injection (fig. 3).

IOP values were significantly higher 5 min [27.27 vs. 15.31 mm Hg, $t(105) = -11.496$; $p = 0.001$], 1 h [17.59 vs. 15.31 mm Hg, $t(105) = -4.829$; $p = 0.001$] as well as 15 days after injection [16.86 vs. 16.00 mm Hg, $t(75) = -2.146$; $p = 0.035$], although the sample size was smaller at this measurement (table 2).

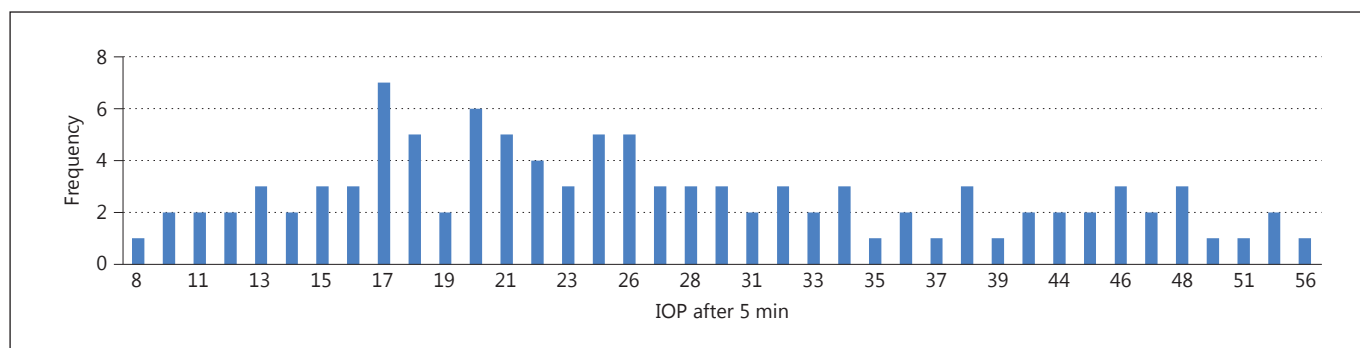


Fig. 2. IOP values after 5 min.

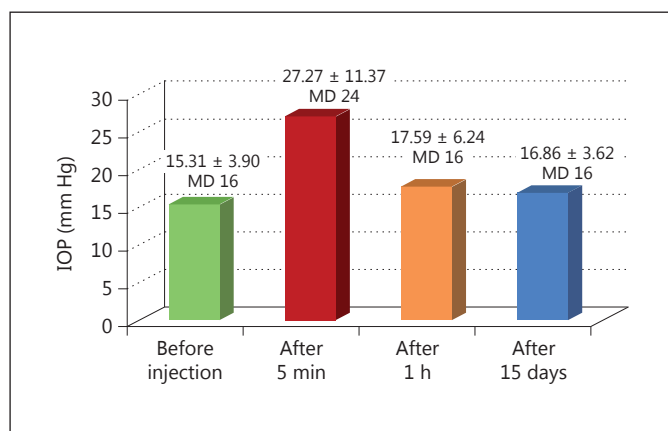


Fig. 3. Mean IOP at each measurement. MD = Median.

Table 2. Mean IOP (mm Hg) before and after injection

	Before injection	After injection	p
After 5 min			0.001
Mean ± SD	15.31±3.902	27.27±11.87	
Range	6–24	8–56	
After 1 h			0.001
Mean ± SD	15.31±3.902	17.59±6.24	
Range	6–24	6–36	
After 15 days			0.035
Mean ± SD	16.00±3.533	16.86±3.62	
Range	8–24	11–27	

Subconjunctival reflux occurred in 12 eyes, which represented 11.3% of the total study sample. The difference between IOPs before and 5 min after injection was significantly lower in patients with reflux than in those without reflux (−2.81 vs. 13.67, $Z = -5.237$; $p = 0.001$). The same was found 1 h after injection [−3.54 vs. 2.95, $t(104) = -4.576$; $p = 0.001$]. However, there was no statistically significant difference in IOP at 15 days between the two groups (−1.25 vs. 1.10; $Z = -1.830$; $p = 0.067$) (table 3). The subconjunctival reflux was more frequent in the superotemporal (11.8%) than in the inferotemporal (6.7%) approach.

The difference between pre- and postinjection IOP was tendentially higher in patients with glaucoma than in those without glaucoma at 5 min (12.90 vs. 11.71) and 1 h (3.59 vs. 1.94) after injection [$t(104) = 0.464$; $p = 0.644$ vs. $t(24.329) = 1.018$; $p = 0.319$, respectively]; 15 days after injection, this difference was greater in nonglaucomatous

patients (1.16 vs. −0.031), although not statistically significant [$t(74) = -1.526$; $p = 0.272$] (table 4).

Our sample showed a tendentially higher increase in IOP at 5 min, 1 h and 15 days after injection in nondiabetic than in diabetic patients [11.28 vs. 13.00, $t(104) = -0.807$; $p = 0.422$ vs. $t(104) = -1.566$; $p = 0.120$ vs. $t(74) = -0.702$; $p = 0.912$, respectively] (table 5).

The difference between the IOP before and 5 min, 1 h and 15 days after injection was tendentially higher in phakic eyes than in pseudophakic eyes [12.16 vs. 11.74, $t(103) = 0.177$; $p = 0.860$; 2.33 vs. 2.25, $t(103) = -0.068$; $p = 0.946$; 0.89 vs. 0.78, $t(73) = 0.111$; $p = 0.912$, respectively] (table 6).

The Pearson correlation between the number of previous injections and increased IOP 5 min ($r = 0.170$, $p = 0.082$), 1 h ($r = 0.105$, $p = 0.285$) and 15 days ($r = 0.022$, $p = 0.853$) after intravitreal injection was not statistically significant.

Seventy-six eyes were injected into the superotemporal quadrant and 30 eyes were injected into the inferotemporal quadrant. In the superotemporal subgroup, at

Table 3. IOP (mm Hg) and subconjunctival reflux

	Reflux	No reflux	p
Mean IOP ± SD before vs. after 5 min	-2.81±3.06	13.67±9.93	0.001
Mean IOP ± SD before vs. after 1 h	-3.54±3.32	2.95±4.56	0.001
Mean IOP ± SD before vs. after 15 days	-1.25±2.31	1.10±3.51	0.067

Table 4. IOP (mm Hg) and glaucoma

	Glaucoma	No glaucoma	p
Mean IOP ± SD before vs. after 5 min	12.90±12.03	11.71±10.40	0.644
Mean IOP ± SD before vs. after 1 h	3.59±7.32	1.94±3.97	0.319
Mean IOP ± SD before vs. after 15 days	-0.31±5.00	1.16±2.91	0.272

Table 5. IOP (mm Hg) and diabetes mellitus

	Diabetes	No Diabetes	p
Mean IOP ± SD before vs. after 5 min	11.28±10.46	13.00±11.12	0.422
Mean IOP ± SD before vs. after 1 h	1.68±4.65	3.19±5.10	0.120
Mean IOP ± SD before vs. after 15 days	0.62±3.79	1.19±2.97	0.485

Table 6. IOP (mm Hg) and phakic status

	Phakic	Pseudophakic	p
Mean IOP ± SD before vs. after 5 min	12.16±11.06	11.74±9.84	0.860
Mean IOP ± SD before vs. after 1 h	2.33±5.05	2.25±4.43	0.946
Mean IOP ± SD before vs. after 15 days	0.89±3.29	0.78±4.13	0.912

the 5-min measurement, an IOP increase of 10.12 mm Hg from baseline was observed and the mean IOP was 25.07 ± 10.79 mm Hg. Moreover, an IOP increase of 1.67 mm Hg was found 1 h after the injection and of 1.6 mm Hg 15 days after the injection. Using the inferotemporal approach, the 5-min measurement showed an IOP increase of 16.64 mm Hg from baseline and the mean IOP was 32.87 ± 12.81 mm Hg. Additionally, an IOP increase of 3.84 mm Hg was found 1 h after the injection and of 1.18 mm Hg 15 days after the injection. This change in IOP was statistically significant between all pre- and postinjection measurements (5 min, 1 h and 15 days; $p <$

0.05) using the superotemporal and inferotemporal approach. Subconjunctival reflux occurred in 11.8% of the superotemporal and in 6.7% of the inferotemporal subgroup.

The study of the probability of subconjunctival reflux occurrence and its relation with possible risk factors, including glaucoma (OR = 2.444; 95% CI = 0.646–9.255; $p = 0.234$), diabetes (OR = 0.508; 95% CI = 0.145–1.787; $p = 0.338$) and phakic status (OR = 3.824; 95% CI = 0.466–31.371; $p = 0.282$), revealed that none of these risk factors showed statistical significance ($p > 0.05$).

Discussion and Conclusion

The use of intravitreal antiangiogenic agents has assumed increasing importance and worldwide application in various vitreoretinal pathologies. Recent evidence suggests that both short-term and sustained IOP increases associated with anti-VEGF intravitreal injection therapy are of a real clinical concern [13].

In our study, at the 5-min measurement, an IOP increase of 11.96 mm Hg from baseline was observed and the mean IOP was 27.27 mm Hg (range between 8 and 56 mm Hg). An IOP increase of 2.28 mm Hg was found 1 h after the injection and of 1.55 mm Hg 15 days after the injection. This change in IOP was statistically significant between all pre- and postinjection measurements (5 min, 1 h and 15 days; $p < 0.05$).

IOP reached levels ≥ 30 mm Hg in more than one third of the patients (37.8%) within 5 min after intravitreal injection of bevacizumab. This pressure could affect the optic nerve by different pathophysiological mechanisms (mechanical direct effect and changes in perfusion pressure). Studies like those by Hollands et al. [3] and Kim et al. [10] also describe pressure peaks in the short-term postinjection period, which corroborates the fact that this increase in IOP can be transitory.

In any case, there is recent evidence suggesting that both IOP increases (short-term and persistent) related to intravitreal injections require a medical approach. Treating physicians should be aware of this infrequent complication and manage these occurrences appropriately.

Current evidence suggests that otherwise healthy eyes can tolerate a short-term IOP rise with no permanent effects on visual function [14]. However, the effects of these IOP spikes pose a real threat to the health of the optic nerve in individuals with advanced glaucomatous optic neuropathy. Prior studies have demonstrated clear visual field progression [15] and even loss of fixation [16] associated with short-term IOP spikes following cataract surgery.

Considerations for management include prophylactic IOP lowering with medicinal therapy and/or preinjection ocular decompression for patients with a history of glaucoma or ocular hypertension and switching to an as-needed injection protocol in patients suffering a sustained IOP rise [5]. However, according to El Chehab et al. [17], the administration of oral acetazolamide is ineffective in preventing these IOP peaks.

Another result that was achieved with statistical significance in our study was the occurrence of subconjunc-

tival reflux in 11.3% of eyes, which contributes to a smaller increase in IOP after injection when compared with patients who did not suffer a reflux ($p < 0.05$). In other studies, the subconjunctival reflux occurred in between 17 [18] and 38% [19] of the eyes. The presence of a subconjunctival reflux depended on the intravitreal injection technique (in order of decreasing reflux rate: straight, oblique and double-plane tunnel scleral [20]) and on the diameter of the needle (30 G causes less reflux than 27 G, particularly when the injection is not beveled [21]). Since the injected dose and volume of the drug as well as the injection technique and needle diameter were the same in all cases, it is unlikely that these variables were the cause of the IOP elevation. One of the limitations of this study is the qualitative evaluation of the subconjunctival reflux instead of a quantitative one.

None of the studied parameters, including diabetes mellitus, glaucoma, injection site (supero/inferotemporal) and number of injections, were statistically significant in this sample. The small sample of glaucoma patients (20.8%) and the no-show of 30 patients 15 days after the injection may have an impact on these results.

While more injections could be expected to lead to a direct toxic effect on aqueous outflow, causing chronic inflammation or trabeculitis, there was no evidence of anterior segment inflammation or synechiae in any of the eyes in this series. Moreover, no significant associations between increased IOP and mean number of injections were observed, leading us to conclude that this factor cannot be implicated as being causative for the elevated IOP in our study. This is in agreement with Good et al. [8] and Mathalone et al. [1] who also did not find the number of injections to be a risk factor for IOP elevation.

The relationship between the presence of subconjunctival reflux and potential risk factors was not statistically significant, which is in agreement with other studies [22]. However, the small number of reflux episodes may have influenced these results.

In conclusion, intravitreal injection of bevacizumab led to an IOP increase of about 14 mm Hg 5 min after the injection, in the absence of subconjunctival reflux. This IOP increase, although lower, was also observed at 15 days indicating that these eyes may be targets of optic nerve damage beyond the immediate postinjection period. For this reason, the authors of this study recommend the implementation of the aforementioned measures of prevention, especially in patients with a history of glaucoma or ocular hypertension, and switching to an as-needed injection protocol (the eyes should be injected in the presence of choroidal neovascularization activity: subretinal/intraret-

inal activity, loss of >5 letters in the best visual acuity or persistent/recurrent retinal hemorrhage) in patients who have suffered a marked rise in IOP in previous injections. The safety and efficacy of a flexible dosing regimen of ranibizumab in neovascular age-related macular degeneration (SUSTAIN study) revealed similar results in a phase III, multicenter trial in which patients were retreated with injection therapy based on prespecified criteria, termed as the 'as-needed' or 'pro re nata' protocol [23].

An IOP increase due to an increase in intraocular volume subsequent to an intravitreal injection is inevitably linked to the elasticity of both ocular tissues. One way to study this in the clinical setting is by using a dynamic contour tonometer and through ocular pulse amplitude analysis. This variable reflects not only the amplitude in cho-

roidal flow during a cardiac cycle, but can also give an indirect insight into the ocular compliance. As the substances injected in this study (anti-VEGF) may have an effect on ocular blood flow, ocular pulse amplitude is a particularly suitable parameter for future research in this field of study [24, 25].

Prospective studies with complementary diagnosis exams of the retinal ganglion cell layer are also needed to investigate and document this possibly irreversible damage to the optic nerve.

Disclosure Statement

The authors declare that they have no competing interests.

References

- 1 Mathalone N, Arodi-Golan A, Sar S, Wolfson Y, Shalem M, Lavi I, Geyer O: Sustained elevation of intraocular pressure after intravitreal injections of bevacizumab in eyes with neovascular age-related macular degeneration. *Graefes Arch Clin Exp Ophthalmol* 2012;250:1435–1440.
- 2 CATT Research Group, Martin DF, Maguire MG, Ying GS, Grunwald JE, Fine SL, Jaffe GJ: Ranibizumab and bevacizumab for neovascular age-related macular degeneration. *N Engl J Med* 2011;364:1897–1908.
- 3 Hollands H, Wong J, Bruen R, Campbell RJ, Sharma S, Gale J: Short term intraocular pressure changes after intravitreal injection of bevacizumab. *Can J Ophthalmol* 2007;42:807–811.
- 4 Bakri SJ, Pulido JS, McCannel CA, Hodge DO, Diehl N, Hillemeier J: Immediate intraocular pressure changes following intravitreal injections of triamcinolone, pegaptinib, and bevacizumab. *Eye (Lond)* 2009;23:181–185.
- 5 Aref AA: Management of immediate and sustained intraocular pressure rise associated with intravitreal anti-vascular endothelial growth factor injection therapy. *Curr Opin Ophthalmol* 2012;23:105–110.
- 6 Rosenfeld PJ, Brown DM, Heier JS, et al: Ranibizumab for neovascular age-related macular degeneration. *N Engl J Med* 2006;355:1419–1431.
- 7 Brown DM, Kaiser PK, Michels M, et al: Ranibizumab versus verteporfin for neovascular age-related macular degeneration. *N Engl J Med* 2006;355:1432–1444.
- 8 Good TJ, Kimura AE, Mandava N, Kahook MY: Sustained elevation of intraocular pressure after intravitreal injections of anti-VEGF agents. *Br J Ophthalmol* 2011;95:1111–1114.
- 9 Gismondi M, Salati C, Salvat ML, et al: Short-term effect of intravitreal injection of ranibizumab on intraocular pressure. *J Glaucoma* 2009;18:658–661.
- 10 Kim JE, Mantravadi AV, Hur EY, Covert DJ: Short-term intraocular pressure changes immediately after intravitreal injections of anti-vascular endothelial growth factor agents. *Am J Ophthalmol* 2008;146:930–934.
- 11 Falkenstein IA, Cheng L, Freeman WR: Changes of intraocular pressure after intravitreal injection of bevacizumab. *Retina* 2007;27:1044–1047.
- 12 Michelson G, Groh MJ, Langhans M: Perfusion of the juxtapapillary retina and optic nerve head in acute ocular hypertension. *Ger J Ophthalmol* 1996;5:315–321.
- 13 Menke MN, et al: Long-term intraocular pressure changes in patients with neovascular age-related macular degeneration treated with ranibizumab. *Ophthalmologica* 2013;229:168–172.
- 14 Tranos P, Bhar G, Little B: Postoperative intraocular pressure spikes: the need to treat. *Eye (Lond)* 2004;18:673–679.
- 15 Savage JA, Thomas JV, Belcher CD 3rd, Simmons RJ: Extracapsular cataract extraction and posterior chamber intraocular lens implantation in glaucomatous eyes. *Ophthalmology* 1985;92:1506–1516.
- 16 Kolker AE: Visual prognosis in advanced glaucoma: a comparison of medical and surgical therapy for retention of vision in 101 eyes with advanced glaucoma. *Trans Am Ophthalmol Soc* 1977;75:539–555.
- 17 El Chehab H, Le Corre A, Giraud JM, Ract-Madou G, Swalduz B, Dot C: Efficacy of prophylactic treatment of intraocular pressure spikes due to intravitreal injections (in French). *J Fr Ophthalmol* 2012;35:614–621.
- 18 Saeed MU, Qureshi F, Batra R, Clark D: Effect of reflux drug during intravitreal anti-VEGF therapies on foveal thickness. *Semin Ophthalmol* 2011;26:61–63.
- 19 Lorenz K, Zwiener I, Mirshahi A: Subconjunctival reflux and need for paracentesis after intravitreal injection of 0.1 ml bevacizumab: comparison between 27-gauge and 30-gauge needle. *Graefes Arch Clin Exp Ophthalmol* 2010;248:1573–1577.
- 20 Özkaya A, Alkin Z, Celik U, Yüksel K, Özgürhan EB, Ağca A, Yazici AT, Demirok A: Comparing the effects of three different intravitreal injection techniques on vitreous reflux and intraocular pressure. *J Ocul Pharmacol Ther* 2013;29:325–329.
- 21 Rodrigues EB, Grumann A Jr, Penha FM, Shirota H, Rossi E, Meyer CH, Stefano V, Maia M, Magalhaes O Jr, Farah ME: Effect of needle type and injection technique on pain level and vitreal reflux in intravitreal injection. *J Ocul Pharmacol Ther* 2011;27:197–203.
- 22 Saeed MU, Batra R, Qureshi F, Clark D: Reflux of drug during intra-vitreal anti-VEGF therapies. *Semin Ophthalmol* 2011;26:357–360.
- 23 Holz FG, Amoaku W, Donate J, Guymer RH, Kellner U, Schlingermann RO, Weichselberger A, Staurenghi G: Safety and efficacy of a flexible dosing regimen of ranibizumab in neovascular age-related macular degeneration: the SUSTAIN study. *Ophthalmology* 2011;118:663–671.
- 24 Abegão Pinto L, Vandewalle E, Willekens K, Marques-Neves C, Stalmans I: Ocular pulse amplitude and Doppler waveform analysis in glaucoma patients. *Acta Ophthalmol* 2014;92:e280–e285.
- 25 Stalmans I, Harris A, Vanbellinghen V, Zeyen T, Siesky B: Ocular pulse amplitude in normal tension and primary open angle glaucoma. *J Glaucoma* 2008;17:403–407.