

Author Query Form

Journal Title : JCN
Article Number : 429856


Dear Author/Editor,

Greetings, and thank you for publishing with SAGE Publications. Your article has been copyedited, and we have a few queries for you. Please address these queries when you send your proof corrections to the production editor. Thank you for your time and effort.

Please assist us by clarifying the following queries:

No.	Query	Remarks
1	Please check the quality of all figures and confirm that you approve how they appear in the article. If the quality is too low, please send a high-quality original file when you submit your corrections and answers to queries.	
2	Please verify that the existing conflict of interest statement is accurate and correct.	
3	Please verify that the existing funding disclosure is accurate and correct.	

Primary Ciliary Dyskinesia and Hydrocephalus With Aqueductal Stenosis

Journal of Child Neurology
00(0) 1-4
© The Author(s) 2011
Reprints and permission:
sagepub.com/journalsPermissions.nav
DOI: 10.1177/0883073811429856
http://jcn.sagepub.com


AQ1

José Pedro Vieira, MD¹, Patricia Lopes, MD¹, and Rita Silva, MD¹

Abstract

We report 1 female patient with situs inversus, dextrocardia, a complex heart malformation, hydrocephalus due to aqueductal stenosis, and abnormal ultrastructure of the respiratory epithelium cilia. Several animal models of this disorder implicate abnormal ciliary function in the genesis of hydrocephalus, and 11 patients were previously reported with hydrocephalus and the syndrome of primary ciliary dyskinesia. Primary ciliary dyskinesia–associated aqueductal stenosis should be considered as a possible cause for fetal or neonatal hydrocephalus if heterotaxy, heart malformations, and/or a probable genetic etiology are present.

Keywords

Primary ciliary dyskinesia, hydrocephalus, aqueductal stenosis

Received April 05, 2011. Received revised October 14, 2011. Accepted for publication October 19, 2011.

Diseases that affect cilia became recently the object of considerable interest. Disturbed ciliary function underlies some human diseases of the brain, retina, respiratory system, liver, and kidney although their pathophysiology is incompletely understood.¹

It is known for decades that abnormal structure and function of cilia is the basis for Kartagener syndrome, now referred to as primary ciliary dyskinesia. The clinical spectrum for this disorder includes sinusitis, bronchitis, dextrocardia, situs inversus, and infertility. A few cases were reported with prenatal or neonatal hydrocephalus.²⁻⁷ Ependymal cells that line the ventricular system have cilia, their movement may be important for the flow of cerebrospinal fluid in the aqueduct of Sylvius, and their abnormal function may cause hydrocephalus⁸; investigations studying hydrocephalus associated with hop gait (hyh), a recessive disease of mice, support the view that abnormal epithelial lining of the ventricular system is a precursor of hydrocephalus.⁹

We report our observation of a female newborn with dextrocardia, a complex heart malformation, situs inversus, chronic low-grade hydrocephalus due to aqueductal stenosis, and abnormal ciliary ultrastructure. Our work is based on data from the patient's clinical files and received Ethics Committee approval.

Case Report

Our patient was a female, the first child of healthy, second-degree consanguineous parents of Gypsy ethnic origin. There

was no family history of congenital malformations or of neurologic disease. The mother had not been exposed during pregnancy to tobacco smoking, alcohol, ionizing radiation, or drugs, either of prescription or illicit, and had no intercurrent febrile illnesses or gestational diabetes. She had regular medical surveillance by her primary care practitioner without any apparent complication until the 21st week. Fetal ultrasound was performed at this time and revealed cardiomegaly without signs of congestive heart failure. She was then referred to our obstetric unit; serial fetal echocardiograms were performed every 2 weeks and revealed congenital atrioventricular block and a possible right heart malformation. Extensive laboratory investigations failed to reveal any autoimmune or infectious disease during pregnancy.

The child's delivery was at 38 weeks by elective cesarean section. This female newborn had a birth weight of 3040 g, length 48.1 cm, and head circumference 35.0 cm. Apgar index was 8 at 1 minute and 9 at 5 minutes but, because of persistent bradycardia due to atrioventricular block, she was admitted to our neonatal intensive care unit. Cardiologic evaluation

¹ Department of Neurology, Hospital de Dona Estefânia, Centro Hospitalar de Lisboa Central, Lisbon, Portugal

Corresponding Author:

José Pedro Vieira, MD, Department of Neurology, Hospital de Dona Estefânia, Centro Hospitalar de Lisboa Central, Rua Jacinta Marto, 1159045 Lisbon, Portugal
Email: jose.vieira@chlc.min-saude.pt

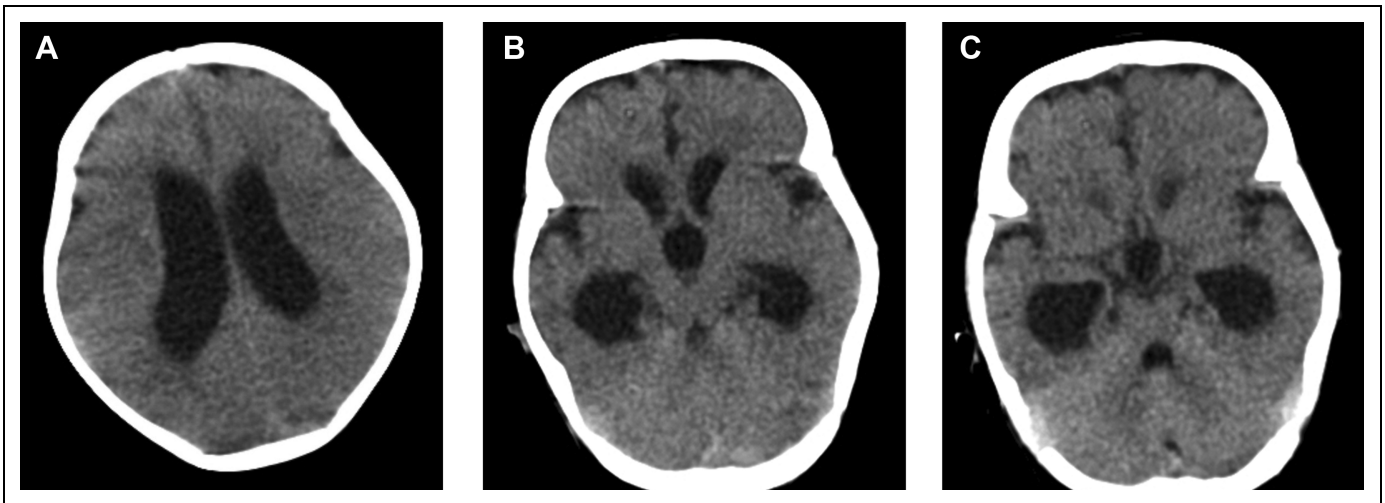


Figure 1. (A) Head computed tomographic (CT) scan showing hydrocephalus with dilated lateral ventricles. (B) Head CT scan showing dilated lateral and third ventricles. (C) Head CT scan showing dilated temporal horns of the lateral ventricles and small fourth ventricle.

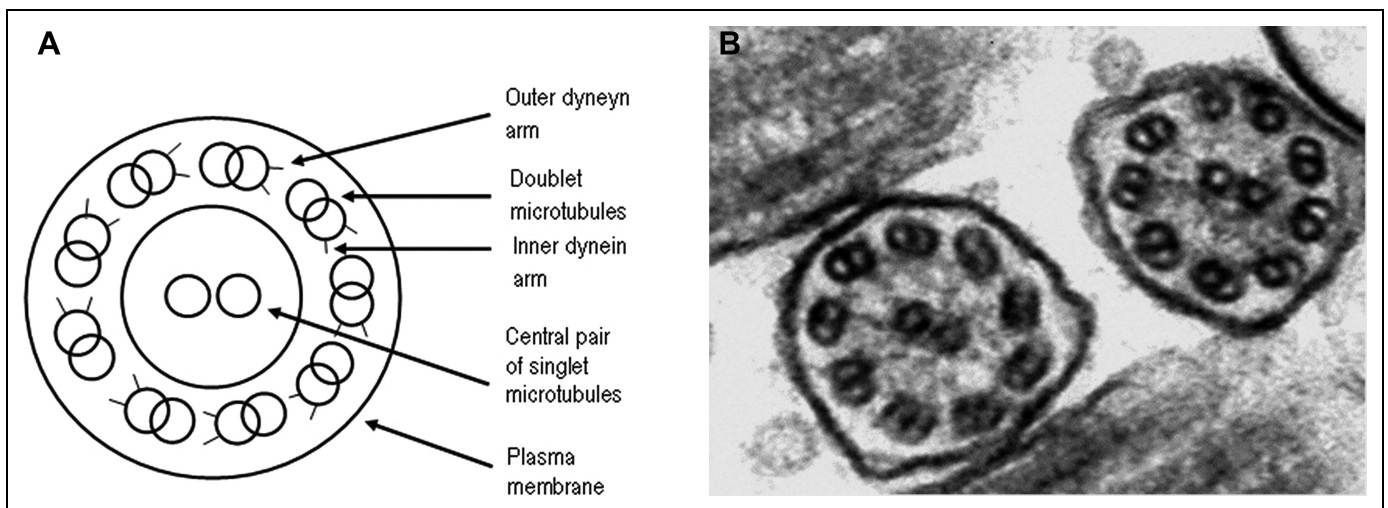


Figure 2. (A) Scheme of normal ciliary ultrastructure. (B) Electron microscopic image of the patient's respiratory epithelium cilia showing abnormal microtubules with absent inner and outer dynein arms.

revealed a complex heart malformation (dextrocardia, common atrium, and patent ductus arteriosus); the patient also had situs inversus totalis and intestinal malrotation and was transferred to the pediatric cardiology unit. At 35 days of age, 12 days after elective cardiac surgery, she was in cardiorespiratory failure, dependent on mechanical ventilation, had infectious endocarditis, and required major abdominal surgery because of necrotizing enterocolitis. Neurologic evaluation was then requested because further efforts at treatment were considered to be dependent, at least partially, on prognosis regarding neurologic function.

There were no facial or limb malformations. Anterior fontanel was slightly tense. Sutures were not diastatic. Head circumference was 36 cm. Despite being sedated, the child had periods of wakefulness and moved the limbs symmetrically. Cranial nerve examination was normal. Tone was slightly increased

in the lower limbs and reflexes were brisk. Ankle clonus was not present.

Because of the possible abnormal tension of the fontanel, a computed tomographic (CT) scan was performed and revealed a triventricular hydrocephalus. The lateral and third ventricles were visibly enlarged (Figure 1A and B). The fourth ventricle was small (Figure 1C). Hydrocephalus seemed to be low grade or arrested because there was no periventricular hypodensity related to transependymal reabsorption of cerebrospinal fluid. No other central nervous system abnormalities were apparent.

The patient's nasal mucosa cells were studied ultrastructurally and showed abnormal cilia consistent with a diagnosis of primary ciliary dyskinesia (Figure 2).

Despite all efforts, the child died at the age of 182 days of cardiorespiratory failure. Only some exons of the *DNAI1* and

DNAH5 genes were investigated because DNA available for these studies was insufficient; no mutation was found.

Discussion

Ciliary motility is needed for the determination of right-left asymmetry during embryonic development, for the adequate functioning of epithelial cells of the respiratory tract, and for the motility of gamete. More recently, there is also evidence that the function of the retina, liver, and kidneys is also affected by abnormal cilia.¹

Neuropathologic studies of hydrocephalus reveal that increased intraventricular pressure causes damage to ependymal cells and disturbs ciliary function.¹⁰

There is nevertheless convincing evidence from experimental studies of hydrocephalus in mice with ciliary dyskinesia that ciliary dysfunction is, in these cases, the cause rather than the consequence of hydrocephalus probably because ciliary beating is needed for cerebrospinal fluid flow, especially in the aqueduct of Sylvius. In addition, in a critical period of development, this dysfunction may lead to abnormal aqueductal morphology.^{8,11,12}

In mice, mutations in *Hydin*, *Pcdp1*, and *Mdnah5* genes determine abnormal ciliary function and prenatal hydrocephalus.^{8,11,12} The *Mdnah5* gene is homologous of the human *DNAH5* gene, mutated in some patients with primary ciliary dyskinesia. It must be mentioned that in all animal models of these genetic disorders, the type of hydrocephalus implicated is aqueductal stenosis. In human primary ciliary dyskinesia, mutations in *DNAI1* and *DNAH5* genes were identified earlier although others may be implicated.¹

Six reports described 11 patients with fetal ventriculomegaly or hydrocephalus with onset in infancy, associated with primary ciliary dyskinesia²⁻⁷: 5 cases were isolated, and 6 occurred in 2 families. Four patients had dextrocardia, situs inversus, or heart malformations; 1 fetus had a 3-lobed left lung. Hydrocephalus was diagnosed either prenatally (at 19th and 29th weeks' gestation) or in early postnatal life (always before 5 months). Aqueductal stenosis was explicitly reported in 2 cases,^{3,4} is implicit in the report by Kosaki², and was also present in our patient. The other patients either were studied with CT but all that is mentioned is "enlarged lateral ventricles"⁵ or the diagnosis of hydrocephalus was based on fetal ultrasound and were reported without information on the type of hydrocephalus.⁶ We did not have access to the report by Picco et al.⁷

One study estimated the incidence of fetal/congenital hydrocephalus at 0.82/1000 live births.¹³ Others have found a lower incidence of 0.46/1000, but hydrocephalus associated with neural tube defects was not included.¹⁴ Developmental anomalies stand as the major cause of fetal hydrocephalus, and several investigators considered that aqueductal stenosis was a major cause of hydrocephalus identified at birth (33%).^{15,16} Congenital hydrocephalus is genetic in 2% to 15% of cases.¹⁷ Although X-linked hydrocephalus due to *LICAM* mutations is the most commonly recognized cause, there are in the literature very rare cases of autosomal recessive¹⁸⁻²⁰ and 2 reports of families

with apparently autosomal dominant^{21,22} hydrocephalus with aqueductal stenosis. One family with autosomal dominant hydrocephalus had in addition a situs inversus anomaly.²¹

Several reports on the outcome of a considerable number of children with a previous diagnosis of isolated fetal ventriculomegaly did not identify patients with ciliary dyskinesia.²³ Moreover, all patients with hydrocephalus and primary ciliary dyskinesia previously described had heterotaxy and/or heart malformations. It is therefore unlikely that primary ciliary dyskinesia is responsible for a considerable number of cases of isolated unexplained hydrocephalus.

We think that our patient and others previously reported nevertheless constitute evidence for a rare etiology of prenatal or early-onset postnatal, autosomal recessive hydrocephalus.

The diagnosis of primary ciliary dyskinesia-associated hydrocephalus should be considered when fetal ventriculomegaly or hydrocephalus with aqueductal stenosis at birth or in early life are found in association with heterotaxy or heart malformations and/or a genetic autosomal recessive pattern of inheritance is likely.

Finally, evidence that ciliary dyskinesia may be implicated in aqueductal stenosis is 1 interesting hypothesis on the pathophysiology of hydrocephalus.

Acknowledgment

The authors would like to thank Dr. J Moura Nunes who performed the ultrastructural study of the respiratory cilia.

Author Contributions

JPV was responsible for general conception of the article, wrote the first draft, and performed a final review of the manuscript. PL and RS were involved in clinical care of the patient, wrote the case report, and collaborated in the review of the manuscript.

Declaration of Conflicting Interests

The authors declared no potential conflicts of interest with respect to the research, authorship, and/or publication of this article.

Funding

The authors received no financial support for the research, authorship, and/or publication of this article.

Ethical Approval

This work was approved by the Ethics Committee of Centro Hospitalar de Lisboa Central.

References

1. Bush A, Chodhari R, Collins N, et al. Primary ciliary dyskinesia: current state of the art. *Arch Dis Child*. 2007;92(12):1136-1140.
2. Kosaki K, Ikeda K, Miyakoshi K, et al. Absent inner dynein arms in a fetus with familial hydrocephalus-situs abnormality. *Am J Med Genet A*. 2004;129A(3):308-311.
3. De Santi MM, Magni A, Valletta EA, Gardi C, Lungarella G. Hydrocephalus, bronchiectasis, and ciliary aplasia. *Arch Dis Child*. 1990;65(5):543-544.
4. Greenstone MA, Jones RW, Dewar A, Neville BG, Cole PJ. Hydrocephalus and primary ciliary dyskinesia. *Arch Dis Child*. 1984;59(5):481-482.

AQ2

AQ3

5. al-Shroof M, Karnik AM, Karnik AA, Longshore J, Sliman NA, Khan FA. Ciliary dyskinesia associated with hydrocephalus and mental retardation in a Jordanian family. *Mayo Clin Proc.* 2001;76(12):1219-1224.
6. Wessels MW, den Hollander NS, Willems PJ. Mild fetal cerebral ventriculomegaly as a prenatal sonographic marker for Kartagener syndrome. *Prenat Diagn.* 2003;23(3):239-242.
7. Picco P, Leveratto E, Cama A, et al. Immotile cilia syndrome associated with hydrocephalus and precocious puberty. *Eur J Pediatr Surg.* 1993;3(suppl 1):20-21.
8. Ibañez-Tallon I, Pagenstecher A, Fliegauf M, et al. Dysfunction of axonemal dynein heavy chain Mdnah5 inhibits ependymal flow and reveals a novel mechanism for hydrocephalus formation. *Hum Mol Genet.* 2004;13(18):2133-2141.
9. Páez P, Bátiz LF, Roales-Buján R, et al. Patterned neuropathologic events occurring in hyh congenital hydrocephalic mutant mice. *J Neuropathol Exp Neurol.* 2007;66(12):1082-1092.
10. Bannister CM, Chapman SA. Ventricular ependyma of normal and hydrocephalic subjects: a scanning electron microscopic study. *Dev Med Child Neurol.* 1980;22(6):725-735.
11. Lee L, Campagna DR, Pinkus JL, et al. Primary ciliary dyskinesia in mice lacking the novel ciliary protein Pcdp1. *Mol Cell Biol.* 2008;28(3):949-957.
12. Lechtreck KF, Delmotte P, Robinson ML, et al. Mutations in Hydin impair ciliary motility in mice. *J Cell Biol.* 2008;180(3):633-643.
13. Persson EK, Hagberg G. Hydrocephalus prevalence and outcome in a population-based cohort of children born in 1989-1998. *Acta Paediatr.* 2005;94(6):726-732.
14. Garne E, Loane M, Addor MC, et al. Congenital hydrocephalus—prevalence, prenatal diagnosis and outcome of pregnancy in four European regions. *Eur J Paediatr Neurol.* 2010;14(2):150-155.
15. Mealey J, Jr, Gilmore RL, Bubb MP. The prognosis of hydrocephalus overt at birth. *J Neurosurg.* 1973;39(3):348-355.
16. McCullough DC, Balzer-Martin LA. Current prognosis in overt neonatal hydrocephalus. *J Neurosurg.* 1982;57(3):378-383.
17. Zhang J, Williams MA, Rigamonti D. Genetics of human hydrocephalus. *J Neurol.* 2006;253(10):1255-1266.
18. Castro-Gago M, Alonso A, Eirís-Puñal J. Autosomal recessive hydrocephalus with aqueductal stenosis. *Childs Nerv Syst.* 1996;12(4):188-191.
19. Lapunzina P, Delicado A, de Torres ML, Mor MA, Pérez-Pacheco RF, López PI. Autosomal recessive hydrocephalus due to aqueduct stenosis: report of a further family and implications for genetic counselling. *J Matern Fetal Neonatal Med.* 2002;12(1):64-66.
20. Hamada H, Watanabe H, Sugimoto M, Yasuoka M, Yamada N, Kubo T. Autosomal recessive hydrocephalus due to congenital stenosis of the aqueduct of Sylvius. *Prenat Diagn.* 1999;19(11):1067-1069.
21. Verhagen WI, Bartels RH, Fransen E, van Camp G, Renier WO, Grotenhuis JA. Familial congenital hydrocephalus and aqueduct stenosis with probably autosomal dominant inheritance and variable expression. *J Neurol Sci.* 1998;158(1):101-105.
22. Al-Anazi AR. Adult onset hydrocephalus and situs inversus: new autosomal dominant syndrome? *Br J Neurosurg.* 2003;17(3):263-266.
23. Laskin MD, Kingdom J, Toi A, Chitayat D, Ohlsson A. Perinatal and neurodevelopmental outcome with isolated fetal ventriculomegaly: a systematic review. *J Matern Fetal Neonatal Med.* 2005;18(5):289-298.