

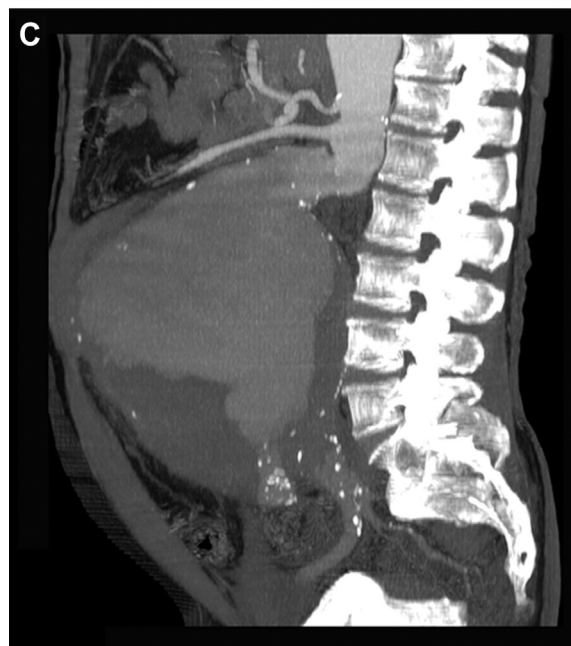
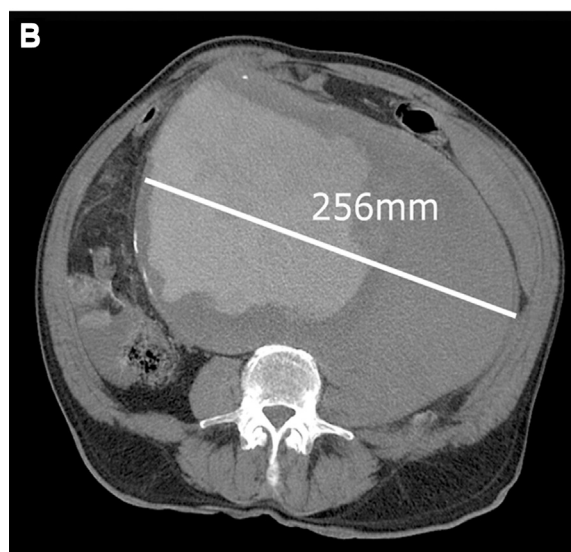
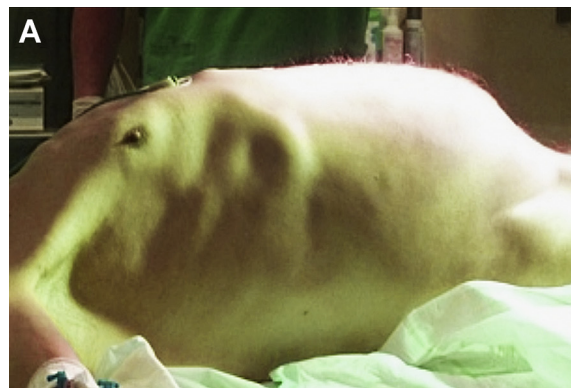Giant aneurysm of the abdominal aorta

Hugo Rodrigues, MD,^a Frederico Bastos Gonçalves, MD,^{a,b} and Maria Emília Ferreira, MD,^a
Lisbon, Portugal; and Rotterdam, The Netherlands

A 79-year-old man with a history of smoking, hypertension, chronic pulmonary disease, and nondisabling stroke was admitted to the emergency department due to loss of consciousness and diffuse abdominal pain. At admission, the patient was vigilant but hypotensive (90/60 mm Hg) and tachycardic (107 bpm). Physical examination revealed a tender, pulsatile mass occupying the entire abdomen (A). His hemoglobin level was 6.5 g/dL. Computed tomographic angiography revealed a giant infrarenal aortic aneurysm with a maximum transverse diameter of 256 mm (B and C). A small layer of blood was visible in the left retroperitoneal space. Considerable displacement of the mesentery and left kidney was evident after postprocessing reconstruction (D).

Anatomic constraints, which included a severely angulated, wide conical infrarenal neck, tortuous iliac arteries, and wide aortic lumen, precluded endovascular repair. The patient underwent emergency open repair through a transperitoneal midline approach. Temporary suprarenal aortic clamping was necessary for proximal control. After evacuation of the aneurysm sac content, an inlay aorto-aortic Dacron graft reconstruction was performed (E). Despite prolonged hospitalization due to respiratory complications and transient renal deterioration, the patient was discharged home after 39 days.

The rupture risk of abdominal aortic aneurysms is intimately associated with the maximum diameter. However, other factors are known to influence the risk of rupture, and individual variability is considerable.¹ Current recommendations advise repair for aneurysms >5.5 cm in diameter.² For aneurysms >6 cm, the annual rupture risk exceeds 14%.³ Therefore, it is rare to encounter very large aneurysms (>10 cm); most would have previously ruptured or undergone repair. Unidentified protective factors for rupture possibly may allow aneurysms to occasionally grow insidiously to extreme dimensions. Although open repair may present significant technical difficulties, endovascular repair with current endovascular devices is frequently impossible due to anatomic limitations. To our knowledge, this case represents the largest abdominal aortic aneurysm ever reported.



From the Department of Angiology and Vascular Surgery, Hospital de Santa Marta, Centro Hospitalar Lisboa Central, Lisbon^a; and the Department of Vascular Surgery, Erasmus University Medical Center, Rotterdam.^b

Author conflict of interest: none.

E-mail: fredericobastosgoncalves@gmail.com.

Additional material for this article may be found online at www.jvascsurg.org.

The editors and reviewers of this article have no relevant financial relationships to disclose per the JVS policy that requires reviewers to decline review of any manuscript for which they may have a conflict of interest.

J Vasc Surg 2014;59:826-7

0741-5214/\$36.00

Copyright © 2014 by the Society for Vascular Surgery.

<http://dx.doi.org/10.1016/j.jvs.2012.09.010>

REFERENCES

1. Brown LC, Powell JT. Risk factors for aneurysm rupture in patients kept under ultrasound surveillance. UK Small Aneurysm Trial Participants. *Ann Surg* 1999;230:289-96; discussion: 296-7.
2. Chaikof EL, Brewster DC, Dalman RL, Makaroun MS, Illig KA, Sicard GA, et al. The care of patients with an abdominal aortic aneurysm: the Society for Vascular Surgery practice guidelines. *J Vasc Surg* 2009;50(4 Suppl):S2-49.
3. Brown PM, Zelt DT, Sobolev B. The risk of rupture in untreated aneurysms: the impact of size, gender, and expansion rate. *J Vasc Surg* 2003;37:280-4.

Submitted Sep 7, 2012; accepted Sep 13, 2012.

