

*Reprint from*

# Cancer of the Head and Neck

*Paper presented at the International Workshop on Cancer  
of the Head and Neck, New York City, May 10–14, 1965*

Washington  
BUTTERWORTHS

1967

## SURGICAL INDICATIONS FOR HEAD AND NECK TUMORS IN CHILDREN

ANTÓNIO GENTIL MARTINS

The field of Pediatric Cancer is an ever growing one. Its importance is caused not only by the increased incidence, which to a certain extent runs parallel to that of congenital malformations, but by the significant rise in its percentage as a cause of death in the pediatric age group (0-14 years), now that infectious diseases are better controlled. It is given importance also by the increased awareness of doctors in its existence. Above all however, its importance is due to the fact that childhood tumors are no longer doomed to a hopeless prognosis.

### INCIDENCE AND TYPES OF JUVENILE TUMORS

It is extremely important that everyone realizes that childhood cancer can be cured in the same way as that in an adult. For this reason it is most important that pediatricians should become 'cancer minded.' Children's tumors are by no means a rarity: in the last 10 years 237 children with malignant tumors were seen at the Portuguese Cancer Institute. About one-third of these tumors were located in the head and neck (*Table 1*).

It is true that the type of tumors that are normally seen at a given Hospital sometimes does not reflect the true incidence of those tumors but rather the particular local interests and tendencies. At the beginning of 1960 a separate Department of Pediatric Cancer, one of the first of its kind in Europe, was opened at the Portuguese Cancer Institute in Lisbon, resulting in a marked increase in the number of pediatric neoplasms seen in that Hospital (1955/59 = 89; 1960/64 = 147).

Contrary to what happens in adults, in whom epithelial tumors are by far the most common (around 90 per cent of all tumors), they are extremely rare in children. If we exclude our patients suffering from xeroderma pigmentosum, only 8 per cent of our patients with malignant tumors belong to that group. In children the various types of sarcomas, embryomas, and teratoid tumors predominate. An ulcerated skin tumor in this age group is more often originated in the deeper structures; in fact it is usually a sarcoma of soft somatic tissues rather than an epithelioma.

If certain tumors, such as retinoblastoma, are discovered mostly during the first four or five years, lymphosarcoma, reticulum-cell sarcoma and thyroid tumors become more frequent thereafter. From a predominance of sarcomas we progressively change into an adult pattern at the end of puberty.

TABLE 1  
TUMORS OF THE HEAD AND NECK  
Portuguese Cancer Institute, 1955-1964

<i>Topographic distribution by age (years)</i>	<i>0-1</i>	<i>1-4</i>	<i>5-9</i>	<i>10-14</i>	<i>Total</i>
Eye.....	2	25	6	1	34
Bones.....	—	3	—	8	11
Soft somatic tissues.....	—	4	3	3	10
Oral cavity and pharynx.....	—	1	5	3	9
Lymphatic system.....	—	1	1	4	6
Skin.....	—	1	1	1	3
Thyroid gland.....	—	—	—	2	2
Xeroderma (multiple tumors).....	—	1	3	2	6
<i>Total.....</i>	<i>2</i>	<i>36</i>	<i>19</i>	<i>24</i>	<i>81</i>
<i>Histologic types by age</i>					
Retinoblastoma.....	1	24	6	1	32
Sympathicoblastoma.....	—	1	—	—	1
Malignant neurinoma.....	—	—	—	1	1
Reticulosarcoma.....	—	1	3	7	11
Hodgkin's disease (localized).....	—	—	1	—	1
Reticuloendothelioses.....	—	1	—	—	1
Malignant hemangioendothelioma.....	—	—	1	1	2
Embryonal rhabdomyosarcoma.....	—	1	2	—	3
Fibromyxosarcoma.....	—	—	1	1	2
Myxosarcoma.....	—	1	—	—	1
Liposarcoma.....	—	1	—	—	1
Osteosarcomas and condrosarcomas.....	—	—	—	4	4
Undifferentiated sarcoma.....	—	1	—	—	1
Undifferentiated adenocarcinoma (of the thyroid gland).....	—	—	—	1	1
Papillary adenocarcinoma (of the Thyroid gland).....	—	—	—	1	1
Malignant melanoma.....	—	—	—	1	1
Squamous and basal cell carcinoma.....	—	1	1	3	5
Squamous and basal cell carcinoma, melanoma, (xeroderma).....	—	1	3	2	6
No histology available.....	1	2	2	1	6
<i>Total.....</i>	<i>2</i>	<i>36</i>	<i>19</i>	<i>24</i>	<i>81</i>

## PATHOGENESIS

### Hormonal factors

Although not explainable in the light of our present knowledge, there is normally a decrease in incidence of malignant neoplasms during the prepubertal period. That this low incidence may be related to hormonal factors is a distinct possibility.

### Heredity

Heredity seems to play an important role in certain head and neck tumors in children, considering that retinoblastoma and xeroderma pigmentosum are usually detected in this age group.

## Location

As far as location is concerned many differences exist between children and adults. Central nervous system tumors (including retinoblastoma), soft tissue tumors, and tumors of the lymphatic and hematopoietic systems predominate in children, but on the other hand neoplasms of the skin, larynx, or esophagus are certainly a rarity.

## DIFFERENTIAL DIAGNOSIS

Some tumors in children may present at birth or at least appear during the first months of life: it is therefore essential that the possibility of a malignant tumor be considered in the differential diagnosis of any head and neck lump. The high frequency of inflammatory tumors about the head and neck in children and particularly their altered evolution brought about by the use of antibiotics, together with the high frequency of tumorous congenital malformations about that region, make differential diagnosis sometimes exceedingly difficult. Cervical lymphadenopathy, particularly when unilateral and painless, must always arouse suspicion, for lymphosarcoma, reticulum-cell sarcoma, localized Hodgkin's disease, metastatic thyroid carcinoma, and so on, may be present.

A short waiting period under close observation is normally indicated, although too much delay may often lead to disaster. Not more than a few weeks should elapse before a biopsy is performed for a lump the origin of which has not become obvious during that period.

## Aspiration biopsy

Aspiration biopsy is particularly valuable, especially as an office or out-patient procedure. It may not only determine the presence of pus, blood, or other liquid but may also obtain a small specimen for cytological or histological examination.

## Surgical biopsy

Surgical biopsy should be planned so as to be directed towards the main lesion and performed in a place where its scar may easily be excised at the time of definitive surgery if this is required. The incision should fall into the natural skin creases, attempting as much as possible to follow the concept of the esthetic units of the face. Biopsy performed on a benign lesion should leave no more than a negligible scar. Cosmetic reasons alone, particularly in female patients, should not deter one from performing a timely biopsy which, whenever possible, should be of the 'total excision' type.

Often, particularly in smaller children, biopsy is better performed under general anesthesia because, if the possibility of immediate pathologic study through quick frozen-sections is available, definitive surgery can then be carried out if necessary.

Considering that it is the only way of obtaining a correct histological diagnosis, essential for instituting the right therapy, the role of biopsy cannot be

overemphasized. All tissues removed at biopsy or operation, no matter how benign they may seem or how convinced one is of the diagnosis, must always be sent for histological examination.

### **Histology**

One aspect that needs to be emphasized is that the histological appearance of many benign childhood tumors closely resembles that of adult malignancies, as happens with juvenile melanoma. True malignant melanoma was only found once in our series, although many cases of juvenile melanoma were treated. The treatment of malignant melanoma is no different from that advised for adults, and consists mainly of the widest practicable excision. Elective radical lymph node dissection is only justified if the presence of metastatic nodes is suspected. Cellular non-differentiation of tumor tissues—which in the adult normally means high malignancy—is many times found in benign teratoid tumors. Frequent mitosis, invasion, and infiltration of surrounding tissues, usually a bad sign, are frequently found in benign childhood tumors, namely the hemangiomas. In our series of many thousand of these tumors, only two true malignant hemangioendotheliomas were found. These should be treated by using surgery whenever possible, associated with postoperative roentgentherapy.

Conversely, certain tumors which appear to be benign when using the usual histological criteria, as happens with certain fibrous tissue tumors, show definite clinical malignancy with persistent local recurrence after an apparently adequate excision and leading to death of the patient due to progressive invasion and destruction. Some of the so-called fibromas of the mandible are no more than low grade fibrosarcomas, normally non-metastasizing but requiring from the very beginning an aggressive approach. This aggressive approach means that bone has to be largely resected and not only conservative tumor excision performed.

Another interesting feature of some childhood tumors is that they possess the possibility of undergoing spontaneous cure even in the presence of generalized soft tissue metastases, as happens with neuroblastomas. Some of these tumors, composed of not completely differentiated cells, may progressively differentiate and change into a less malignant or even benign type of tumor. This justifies the performance, in the presence of generalized metastases, of total or even partial excision of these tumors, complemented by roentgentherapy and/or chemotherapy.

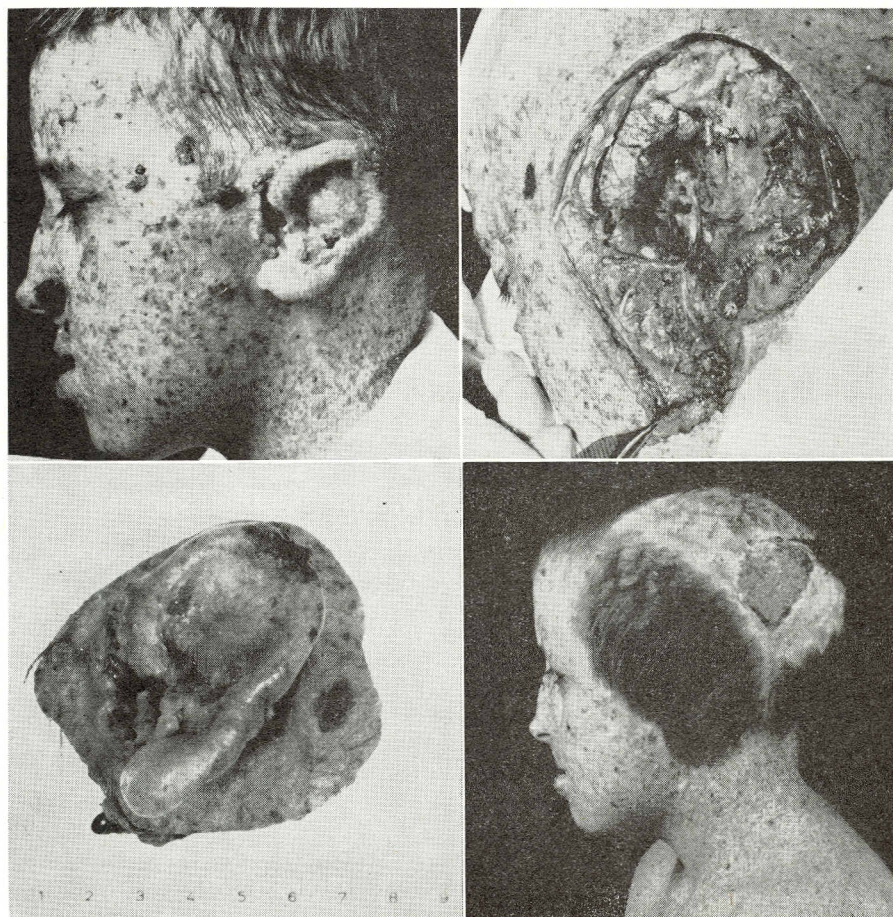
### **SURGICAL TREATMENT**

In this age group early diagnosis is as important as in any other. The same holds true for benign tumors, which in certain cases may cause death by virtue of their location, sudden growth, hemorrhage, and so on. The proper timing for operation is usually as early as possible. Modern advances in pediatric surgery and anesthesiology make it safe to operate on any child at any age, provided careful preoperative, intraoperative, and postoperative management are used. The all-important aim of the surgeon must be the complete, wide, and safe surgical excision of the tumor, always bearing in mind that reconstructive prob-

lems and mutilation fears must be considered as secondary to the cure of the patient.

We must be conservative if possible and never operate without having planned reconstruction carefully: if our patients are going to survive they will need acceptable function and also acceptable cosmetic appearance. To be conservative one must fully understand the nature and natural history of the tumor one is dealing with.

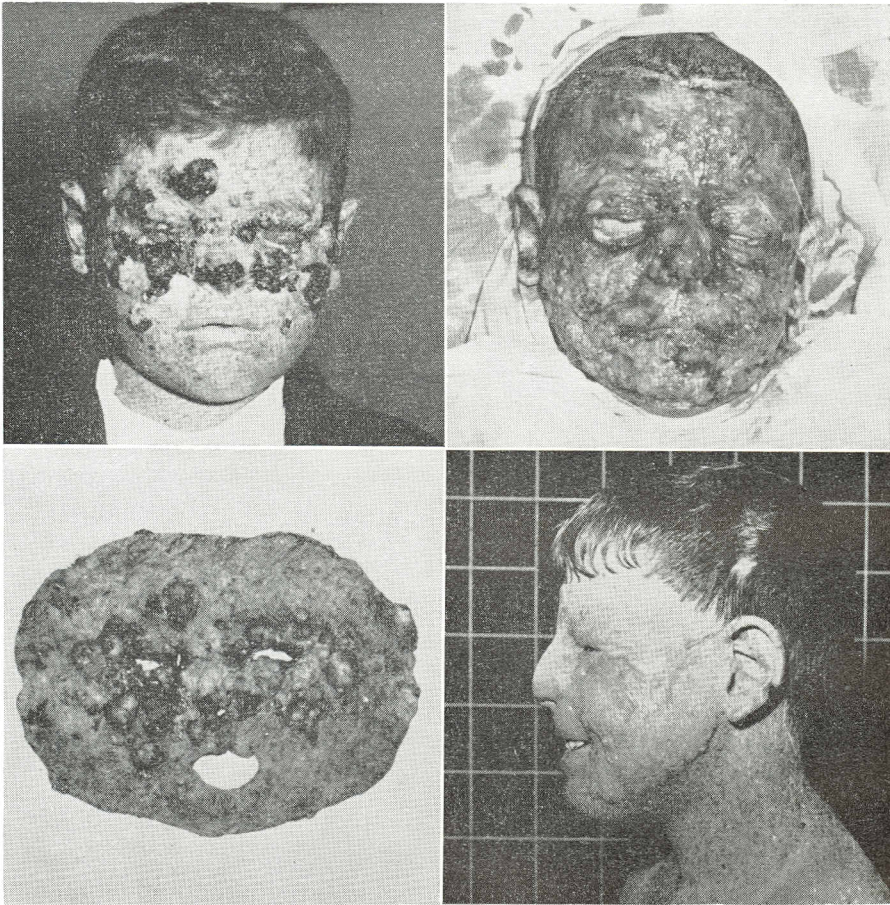At present surgery seems to be our most powerful tool in the treatment of head and neck tumors in children. Nevertheless, surgery must be considered as only part of the total care of the child. Often it has to be associated with other types of treatment such as roentgentherapy and chemotherapy, as is the case in



*Fig. 1.*—Eleven-year-old boy, suffering from Xeroderma Pigmentosum, had a squamous-cell carcinoma of the left ear invading the middle ear. He was treated by wide excision of the tumor, together with partial temporal bone resection preserving the facial nerve and followed by immediate reconstruction through a scalp flap and free grafting.

embryonal rhabdomyosarcoma, lymphosarcoma, sympathicoblastoma, localized Hodgkin's disease, and so on.

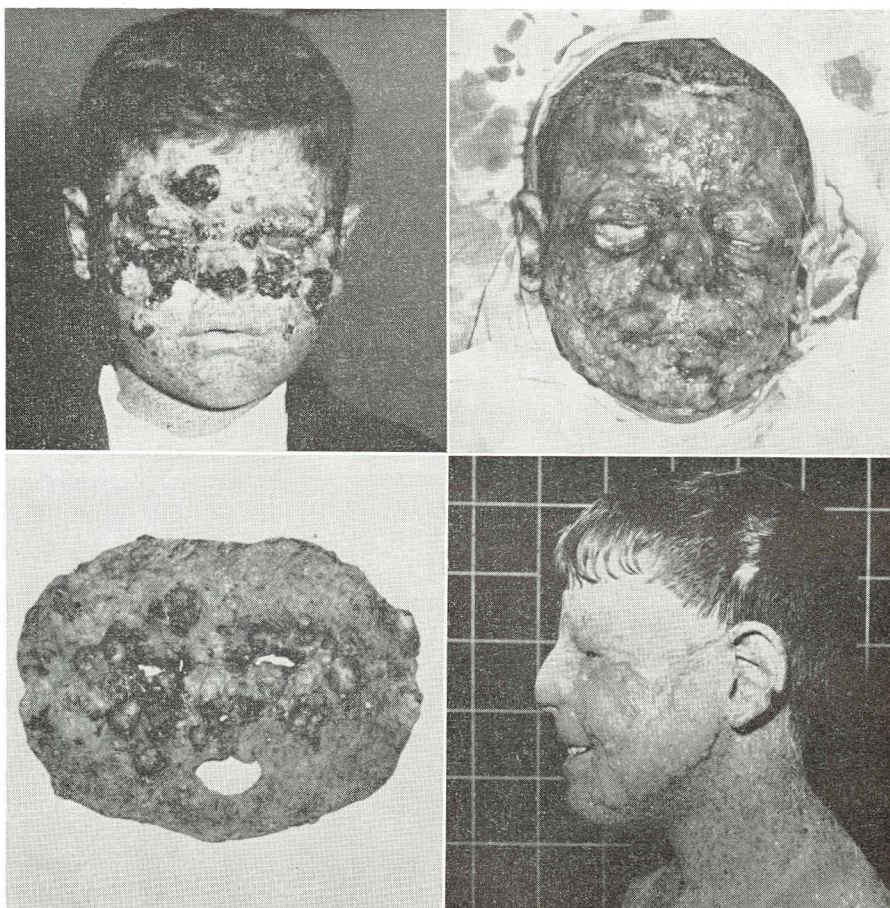
In retinoblastoma enucleation is often indicated, in unilateral cases, but orbital exenteration must always be contemplated if the tumor has extended beyond the eye itself. In these cases it is at times necessary to effect a total parotidectomy and radical neck dissection, with immediate facial nerve grafting if this nerve has to be sacrificed during removal of metastases. Roentgentherapy and chemotherapy are normally associated with surgery. In Xeroderma Pigmentosum treatment is exclusively surgical (Figs. 1 and 2), if we exclude prophylaxis, which is mostly avoidance of exposure to sunlight and the use of protective cover



*Fig. 2.*—Nine-year-old boy, suffering from Xeroderma Pigmentosum, had disseminated infected squamous-cell and basal-cell carcinomas occupying all his face. He was treated by a one-stage total facial skin monobloc excision with immediate reconstruction through free skin grafting, later complemented by tube pedicle rhinoplasty and other smaller surgical procedures.

embryonal rhabdomyosarcoma, lymphosarcoma, sympathicoblastoma, localized Hodgkin's disease, and so on.

In retinoblastoma enucleation is often indicated, in unilateral cases, but orbital exenteration must always be contemplated if the tumor has extended beyond the eye itself. In these cases it is at times necessary to effect a total parotidectomy and radical neck dissection, with immediate facial nerve grafting if this nerve has to be sacrificed during removal of metastases. Roentgentherapy and chemotherapy are normally associated with surgery. In Xeroderma Pigmentosum treatment is exclusively surgical (FIGS. 1 and 2), if we exclude prophylaxis, which is mostly avoidance of exposure to sunlight and the use of protective cover



*Fig. 2.*—Nine-year-old boy, suffering from Xeroderma Pigmentosum, had disseminated infected squamous-cell and basal-cell carcinomas occupying all his face. He was treated by a one-stage total facial skin monobloc excision with immediate reconstruction through free skin grafting, later complemented by tube pedicle rhinoplasty and other smaller surgical procedures.



creams. In this disease the appearance of malignant tumors is frequent, particularly in the face as the place more exposed to actinic radiation, and generally imposes diathermy excision of all small lesions until a time when a staged total facial skin replacement is justified. Roentgentherapy in these patients is to be strongly condemned. In other rare cutaneous neoplasms treatment is similar to that of adults, consisting of wide excision and immediate reconstruction; however, radical neck dissection is only justified if metastases are suspected (FIG. 3).

It is astonishing to see the adaptability of children to the large mutilations which may be necessary. A child should never be lied to before operation. If he is old enough to understand, a simple explanation of what is to come will often

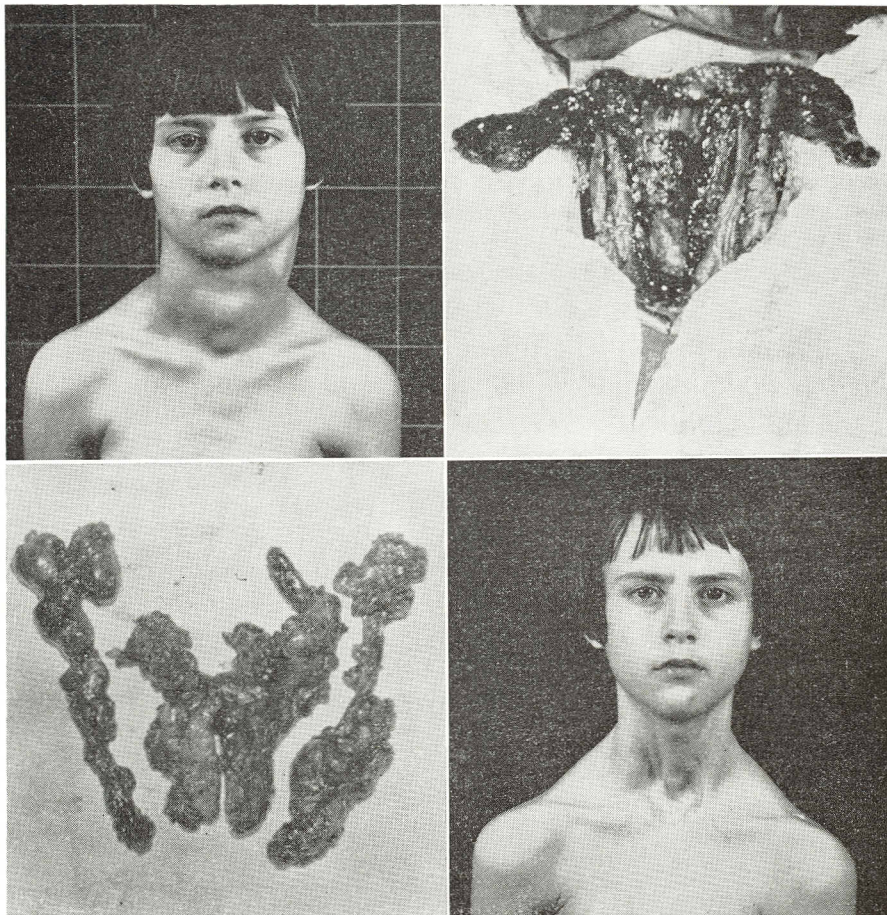


Fig. 3.—Ten-year-old girl, suffering from papillary carcinoma of the thyroid gland with bilateral cervical and pulmonary metastases. Treated by total thyroidectomy, dissecting the tumor from the thyroid cartilage which was partially invaded, and by bilateral neck dissection, followed by the use of  $^{131}\text{I}$  for treatment of remaining metastases.

help him enormously in the postoperative and convalescent periods. The essential features that are likely to upset him should be discussed: we must make him understand why he is to be operated upon but not indulge in lengthy explanations, particularly about mutilations, which may upset him more than help. The same holds true as regards parents. We must 'treat' not only the child but also his family: sooner or later the child will reflect the attitude of his parents. In many cases parents are aware that they may lose their child and it is the duty of doctors to minimize their suffering as much as possible. Above all they should never be given the impression that hope is completely lost or that everything possible has not been done.

#### SUMMARY

It is unquestionable that the outlook for children with cancer of the head and neck has changed and that nowadays many tumors do have a good chance of cure, provided adequate and timely treatment is given. Surgery is indicated in all localized lesions and even many times for those lesions that have extended beyond their original limits. Excision of the tumor is often associated with monobloc dissection of the regional nodes. Even embryonal rhabdomyosarcoma, probably one of the most refractory tumors to treatment in children, may many times permit if not a complete cure, at least a prolonged survival.

The surgeon must never lose hope and stop fighting: only then may he give his little patients the best chances for a cure that should never be denied to them.