

Canadian Journal of Cardiology ■ (2013) 1.e1–1.e3 [www.onlinecjc.ca](http://www.onlinecjc.ca)Case Report 

# Intracardiac Mass Due to Fibrosing Mediastinitis: The First Reported Case

Tiago Pereira-da-Silva, MD,<sup>a</sup> Ana Galrinho, MD,<sup>a</sup> Ana Ribeiro, MD,<sup>b</sup> Nuno Jalles, MD,<sup>c</sup> Fernando Martelo, MD,<sup>d</sup> José Fragata, MD, PhD,<sup>d</sup> and Rui Cruz Ferreira, MD<sup>a</sup>

<sup>a</sup>Cardiology Department, Hospital de Santa Marta, Centro Hospitalar de Lisboa Central, Lisbon, Portugal

<sup>b</sup>Anatomical Pathology Department, Hospital de São José, Centro Hospitalar de Lisboa Central, Lisbon, Portugal

<sup>c</sup>MRI Caselas, Lisbon, Portugal

<sup>d</sup>Cardiothoracic Surgery Department, Hospital de Santa Marta, Centro Hospitalar de Lisboa Central, Lisbon, Portugal

## ABSTRACT

We report a case of a woman, aged 53 years, presenting with a right atrial mass due to idiopathic fibrosing mediastinitis with periaortic involvement. This challenging diagnosis was confirmed by different imaging modalities and histopathologic analysis. The diagnosis of cardiac tumours is often difficult. To our knowledge, this is the first reported case of an intracavitary cardiac mass due to fibrosing mediastinitis. This rare disorder, which is characterized by invasive proliferation of fibrous tissue within the mediastinum, should be included in the differential diagnosis of intracardiac tumours.



## RÉSUMÉ

Nous rapportons le cas d'une femme âgée de 53 ans présentant une masse auriculaire droite causée par une médiastinite fibreuse idiopathique ayant une atteinte périaortique. Ce diagnostic complexe a été confirmé par les diverses modalités d'imagerie et l'analyse histopathologique. Le diagnostic de tumeurs cardiaques est souvent difficile. À notre connaissance, il s'agit du premier cas rapporté de masse cardiaque intracavitare causée par une médiastinite fibreuse. Ce trouble rare qui est caractérisé par la prolifération invasive de tissu fibreux dans le médiastin devrait être inclus dans le diagnostic différentiel des tumeurs intracardiaques.

The diagnosis of cardiac tumours is often challenging because of their rarity and diverse etiology.<sup>1</sup> To our knowledge fibrosing mediastinitis (FM) has not yet been reported as a cause of an intracavitary cardiac mass. We report a case of a right atrial mass and periaortic involvement due to this unexpected condition.

## Case Report

A woman, aged 53 years, with no relevant past medical history, except for mild hypertension, went to the emergency department because of retrosternal pain radiating to the back, which had started 2 weeks before. The electrocardiogram, chest radiograph, and blood analysis were normal, and she was discharged. She remained asymptomatic, but a transthoracic echocardiogram revealed an unexpected round, echodense, and heterogeneous 20 × 14-mm right atrial mass, without significant mobility, distinct from the valvular plane, in

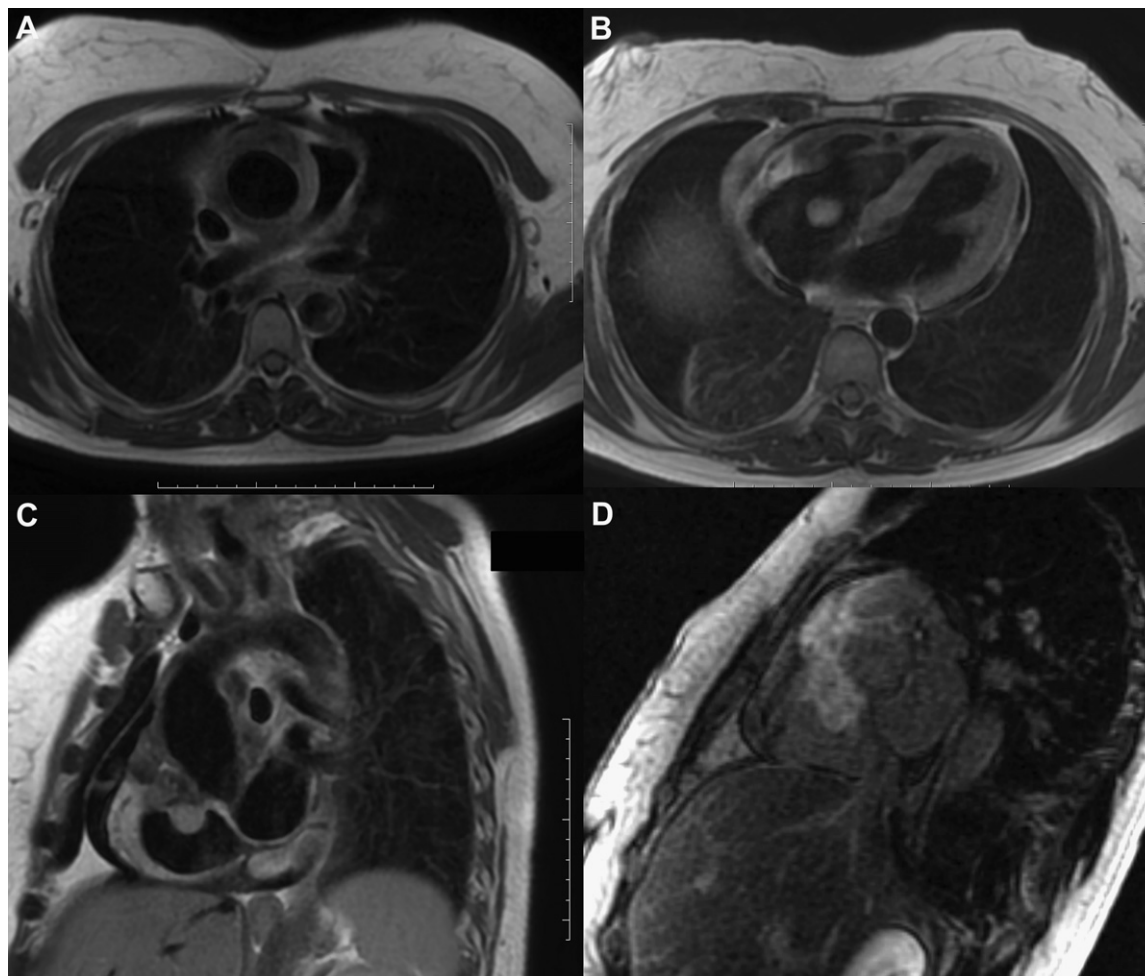
addition to a thickened aorta. The chest-abdomen-pelvis computed tomography scan showed a partially calcified circumferential thickening of the ascending aorta extending to the right atrioventricular groove, where it continued with the atrial mass, in addition to mediastinal lymphadenopathy mainly in the right paratracheal group. The cardiac magnetic resonance imaging further characterized the periaortic and atrial masses, which were in continuity (Fig. 1; Video 1 , view video online). The hemogram, coagulation, biochemistry, autoimmune screening, and microbiological examinations were normal. Because of the possibility of malignancy, a percutaneous atrial mass biopsy via jugular approach, guided by a transesophageal echocardiogram, was performed (Video 2 , view video online). The histopathology revealed marked fibrosis, but malignancy could not be excluded. A video-mediastinoscopy attempting to biopsy mediastinal lymphadenopathy was unsuccessful because of extensive mediastinal fibrosis. Finally, a median sternotomy was performed, and a nonvascularized white solid mass involving the ascending aorta was identified. An extensive sampling of the periaortic tissue was performed, and the histologic and immunohistochemical analysis confirmed the diagnosis of FM (Fig. 2). The periaortic tissue was identical to the right atrial mass tissue, confirming that the atrial mass, which was in continuity with the periaortic mass, was also due to FM. Both samples

Received for publication October 7, 2012. Accepted November 16, 2012.


Corresponding author: Tiago Pereira-da-Silva, MD, Cardiology Department, Hospital de Santa Marta, Centro Hospitalar de Lisboa Central. Rua de Santa Marta, n° 50, 1169-024, Lisbon, Portugal.

E-mail: [tiagopsilva@sapo.pt](mailto:tiagopsilva@sapo.pt)

See page XXX for disclosure information.



**Figure 1.** (A-C) Cardiac magnetic resonance T1-weighted black blood imaging and (D) gradient-echo inversion-recovery post gadolinium imaging. Ascending aorta thickening (A, axial plane) and right atrial mass (B, axial plane) in continuity, both with heterogeneous signal (hypo, iso, hyperintense) (C, sagittal plane). High signal on inversion recovery imaging due to the large volume of gadolinium distribution, typical of fibrotic tissue (D, sagittal plane).

revealed no bacteria or fungi (Gram and periodic acid-Schiff staining, tissue culture) or increased number of IgG4-positive cells. The *Histoplasma* serology and the tuberculin skin test were normal. Systemic corticosteroids were started, considering it was an idiopathic presentation. Nine months later, the patient is still on corticosteroids and asymptomatic. The periaortic and atrial masses are smaller (Supplemental Fig. S1; Video 3 , view video online).

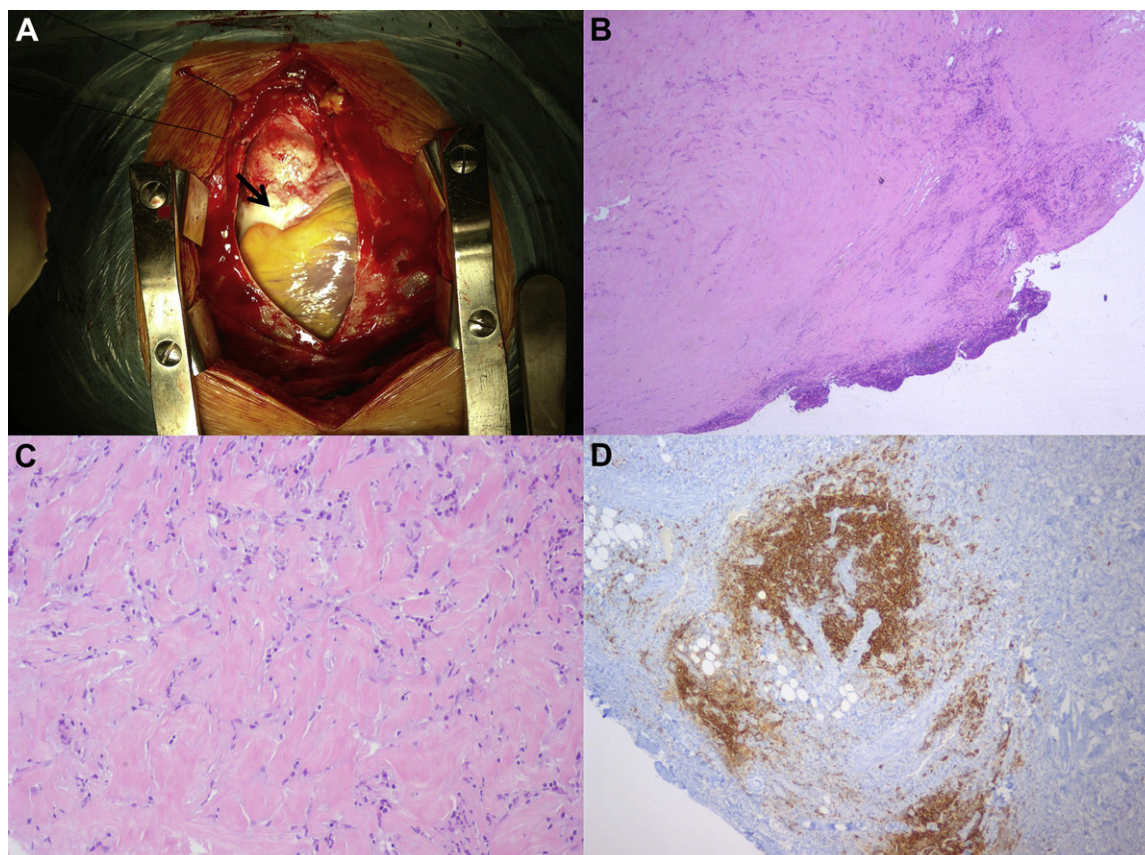
## Discussion

A cardiac mass detected on transthoracic echocardiography can be further characterized by other imaging techniques, but histologic examination is usually necessary to establish a definitive diagnosis,<sup>1</sup> as it was in this case. The dimension of the atrial mass sample obtained percutaneously was insufficient to exclude malignancy, as previously reported.<sup>2</sup> Thus, an extensive sampling via sternotomy was performed, confirming this challenging diagnosis.

FM is a rare benign disorder characterized by invasive proliferation of fibrous tissue within the mediastinum.<sup>2-4</sup> It

commonly involves the superior vena cava, pulmonary vessels, tracheobronchial tree, or esophagus, and the clinical presentation is usually related to obstruction or compression of these structures.<sup>2-4</sup> Less-frequently-involved structures include aorta and aortic branch vessels, pericardium, coronary arteries, lymph nodes, nerves, neck, thyroid, pleura, and spinal cord, and FM may be associated with retroperitoneal fibrosis.<sup>2-5</sup>

FM has an unpredictable but often benign course.<sup>2-4</sup> The main treatment options are systemic antifungal agents or corticosteroids, surgical resection, and local therapy.<sup>2,3</sup> The response to corticosteroid therapy is highly variable; while many patients do not improve, there are cases of effective treatment, particularly in idiopathic cases or cases with an active inflammatory process.<sup>2-5</sup> Surgical and local interventions are usually reserved for symptomatic patients for relief of compression.<sup>2,3</sup> It was decided not to excise the atrial mass, because the patient was asymptomatic and the excision could be associated with increased morbidity and mortality,<sup>2</sup> particularly in this case, where excision would be technically difficult without extreme wall replacement. In addition, the



**Figure 2.** (A) Median sternotomy: white mass involving the ascending aorta (arrow). Periaortic sample with extensive paucicellular fibrous tissue, mononuclear cell infiltration, and malignancy absence, seen on hematoxylin and eosin staining (B, C). B-cell infiltration evidenced by CD20 staining and fibrous tissue obliterating adipose tissue (D). Magnification: (B)  $\times 25$ ; (C)  $\times 100$ ; (D)  $\times 40$ .

atrial mass was not likely to embolize or cause obstruction, given its nonfragile appearance, high adherence, limited mobility, and the small dimensions. Moreover, the atrial and periaortic masses diminished with corticosteroids. The role of anticoagulation is not yet established.

To our knowledge, FM has not yet been reported as a cause of intracardiac tumours. This condition should be included in the differential diagnosis of intracardiac masses.

### Disclosures

The authors have no conflicts of interest to disclose.

### References

1. Paraskevidis I, Michalakeas C, Papadopoulos C, Anastasiou-Nana M. Cardiac tumors. *ISRN Oncol* 2011;2011:208929. Available at: <http://www.ncbi.nlm.nih.gov/pmc/articles/PMC3195386/>. Accessed December 3, 2012.
2. Rossi SE, McAdams HP, Rosadso-de-Christenson ML, Franks TJ, Galvin JR. Fibrosing mediastinitis. *Radiographics* 2001;21:737-57.
3. Peikert T, Colby TV, Midthun DE, et al. Fibrosing mediastinitis: clinical presentation, therapeutic outcomes, and adaptive immune response. *Medicine (Baltimore)* 2011;90:412-23.
4. Worrell JA, Donnelly EF, Martin JB, Bastarache JA, Loyd JE. Computed tomography and the idiopathic form of proliferative fibrosing mediastinitis. *J Thorac Imaging* 2007;22:235-40.
5. Ichimura H, Ishikawa S, Yamamoto T, et al. Effectiveness of steroid treatment for hoarseness caused by idiopathic fibrosing mediastinitis: report of a case. *Surg Today* 2006;36:382-4.

### Supplementary Material

To access the supplementary material accompanying this article, visit the online version of the *Canadian Journal of Cardiology* at [www.onlinecjc.ca](http://www.onlinecjc.ca) and at <http://dx.doi.org/10.1016/j.cjca.2012.11.020>.