

Leflunomide and polyomavirus-associated nephropathy in renal transplant

Ana Carina Ferreira¹, Aníbal Ferreira¹, Marília Possante¹, João Sousa¹,
Helena Viana², Fernanda Carvalho², Fernando Nolasco¹

¹ Renal Transplant Unit

² Renal Morphology Department

Hospital de Curry Cabral, Lisbon, Portugal.

Received for publication: 05/04/2009

Accepted in revised form: 04/08/2009

ABSTRACT

Polyomavirus nephropathy is a major complication in renal transplantation, associated with renal allograft loss in 14 to 80% of cases. There is no established treatment, although improvement has been reported with a variety of approaches.

The authors report two cases of polyomavirus infection in renal allograft recipients. In the first case, a stable patient presented with deterioration of renal function, worsening hypertension and weight gain following removal of ureteral stent placed routinely at the time of surgery. Ultrasound examination and radiology studies revealed hydronephrosis due to ureteral stenosis. A new ureteral stent was placed, but renal function did not improve. Urinary cytology revealed the presence of decoy cells and polyomavirus was detected in blood and urine by qualitative polymerase chain reaction. Renal biopsy findings were consistent with polyomavirus-associated nephropathy. In the second case, leucopaenia was detected in an asymptomatic patient 6 months after transplantation. Mycophenolate mophetil dosage was reduced but renal allograft function deteriorated, and a kidney biopsy revealed polyomavirus-associated nephropathy, also with SV40 positive cells.

In both patients immunosuppression with tacrolimus was reduced, mycophenolate mophetil stopped and intravenous immune globulin plus ciprofloxacin

started. As renal function continued to deteriorate, therapy with leflunomide (40 mg/day) was associated and maintained during 5 and 3 months respectively. In the first patient, renal function stabilised within one month of starting leflunomide and polymerase chain reaction was negative for polyomavirus after 5 months. A repeated allograft biopsy 6 months later showed no evidence of polyomavirus nephropathy. In the second patient, polyomavirus was undetectable in blood and urine by polymerase chain reaction after 3 months of leflunomide treatment, with no evidence of polyomavirus infection in a repeated biopsy 6 months after beginning treatment.

Key-Words:

Immunosuppression; kidney transplant; leflunomide; polyomavirus-associated nephropathy; SV 40 virus.

INTRODUCTION

Renal transplantation is the treatment of choice for end stage renal disease patients, but it is often complicated by infections that can lead to life-threatening situations or allograft loss.

Human polyomavirus infection is one of these major clinical complications¹. The first case of polyomavirus infection in a kidney transplant was reported in 1971².

Only two polyomavirus strains are thought to be pathogenic in humans; polyomavirus hominis 1 (BK virus) and polyomavirus hominis 2 (JC virus)³. Although these viruses are highly seroprevalent in humans, they appear to cause clinical disease only among immunocompromised patients. The BK virus manifests as interstitial nephritis, ureteral stenosis or cystitis in both renal or bone marrow transplant recipients. The JC virus manifests as a progressive multifocal leucoencephalopathy, typically observed in HIV infected patients^{3,4}. Primary infection with BK virus usually occurs in childhood, with an adult seroprevalence rate of 80%, from which approximately 5% have low levels of BK virus replication in their urine^{4,5}. The typical pattern in a renal transplant recipient is the progression from BK virus viruria to BK virus viraemia and then to BK nephropathy at intervals of approximately 6 weeks, allowing diagnosis at an early stage⁶.

In recent years, polyomavirus-associated nephropathy has emerged as a major cause of allograft failure following renal transplantation^{3,7-9}. Studies show that the prevalence of infection ranges from 1 to 10% and the risk of irreversible graft loss ranges from 14% to more than 80% of infected patients⁹.

Beyond reduction of immunosuppressive agents, there is no established treatment for BK nephropathy and the overall results are limited. Recently several drugs have been used in small case series^{1,7-9}.

In this report, we describe two cases of polyomavirus-associated nephropathy successfully treated with immunosuppression reduction, IVIG, ciprofloxacin and leflunomide.

■ CASE REPORT 1

A 66-year-old Caucasian male, 2 years and 5 months on haemodialysis (chronic renal failure stage 5d due to nephroangiosclerosis), received a deceased donor kidney graft. Donor and recipient shared 3 HLA matches (1 A and 2 B), and the complement dependent lymphocytotoxicity crossmatch was negative. A ureteral stent was placed during surgery. Diuresis was immediate. The patient was discharged from hospital on day 8 with a Scr of 1.6

mg/dl, under immunosuppression with MMF (1000 mg + 1000 mg/day), FK (2 mg + 2mg/day) and prednisolone (PDN) (20 mg/day). MMF was subsequently reduced to 1000 mg/day and PDN tapered to 5 mg/day. Serum tacrolimus levels were maintained between 8 – 12 ng/ml.

The ureteral stent was removed 5 months after transplantation, with Scr 2 mg/dl and no evidence of obstruction. Since then the patient became more hypertensive, with lower limb oedema and significant weight gain (6 Kg). One month later, he became hyponatraemic (Na⁺ 129 mEq/L), Scr increased to 2.9 mg/dl and FK serum levels were 9 ng/ml. An ultra sound study showed hydronephrosis and distal ureteral stenosis was revealed by descendent pielography. A new urethral stent was introduced, and hydronephrosis was solved without renal function improvement in the following days.

At this time urinary cytology revealed decoy cells (Fig. 1) and qualitative blood and urine PCR tests were positive for polyomavirus. A renal biopsy was performed. The biopsy findings were consistent with polyomavirus-associated nephropathy, exhibiting interstitial cell infiltrate, tubulitis and intranuclear basophilic viral inclusions without surrounding halo (Fig. 2). Immunohistochemistry for the T antigen of the SV40 virus was positive.

Immunosuppression was reviewed. MMF was stopped, FK reduced from 2 mg to 1 mg/day (serum

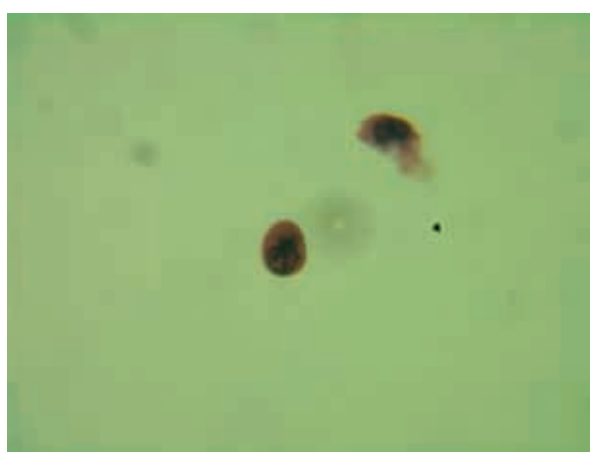


Figure 1

Urinary cytology with decoy cells (x400).

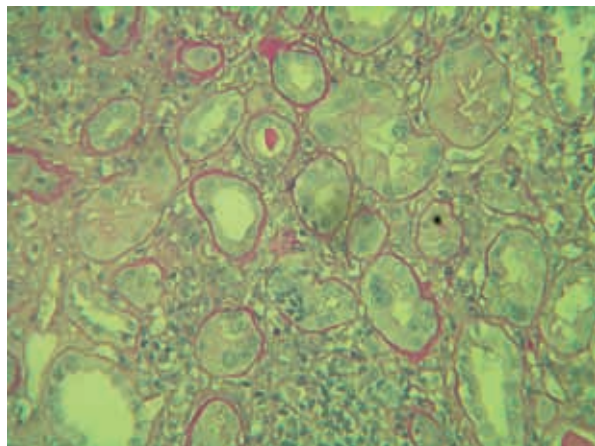


Figure 2

Allograft biopsy (PAS x 200) showing tubulointerstitial nephritis with tubulitis).

levels <6ng/ml), PDN maintained at 5 mg/day. Ciprofloxacin (500 mg/day) plus intravenous immune globulin (IVIg) 400 mg/Kg/day in 2 cycles of 10 days were started. As allograft function continued to decrease (Scr 3.2 mg/dl), antiviral treatment was considered and leflunomide (40 mg/day) was started and maintained over the following 5 months. One month after beginning therapy with leflunomide his renal function was stable (Scr 2.8 mg/dl) and 5 months after his PCR tests for BK virus in blood and urine were negative. A control allograft biopsy 6 months later showed no evidence of acute polyomavirus infection, including negative immunostaining.

Presently, after 19 months of follow up, the patient is under immunosuppression with MMF (500 mg + 500 mg), FK (1.5 mg + 1.5 mg) and PDN (5 mg), with stable renal function (Scr 2.7 mg/dl), no oedema, normal blood pressure and polyomavirus undetectable by PCR in blood and urine.

■ CASE REPORT 2

A 36-year-old Caucasian male with a past medical history of pulmonary tuberculosis underwent a deceased donor kidney transplant after 15 years on haemodialysis (membranoproliferative glomerulonephritis). Donor and recipient shared 2 HLA matches (1 A and 1 DR), and the complement dependent lym-

phocytotoxicity crossmatch was negative. Diuresis was immediate. The patient was discharged from hospital on day 7 immunosuppressed with MMF (1000 mg + 1000 mg/day), FK (4 mg + 4mg/day) and PDN (20 mg/day) and with a Scr of 2 mg/dl, which improved to 1.5mg/dl after 3 months. He was maintained under the same immunosuppression, with PDN tapering, and 6 months later, he became leucopaenic, with WBC count of $3100/\text{mm}^3$. MMF was reduced to 1000 mg/day and PDN maintained at 12.5 mg/day. Although leucopaenia improved, his renal function began to deteriorate and his Scr reached 2.3 mg/dl. FK serum levels were 11 ng/ml. A kidney biopsy was performed, and polyomavirus-associated nephropathy diagnosed based on interstitial cell infiltrate and intranuclear basophilic viral inclusions without surrounding halo. Immunostaining for large T cell antigen of the SV40 virus was positive (Fig. 3). A urinary cytology revealed decoy cells, and a qualitative PCR blood test was positive for polyomavirus.

MMF was stopped, tacrolimus reduced from 8 mg to 4 mg/day, prednisolone reduced to 10 mg/day, ciprofloxacin (500 mg/day) and intravenous immune globulin (400 mg/Kg/day, 5 days) started. As renal function continued to deteriorate (Scr 2.6 mg/dl) a second IVIg course was performed and the patient was started on leflunomide 40 mg/day. Polyomavirus was undetectable in blood and urine by polymerase chain reaction after 3 months and leflunomide was stopped. Presently, after 6 months, renal allograft function has improved (Scr of 1.8 mg/dl) and his PCR

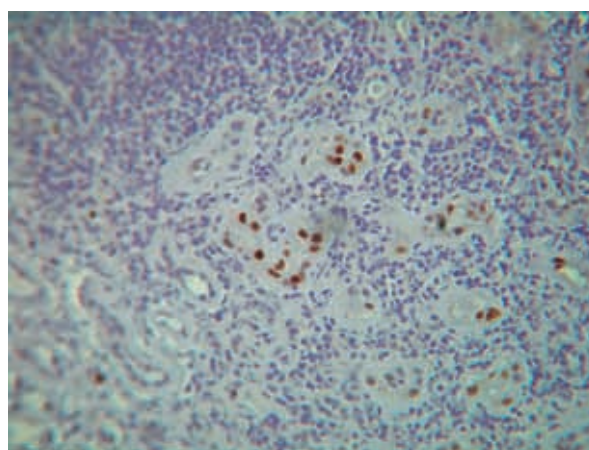


Figure 3

Immunohistochemistry for SV40 positive.

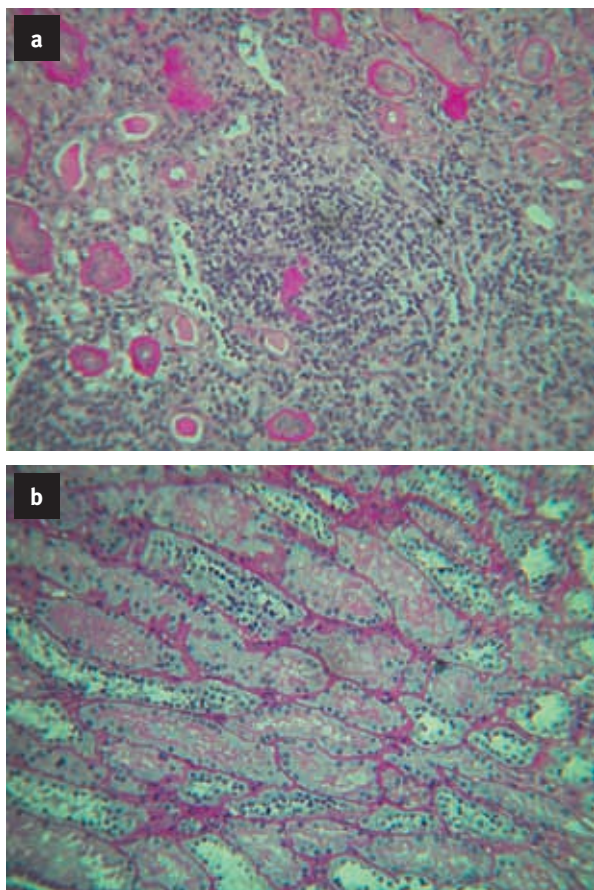


Figure 4
Allograft biopsy before (4a) and after (4b) leflunomide treatment. Note the interstitial infiltrate improvement (PAS x 250).

urine test for polyomavirus is negative. A second biopsy was performed and revealed BK nephropathy improvement, with important reduction of interstitial infiltrates and negative SV40 staining (Fig. 4). Following these results, the patient is immunosuppressed with FK 4 mg/day and PDN 10 mg/day.

DISCUSSION

BK virus-associated nephropathy is nowadays a more common complication of kidney transplantation than in the ciclosporin era, and frequently difficult to diagnose. The symptoms are nonspecific, with malaise, myalgia, anaemia, leucopaenia, thrombocytopenia

and renal function deterioration⁷. Although the use of such drugs as MMF or tacrolimus has contributed to the reduction in the incidence of acute rejection episodes, it has also been associated with a rise in the incidence of BK virus infection⁷⁻⁹. This association between these two agents and the rise in BK infection is probably caused by the greater immunosuppression induced by these drugs. Indeed, BK nephropathy seems to be an indicator of intense immunosuppression⁷.

The diagnosis of BK-associated nephropathy is first suspected clinically. This suspicion can be supported by the use of urine cytology to detect decoy cells in the urine. The presence of these cells does not mean that the patient has the disease; it only points to a virus reactivation¹⁰. Decoy cells test is positive in 30% of cases of BK nephropathy allowing for earlier diagnosis by renal biopsy. The use of molecular techniques can indicate the real risk for BK-associated nephropathy development: patients with viral load exceeding 1×10^4 copies/ml in plasma⁴ or 1×10^5 copies/ml in urine⁷ are at major risk⁷. However some authors claim that these techniques are more useful in the management of established cases than in diagnosis^{8,11}. The gold standard for diagnosis is renal biopsy, but unfortunately the changes are focal and may be missed in more than 25% of biopsy samples consisting of only one small core cortex^{7,9}. Cross-reaction of epitopes from the human polyomavirus with the Simian Virus 40 large T antigen is the basis for the identification of infected cells. Immunostaining for the SV40 large T cell antigen is mandatory and should always be performed when infection is suspected.

There is no consensus on the treatment of BK virus-associated nephropathy. Immunosuppression reduction, although sometimes effective, does not always result in viral replication abrogation or reduction. In these cases, antiviral drugs can be used. Anecdotal reports exist on the use of cidofovir, leflunomide, quinolone antibiotics and intravenous immunoglobulin with variable success. Only two recent reports showed good results, the first with low dose cidofovir¹² and the second with leflunomide¹³.

The use of cidofovir is limited due to its nephrotoxicity even in reduced dose and contraindicated in patients with impaired renal function. For this reason, this drug is not currently indicated as first line treat-

ment for the disease⁹. Since 2003, leflunomide has emerged as a potential new therapeutic drug for this disease, but randomised controlled trials are still lacking¹³⁻¹⁵. Leflunomide is an antiviral, prodrug, antimetabolite, rapidly metabolised to its active metabolite A77 1726, a malononitrilamide¹. Its mechanism of action seems to involve the inhibition of a mitochondrial enzyme necessary for orotate synthesis in the *de novo* pathway to uridine, and the inhibition of certain tyrosine kinases involved in T-cell, B-cell, vascular smooth muscle cell and fibroblast signalling cascades^{3,7}. The first evidence of the antiviral effects of leflunomide was with Waldman *et al.*¹⁶, who showed that human CMV was inhibited by A77 1726 in vitro, disrupting virion assembly at the level of nucleocapsid tegumentation. However, treatment of CMV infection in renal transplanted patients with leflunomide is limited and not successful¹. Unlike CMV, treatment of polyomavirus infection with leflunomide seems to be promising, but its mechanism of action against this virus is unknown.

In the first case the patient had a distal ureteral stenosis and renal function decrease, with decoy cells in the urine cytology, qualitative PCR positive test for polyomavirus in urine and blood and an allograft biopsy showing interstitial nephritis and positive SV40.

In the second clinical case, the symptoms were nonspecific with leucopaenia assumed to be secondary to MMF therapy. Diagnosis of polyomavirus nephropathy was made by a kidney biopsy performed due to allograft kidney dysfunction.

In both cases, despite the immunosuppression reduction, IVIG and ciprofloxacin treatment, the renal allograft function only stabilised after the introduction of leflunomide. We treated the two patients with a 40 mg day dose, since the most commonly successful used dose was 20 to 40 mg day in the reported cases³. Although we didn't have the levels of the active metabolite A77 1726, we obtained, with this therapeutic approach, a negative PCR test in blood and histological resolution of polyomavirus nephropathy. Nevertheless, the relationship between drug dose and level is unpredictable, and we monitored haematologic and hepatic toxicity.

Due to the potential of extensive fibrosis with subsequent allograft loss, early diagnosis of BK

nephropathy is one of the main factors for a successful outcome. Screening for viraemia with a urinary cytology should be performed every three months in the first 2 years and yearly after transplantation¹⁷. Once positive, evaluation of viraemia should be performed. If present for 3 weeks or more, viraemia indicates progression to BK-associated nephropathy. In these cases, an allograft biopsy must be performed to confirm the diagnosis. After the confirmation, treatment should be guided by blood PCR test. This test must be performed every 2 to 4 weeks, until a negative result is obtained. There is again no consensus as to how long treatment should be maintained. We withdraw leflunomide after a 5 and a 3 months period, attending to the result of blood PCR test. Although leflunomide is an antimetabolite, its use as immunosuppressive agent in renal transplanted patients isn't approved. In fact, an analogue of the active metabolite of leflunomide, FK 778, appears to suppress both cellular and humoral immune response. A multicentre study was performed in 2004 using FK 778 in order to study its effects at preventing allograft rejection in combination with tacrolimus and prednisolone. The results brought an end to the use of this drug in the United States, as it was not superior to the conventional therapy¹⁸.

Finally, although antiviral treatment with leflunomide seemed to be the most relevant step in treating our patients, the exact weight of quinolone therapy association and immunosuppression reduction cannot be quantified.

Conflict of interest. None declared.

References

1. Josephson MA, Williams JW, Chandraker A, Randhawa PS. Polyomavirus-associated nephropathy: update on antiviral strategies. *Transpl Infect Dis* 2006;8:95-101
2. Gardner SD, Field AM, Coleman DV. New human papovavirus (BK) isolated from urine after renal transplantation. *Lancet* 1971;1:1253-1257
3. Hilton R, William Tong CY. Antiviral therapy for polyomavirus-associated nephropathy after renal transplantation. *J Antimicrob Chemother* 2008 (Epub ahead of print)
4. Knowles WA, Pipkin P, Andrews N, *et al.* Population-based study of antibody to the human polyomavirus BKV and JCV and the simian polyomavirus SV 40. *J Med Virol* 2003;71:115-123
5. Hirsch HH, Steiger J. Polyomavirus BK. *Lancet Infect Dis* 2003;3:611-623
6. Hirsch HH, Knowles W, Dickenmann M, *et al.* Prospective study of polyomavirus type BK replication and nephropathy in renal transplant recipients. *N Engl J Med* 2002;347:488-496

7. Bonvoisin C, Weekers L, Xhignesse P, *et al.* Polyomavirus in renal transplantation: a hot problem. *Transplantation* 2008;85:542-548
8. Kotton CN, Fishman JA. Viral infection in the renal transplant recipient. *J Am Soc Nephrol* 2005;16:758-1774
9. Hirsch HH, Brennan DC, Drachenberg CB, *et al.* Polyomavirus associated nephropathy in renal transplantation: interdisciplinary analysis and recommendations. *Transplantation* 2005;79:1277-1286
10. Nicleleit V, Hirsch HH, Binet IF. Polyomavirus infection of renal allograft recipients: from latent infection to manifest disease. *J Am Soc Nephrol* 1999;10:1080-1089
11. Merlino C, Bergallo M, Gribaudo G. Polyomavirus BK DNA quantification assay to evaluate viral load in renal transplant recipients. *J Clin Virol* 2003;28:265-274
12. Kuypers DR, Vandooren AK, Lerut E, *et al.* Adjuvant low dose cidofovir therapy for BK polyomavirus interstitial nephritis in renal transplant recipients. *Am J Transplant* 2005;5:1997-2004
13. Faguer S, Hirsch HH, Kamar N, *et al.* Leflunomide treatment for polyomavirus BK associated nephropathy after kidney transplantation. *Transpl Int* 2007;962-969
14. Josephson MA, Gillen D, Javadi B, *et al.* Treatment of renal allograft polyoma BK virus infection with leflunomide. *Transplantation* 2006;81:704-710
15. Williams JW, Javadi B, Kadambi PV, *et al.* Leflunomide for polyoma type BK nephropathy. *N Engl J Med* 2005;352:1157-1158
16. Waldman WJ, Knight DA, Lurain NS, *et al.* Novel mechanism of inhibition of cytomegalovirus by the experimental immunosuppressive agent leflunomide. *Transplantation* 1999; 68:814-825
17. Drachenberg CB, Papadimitriou JC, Ramos E. Histologic versus molecular diagnosis of BK polyomavirus-associated nephropathy: a shifting paradigm? *Clin J Am Soc Nephrol* 2006;1:374-379
18. Vanrenterghem Y, van Hooff JP, Włodarczyk Z, *et al.* The effects of FK 778 in combination with tacrolimus and steroids: a phase II multicenter study in renal transplant patients. *Transplantation* 2004; 78:9-14

Correspondence to:

Dr Ana Carina Ferreira
Rua da Beneficência nº 8
1069-639 Lisbon, Portugal
karinadacostafer@hotmail.com