

# Two gestational sacs, two locations - Heterotopic pregnancy - Case report

Centro Hospitalar de Lisboa Central  
Hospital Dona Estefânia  
Lisboa, Portugal

Vanessa Olival, Maria José Bernardo, Carla Leitão, Manuela Coelho, Maria João Nunes,  
Isabel Nery  
Department Chair – Ricardo Mira, MD

Heterotopic pregnancy (HP) is defined as two gestational sacs simultaneously present in two different locations, being the uterus and the fallopian tubes the more common. Sporadic HP is a very rare condition (1:30,000 pregnancies). With the use of medically assisted reproduction the prevalence is significantly higher (1:7,000). Considering spontaneous pregnancy, HP is associated with risk factors, being prior inflammatory pelvic disease the most common. The clinical presentation is similar to that of ectopic pregnancy or spontaneous miscarriage although it is usually a more late diagnosis.

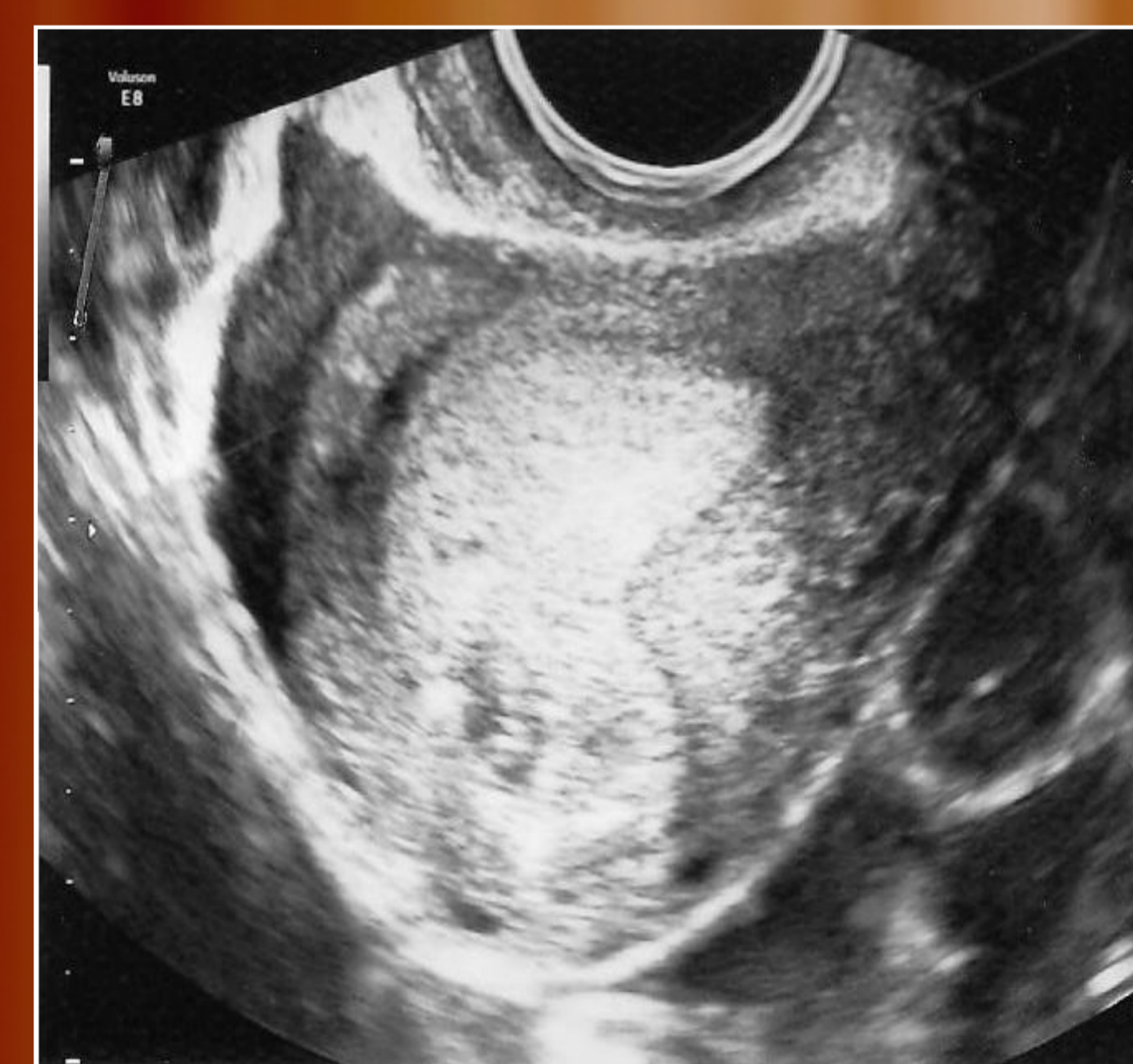
## Case report

- 25 year-old pregnant woman
- OI 0000, previously healthy
- Admitted at the Emergency Department (ED) with acute pelvic pain mainly at the right iliac fossa and moderate vaginal bleeding confirmed by speculum examination

- She was hemodynamically stable and the bimanual palpation was painful; no prior medically assisted reproduction technique had been performed

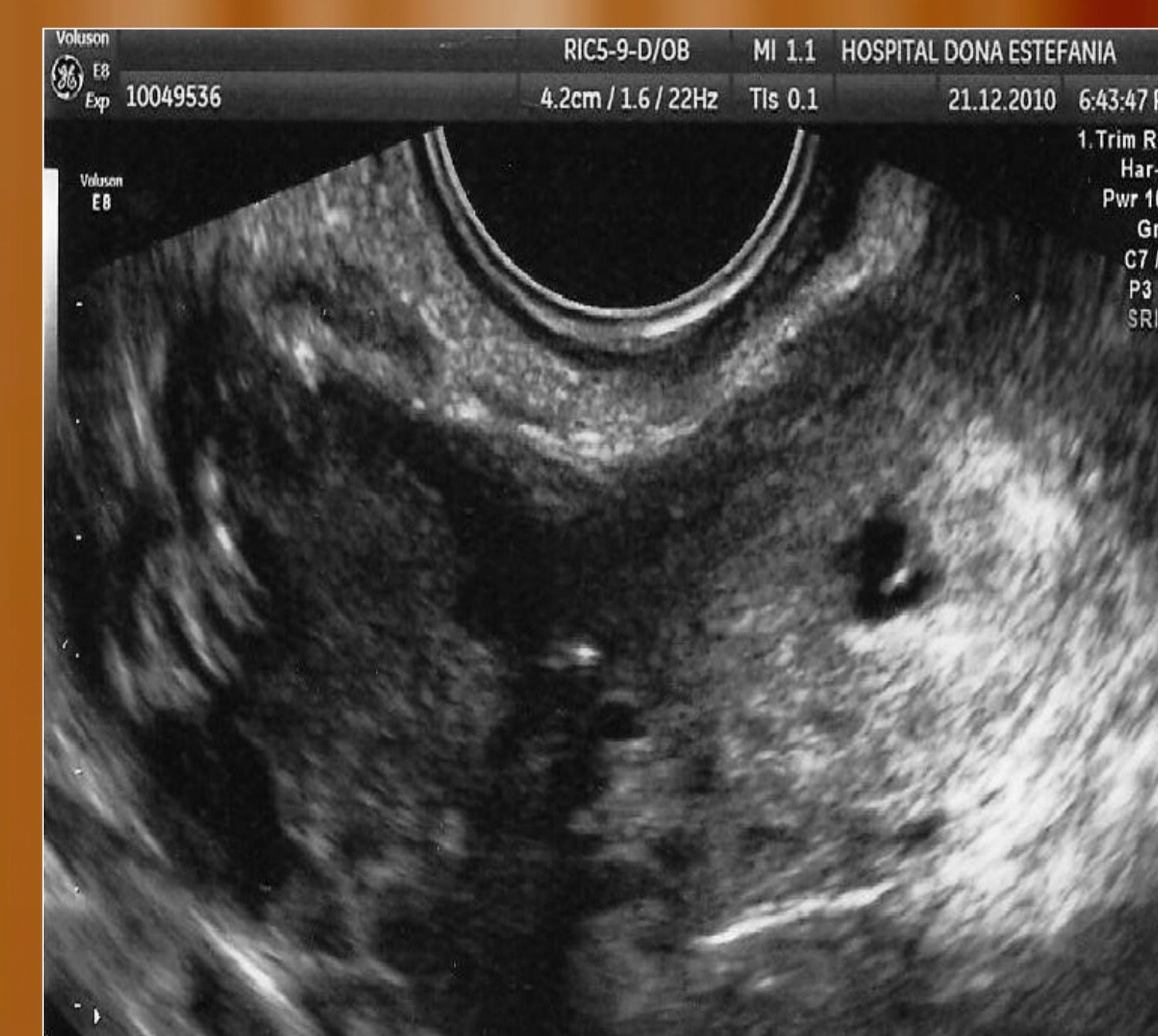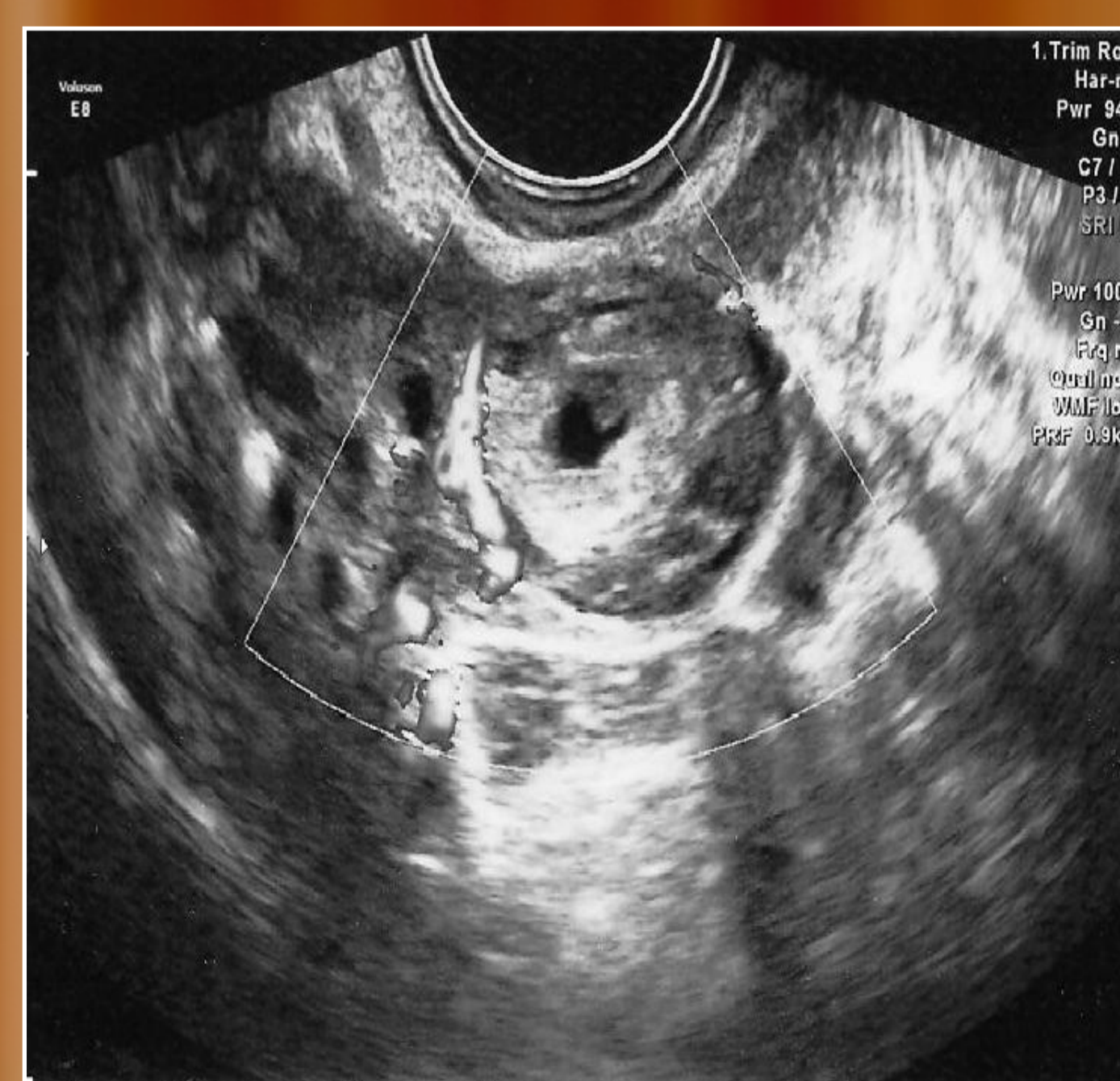- The haemoglobin value was within normal range and the serum  $\beta$ -hCG was 2,763mUI/mL

- The ultrasonography at the ED showed an *in utero* gestational sac and another one inside the right fallopian tube; in both gestational sacs cardiac activity was absent



1- Pregnancy “*in utero*”

HP diagnosis was then established and the patient was admitted at the Obstetrics Ward for surveillance and ultrasonographic/laboratorial reassessment; complete miscarriage of the uterine pregnancy occurred but methotrexate was necessary for the treatment of persistent tubarian pregnancy.



2- Pregnancy in fallopian tube

## Conclusion

When evaluating a pregnant woman with pelvic pain and vaginal bleeding one should always be aware of several differential diagnosis amongst which HP should be considered. If the patient has *in utero* viable pregnancy the treatment of the ectopic concomitant gestational sac should be as conservative as possible; methotrexate should not be used in that situation as it leads to uterine pregnancy miscarriage in about one-third of the patients.

## References:

- 1- “Abdominal pregnancy, cesarean scar pregnancy, and heterotopic pregnancy” – Thomas A Molinaro, MD, Setembro 2010, UpToDate – [www.uptodate.com](http://www.uptodate.com)