

# APPENDICEAL MUCOCELE - Unexpected diagnosis in a Gynecology Department -

André Correia, Fazila Mahomed

Gynecology Department – D. Estefânia Hospital, Lisbon, Portugal

**Introduction:** Pelvic cystic disease is common and the majority originates in the ovary. Mimics of ovarian cyst include: peritoneal inclusion cysts, paraovarian cysts, appendiceal mucocele and others. *Appendiceal mucocele* is a term widely used in both benign and malignant (10%) lesions. It is a rare entity, occurring in < 1% appendicectomies, with a female predominance 4/1 (F/M), and diagnosed in their 50s or 60s. The symptoms and laboratory findings are nonspecific or absent. Because of that, it is often incidentally discovered, either during surgery or on radiologic examination. Majority are a benign process (mucinous cystadenoma), most of which can be treated by appendicectomy alone, with careful exploratory laparotomy, to minimize the risk of seeding the peritoneal cavity with tumorous mucin.

**Objective:** The authors present **two cases** of appendiceal mucocele, diagnosed in our Department, as an intraoperative finding.

## CASE REPORT 1

- Year: 2004
- Age: 56 yr
- Postmenopausal
- Asymptomatic
- Routine Pelvic US finding:
  - ✓ Right adnexal *septated cystic image, 53x48mm, hypovascularized septa and a vascularized capsula with low flow resistance*
- Laboratory findings: ↑CA125 (71,3U/ml)

## CASE REPORT 2

- Year: 2010
- Age: 62yr
- Postmenopausal
- Asymptomatic
- Routine Pelvic US finding:
  - ✓ *Heterogenous right adnexal mass, 94x84mm, without signs of vascularization in its interior*
- Laboratory findings: ↑CEA (41,47U/ml)

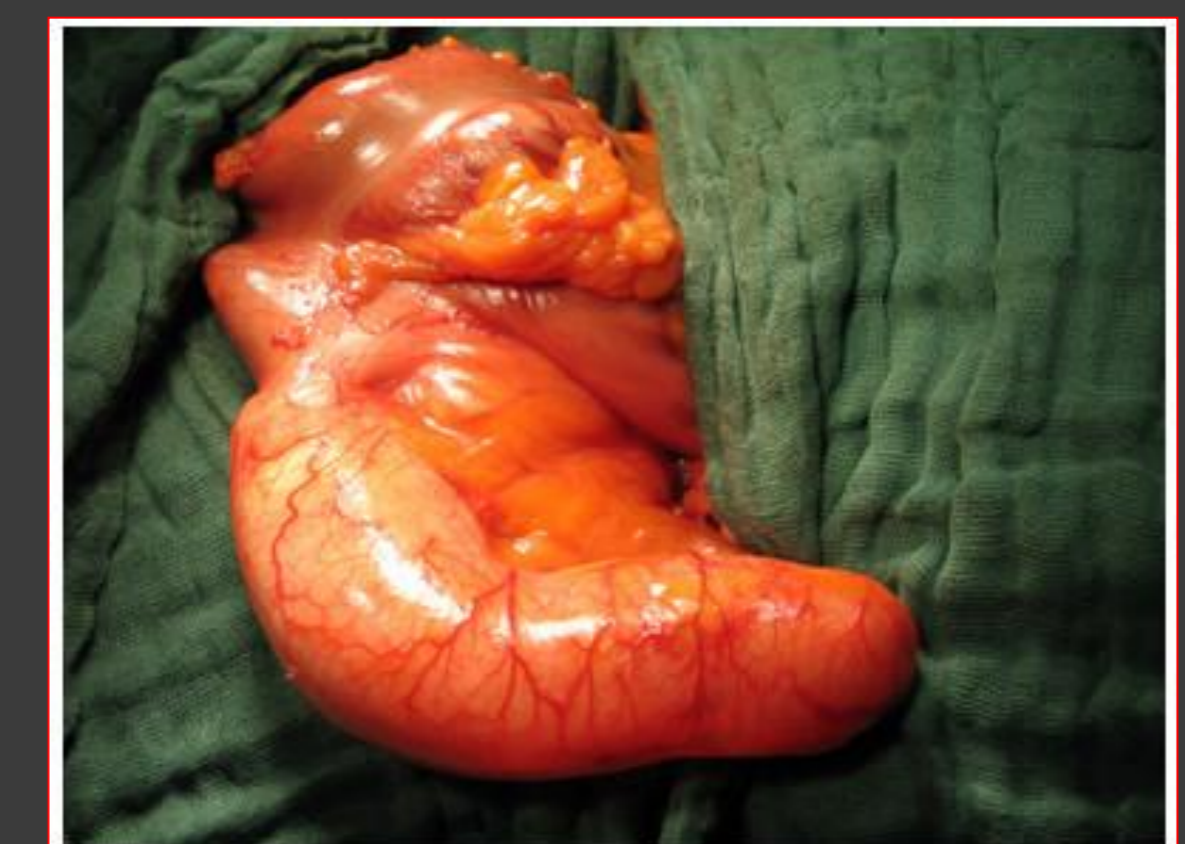
### Exploratory Laparotomy

- An increasead gelatinous right ovary
- Appendicular enlargement

- Appendicular enlargement
- Macroscopically normal pelvic organs

↪ Intraoperative examination  
*Pseudomixoma peritonei associated with an appendiceal mucocele and a mucinous ovary tumor*

### Appendicectomy



### Radical Surgery

### Final Histologic Diagnosis

*Appendix mucinous cystadenoma with peritoneal mucinous dissemination involving the right ovary*

*Appendix mucinous cystadenoma and signs of localized pseudomixoma peritonei*

**Discussion:** The appendiceal mucocele despite rare, should be considered when a patient presents with a right adnexal mass. To the gynecologist, this finding represents a challenge in surgical approach and sometimes requires the support of the surgeon and medical oncology.