

## Monilethrix

**A** 12-year-old girl presented with a 2-year history of progressive hair loss involving the top of the scalp. She also complained of partial loss of eyebrows. Family history was unremarkable. Examination revealed mild widening of the central parting, suggesting a diagnosis

of female pattern hair loss (**Figure, A**) and alopecia of the eyebrows and lower eyelashes (**Figure, B**). Dermoscopy of the scalp showed a few characteristic monilethrix hair shafts characterized by uniform elliptical nodes, separated by intermittent constrictions. Broken hair shafts at internode levels were also evident (**Figure, C**). Dermoscopy of the eyebrows was also diagnostic for monilethrix.

The term monilethrix derives from both the Latin *monile* (necklace) and the Greek *thrix* (hair). The hair shaft has a beaded appearance due to the presence of elliptical nodes that have the diameter of normal hair and are medullated, regularly separated by internodes that are narrow, devoid of medulla and are the site of fracture.<sup>1,2</sup>

It is an autosomal dominant disorder, with variable expression, due to mutations of the human basic hair keratins hHb6 and hHb1. The hair is dull, fragile, and breaks easily, especially in the sites of friction such as the nape and occipital areas. Follicular keratosis of the affected scalp and keratosis pilaris are also typical. The severity of monilethrix considerably varies even among members of the same family and may range from an almost normal scalp, to total alopecia.<sup>3,4</sup>

In this case, the disease was mild and went unnoticed until adolescence. The correct diagnosis was indicated by dermoscopy that easily evidenced the few hairs affected by the abnormality. The parents were advised to avoid trauma to scalp hair and informed that the condition may spontaneously improve with age, whereas no effective treatment is currently available.<sup>3,5</sup> ■

### André de Lencastre, MD

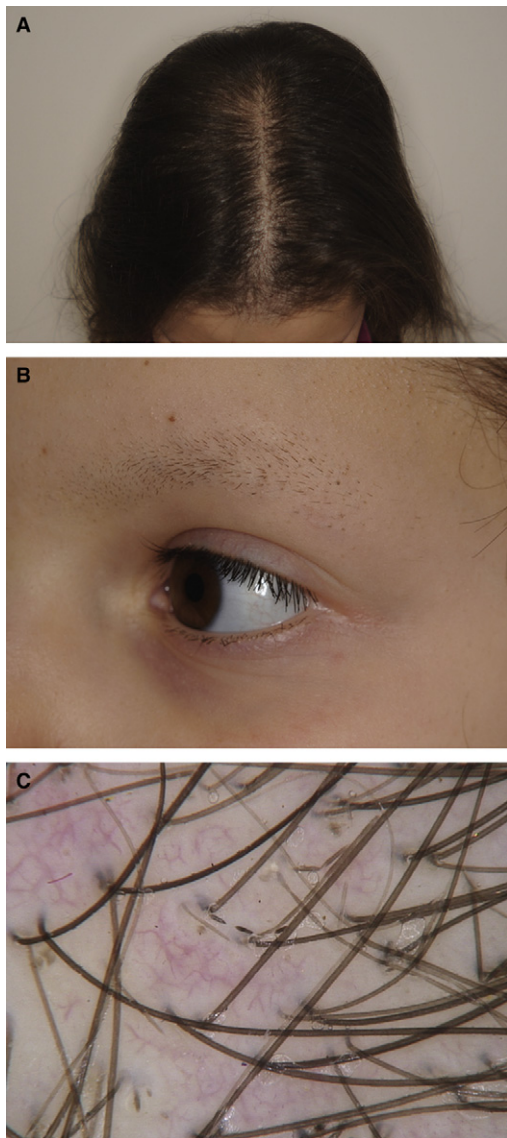
Dermatology Service  
Hospital de Santo António dos Capuchos  
Centro Hospitalar de Lisboa Central  
Lisbon, Portugal

### Antonella Tosti, MD

Department of Dermatology and Cutaneous Surgery  
Miller School of Medicine  
University of Miami  
Miami, Florida

## References

1. Tosti A, Torres F. Dermoscopy in the diagnosis of hair and scalp disorders. *Actas Dermosifliogr* 2009;100(Suppl 1):114-9.
2. Rakowska A, Slowinska M, Kowalska-Oledzka E, Rudnicka L. Trichoscopy in genetic hair shaft abnormalities. *J Dermatol Case Rep* 2008;2:14-20.
3. Gebhardt M, Fischer T, Claussen U, Wollina U, Elsner P. Monilethrix-improvement by hormonal influences? *Pediatr Dermatol* 1999;16:297-300.
4. Jain N, Khopkar U. Monilethrix in pattern distribution in siblings: diagnosis by trichoscopy. *Int J Trichology* 2010;2:56-9.
5. Finley E, Ertle JO, Marschall S. Alopecia in a 19-month-old boy. *Arch Dermatol* 1994;130:1055-6.



**Figure.** **A**, Diffuse alopecia with widening of the central parting of the scalp. **B**, Alopecia and breakage of the eyebrows and eyelashes (especially of the lower eyelid). **C**, Dermoscopy of the scalp where at least 1 monilethrix is easily seen at the center of the image.