

Primary angiosarcoma of the pericardium: case report and review of the literature

Pierwotny mięsak naczyniowy osierdza: opis przypadku i przegląd piśmiennictwa

Ana Teresa Timóteo, Luísa Moura Branco, Ivan Bravio, Eugénia Pinto, Teresa Timoteo,
Pedro Matos, Rui Cruz Ferreira

Santa Marta Hospital, Lisbon, Portugal

Abstract

Primary cardiac tumours are rare entities and angiosarcoma is the most frequent primary cardiac malignant tumour. Mean survival is six months and the tumour responds poorly to chemotherapy. We present the case of a 50 year-old patient with localised pericardial angiosarcoma who survived 23 months after diagnosis with a combined approach of chemotherapy and surgery.

Key words: pericardial angiosarcoma, primary cardiac tumours, chemotherapy

Kardiol Pol 2010; 68, 7: 802–805

INTRODUCTION

Primary cardiac tumours are rare entities and angiosarcoma is the most frequent primary malignant cardiac tumour [1, 2]. The mean survival is six to eleven months and the tumour responds poorly to chemotherapy [3, 4].

CASE REPORT

A 50 year-old female was referred to our institution for evaluation of pericardial effusion. She complained of persistent precordial pain with onset five months before admission with progressive development of dyspnea, fatigue, ankle oedema and increase in abdominal volume in subsequent months. A chest-X ray, electrocardiogram and routine laboratory studies were normal. A transthoracic echocardiogram (TTE) showed a moderate-sized pericardial effusion. Later on, the patient developed tamponade and pericardiocentesis yield 700 mL of hemorrhagic fluid. Cytological and bacteriological tests of the fluid were negative. The patient was treated for presumed viral pericarditis. Follow-up TTE showed residual small pericardial effusion next to the right atrium, with an echodense image that was considered a residual organized hematoma. Two months after drainage, symptoms recurred. At that time, TTE also

showed a bright echodensity in the right atrium posterior wall (35 × 33 mm) and adjacent pericardial space, with another extrinsic mass outside left atrium (24 × 31 mm), confirmed by transthoracic echocardiography. The first mass was in the pericardial sac between the right atrium and left atrium, extending into the right atrium (Fig. 1). A thoracic computed tomography (CT)-scan done in the meantime showed diffuse thickening of the pericardial membrane and pathological lymph nodes in the superior and anterior mediastinum. The patient was again admitted for evaluation. Laboratory studies showed an increase in erythrocyte sedimentation rate (ESR), as well as slight normocytic normochromic anaemia. The electrocardiogram showed sinus tachycardia and negative T waves in the anterior and lateral leads. Abdominal and kidney ultrasound was normal. Cardiac magnetic resonance imaging (MRI) confirmed diffuse thickening of the pericardium with moderate to large pericardial effusion that caused constriction, with a haematic and solid component. There was a mass in the top of right atrium, which invaded the wall as well as the superior mediastinum (namely superior vena cava) (Fig. 2, 3). The left atrium extrinsic mass was interpreted as a blood collection that compressed right lower pulmonary vein.

Address for correspondence:

Ana Teresa Timóteo, Cardiology Department, Santa Marta Hospital, Rua Santa Marta 1169-024 Lisboa, Portugal, tel: + 351 21 3594000, e-mail: ana_timoteo@yahoo.com

Received: 16.11.2009 Accepted: 18.11.2009

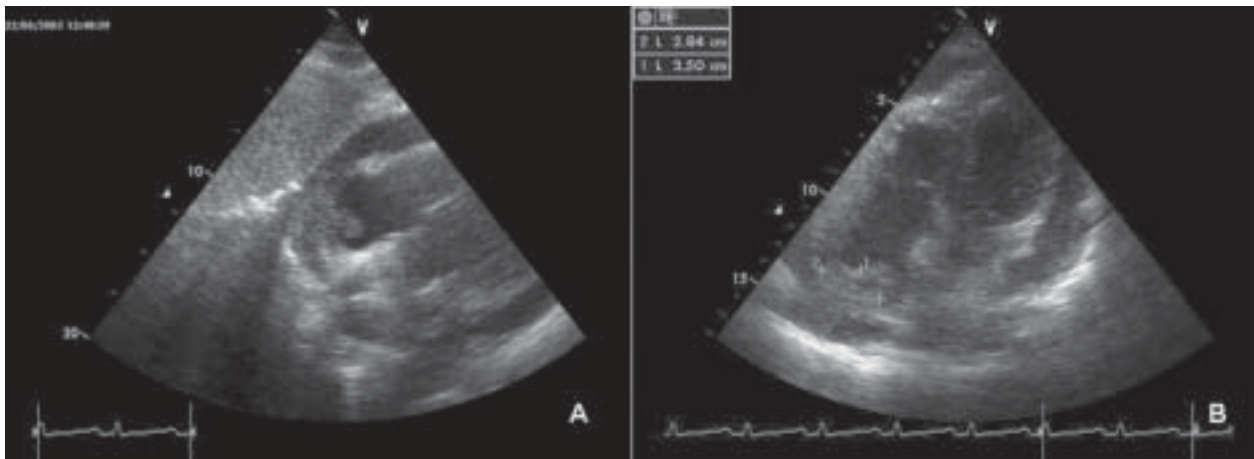


Figure 1. A. Sub-costal view showing a mass inside the pericardium (with pericardial effusion) and extending to the right atrium free wall and inside; B. Apical 4-chamber view showing the pericardial mass extending to the right atrium

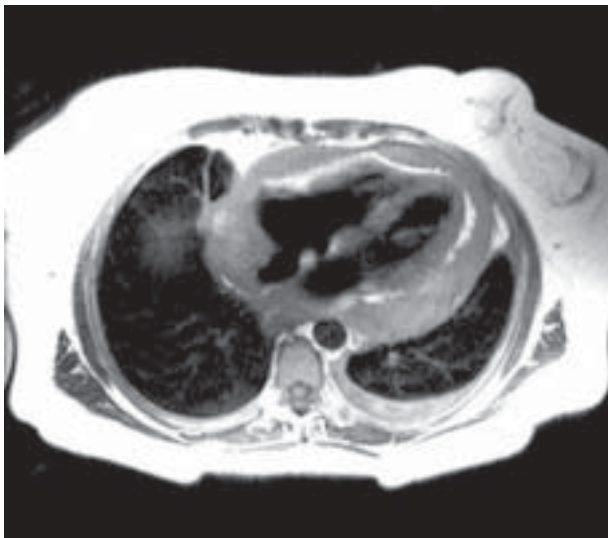


Figure 2. MRI Proton Density (Double IR) showing an isointense mass in right atrium wall, invading surrounding structures and also pericardial effusion

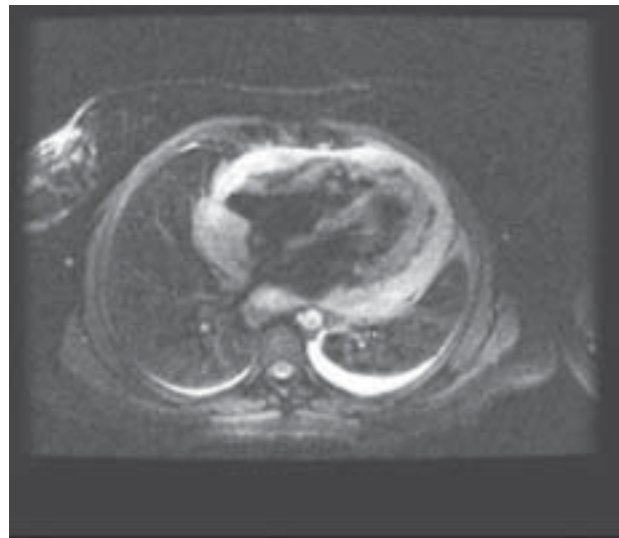


Figure 3. MRI T2 FATSAT sequence, which shows the same mass, now hyperintense, in the same location as described in Figure 2

The clinical condition of the patient deteriorated quickly and mediastinoscopy was performed with pericardiocentesis, without significant removal of pericardial fluid, but with pericardial and lymph node biopsy. Pathological examination revealed a papillary neoplasia composed of pleomorphic spindle cells arranged as interconnecting vascular spaces. Immunohistochemical staining was positive for Vimentin and CD31, confirming vascular differentiation and supporting the diagnosis of poorly differentiated angiosarcoma (Fig. 4). Lymph node biopsy showed only reactive inflammation. No other localization was found for angiosarcoma. The patient was transferred to the Oncology Department, where chemothe-

rapy was started with Ifosfamide 5 g/m² day 1, Epirubicine 50 mg/m² day 1, Mesna 5 g/m² day 1 and 2.5 mg/m² day 2, every 3 weeks (nine cycles: cumulative dose of epirubicine 540 mg/m²). At six-month follow up, the patient was symptom-free with complete disappearance of pericardial effusion and no residual mass in the right atrium. A few months later, a small pericardial effusion and mass recurred, confirmed by cardiac-MRI, although the patient remained with few symptoms (chest pain). Chemotherapy was restarted for more six cycles (liposomal doxorubicine 30 mg/m² day 1, instead of epirubicine). Positron emission tomography (PET)-scan excluded disseminated disease and the patient decided to un-

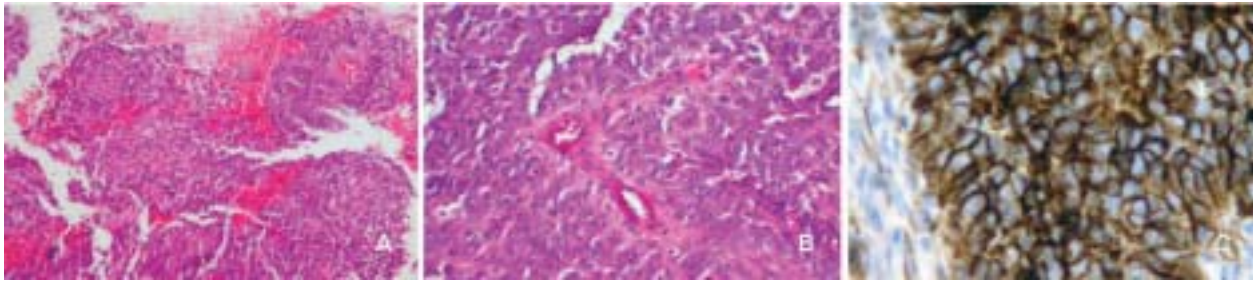


Figure 4. A, B. Papillary neoplasia composed of atypical endothelial cells (pleomorphic spindle cells) arranged as interconnecting vascular spaces (HE); **C.** Immunohistochemistry with positive staining for CD31, confirming vascular differentiation

derwent cardiac surgery at another institution. Intra-operatively, there was a localized mass in the pericardium that did not seem to invade the right atrial wall, so the tumour was surgically removed “en bloc” as well as right atrial free wall which was reconstructed using a pericardial patch. There was however a new recurrent pericardial effusion detected at surgery, that was positive for malignant cells in post-operative pathological examination. In the first post-operative TTE (one month later), moderate heterogeneous pericardial effusion was present, mainly septated next to the right ventricular apex. No mass was detected in the right atrium. In subsequent TTE, pericardial effusion increased, without causing tamponade. A new PET-scan showed images of neoplastic masses around the heart. Chemotherapy was changed to Docetaxel 100 mg/m² due to a decrease in cardiac function, with poor tolerance and only slight improvement in pericardial effusion dimensions. The patient died with multiorgan failure 30 months after the first symptoms, 23 months after diagnosis and 13 months after surgery.

DISCUSSION

Primary cardiac tumours are rare entities (0.0017–0.003% of routine autopsy studies, 25% malignant) [1]. Angiosarcoma is the most frequent primary malignant cardiac tumour (31% of all the malignancies) [2]. They have a tendency to occur in the 3rd – 5th decade and are more common in males [5]. Metastatic disease is very frequent at the time of diagnosis (66–89%), mainly locally (mediastinal lymph nodes, lungs and vertebra) [6]. In a retrospective analysis of 149 primary cardiac tumours, those arising from the pericardium (80%) and arising on the right side of the heart (43.5%) were usually malignant [7]. Those originating from the posterior wall of the right atrium increase the likelihood of a malignant process. These tumours have a silent evolution for a long time, with non-specific symptoms [8].

Primary cardiac tumours are often first detected by TTE with pericardial effusion as in our case. Transesophageal echocardiography delineates the tumour more accurately, namely its location and characteristics [7]. Computed tomography and

MRI have excellent diagnostic advantages with regard to tumour delineation, characterisation and spread [5]. In MRI, T1 weighted or proton density (Double IR) images are iso or hyperintense related to myocardium and T2 weighted are hyperintense. These characteristics were present in our case. MRI also allowed a more precise definition of localisation, contour, local spread and involvement of adjacent structures. When drained, the fluid is usually hemorrhagic and cytological analysis is often negative for malignant cells as in our patient [9]. The main location is in the right atrium (90%) and pericardial involvement can cause pericardial constriction [9]. These tumours grow rapidly with local invasion and distant metastasis. It is usually a fungating pink-tan mass with vascular channels by endothelial malignant differentiation [9]. It stains immunohistochemically positive for CD31, CD34 and Factor VIII, confirming vascular differentiation (CD31 in our patient) [9].

Mean survival is 6–11 months with some anecdotal cases up to two years and one case up to four years [3, 10]. Angiosarcoma responds poorly to chemotherapy [4]. Chemotherapeutic drugs used to treat cardiac angiosarcoma include adriamycin, ifosfamide, cyclophosphamide, vincristine or dacarbazine [5]. Most oncologists use adriamycin-based regimens. Results of surgical resection alone have been discouraging because most patients have advanced disease with a mean survival of nine months, depending on whether adjuvant treatment with radiation and/or chemotherapy was given [6]. Mean survival of patients with more localised masses, with tumour resection (more than half received adjuvant chemotherapy), is only ten months [6]. Orthotopic cardiac transplantation has been carried out in some cases, but survival did not differ from those without transplantation [11].

Our patient had a very impressive initial response to chemotherapy during the first 6 months. However, the tumour soon recurred. Although the lack of myocardial adhesions and distant metastatisation allowed surgical exeresis, and despite prolonged intensive chemotherapy, the patient died because of pericardial recurrence. This is one of the longest survivals of a patient with cardiac angiosarcoma, in a patient with a relatively localised tumour.

References

1. Silverman NA. Primary cardiac tumor. *Ann Surg*, 1980; 191: 127–138.
2. Blondeau PH. Primary cardiac tumours. French studies of 533 cases. *Thorac Cardiovasc Surg*, 1990; 38: 192–196.
3. Dichek DA, Holmvang G, Fallon JT. Angiosarcoma of the heart: three-year survival and follow-up by nuclear resonance imaging. *Am Heart J*, 1988; 115: 1323–1324.
4. Putnam JB Jr, Sweeney MS, Colon R et al. Primary cardiac sarcomas. *Ann Thorac Surg*, 1991; 51: 906–910.
5. Kurian KK, Weisshaar D, Parekh H et al. Primary angiosarcoma: case report and review of the literature. *Cardiovascular Pathology*, 2006; 15: 110–112.
6. Herrmann MA, Shankerman RA, Edwards WD et al. Primary cardiac angiosarcoma: a clinico-pathological study of six cases. *J Thorac Cardiovasc Surg*, 1992; 103: 655–654.
7. Qingyi M, Hong L, Lima J et al. Echocardiographic and pathological characteristics of primary cardiac tumors: a study of 149 patients. *Int J Card*, 2002; 84: 69–75.
8. Grande AM, Ragni T, Vigano M. Primary cardiac tumors. A clinical experience of 12 years. *Tex Heart Inst J*, 1993; 20: 223–230.
9. Tremaine LA, Gaertner EM. Persistent hemopericardial effusion in a 54-year-old-man. *Arch Pathol Lab Med*, 2005; 129: 117–118.
10. Cantella T, Oliva E, Andrade IG et al. A patient with cardiac angiosarcoma who survived for four years. Case report and literature review. *Rev Esp Cardiol*, 2005; 58: 310–312.
11. Kakizaki S, Takagi H, Hosaka Y. Cardiac angiosarcoma responding to multidisciplinary treatment. *Int J Cardiol*, 1997; 62: 273–275.