

Case report

## Chiropractic manipulation: Reasons for concern?

Liliana Olim Gouveia<sup>a,\*</sup>, Pedro Castanho<sup>b</sup>, Joaquim J. Ferreira<sup>c</sup>,  
Miguel Moura Guedes<sup>d</sup>, Filipa Falcão<sup>a</sup>, Teresa Pinho e Melo<sup>a</sup>

<sup>a</sup> Department of Neurology, Hospital de Santa Maria, Av. Prof Egas Moniz, 1649-035 Lisbon, Portugal

<sup>b</sup> Department of Neurosurgery, Hospital de Sao Jose, Lisbon, Portugal

<sup>c</sup> Neurological Clinical Research Unit, Institute of Molecular Medicine, Lisbon, Portugal

<sup>d</sup> Department of Neurosurgery, Hospital de Santa Maria, Lisbon, Portugal

Received 16 April 2007; received in revised form 31 July 2007; accepted 10 August 2007

### Abstract

Chiropractic's popularity is rising among the general population. Moreover, few studies have been conducted to properly evaluate its safety. We report three cases of serious neurological adverse events in patients treated with chiropractic manipulation. The first case is a 41 years old woman who developed a vertebro-basilar stroke 48 h after cervical manipulation. The second case represents a 68 years old woman who presented a neuropraxic injury of both radial nerves after three sessions of spinal manipulation. The last case is a 34 years old man who developed a cervical epidural haematoma after a chiropractic treatment for neck pain.

In all three cases there were criteria to consider a causality relation between the neurological adverse events and the chiropractic manipulation. The described serious adverse events promptly recommend the implementation of a risk alert system.

© 2007 Elsevier B.V. All rights reserved.

**Keywords:** Spinal manipulation; Chiropractic; Adverse events; Safety

### 1. Introduction

Chiropractics are defined as a health profession concerning the mechanical disorders of the musculoskeletal system, with emphasis on manual treatments including spinal manipulation or adjustment [1]. Although the evidence about its efficacy is often contradictory because of the low quality of the clinical trials, the heterogeneity of the interventions and the diversity of the targeted populations, chiropractic interventions have recently gain a renew interest among health professionals and the general population. For instance, for the treatment of neck pain, several systematic reviews and randomized controlled trials found limited evidence that manipulation or mobilisation improved symptoms compared with other or no treatment [2–8]. Although safety data from properly designed randomized controlled trials are scarce and sometimes inconclusive [9], there is a generalized belief that they correspond to safe treatments. We report three cases of

serious neurological adverse events in patients after receiving chiropractic treatment.

### 2. Case report

#### 2.1. Case 1

A 41 years old woman, with no relevant past medical history sought chiropractic treatment for neck pain with 2 months duration. She was submitted to one session consisting mainly of cervical manipulation. Three hours later, she complained of vertigo and experienced quick improvement within the next hours; in the next day she described a similar transient episode. Forty-eight hours after the cervical manipulation she noticed a sudden occipital headache followed by progressive consciousness deterioration and cardio-respiratory failure mandating mechanical ventilation for 24 h.

After regaining spontaneous ventilation, neurological examination revealed that she was afagic and hypofonic, with

\* Corresponding author.

E-mail address: lilianafog@gmail.com (L.O. Gouveia).

a rotatory nistagmus, right Horner Syndrome with hypoalgesia of the right hemiface, weakness and hypoalgesia of the contralateral limbs and ipsilateral dysmetria.

A MR performed on admission disclosed an ischemic stroke in the vertebro-basilar territory. The angio-MR showed a filiform basilar artery with stenotic vertebral arteries suggesting bilateral dissection. Transcranial Doppler showed asymmetric flow velocities between the vertebral arteries with increased flow resistance in the right. Conventional digital subtraction angiography confirmed the diagnosis of bilateral vertebral dissection (Fig. 1).

Routine laboratory tests, including erythrocyte sedimentation rate (ESR), serum homocysteine, total cholesterol, and triglyceride levels, were all unremarkable. Performed serologies (antibodies anti-HIV, VDRL, TPHA) were also normal. Vasculitides and prothrombotic status were excluded. Imaging of the abdominal vasculature, including the renal arteries, was normal.

The patient was placed on heparin and started rehabilitation, with only partial resolution of her symptoms at discharge (Rankin 3).

## 2.2. Case 2

A 68 years old woman with a past medical history of osteoporosis had three sessions of chiropractics for a cervical and low-back pain; in each session she was submitted to compression and traction of multiple musculoskeletal segments. Ten days later, as she experienced no improvement, she received a manual treatment that included bilateral suspension by the axillary regions. On the next day, she developed paresthesias involving mainly her left thumb, rapidly progressing to dorsiextension palsy of her wrist. Three days later, the same symptoms started on the right upper limb.

On the emergency room a bilateral wrist drop was documented and she was hospitalised.

Electromyography was compatible with a neuropraxic injury of both radial nerves. Serologic tests were made to exclude an infectious cause (namely HIV 1 and 2, CMV, VDRL, TPHA). Vasculitides were also excluded. Sleep paralysis and REM sleep behaviour disorder were appropriately ruled-out.

The patient initiated physiotherapy and presented a full recovery at the 2 months follow-up visit.

## 2.3. Case 3

A 34-year-old man complained of cervical pain, compelling him to seek for chiropractic treatment. A few hours after having cervical manipulation he noticed weakness and hypoalgesia involving the whole trunk and limbs.

He was admitted in the Emergency Department of our Hospital and a tetraparalysis (grade 3 on the MRC scale) was documented, with C5–C6 level of algic hypostesy.

A cervical MR disclosed an epidural haematoma between C3 and C6 vertebrae (Fig. 2). An underlying bleeding disorder was excluded.

Emergency laminectomies of C3–C6 with removal of the haematoma were performed, leading to a full recovery.

## 3. Discussion

We describe three cases of serious adverse events requiring hospitalisation (two of which life-threatening) following chiropractic manipulation. In all cases there were criteria to consider a causality relation between the neurological disorders and chiropractic manipulation: consistency of time of exposure to neurological deficit onset, clinical plausibility, lack of identified concomitant factors and lack of alternative explanation [10]. We recognise the limitations of these case reports. We were not able to judge the adequacy of the technical approaches (we only described the manoeuvres mentioned by the patients), and as a consequence we cannot exclude the possibility the adverse events resulted from malpractice and not from the therapeutic intervention itself. In all cases it cannot be excluded with complete certitude a temporal bias meaning that the reason why patients asked for

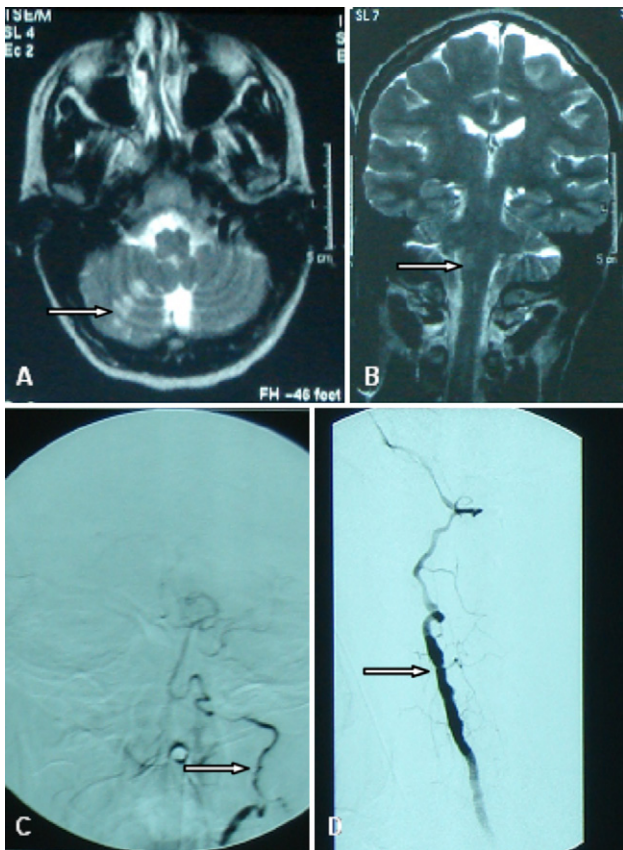


Fig. 1. (A and B) Axial T2-weighted images show an acute ischemic lesion in the territory of the right PICA; the coronal view discloses also ischemic lesions in the homolateral medulla oblongata; (C and D) the digital subtraction angiography shows irregularity and narrowing of both vertebral arteries above C2–C3, with the absence of the right PICA.

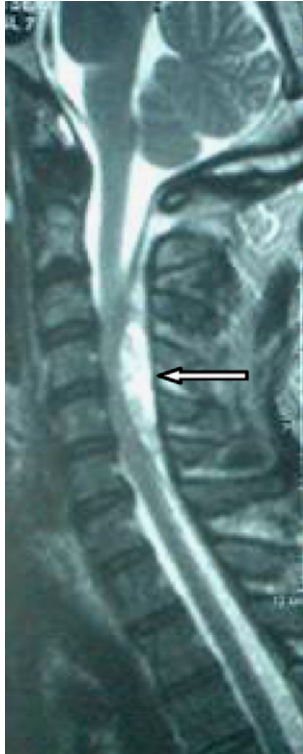

Fig. 2. Sagittal T2-weighted images showing an epidural haematoma between C3 and C6.

a chiropractic treatment was already the onset of the adverse event reported. A pragmatic approach recommends appraising these events as they happened independently of these limitations.

Despite the increasing number of randomized controlled trials focused on its efficacy for the treatment of a multitude of diseases [11–16], the benefits of chiropractics are still not well established [9]. On the other hand, there is only one controlled trial published concerning the safety profile [17]. Although several observational studies describe the adverse events associated with chiropractic manipulation [18–20], the true incidence, risk factors and type of events are still unknown [21,22]. A survey from the Danish Chiropractors Association attempted to estimate the occurrence of cerebrovascular accidents (CVA) after chiropractic treatment to the cervical spine. One case of CVA appeared for every estimated 1.3 million cervical treatment sessions and 1 for every 0.9 million upper cervical treatment sessions. Rotation procedures to the upper cervical spine were almost twice as often linked to CVI as nonrotation procedures of that area [23,24]. A survey of 177 neurologists in California reported 55 strokes, 16 myelopathies, and 30 radiculopathies. Most of the patients continued to have persistent neurologic deficits 3 months after the onset, and about one-half had marked severe deficits [25].

Chiropractic by not being a drug nor a medical device has not been submitted to formal evaluation by the medicinal agencies. Similarly, its safety profile escapes to the phar-

macovigilance networks. In our opinion, the serious adverse events we describe, promptly recommend the implementation of a system to signal a risk alert. This recommendation gains even more relevancy when it is expected a growing number of patients exposed due to the renew interest among health professionals and the general population.

## References

- [1] Homola S. Chiropractic: history and overview of theories and methods. *Clin Orthop Relat Res* 2006;444:236–42.
- [2] Conlin A, Bhogal S, Sequeira K, Teasell R. Treatment of whiplash-associated disorders—part I: non-invasive treatment. *Pain Res Manag* 2005;10(81):21–32.
- [3] Sarig-Bahat H. Evidence for exercise therapy in mechanical neck disorders. *Man Ther* 2003;8(1):10–20.
- [4] Update Quebec Task Force on Whiplash Related Disorders; January 2001.
- [5] Koes BW, Assendelft WJ, Van der Heijden GJ, et al. Spinal manipulation and mobilisation for back and neck pain: a blinded review. *BMJ* 1991;303:1298–303.
- [6] Kjellman GV, Skargren EI, Oberg BE. A critical analysis of randomised clinical trials on neck pain and treatment efficacy. A review of the literature. *Scand J Rehabil Med* 1999;31:139–52.
- [7] Aker PD, Gross AR, Goldsmith CH, et al. Conservative management of mechanical neck pain: systematic overview and meta-analysis. *BMJ* 1996;313:1291–6.
- [8] Hurwitz EL, Aker PD, Adams AH, et al. Manipulation and mobilization of the cervical spine: a systematic review of the literature. *Spine* 1996;21:1746–60.
- [9] Morley J, Rosner AL, Redwood D. A case study of misrepresentation of the scientific literature: recent reviews of chiropractic. *J Altern Complement Med* 2001;7(1):65–78.
- [10] Guideline for proposing case clinical safety information of drugs. Reports of CIOMS working group III; 1995.
- [11] Hurwitz EL, Morgenstern H, Kominski GF, Yu F, Chiang LM. A randomized trial of chiropractic and medical care for patients with low back pain: eighteen-month follow-up outcomes from the UCLA low back pain study. *Spine* 2006;31(6):611–21.
- [12] Bove G, Nilsson N. Spinal manipulation in the treatment of episodic tension-type headache. A randomized controlled trial. *J Am Med Assoc* 1998;280(18):1576–9.
- [13] Walsh M, Polus B. A randomized, placebo-controlled clinical trial on the efficacy of chiropractic therapy on premenstrual syndrome. *J Manipulative Physiol Ther* 1999;22(9):582–5.
- [14] Balon J, Aker PD, Crowther ED, Danielson C, Cox PG, O'Shaughnessy D, et al. A comparison of active and simulated chiropractic manipulation as adjunctive treatment for childhood asthma. *N Engl J Med* 1998;339(15):1013–20.
- [15] Tuchin PJ, Pollard H, Bonello R. A randomized controlled trial of chiropractic spinal manipulative therapy for migraine. *J Manipulative Physiol Ther* 2000;23(2):91–5.
- [16] Olafsdottir E, Forshei S, Fluge G, Markestad T. Randomised controlled trial of infantile colic treated with chiropractic spinal manipulation. *Arch Dis Child* 2001;84:138–41.
- [17] Hurwitz EL, Morgenstern H, Vassilaki M, Chiang LM. Frequency and clinical predictors of adverse reactions to chiropractic care in the UCLA neck pain study. *Spine* 2005;30(13):1477–84.
- [18] Smith WS, Johnston SC, Skalabrin EJ, Weaver M, Azari P, Albers GW, et al. Spinal manipulative therapy is an independent risk factor for vertebral artery dissection. *Neurology* 2003;60(9):1424–8.
- [19] Assendelft WJ, Bouter LM, Knipschild PG. Complications of spinal manipulation: a comprehensive review of the literature. *J Fam Pract* 1996;43(4):475–80.

- [20] Rothwell DM, Bondy SJ, Williams JJ. Chiropractic manipulation and stroke: a population-based case-control study. *Stroke* 2001;32(5):1054–60.
- [21] Haldeman S, Carey P, Townsend M, Papadopoulos C. Clinical perceptions of the risk of vertebral artery dissection after cervical manipulation: the effect of referral bias. *Spine J* 2002;2(5):334–42.
- [22] Nelson CF, Metz RD, LaBrot TM, Pelletier KR. The selection effects of the inclusion of a chiropractic benefit on the patient population of a managed health care organization. *J Manipulative Physiol Ther* 2005;28(3):164–9.
- [23] Klougart N, Leboeuf-Yde, Rasmussen LR. Safety in chiropractic practice. Part I: The occurrence of cerebrovascular accidents after manipulation to the neck in Denmark from 1978–1988. *J Manipulative Physiol Ther* 1996;19(6):371–7.
- [24] Klougart N, Leboeuf-Yde, Rasmussen LR. Safety in chiropractic practice. Part II: Treatment to the upper neck and the rate of cerebrovascular incidents. *J Manipulative Physiol Ther* 1997;19(6):371–7.
- [25] Lee KP, Carlini WG, McCormick GF, Albers GW. Neurologic complications following chiropractic manipulation: a survey of California neurologists. *Neurology* 1995;45(6):1213–5.