

Journal section: *Oral Medicine and Pathology*
Publication Types: *Research*

doi:10.4317/jced.2.e67

Frozen section evaluation of lymph nodes in Oral squamous cell carcinoma – A retrospective study.

Dinkar K. Desai¹, G.S. Kumar²

¹ Professor and Head, Dept. Oral Pathology, A.J. Institute of Dental Sciences, Mangalore, Karnataka, India.

² Principal and Professor of Oral Pathology, K.S.R. Institute of Dental Science & Research, Tiruchengode, Namakkal, Tamilnadu, India.

Correspondence:

Department of Oral & Maxillofacial Pathology
A.J. Institute of Dental Sciences
N.H.17, Kuntikana, Mangalore-575004
Karnataka, India.
dinkar22desai@gmail.com

Received: 31/12/2009

Accepted: 03/03/2010

Desai DK ,Kumar GS. Frozen section evaluation of lymph nodes in Oral squamous cell carcinoma – A retrospective study. J Clin Exp Dent. 2010;2(2):e67-70.
<http://www.medicinaoral.com/odo/volumenes/v2i2/jcedv2i2p67.pdf>

Article Number: 678936 <http://www.medicinaoral.com/odo/indice.htm>
© Medicina Oral S. L. C.I.F. B 96689336 - eISSN: 1989-5488
eMail: jced@jced.es

Abstract

The principal indication of performing a frozen section is to obtain a definite immediate diagnosis, on the basis of which a surgical decision will be made. Immediate diagnosis allows the surgeon to proceed with further therapy without any delay. A definite immediate diagnosis is said to be dependent on the reliability of frozen sections.

Many authors have carried out frozen section study on soft tissue tumors and lymph node evaluation in different parts of the body with varying percentages of reliability. However, it appears that lymph node evaluations specifically in oral squamous cell carcinoma cases were not performed, or limited. Hence the present study was undertaken to determine the reliability of frozen section diagnosis in the lymph nodes of oral squamous cell carcinomas. This study was performed so that the surgeons would have an intraoperative assessment of the extent of local metastasis and to determine the adequacy of resection before the wound is closed.

The objectives of the present study are to assess microscopically the frozen section of the palpable and non palpable lymph nodes of neck for metastasis in patients with squamous cell carcinoma of oral cavity. To compare the microscopic features of paraffin embedded lymph node sections with those of frozen sections. To assess the reliability of frozen section evaluation of cervical lymph nodes in oral squamous cell carcinoma.

The present research work gives 100% accuracy of frozen sections with due care by additional staining to frozen sections by phloxine methylene blue stain, however cannot be in any way superior to the magnetic resonance imaging, computed tomography, immunoscintigraphy and lymphangioscintigraphy.

Key words: *Frozen sections, reliability, cervicofacial region, lymph nodes, oral squamous cell carcinoma.*

Introduction

The frozen section technique is now a well established procedure for rapid diagnosis of specimens. This procedure serves the surgeon by providing the diagnosis, tissue recognition, extent of resection and thus helps in making the therapeutic decision (1).

Many comparative studies regarding frozen and paraffin sections were extensively done to find out the reliability of frozen sections in the diagnosis of prostrate carcinoma, breast cancer, skin cancer, tumors of colon, gall bladder, kidney, head and neck neoplasm (2).

Reliability of frozen sections in lymph node evaluation has been done in prostrate carcinoma, breast cancer, head and neck neoplasm etc, but due to paucity of specific studies relating to cervical lymph nodes in oral squamous cell carcinoma, this study was undertaken.

The present study gives information about the reliability of frozen section evaluation of cervical lymph nodes in oral squamous cell carcinoma. The microscopic features of frozen sections are compared with those of paraffin embedded lymph node sections.

Materials and methods

The study was carried out by collecting a total number of 60 fresh lymph nodes from the resected tumor masses of cervicofacial regions of 30 patients reporting to the Department of Oral and Maxillofacial Surgery. The selected patients were of varying age groups and with preoperative diagnosis of oral squamous cell carcinoma. The collected lymph nodes belonging to the different sites were submandibular, right supra clavicular, cervical, jugulomyoid, superior cervical, external jugular, buccal and jugular nodes.

Frozen sections were stained both by hematoxylin eosin (H&E) and Phloxine methylene blue stain and they were compared with paraffin sections. The reliability of frozen section diagnosis in detecting its accuracy, specificity, false positivity, false negativity, predictive value of positivity and negativity and its efficiency in terms of percentage were estimated.

The materials required for the frozen section study are: 1. Clarke's fluid, 2. Phloxine-methylene blue stain, 3. H&E stain, 4. Lithium carbonate, 5. Embedding media and 6. DPX (mounting media).

The equipments are: 1. Cryostat (Leica CM 1900), 2. Microscope with photomicrograph facility.

The lymph node was cut into 2 halves, one half chosen for frozen section study and the other half for paraffin section study. A total of 6 sections were obtained from each lymph node, 4 sections for frozen study and 2 sections for paraffin study. In frozen study 2 sections were stained with H&E stain and other 2 sections with phloxine methylene blue stain. Thus a total of 360 sections were observed.

The cryostat cabinet temperature was adjusted to -20

°C to -25 °C. The lymph node requires a specimen head temperature ranging from -15°C to -25°C to obtain proper frozen sections of 6µ thickness. The sections were fixed in Clark's fluid for 1 to 2 minutes then stained with Harris hematoxylin stain for 2 to 3 minutes and immersed in lithium carbonate solution for 30 -60 seconds later counter stained with eosin for 1 minute. Each time before staining, the slides were washed in running water for 1 to 2 minutes.

The frozen sections were also stained with phloxine methylene blue stain which gives a clear picture with better nuclear definition than H&E stain. The slides were placed in Clarke's fluid for 1 to 2 minutes, and then they were placed in 90% alcohol for 2 seconds, followed by absolute alcohol for 2 seconds. The slides were then immersed in xylene and agitated till they were clear. The slides were then placed in alcohol for 2 seconds followed by 90% alcohol for 2 seconds and flooded with water for 10 seconds. The slides were kept in phloxine for 1 minute and wash in running water, then stain with methylene blue for 30 seconds and wash with 2% acetic acid in distilled water for 20 to 30 seconds. The slides were then washed with 96% alcohol for differentiation later flooded with absolute alcohol and blotted dry. The slides were then cleared in xylene and mounted in DPX solution. Routine hematoxylin and eosin staining procedure was done for paraffin sections.

Results

The results were obtained after careful microscopic observation of 360 sections. The six sections of each lymph node for the frozen and paraffin study were observed to know the metastasis or disease in the lymph node. The frozen sections stained with H&E and Phloxine methylene blue were observed to confirm the presence or absence of metastasis. These were then compared with the paraffin sections of H&E stain. If both frozen and paraffin sections show presence of metastasis then they were taken as true positive sections (T+) (Fig. 1,2).

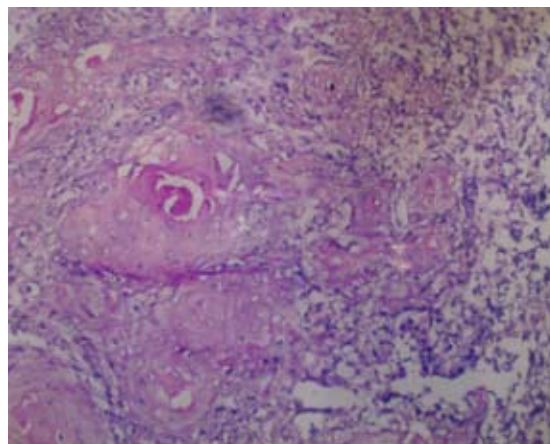


Fig. 1. Frozen section stained with Phloxine methylene blue stain showing the features of lymph node metastasis (T+).

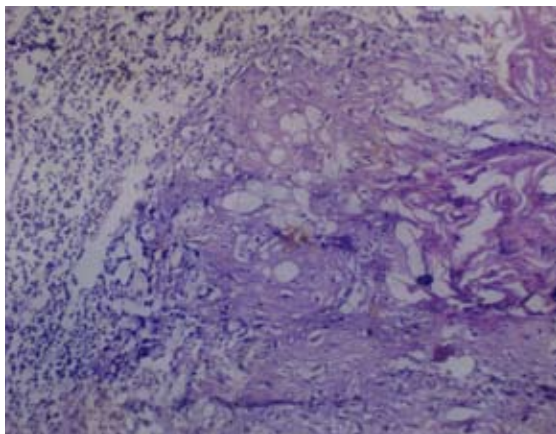


Fig. 2. Paraffin section stained with Hematoxylin & eosin stain showing the features of lymph node metastasis (T+).

If both the sections were free from lymph node metastasis then they were taken as true negative sections (T-). A meticulous observation of these sections will minimize or eliminate the errors of frozen and paraffin sections such as false positive (F+) and false negative (F-). Similar observations were done with all the frozen and paraffin sections of lymph nodes (Table 1). These were tabulated and calculated according to the biostatistical nomenclature to obtain 100% accuracy (Table 2).

Discussion

The reliability of frozen sections in diagnosis of lesions in different regions of the body was varied in their accuracy from 91.5 to 98% (2-4) and in head and neck neoplasm, 96% to 99% (5,6).

Total Number of cases	Total Number of L.Ns	Total number of L.N sections	True positive sections (T+)	True negative sections (T-)	False positive sections (F+)	False negative sections (F-)
30	60	360	270	90	0	0

(T+ = correctly diagnosed as having the disease, T- = correctly diagnosed as free of disease, F+ = incorrectly diagnosed as having the disease, F- = incorrectly diagnosed as free of disease, L.N = Lymph node)

Table 1. Tabulation of true positive, true negative, false positive and false negative results based on comparative frozen and paraffin section findings.

Terminology	Definition	Biostatistical nomenclature	Percentage of reliability
Sensitivity	Probability of positive test when the disease is present	$\frac{T+ (x) 100}{T+ (+) F-}$	100 %
Specificity	Probability of negative test when the disease is not present	$\frac{T- (x) 100}{T- (+) F+}$	100%
False negative	Probability of negative test when the disease is present	$\frac{F- (x) 100}{T+ (+) F-}$	0
False positive	Probability of positive test when the disease is not present	$\frac{F+ (x) 100}{T- (+) F+}$	0
Predictive value of positive test	Probability of disease when test is positive	$\frac{T+ (x) 100}{T+ (+) F+}$	100%
Predictive value of negative test	Probability of no disease when test is negative	$\frac{T- (x) 100}{T- (+) F-}$	100%
Accuracy (efficiency)	Percent of all results that are true	$\frac{T+ (+) T-}{\text{Total tests}}$	100%

Table 2. Comparative statistical analysis of frozen with paraffin sections (3).

Regional lymph nodes for metastases have been largely studied in pelvic lymph nodes due to prostatic cancer. The accuracy of frozen section varied from 84% to 96.5% (7,8).

Few frozen sections studies of cervical lymph nodes for metastasis from aero digestive tract neoplasm were reported and the accuracy was determined to be 92.3% (9). Kumar et al. reported 100% accuracy in neoplasm of different sites which involved 14 cases of oral cancer (10).

The present study also has an accuracy of 100% and is also note worthy that both metastatic and nonmetastatic lymph nodes were seen. Though the sample size is smaller than the previous studies but is restricted to cervicofacial regions of oral squamous cell carcinoma thus obtaining 100% accuracy with due care is obvious.

The errors in the frozen section study outlined by Saltzstein and Nahum, and Holaday and Assor as sampling error, communicative errors, technical errors, grading errors, false positivity, false negativity and deferred diagnosis (11,12).

When the frozen sections were compared with paraffin sections for accuracy in diagnosis, false positivity, false negativity and disagreement were seen in other studies. The errors due to false positivity were ranged from 0.07% to 0.15% (2), false negativity were ranged from 0.7% to 10% (13,14) and the deferred diagnosis were 0.15% to 1.7% (2,15). However in the present study there were no errors and thus accurate frozen section diagnosis of lymph nodes were observed.

The predictive value of negative frozen section was said to be useful in clinical practice by providing direct information to the patient, as being free of disease (16). Our study has also fulfilled this objective.

Kaufman et al. explained in case of clinical suspicion of malignancy, more than one sample must be examined in order to decrease the false negative diagnosis in frozen section (1). However in the present study the suspected malignant cases were sectioned twice and stained with H&E and other with phloxine methylene blue stain. The phloxine methylene blue stain was used as it brings out nuclear details more clearly and hence 0% false negativity was observed.

Davis reported efficiency of frozen section diagnosis in assessment of pelvic lymph nodes for metastasis, when compared with MRI (magnetic resonance imaging), CT (computed tomography), Lymphangiography, ISG (immunoscintigraphy) and LSG (lymphangioscintigraphy) (3). However the 100% efficiency of frozen sections observed in this study cannot be in any way superior to the MRI, CT, ISG and LSG.

References

1. Kaufman Z, Lew S, Griffel B, Dinbar A. Frozen-section diagnosis in surgical pathology. A prospective analysis of 526 frozen sections. *Cancer*. 1986;57:377-9.

2. Prey MU, Vitale T, Martin SA. Guidelines for practical utilization of intraoperative frozen sections. *Arch Surg*. 1989;124:331-5.
3. Davis GL. Sensitivity of frozen section examination of pelvic lymph nodes for metastatic prostate carcinoma. *Cancer*. 1995;76:661-8.
4. Ackerman LV, Ramirez GA. The indications for and limitations of frozen section diagnosis; a review of 1269 consecutive frozen section diagnoses. *Br J Surg*. 1959;46:336-50.
5. Nakazawa H, Rosen P, Lane N, Lattes R. Frozen section experience in 3000 cases. Accuracy, limitations, and value in residency training. *Am J Clin Pathol*. 1968;49:41-51.
6. Remsen KA, Lucente FE, Biller HF. Reliability of frozen section diagnosis in head and neck neoplasms. *Laryngoscope*. 1984;94:519-24.
7. Epstein JI, Oesterling JE, Eggleston JC, Walsh PC. Frozen section detection of lymph node metastases in prostatic carcinoma: accuracy in grossly uninvolved pelvic lymphadenectomy specimens. *J Urol*. 1986;136:1234-7.
8. Kramolowsky EV, Narayana AS, Platz CE, Loening SA. The frozen section in lymphadenectomy for carcinoma of the prostate. *J Urol*. 1984;131:899-900.
9. Rassekh CH, Johnson JT, Myers EN. Accuracy of intraoperative staging of the NO neck in squamous cell carcinoma. *Laryngoscope*. 1995;105:1334-6.
10. Kumar RV, Mukherjee G, Bhargava MK. Frozen sections--a retrospective study. *Indian J Pathol Microbiol*. 1992;35:27-33.
11. Saltzstein SL, Nahum AM. Frozen section diagnosis: accuracy and errors; uses and abuses. *Laryngoscope*. 1973;83:1128-43.
12. Holaday WJ, Assor D. Ten thousand consecutive frozen sections. A retrospective study focusing on accuracy and quality control. *Am J Clin Pathol*. 1974;61:769-77.
13. Gephardt GN, Rice TW. Utility of frozen-section evaluation of lymph nodes in the staging of bronchogenic carcinoma at mediastinoscopy and thoracotomy. *J Thorac Cardiovasc Surg*. 1990;100:853-9.
14. Remacle M, Hamoir M, Marbaix E, Deggouj N, Frederickx Y. Interest in frozen section examination of margins and lymph nodes in laryngeal surgery. *J Laryngol Otol*. 1988;102:818-21.
15. Arora HL, Solanki RL, Gupta R. Evaluation of cryostat frozen section in the diagnosis of surgical biopsies. *Indian J Pathol Microbiol*. 1991;34:136-9.
16. Hermansen DK, Whitmore WF Jr. Frozen section lymph node analysis in pelvic lymphadenectomy for prostate cancer. *J Urol*. 1988;139:1073-4.

Acknowledgements

My special thanks to the staff members of S.D.M.College of Dental Sciences, Dharwad, Karnataka, India.