

Expression of p53 Protein and Tumor Angiogenesis as Prognostic Factors in Nasopharyngeal Carcinoma Patients*

L. Rubio¹, J.S. Burgos², J.A. Lopez-Guerrero³, C. Morera⁴,
F.J. Vera-Sempere¹

¹Service of Pathology II, Laboratory of Molecular Pathology, University Hospital La Fe, Medical School of Valencia University;

²Center of Molecular Biology "Severo Ochoa", CSIC-Autonomous University of Madrid;

³Department of Pathology, Medical School of Valencia; and

⁴Service of ORL, University Hospital La Fe, Valencia, Spain.

Summary

The objective of this study was to evaluate the possible prognostic significance of p53 protein overexpression and tumor angiogenesis (TA) in nasopharyngeal carcinoma (NPC) patients, together with other clinicopathological variables. Forty-two NPC patients were evaluated in relation to survival. Nuclear p53 overexpression in neoplastic and endothelial cells was detected by immunohistochemistry (IHC) with the monoclonal antibody DO-7 and the polyclonal antibody against factor VIII-related antigen, respectively. Thereafter, we evaluated p53 cases in order to determine their nuclear immunoreactivity from negative (-) to positive (+, ++, +++). In addition, microvessels were counted in the most active areas of tumor neovascularization or *hotspots* using an image computer analyzer (MicroImage®).

A Cox multiple regression survival analysis was used to determine the best prognostic indicators in NPC patients. As a result, tumor microvessel count, considered as a continuous variable, was the most important independent prognostic indicator in relation to survival ($p = 0.0273$), with a relative risk of death of 2,4399 [95% confidence interval = 1.1051 ; 5.3871] associated with the highest microvessel counts. Moreover, the only clinicopathological variable that demonstrated prognostic value in a Cox multiple regression survival analysis was histological type ($p = 0.05$). In addition, we did not

observe any statistical association between intratumoral microvessel density (IMD), clinicopathological variables and p53 protein expression.

Key words: p53 protein – Angiogenesis – Morphometry – Prognosis – Nasopharyngeal carcinoma

Introduction

Nasopharyngeal carcinoma (NPC) is the most common epithelial malignancy of the nasopharynx and is strongly associated with the EBV virus [16, 34, 35]. Due to its particular biologic behavior, patients in similar stages of NPC demonstrate different clinical outcome and responses to the same treatment. In order to achieve a more reliable prognostic evaluation of such patients, we sought to identify other prognostic indicators that could be used in conjunction with other well-established factors to obtain a better therapeutic approach.

The p53 tumor suppressor gene is a regulator of normal cell growth and also plays an important role in the apoptosis mechanism [14]. There is evidence that the p53

* This work was supported in part by grant 99/0454 from the Fondo de Investigaciones Sanitarias (FIS), Madrid.

Address for correspondence: F.J. Vera-Sempere, Service of Pathology, University Hospital La Fe, Avda. Campanar 21, 46009-Valencia, Spain.

Phone: +34-6-963862799; Fax: +34-6-963868789

protein is involved in the cell cycle by regulating the G₁-S transition after DNA damage [3]. This gene frequently appears mutated in many different human tumors. For this reason, the nuclear p53 phosphoprotein is very often altered in the majority of such neoplasms [18]. The p53 mutated protein has a half-life increase, regarding the wild type, that permits detection using IHC procedures [6]. Overexpression of p53 protein revealed by IHC has proven a reliable prognostic indicator in certain human tumors [27], although some contradictory results exist [39]. We evaluated the expression of p53 protein in order to elucidate its possible prognostic role in NPC patients.

Angiogenesis, the growth of new capillary blood vessels, is on the other hand essential in normal processes such as wound healing; it also has proven to be necessary for the growth and metastatic spread of solid neoplasms [4, 11], including head and neck cancer. A fragmented basement membrane of newly-formed capillaries increases the likelihood of tumoral cell invasion. Moreover, several observations have proposed that IMD is associated with overall survival in various tumor types; further, in the past decade, angiogenesis has been incorporated as a new prognostic indicator in the evolution of many malignant neoplasms [5, 11, 15, 21, 27, 29, 32, 37, 38].

Patients and Methods

Patients

In a retrospective study we examined tumor specimens from 54 patients with NPC (35 men and 19 women, mean age 49) morphologically diagnosed and treated at University Hospital La Fe between 1977 and 1994 at University Hospital La Fe. Follow-ups ranged from 2 to 120 months (average 34 months). Seven cases were excluded because they contained metastatic tissue (13%), and 5 cases (9%) because of scanty tissular material in original paraffin blocks. Hence, when this study was carried out with 42 primary neoplasms, 29 patients had died and 13 were alive. Histological diagnosis of the 42 cases was done according to Micheau's scheme [17], which accepts two major microscopical types. Thus, 33 cases (79%) were considered as UCNT (undifferentiated carcinoma of nasopharyngeal type) and 9 (21%) as SCC (squamous cell carcinoma).

Antibodies

Tumoral cells were IHC stained using the DO-7 monoclonal antibody (DAKO, Denmark) that recognizes an epitope in the N-terminal of the human p53 protein between amino acids 35 and 45. This DO-7 antibody is highly recommended for retrospective studies on paraffin-embedded samples [9, 23, 31]. The DO-7 monoclonal antibody was diluted 1:100 and displayed by the streptavidin-biotin complex method [12]. Negative controls were carried out in every case by omitting the primary and secondary antibodies, respectively, from the IHC procedure. Additionally, a p53-positive control was done with a known p53-positive case. We evaluated p53 protein expression by the percentage of tumoral cells showing nuclear signal. A case was labelled as positive when some tumoral cells

showed nuclear staining, and we assigned three positive grades (+, ++, +++). We employed different positive grades depending on the number of tumoral cells expressing p53 protein, and depending on their high or low immunostaining.

Intratumoral microvessels were highlighted by staining endothelial cells using the polyclonal antibody against factor VIII-related antigen (von Willebrand factor, Biomedica Corp., USA). IHC staining was carried out by the streptavidin-biotin complex method. It was thus possible to identify the most intensely vascularized areas of the tumors. Negative controls were done in every case by omitting the primary and secondary antibodies, respectively, from the IHC procedure.

Immunohistochemistry (IHC)

IHC staining was done by the streptavidin-biotin complex method. Formalin-fixed and paraffin-embedded 4 μ m-thick sections were evaluated. Sections were dewaxed and microwave treated to retrieve the antigens. Later they were incubated in 3% hydrogen peroxide in methanol for 10 min to block endogenous peroxidase activity, followed by washing in phosphate-buffered saline PBS (Biomedica Corp., USA). Predigestion of the tissue was carried out by incubating the sections for 10 min at 37 °C in trypsin 1mg/ml PBS, then washing in PBS for 5 min. Sections were then incubated in bovine serum albumin to reduce unspecific staining, followed by incubation with the primary antibody for 30 min at room temperature. After washing in PBS for 5 min, sections were incubated with biotinylated secondary antibody (Dako, Denmark) and thereafter incubated with streptavidin conjugated to horseradish peroxidase at room temperature (Dako, Denmark). The peroxidase reaction was developed using 3,3'-diaminobenzidine tetrahydrochloride 5% as chromogen (Dako, Denmark), and sections were counterstained with hematoxylin (Dako, Denmark).

Intratumoral microvessel density (IMD)

IMD was observed in areas of most intense neovascularization or "hotspots" by scanning the tumor sections at low power (40 \times and 100 \times) and identifying areas of invasive tumor with the greatest number of discrete microvessel staining per area (Fig. 2). Microvessels were automatically counted using an image computer analyzer on a 250 \times field in the "hotspot". An image of each slide was captured digitally using a CCD camera connected to an image computer analyzer (MicroImage®). The CCD camera was attached to an Olympus CH-2 microscope. However, the slide image captured by the computer had a field on the TV screen of 0.5028 mm². We then proceeded with RGB digital color images, establishing the brown color range of the microvessel staining and selecting a single, countable microvessel by computer. Any brown-staining endothelial cell or cell cluster that was clearly separated from adjacent microvessels was considered as a single, countable microvessel. A vessel lumen was not required for identification; microvessels with a greater diameter (> 50 μ m) were excluded from the study, in accordance with Weidner et al. [38]. Each count was expressed as the highest number of microvessels identified within any 250 \times field.

Statistics

All statistical analyses were carried out using the SPSS-X statistical computer package (SPSS Inc, Chicago) for Windows 9.0. Univariate analysis by Student's t test and Mann-Whitney

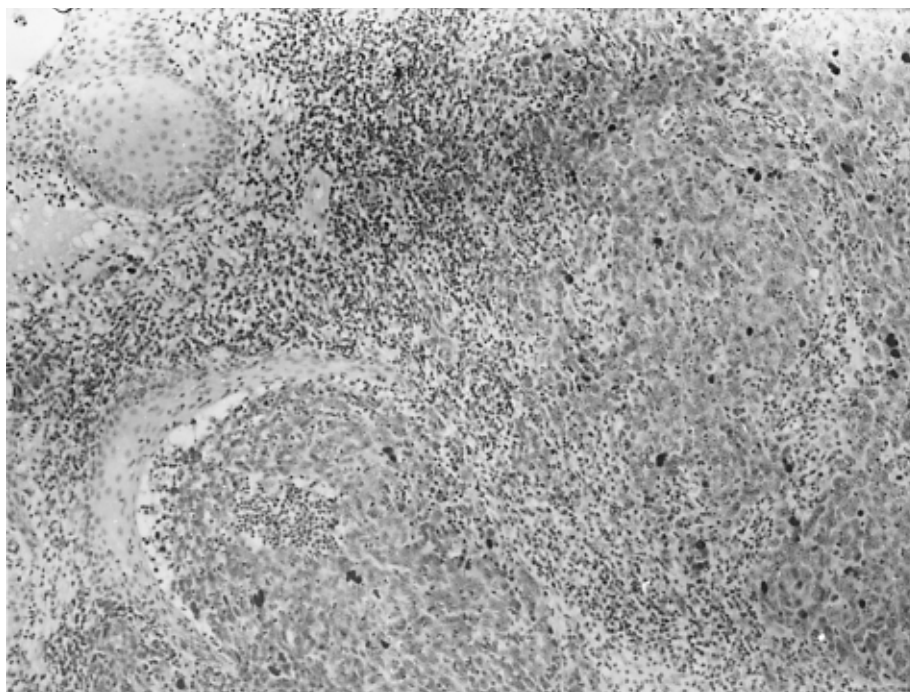

Fig. 1. Intense p53 immunostaining observed in the nuclei of some tumoral cells in an undifferentiated carcinoma case (UCNT) (200 \times).

method was used to assess differences between angiogenesis in relation to clinicopathological variables and p53 expression. A Chi-square test with Fisher's correction was used for categorical variables to analyze the associations between p53 expression and clinicopathological variables. At the least, a Cox multiple regression survival analysis was done to determine the best independent prognostic indicators in NPC patients. A p value less than 0.05 was considered significant [1, 13].

Results

p53 protein expression

p53 immunostaining was observed in the nuclei of tumoral cells (Fig. 1). Cases were labelled in different groups according to their immunoreactivity intensity and the number of p53-positive cells. We then evaluated the p53 expression from negative (-) to positive (+, ++, +++). For better statistical study we created two groups including negative (-) and low (+) p53 staining compared to high p53 staining (++, +++). With respect to p53 expression, four of the nine (44%) SCC cases showed high (++, +++). Moreover, all advanced IV-stage cases showed high p53 (++, +++). Additionally, none of the 9 poor prognosis-SCC cases was metastasis-positive. When a Cox multiple regression survival analysis was done, p53 expression failed to demonstrate any prognostic value ($p = 0.9953$).

Correlation between IMD and p53 expression

Mean and median values for IMD were 37 vessels. Upon comparing IMD in relation to p53 expression, we

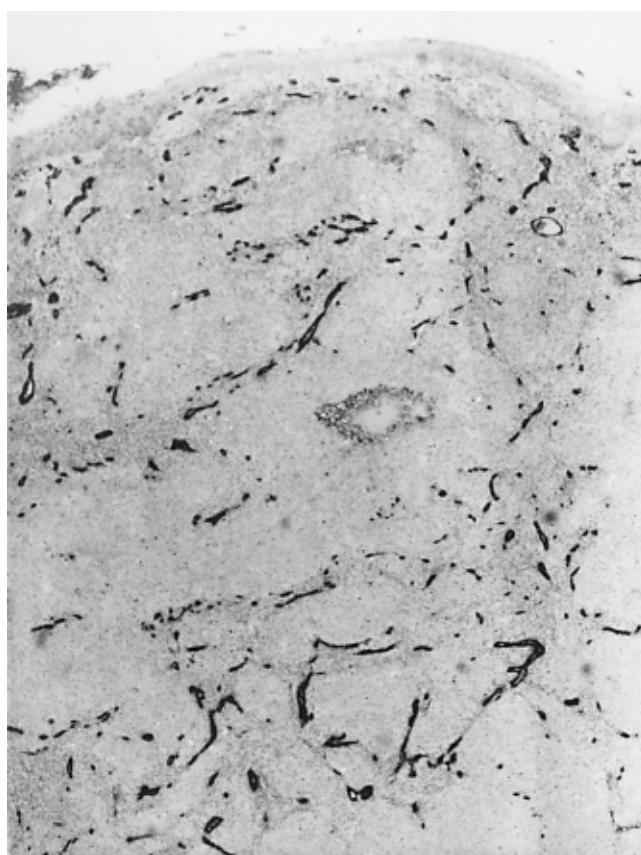


Fig. 2. Microvessels stained for anti-von Willebrand factor (Factor VIII) in a nasopharyngeal carcinoma biopsy. Intratumoral microvessel density (IMD) was determined in the most intensely neovascularized area or "hotspots" (125 \times).

did not observe any statistical association ($p > 0.05$). Cases with p53 (-) and p53 (+, ++, +++) expression were separated and compared with their microvessel mean count; cases were also divided into negative or low p53 staining (-, +) versus positive or high p53 staining (++, +++) and no statistical correlation was observed in either case (Table 1).

Angiogenesis correlated with clinicopathological variables

We analyzed certain clinicopathological variables, such as tumoral type (UCNT and SCC), tumor size (T), stage (I, II, III, IV), metastasis (M), sex and patient age (mean and median = 49 years) in relation to angiogenesis. Sta-

Table 1. Correlation between tumor microvessel count, clinicopathological variables and p53 expression

Variable	Group	No. Patients	Vessels* (mean group)
Histological Type	UCNT	33	37
	SCC	9	34
Tumor size	T = 1/T = 2	15	31
	T = 3/T = 4	27	39
Tumor stage	I, II, III,	6	38
	IV	36	36
Metastasis	negative	30	35
	positive	12	40
Sex	men	26	34
	women	16	40
Age	≥ 49	22	38
	< 49	20	35
p53 expression	(-)	29	37
	(+, ++, +++)	13	37
	(-, +)	33	37
	(++, +++)	9	35

*Mann-Whitney method and Student's t test ($p > 0.05$)

Table 2. Significant independent prognostic indicators in NPC patient-related death

Multivariatic analysis*			
Prognostic factor	P-value	Relative risk ¹	95% CI ²
Histological type	0.05	0.5363	(0.2789; 1.0315)
p 53 expression	0.9953	0.9976	(0.4488; 2.2176)
Microvessel count	0.0273	2.4399	(1.1051; 5.3871)

*Cox multiple regression survival analysis,

¹of death associated with histological type, p53 expression or microvessel count, ²confidence interval for relative risk.

tistical analysis was done using the Student's t-test, plus a non-parametric test (Mann-Whitney). Both methods failed to reveal differences between clinicopathological variables and microvessel count. Therefore, angiogenesis appears to be a possible independent factor apart from histological type, size, stage, metastasis, sex and age (Table 1).

Prognostic indicators in NPC patients

Furthermore, we used a multivariate analysis to determine the best prognostic indicators in NPC patients. The multiple analysis was done by a Cox multiple regression survival model, which revealed two significant prognostic indicators of survival patients, namely histological type (SCC-tumoral type had a poor prognosis compared to UCNT, $p = 0.05$), and tumor microvessel count, considered as a continuous variable ($p = 0.0273$). As a result, angiogenesis was the most important independent prognostic indicator in relation to survival, with a relative risk of death of 2,4399 [95% confidence interval = 1,1051; 5,3871] associated with the highest microvessel counts (Table 2).

Discussion

We studied 42 NPC cases to establish a possibly significant correlation between p53 expression, angiogenesis and other clinicopathological variables in order to determine the best independent prognostic indicators in NPC patients.

p53 protein expression was observed in the nuclei of tumoral cells. As was done in previous studies, cases were divided into two groups according to their immunoreactivity intensity and number of p53-positive cells [7, 9]. When a Cox multiple regression survival analysis was done, p53 expression did not demonstrate any prognostic value. However, other studies do show a correlation between p53 expression and overall survival in other tumoral types [7, 26], as in oral SCC cases [31]. Other reports show a statistical correlation between p53 gene mutation and overall survival, but without any correlation when an IHC study was done. Wood et al. [39], in SCC of the head and neck, reported that mutations of the p53 gene determined by PCR-SSCP were significantly associated with survival, but no significant association was observed when p53 expression was analyzed by IHC. In contrast, Rakozy et al. [23] reported that p53 IHC study and not PCR-SSCP was associated with survival in prostate cancer. These results demonstrate that there is no perfect correlation between p53 gene mutations and the mutant protein expression. For this reason, some authors conclude that p53 expression in head and neck cancer is not a reliable predictor of survival [39].

When all microvessels were stained, angiogenesis was assessed as density of microvessels in the most intensively neovascularized areas or “hotspots” so as to reflect the tumor activity and its development. Weidner et al. [38] obtained the measure of angiogenesis through the number of microvessels in the richest microvessel density areas or “hotspots”. Moreover, the same authors showed that patients with a high microvessel count had a poor prognosis in relation to those with a low microvessel count [37]. Their findings revealed that the probability of metastasis increases when the number of microvessels does, which is in accordance with recent results in the literature [10].

Upon comparing IMD with p53 expression, we did not observe any statistical association; cases with p53(-) and p53 (+, ++, +++) expression, and cases with negative or low p53 staining (-, +) versus positive or high p53 staining (++, +++) were separated; we then compared their mean microvessel count, and no statistical correlation was observed under any circumstances. This result is in accordance with Giatromanolaki et al. [9], who showed no correlation between microvessel count and p53 expression in non-small-cell cancer, but this result is in disagreement with other lung cancer [7] and NPC reports [8]. Indeed, Gasparini et al., in SCC head and neck cancer, did show a statistical correlation between these two biological markers in relation to metastasis [8]. In our series 9 (21%) of 42 cases were SCC cases, and none had tumor spread. Moreover, angiogenesis is considered an early event in the development of an invasive tumor, in contrast to p53 mutations, considered a late event in head and neck cancer [8].

With respect to the clinicopathological variables (histological type, size, and stage of tumor, metastasis, sex and age), the only independent prognostic indicator in relation to survival in our study is histological type. Hence, SCC tumoral type predicted poor prognosis compared to UCNT; four of the nine (44%) SCC cases showed a high (++, +++) p53 staining. Further, four of the nine cases with high (++, +++) p53 staining were SCC cases. Thus, none of the 9 poor prognosis SCC cases proved metastasis-positive; these differences can help distinguish characteristics between SCC and UCNT tumoral type.

We also observed a trend between p53 expression and stage; all cases showing a high p53 (++, +++) staining were stage IV (advanced). This result is in accordance with previous studies [7, 9, 27, 31] showing a correlation between p53-positive expression and advanced tumor stage. On the other hand, none of the SCC cases was metastasis-positive. This result demonstrates that angiogenesis is not only regulated by p53, but that other angiogenesis factors are probably also implicated, such as the expression of vascular endothelial growth factor (VEGF) [9, 10, 36]. Moreover, mean tumor microvessel count in SCC cases is not higher than in UCNT cases.

Thus, SCC poor prognosis cannot be explained by microvessel count. In our report no statistical differences between clinicopathological variables and microvessel number were detected, which is in accordance with similar results in gastric cancer [27]. For this reason, angiogenesis can be taken as an independent prognostic factor apart from histological type, size and stage, as well as from metastasis, sex, and age of patients.

Alternatively, our multivariable study revealed that the most important prognostic indicator in relation to survival was tumor microvessel count, also in agreement with previous reports [7, 11, 27]. Consequently, angiogenesis is the major prognostic indicator that could be routinely incorporated in the prognosis of NPC patients.

In conclusion, the image analyzer is an effective and new tool with which to measure microvessels, thereby enabling us to establish a reliable prognosis. Indeed, automatic analysis eliminates the major problem in this kind of work, namely that of subjectivity. Controversial results in angiogenesis studies would disappear if morphometric studies were used routinely. Measuring angiogenesis may prove to be a further prognostic indicator that can be used in conjunction with other well-established factors, so as to achieve a more reliable prognostic approach in NPC patients.

References

1. Cox DR (1972) Regression models and life tables. *J R Stat Soc B* 34: 187–220
2. De Jong JS, Van Diest PJ, Baak JPA (1995) Heterogeneity and reproducibility of microvessel counts in breast cancer. *Lab Invest* 73: 922–926
3. Edström E, Cvetkovska E, Westin T, Young C (2001) Overexpression of p53-related proteins predicts rapid growth rate of head and neck cancer. *Laryngoscope* 111: 124–130
4. Folkman J (1990) What is the evidence that tumors are angiogenesis-dependent? *JNCI* 82: 4–6
5. Fontanini G, Bigini D, Vignati S, Basolo F, Mussi A, Lucchi M, Chiné S, Angeletti CA, Harris AL, Bevilacqua G (1995) Microvessel count predicts metastatic disease and survival in non-small cell cancer. *J Pathol* 177: 57–63
6. Fontanini G, Vignati S, Bigini D, Merlo GR, Ribecchini A, Angeletti CA, Basolo F, Pingitore R, Bevilacqua G (1994) Human non-small cell lung cancer: p53 protein accumulation is an early event and persists during metastatic progression. *J Pathol* 174: 23–31
7. Fontanini G, Vignati M, Lucchi M, Mussi A, Calcinai A, Boldrini L, Chiné S, Silvestri V, Angeletti CA, Basolo F, Bevilacqua G (1997) Neoangiogenesis and p53 protein in lung cancer: their prognostic roles and their relation with vascular endothelial growth factor (VEGF) expression. *Br J Cancer* 75 (9): 1295–1301
8. Gasparini G, Weidner N, Maluta S, Pozza F, Boracchi P, Mezzetti M, Testolin A, Bevilacqua G (1993) Intratumoral microvessel density and p53 protein: correlation with metastasis in head-and-neck squamous-cell carcinoma. *Int J Cancer* 55: 739–744

9. Giatromanolaki A, Koukourakis MI, Kakolyris S, Turley H, O'Byrne K, Scott PAE, Pezzella F, Georgoulas V, Harris AL, Gatter KC (1998) Vascular endothelial growth factor, wild-type p53, and angiogenesis in early operable non-small cell lung cancer. *Clin Cancer Res* 4: 3017–3024
10. Guang-Wu H, Sunagawa M, Jie-En L, Shimada S, Gang Z, Tokeshi Y, Kosugi T (2000) The relationship between microvessel density, the expression of vascular endothelial growth factor (VEGF), and the extension of nasopharyngeal carcinoma. *Laryngoscope* 110: 2066–2069.
11. Horak ER, Leek R, Klenk N, Lejeune S, Smith K, Stuart N, Greenall M, Stepniowska K, Harris AL (1992) Angiogenesis, assessed by platelet/endothelial cell adhesion molecule antibodies, as indicator of node metastases and survival in breast cancer. *Lancet* 340: 1120–1124
12. Hsu SM, Raine L, Fanger H (1981) A comparative study of the peroxidase-antiperoxidase method and an avidin-biotin complex method for studying polypeptide hormones with radioimmunoassay antibodies. *Am J Clin Pathol* 75: 734–738
13. Kaplan EL, Meier P (1958) Nonparametric estimation for incomplete observations. *J Am Stat Assoc* 53: 457–481
14. Kastan MB, Onyekwere O, Sidransky D, Vogelstein B, Craig W (1991) Participation of p53 protein in the cellular response to DNA damage. *Cancer Res* 51: 6304–6311
15. Kerbel R (2000) Tumor angiogenesis: past, present and the near future. *Carcinogenesis* 21(3): 505–515
16. Liebowitz D (1994) Nasopharyngeal carcinoma: the Epstein-Barr virus association. *Semin Oncol* 21: 376–381
17. Micheau C (1986) What's new in histological classification and recognition of nasopharyngeal carcinoma (NPC)? *Path Res Pract* 181: 249–253
18. Miller CW, Simon K, Aslo A, Kok K, Yokota J, Buys CHCM, Terada M, Koeffler HP (1992) p53 mutations in human lung tumors. *Cancer Res* 52: 1695–1698
19. Nicholls JM (1996) Nasopharyngeal carcinoma: classification and histologic appearances. *Adv Anat Pathol* 4: 71–84
20. Norrby K (1997) Angiogenesis: new aspects relating to its initiation and control. *APMIS* 105: 417–437
21. Ogawa Y, Chung Y-S, Nakata B, Takatsuka S, Maeda K, Sawada T, Kato Y, Yoshikawa K, Sakurai M, Sowa M (1995) Microvessel quantitation in invasive breast cancer by staining for factor VIII-related antigen. *Br J Cancer* 71: 1297–1301
22. Quian CN, Min HQ, Liang XM, Zheng SS, Lin HL (1997) Primary study of neovasculature correlating with metastatic nasopharyngeal carcinoma using computer image analysis. *J Cancer Res Clin Oncol* 123: 645–651
23. Rakozy C, Grignon DJ, Li Y, Gheiler E, Gururajanna B, Pontes JE, Sakr W, Wood Jr DP, Sarkar FH (1999) p53 gene alterations in prostate cancer after radiation failure and their association with clinical outcome: a molecular and immunohistochemical analysis. *Path Res Pract* 195: 129–135
24. Roychowdhury DF, Tseng Jr. A, Fu KK, Weinberg V, Weidner N (1996) New prognostic factors in nasopharyngeal carcinoma. Tumor angiogenesis and *C-erbB2* expression. *Cancer* 77: 1419–1426
25. Rubio L, Burgos JS, Morera C, Vera-Sempere FJ (2000) Morphometric study of tumor angiogenesis as a new prognostic factor in nasopharyngeal carcinoma patients. *Path Oncol Res* 6(3): 210–216
26. Santinelli A, Ranaldi R, Baccharini M, Mannello B, Bearzi I (1999) Ploidy, proliferative activity, p53 and bcl-2 expression in bronchopulmonary carcinoids: relationship with prognosis. *Path Res Pract* 195: 467–474
27. Sanz-Ortega J, Steinberg SM, Moro E, Saez M, Lopez JA, Sierra E, Sanz-Esponera J, Merino MJ (2000) Comparative study of tumor angiogenesis and immunohistochemistry for p53, c-ErbB2, c-myc and EGFr as prognostic factors in gastric cancer. *Histol Histopathol* 15: 455–462
28. Shanmugaratnam K, Sobin LH (1978) Histological typing of upper respiratory tract tumors. *International Histological Classification of Tumors. WHO, Geneva* 19: 20–32
29. Simpson JF, Ahn C, Battifora H, Esteban JM (1996) Endothelial area as a prognostic indicator for invasive breast carcinoma. *Cancer* 77: 2077–2085
30. Tanigawa N, Matsumura M, Amaya H, Kitaoka A, Shimomatsuya T, Lu C, Muraoka R, Tanaka T (1997) Tumor vascularity correlates with the prognosis of patients with esophageal squamous cell carcinoma. *Cancer* 79: 220–225
31. Tatemoto Y, Osaki T, Yoneda K, Yamamoto T, Ueta E, Kimura T (1998) Expression of p53 and p21 proteins in oral squamous cell carcinoma: correlation with lymph node metastasis and response to chemoradiotherapy. *Path Res Pract* 194: 821–830
32. Toi M, Kashitani J, Tominaga T (1993) Tumor angiogenesis is an independent prognostic indicator in primary breast carcinoma. *Int J Cancer* 55: 371–374
33. Tomisaki S, Ohno S, Ichiyoshi Y, Kuwano H, Maehara Y, Sugimachi K (1996) Microvessel quantification and its possible relation with liver metastasis in colorectal cancer. *Cancer* 77: 1722–1728
34. Vera-Sempere FJ, Burgos JS, Botella MS (1998) Comparative analysis of Epstein-Barr virus (EBV) detection by nested-PCR and non-isotopic *in situ* hybridization (NISH) in nasopharyngeal carcinoma. *Clin Chem Acta* 271: 119–132
35. Vera-Sempere FJ, Burgos JS, Botella MS, Córdoba J, Gobernado M (1996) Immunohistochemical expression of Epstein-Barr virus (EBV)-encoded latent membrane protein (LMP-1) in paraffin sections of EBV-associated nasopharyngeal carcinoma (NPC) in Spanish patients. *Oral Oncol Eur J Cancer* 32B: 163–166
36. Wakisaka N, Wen Q-H, Yoshizaki T, Nishimura T, Furukawa M, Kawahara E, Nakanishi I (1999) Association of vascular endothelial growth factor expression with angiogenesis and lymph node metastasis in nasopharyngeal carcinoma. *Laryngoscope* 109: 810–814
37. Weidner N, Folkman J, Pozza F, Bevilacqua P, Allred EN, Moore DH, Meli S, Gasparini G (1992) Tumor angiogenesis: a new significant and independent prognostic indicator in early-stage breast carcinoma. *JNCI* 84: 1875–1887
38. Weidner N, Semple JP, Welch WR, Folkman J (1991) Tumor angiogenesis and metastasis-correlation in invasive breast carcinoma. *N Engl J Med* 324: 1–8
39. Wood NB, Kotelnikov V, Caldarella DD, Hutchinson J, Panje WR, Hedge P, Leugans S, Lafollette S, Taylor SG, Preisler HD, Coon JS (1997) Mutation of p53 in squamous cell cancer of the head and neck: relationship to tumor cell proliferation. *Laryngoscope* 107: 827–833

Received: January 31, 2001

Accepted in revised version: December 21, 2001