

Journal section: Oral Medicine and Pathology
Publication Types: Research

doi:10.4317/jced.3.e297

Fibrous Dysplasia and Ossifying Fibroma - an advent in their diagnosis

Anubha Gulati ¹, Nirmala N. Rao ², Raghu A. Radhakrishnan ²

¹ MDS. Reader, Department of Oral Pathology, Dr. HSJ Institute of Dental Sciences and Hospital, PU, Chandigarh, India

² MDS. Professor, Department of Oral Pathology and Microbiology, Manipal College of Dental Sciences, Manipal, India.

Correspondence:

House No. 18, Sector 9A

Chandigarh-160009

India

Email: gulatianubha@gmail.com

Received: 07/02/2011

Accepted: 08/05/2011

Gulati A, Rao NN, Radhakrishnan RA. Fibrous Dysplasia and Ossifying Fibroma - an advent in their diagnosis. J Clin Exp Dent. 2011;3(4):e297-302.

<http://www.medicinaoral.com/odo/volumenes/v3i4/jcedv3i4p297.pdf>

Article Number: 50503	http://www.medicinaoral.com/odo/indice.htm
© Medicina Oral S. L. C.I.F. B 96689336 - eISSN: 1989-5488	
eMail: jced@jced.es	

Abstract

Objectives: Fibro-osseous lesions of the craniofacial complex comprise of a diverse, interesting and challenging group of conditions that pose difficulties in classification and treatment. The two most confused benign fibro-osseous lesions are fibrous dysplasia and ossifying fibroma. Sometimes, the classic clinical, radiologic or pathologic features of fibrous dysplasia or ossifying fibroma may not be evident, but overlapping features of both may be seen. The dilemma in diagnosis of these lesions rests in the bony trabeculae as well as in the fibrous stroma. Cases of fibrous dysplasia showing lamellated bony trabeculae and osteoblastic rimming have been reported which may confound diagnosis because of resemblance with ossifying fibroma. In the present study, an attempt has been made to demonstrate the fibrous element of these two lesions using histochemical stains.

Study design: The sections of fibrous dysplasia & ossifying fibroma were stained with Haematoxylin and Eosin, Trichrome stain and Peracetic acid-aldehyde fuschin-modified Halmi stain.

Result: The study revealed that the oxytalan fibers were more numerous in ossifying fibroma (seen with both Trichrome and modified Halmi stains).

Conclusion: Although the ultimate diagnosis of fibrous dysplasia and ossifying fibroma is arrived at by correlating clinical, radiographic and routine histopathologic examination, the differences in the configuration of the stroma using histochemical stains may help in the diagnosis of these two lesions.

Key Words: Fibro-osseous lesions, fibrous dysplasia, histochemical diagnosis, ossifying fibroma.

Introduction

Fibro-osseous lesions comprise of a diverse, interesting and challenging group of conditions that pose difficulties in classification and treatment (1, 2). Some benign fibro-osseous lesions of the craniofacial complex are unique to that location, whereas, others are encountered in bones from other regions (3, 4). All these lesions share common histologic features in that the bone is replaced by fibrous cellular tissue composed of collagen fibers and fibroblasts containing variable amounts of substance which may be bone or cementum-like in appearance (1, 5). Whereas, some of these lesions are diagnosable histologically, most require a combined assessment of clinical, microscopic and radiographic features (6).

The two most confused benign fibro-osseous lesions are fibrous dysplasia and ossifying fibroma. Sometimes, the classic clinical, radiologic or pathologic features of fibrous dysplasia or ossifying fibroma may not be evident, but overlapping features of both may be seen.

Fibrous dysplasia is first diagnosed in infancy and childhood (7), mainly in the first and second decades (8). It affects females predominantly and commonly affects the maxilla, presenting itself as a slow growing painless swelling which produces progressive destruction (9). The radiographic picture varies with the maturity of the lesion. Early lesions are largely radiolucent. Lesions showing uniform calcification may show the classic ground-glass appearance but mature lesions show discrete areas of radiopacity. In Haematoxylin and Eosin (H&E) sections, the metaplastic bone is in the form of irregular, feathery, Chinese letter pattern, woven trabeculae with expansile diffuse blending of the margins and occasional osteoblastic rimming (8). The delicate fibrous connective tissue stroma is arranged in a whorled pattern (1).

Ossifying fibroma which is commonly seen in the third and fourth decades (2,8,10,11) and affects females

predominantly (8) represents a neoplastic process that presents with expansion of the buccal and lingual cortices & in larger lesions may expand the inferior surface of the mandible (2,12,13). It is seen mainly in the premolar and molar regions of the mandible (2, 8-11) and follows a painless course (9). Radiographically, it appears initially as relatively well-demarcated radiolucency and later more radio-opaque and relatively less well localized (12). In H&E sections, the metaplastic bone is in the form of numerous small trabeculae of lamellar bone which sometimes join to form a large solid mass with a smooth periphery and an osteoblastic rimming. The fibrous stroma reveals haphazard orientation of collagen fibers (10).

Ossifying fibroma and fibrous dysplasia are the most common fibro-osseous lesions, which may be associated with significant cosmetic and functional disturbances. They show distinct patterns of disease progression (13) and as the treatment and prognosis differs for both (14-16), it is important to distinguish between the two (13). The dilemma in diagnosis of these two fibro-osseous lesions rests in the bony trabeculae as well as in the fibrous stroma. Harrison (5), Berger & Jaffe (7), Waldron (8), Harris et al (17) and Cooke (18) reported cases of fibrous dysplasia showing lamellated trabeculae and osteoblastic rimming. These may resemble those of ossifying fibroma and may pose a difficulty in diagnosis.

Objectives

The aim of this study is to differentiate the fibrous dysplasia and ossifying fibroma using histochemical stains.

Materials and Methods

Five cases each of fibrous dysplasia and ossifying fibroma were obtained from the archives of the Department of Oral Pathology and Microbiology. The clinical and radiographic findings of these ten cases are presented in

Case No.	Age	Gender	Site	Radiographic appearance	Clinical diagnosis
1	17	Female	Maxilla	Mixed lesion, predominantly radiolucent	Fibrous dysplasia
2	40	Male	Maxilla (Fig. 1)	Mixed lesion, predominantly radiopaque (Fig. 2)	Fibrous dysplasia
3	24	Female	Mandible	Radiolucent lesion	Fibrous dysplasia
4	35	Male	Maxilla (Fig. 3)	Mixed lesion, predominantly radiopaque (Fig. 4)	Fibrous dysplasia
5	27	Female	Maxilla	Mixed lesion, predominantly radiolucent	Fibrous dysplasia
6	40	Male	Mandible	Predominantly radiopaque	Ossifying fibroma
7	26	Female	Maxilla	Radiolucent lesion	Ossifying fibroma
8	40	Female	Mandible	Mixed lesion predominantly radiopaque (Fig. 5)	Ossifying fibroma
9	35	Male	Maxilla	Mixed lesion	Ossifying fibroma
10	24	Female	Mandible	Mixed lesion, predominantly radiolucent	Ossifying fibroma

Table 1. Clinicoradiographic presentation

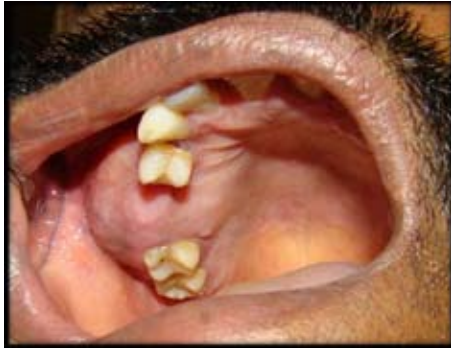

Fig. 1. Clinical photograph of Case 2 – smooth expansile mass seen on right side of the maxilla measuring 3cm X 4cm extending from distal of first premolar to mesial of third molar

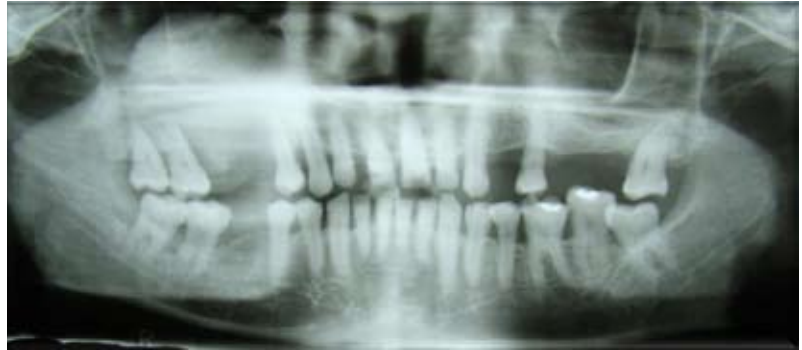


Fig. 2. Panoramic view of Case 2 – well-defined dome-shaped, homogenous radiopacity seen in the right maxillary posterior region. Floor of the maxillary sinus on this side is not evident.

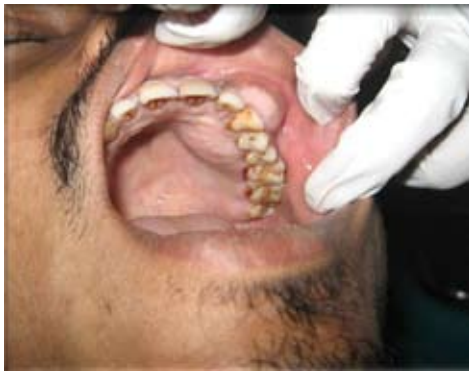

Fig. 3. Clinical photograph of Case 4 – swelling seen on the left side of the maxilla extending from canine to second premolar causing expansion of the buccal and lingual cortical plates.

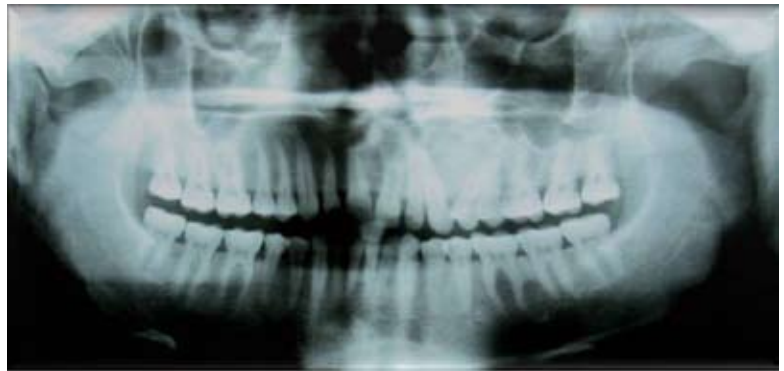

Fig. 4. Panoramic view of Case 4 – diffuse mixed lesion which is predominantly radiopaque causing divergence of the roots of left maxillary canine and left maxillary first premolar.

Table 1. The sections were stained with Haematoxylin and Eosin, Trichrome stain and Peracetic acid-aldehyde fuschin-modified Halmi stain.

Results

Trichrome stain – Collagen appeared bluish green; bone appears greenish red in fibrous dysplasia (Fig. 6) and red in ossifying fibroma (Fig. 7) while oxytalan fibers appear reddish brown.

Peracetic acid-aldehyde fuschin-modified Halmi stain – collagen appears green; bone appears green in fibrous dysplasia (Fig. 8) and purple in ossifying fibroma (Fig. 9) while oxytalan fibers appear purple.

On comparing the two lesions, it was found that the oxytalan fibers were more numerous in ossifying fibroma (seen with both Trichrome and modified Halmi stains).

Discussion

Fibro-osseous lesions usually present a diagnostic dilemma for the clinicians as well as the pathologists. A variety of investigations have been made in an effort to clarify the problem.

Fibrous dysplasia is a genetic non-inherited condition caused by missense mutation in the gene *GNAS1* on chromosome 20, that encodes the alpha subunit of the

stimulatory G protein-coupled receptor, *Gsa*. Fibrous dysplastic lesions have characteristic changes in bone matrix organization, in expression of certain non-collagenous proteins of the extracellular matrix, and in mineralization; and the mutated cells within the lesion are morphologically altered (19, 20). Critical to the diagnosis is the fact that fibrous dysplasia fails to manifest any discrete margins; rather the lesional bone subtly blends into the surrounding normal appearing bone (3, 6, 11). Ultrastructural and biochemical studies have suggested that the fibroblastic component of fibrous dysplasia is related to the osteogenic lineage (21, 22). However, the precise molecular biologic evidence for this has not yet been presented (13).

Ossifying Fibroma is a relatively slow-growing lesion in which the overlying cortical bone and mucosa remain intact and thus the tumour may be present for a number of years before a diagnosis is made. No histopathologic features are available to determine the potential aggressivity of the lesion or its tendency to recur (23). Very few molecular studies have been reported for the ossifying fibroma group of lesions. There have been reports that identify mutations in *HRPT2*, a gene that encodes parafibromin protein (6).

Until 1948 it was believed that fibrous dysplasia and

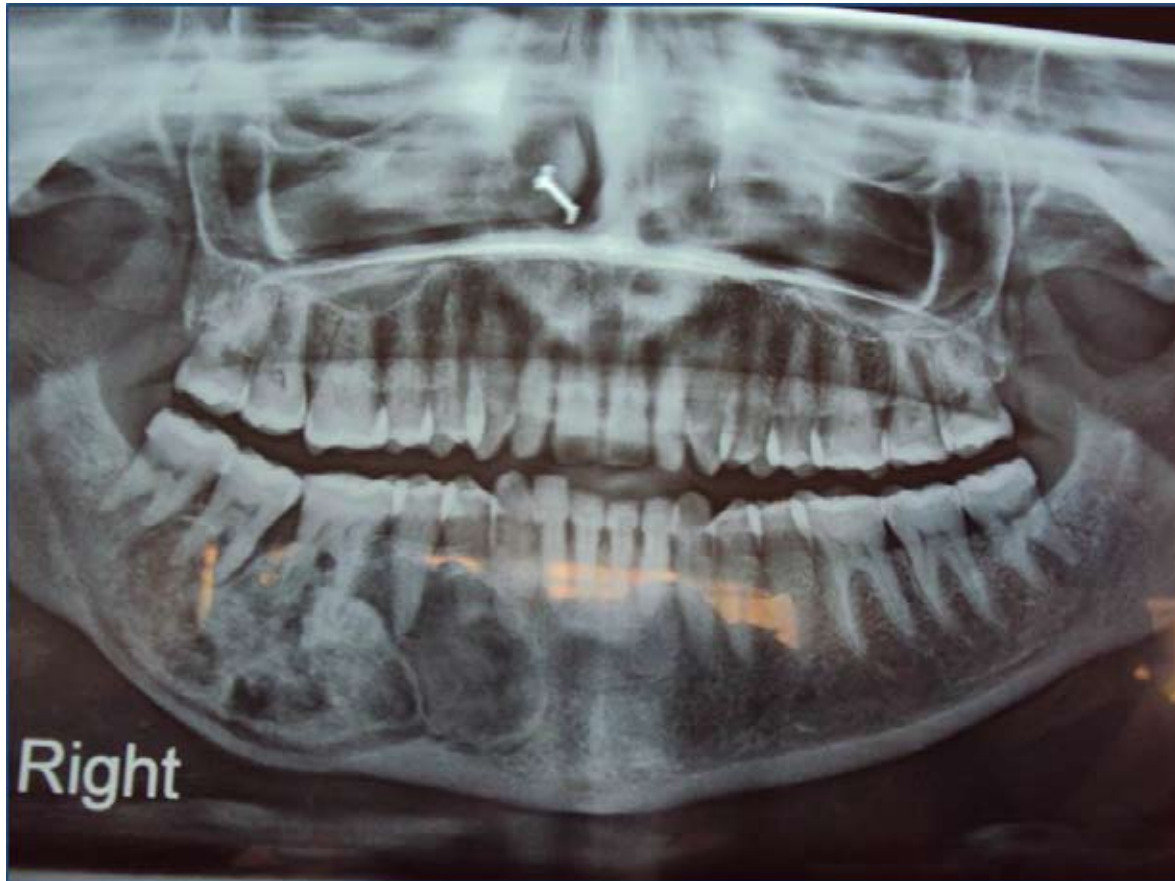

Fig. 5. Panoramic view of Case 8 – well-defined mixed lesion with predominant radioopaque areas extending from right mandibular canine to mesial of right mandibular third molar.

ossifying fibroma were either the same entity or variants of the same lesion (24). Studies by Toyosawa et al demonstrated that immunohistochemical analysis of osteocalcin and PCR analysis of GNAS mutations are useful methods in differentiating between the two, and furthermore suggest that they are probably distinct disease entities (13).

It is generally assumed that in the jaws certain fibro-osseous “tumours” and “dysplasia” may arise from either the periodontal membrane or the endosteum because all of these contain fibrous tissue capable of proliferation (25). The fibrous connective tissue of the periodontal membrane is composed chiefly of collagen fibers, oxytalan fibers, mucopolysaccharides and cells which have the capacity of synthesising bone, cementum and fibrous tissue. Under pathologic conditions, such blastic cells are capable of producing tumours composed of cementum, lamellar bone and fibrous tissue (9, 10, 26).

Lille and Fulmer (1958) reported a previously undescribed connective tissue fibre in the periodontal membrane and gingiva and named it oxytalan fibre. It is derived from a Greek word meaning “acid enduring” or “acid resisting” as these fibers are resistant to acid hydrolysis. These fibers were disclosed accidentally after sections

of human periodontal membrane were stained with aldehyde fuchsin following peracetic acid oxidation (27, 28).

Oxytalan fibers have been reported in various pathologic conditions such as fibrous dysplasia, ossifying fibroma (25) and rarely in dental granulomas, radicular cysts (29) and ameloblastomas (30). Few workers have analysed cases of fibro-osseous lesions and found that oxytalan fibers were present in most of these lesions regardless of their origin, along with mature collagen fibers. They observed more oxytalan fibers in ossifying fibroma than in fibrous dysplasia. Studies by Hamner, Scofield and Cornyn on fibro-osseous lesions showed greater amount of oxytalan fibers in the lesions of periodontal membrane origin compared to fibers seen in fibro-osseous lesions of endosteal origin (25).

In the present study, the basic hard tissue configuration is that of woven bony trabeculae, lamellated bony trabeculae or anastomosing curvilinear trabeculae, while the connective tissue stroma varies from delicate fibrillar to myxomatous areas. With the use of peracetic acid-aldehyde fuchsin and trichrome staining, the results of the present study support the views of Hamner and Fullmer with the presence of greater amounts of oxytalan fibers

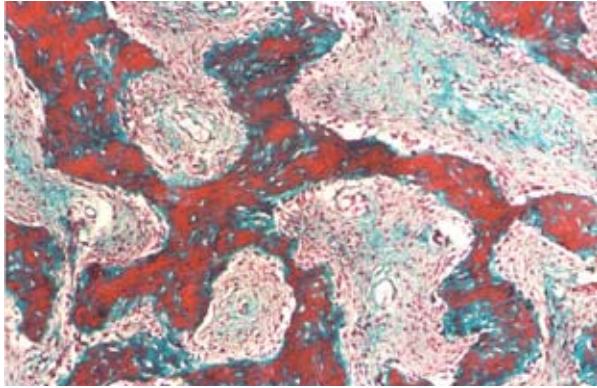


Fig. 6. Fibrous dysplasia – collagen appears bluish-green, bone appears greenish-red and oxytalan fibers appear reddish-brown (Trichrome stain, x10).

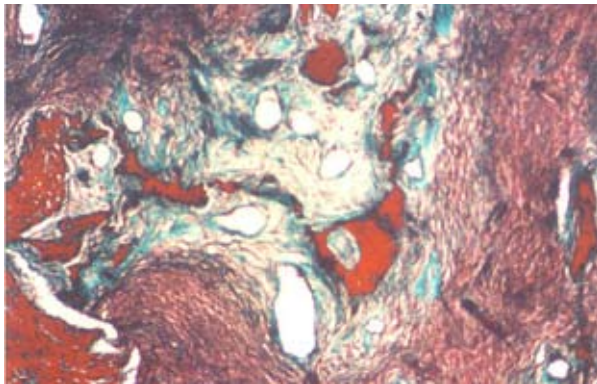


Fig. 7. Ossifying fibroma – collagen appears bluish green, bone appears red and oxytalan fibers appear reddish-brown (Trichrome stain, x10).

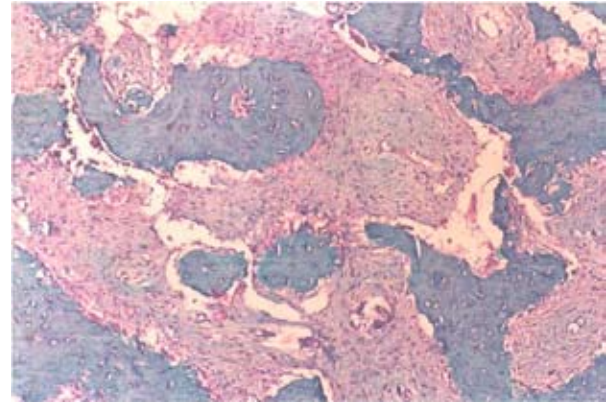


Fig. 8. Fibrous dysplasia – collagen appears green, bone appears green and oxytalan fibers appear purple (modified Halmi stain, x10).

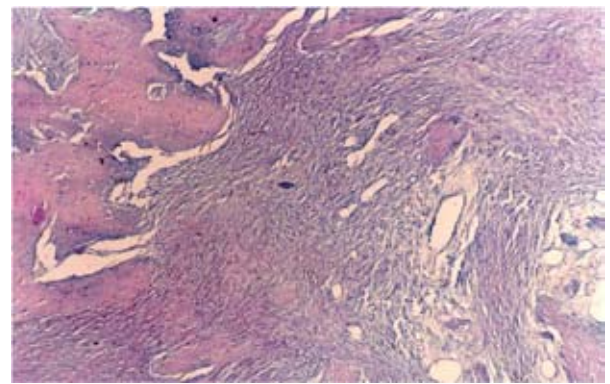


Fig. 9. Ossifying fibroma – collagen appears green, bone appears purple and oxytalan fibers appear purple (modified Halmi stain, x10).

in ossifying fibroma than fibrous dysplasia. Probably, the demonstration of the fibrous elements in both the disease entities by histochemical methods may be an additional aid to the pathologists in solving the thorny problem of diagnosis of these two fibro-osseous lesions, provided, the bony configuration in both is that of lamellated bone which may have led to an erroneous diagnosis of ossifying fibroma. This may also give a conclusive evidence of their origin.

Thus to conclude, though the ultimate diagnosis of fibrous dysplasia and ossifying fibroma depends on the correlation of clinical, radiographic and routine histopathologic examination, the differential stromal configuration observed with histochemical stains may serve as a marker in the diagnosis of fibrous dysplasia and ossifying fibroma in the absence of molecular evaluation, as well as an insight into their origin.

Acknowledgement

The authors would like to thank Dr. Renu Yadav for her review of the manuscript and Mr Shreepati, histopathology technician for his technical assistance.

References

1. Waldron CA. Fibro-osseous Lesions of the Jaws. J Oral Maxillofac Surg. 1985; 43: 249-262.
2. Pecaro BC. Fibro-osseous Lesions of the Head and Neck. Otolaryngol Clin N Am 1986; 19(3): 489-496.
3. Eversole LR, Sabes WR, Rovin S. Fibrous dysplasia: A nosologic problem in the diagnosis of fibro-osseous lesions of the jaws. J Oral Pathol 1972; 1: 189-220.
4. Slootweg PJ. Maxillofacial fibro-osseous lesions: classification and differential diagnosis. Semin Diagn Pathol. 1996; 13: 104-112.
5. Harrison DFN. Osseous and fibro-osseous conditions affecting the craniofacial bones. Ann Otol Rhinol Laryngol 1984; 93: 199-203.
6. Eversole R, Su L, ElMofty S. Benign Fibro-Osseous Lesions of the Craniofacial Complex A Review. Head Neck Pathol 2008; 2(3): 177-202.
7. Berger A, Jaffe HL. Fibrous (fibro-osseous) dysplasia of jaw bones. J Oral Surg 1953; 11(1): 3-17.
8. Waldron CA. Fibro-osseous Lesions of the Jaws. J Oral Maxillofac Surg 1993; 51: 828-835.
9. Langdon JD, Rapidis AD, Patel MF. Ossifying fibroma – one disease or six? An analysis of 39 fibro-osseous lesions of the jaws. B J Oral Surg 1976; 14: 1-11.
10. Hamner JE, Scofield HH, Cornyn J. Benign fibro-osseous jaw lesions of the periodontal membrane origin. An analysis of 249 cases. Cancer 1968; 22: 861-878.
11. Waldron CA, Giansanti JS. Benign fibro-osseous lesions of the jaws: a clinical-radiologic-histologic review of 65 cases. II. Benign fibro-osseous lesions of periodontal ligament origin. Oral Surg Oral Med Oral Pathol 1973; 35: 340-350.
12. Yih W-Y, Pederson GT, Bartley MH. Multiple familial ossifying fibromas: Relationship to other osseous lesions of the jaws. Oral Surg Oral Med Oral Pathol 1989; 68: 754-758.
13. Toyosawa S, Yuki M, Kishino M, Ogawa Y, Ueda T, Murakami S et al. Ossifying fibroma vs fibrous dysplasia of the jaw: molecular and

- immunological characterization. *Mod Pathol* 2007; 20: 389-396.
14. Su L, Weather DR, Waldron CA. Distinguishing features of focal cemento-osseous dysplasias and cemento-ossifying fibromas: I. A pathologic spectrum of 316 cases. *Oral Surg Oral Med Oral Pathol Oral Radiol Endod* 1997; 84: 301-309.
 15. Su L, Weather DR, Waldron CA. Distinguishing features of focal cemento-osseous dysplasia and cemento-ossifying fibromas: II. A Clinical and radiologic spectrum of 316 cases. *Oral Surg Oral Med Oral Pathol Oral Radiol Endod* 1997; 84: 540-549.
 16. Regezi JA. Odontogenic Cysts, Odontogenic Tumors, Fibroosseous, and Giant Cell Lesions of the Jaws. *Mod Pathol* 2002; 15(3): 331-341.
 17. Harris WH, Dudley HR, Barry RJ. The natural history of fibrous dysplasia. *J Bone & Joint Surg* 1962; 44A: 207-233.
 18. Cooke BED. Benign fibro-osseous enlargements of the jaws. Part I. *Br Dent J* 1957a; 102: 1-14.
 19. Feller L, Wood NH, Khammissa RAG, Lemmer J, Raubenheimer EJ. The nature of fibrous dysplasia. *Head & Neck Medicine* 2009; 5: 22.
 20. Corsi A, Collins MT, Riminucci M, Howell PGT, Boyde A, Robey PG et al. Osteomalacic and hyperthyroid changes in fibrous dysplasia of bone: Core biopsy studies and clinical correlations. *J Bone Miner Res* 2003; 18: 1235-1246.
 21. Greco MA, Steiner GC. Ultrastructure of fibrous dysplasia of bone: a study of its fibrous, osseous and cartilaginous components. *Ultrastruct Pathol* 1986; 10: 55-66.
 22. Riminucci M, Fisher LW, Shenker A, Spiegel AM, Bianco P, Gehron Robey P. Fibrous dysplasia of the bone in the McCune-Albright syndrome: abnormalities in bone formation. *Am J Pathol* 1997; 151: 1587-1600.
 23. Eversole LR, Leider AS, Nelson K. Ossifying fibroma: A clinicopathologic study of sixty-four cases. *Oral Surg Oral Med Oral Pathol* 1985; 60: 505-511.
 24. Commins DJ, Tolley NS, Milford CA. Fibrous dysplasia and ossifying fibroma of the paranasal sinuses. *J Laryngol Otol* 1998; 112: 964-968.
 25. Hamner JE, Fullmer HM, Bethesda. Oxytalan Fibers in Benign Fibro-osseous Jaw Lesions. *Arch Path* 1966; 82: 35-39.
 26. Pérez-García S, Berini-Aytés L, Gay-Escoda C. Ossifying fibroma of the upper jaw: Report of a case and review of the literature. *Med Oral* 2004; 9: 333-339.
 27. Sheetz JH, Fullmer HM, Narkates AJ. Oxytalan fibers: Identification of the same fibre by light and electron microscopy. *J Oral Path* 1973; 2: 254-263.
 28. Fullmer HM, Sheetz JH, Narkates AJ. Oxytalan connective tissue fibers: A review. *J Oral Path* 1974; 3: 291-316.
 29. Fullmer HM. Observations on the Development of Oxytalan Fibers in Dental Granulomas and Radicular Cysts. *Arch Path* 1960; 70: 59-67.
 30. Fisher AK, Fullmer HM. Oxytalan Fibers in Ameloblastomas. *Oral Surg* 1962; 15:246-248.