

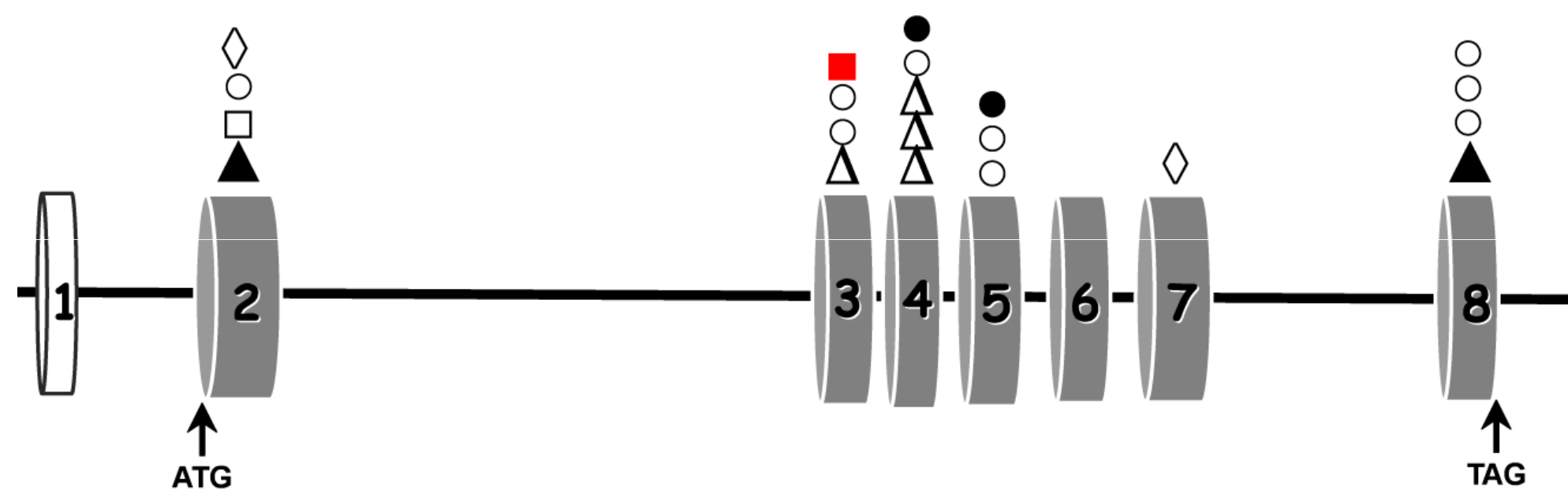
# MPV17: FATAL HEPATOCEREBRAL PRESENTATION

Célia Nogueira<sup>1</sup>, Carolina Souza<sup>2</sup>, Antonette Husny<sup>2</sup>, Terry Derks<sup>3</sup>, Filippo M. Santorelli<sup>4</sup>, Laura Vilarinho<sup>1</sup>

<sup>1</sup>Genetics Department, National Institute of Health, INSA, Porto, Portugal; <sup>2</sup>Medical Genetic Service, Hospital de Clinicas de Porto Alegre, Brazil; <sup>3</sup>Metabolic Diseases Department, Beatrix Children's Hospital, University of Groningen, The Netherlands; <sup>4</sup>Molecular Medicine & Neurogenetics, IRCCS Stella Maris, Pisa, Italy

## Introduction

The hepatocerebral forms of mtDNA depletion syndromes typically manifest soon after birth and cause premature death in childhood [1]. Presentation is usually with early liver failure, followed by development delay and muscle weakness during the first year of life, as well as lactic acidosis and hypoglycemia [2]. These conditions are associated with mutations in at least six genes [3] though further heterogeneity is expected. An ample array of *MPV17* mutations (Figure 1) has been described in about 30 patients from different ethnicities.



**Figure 1** - Described mutations in the *MPV17* gene. ○ Missense mutation; ● Nonsense mutation; △ Small deletion; ▲ Gross deletion; ◇ Small insertion; □ Splicing mutation; ■ c.186+2T>C.

## Patients

We describe a Brazilian infant, the second child of apparently unrelated healthy parents, who presented neonatal hypoglycemia, digestive bleeding and sepsis in the first week of life. Laboratory tests also showed elevated levels of total and free serum bilirubin and transaminases. Amino acids were normal whereas organic acids revealed the presence of lactic acid (3X normal values) and Krebs cycle intermediates at age 2 months. Shortly after the patient manifested failure to thrive, severe hypotonia, nystagmus, poor echoarchitecture at liver ultrasound, and cirrhotic ascites. He died at 5-months-old with hepatic insufficiency associated with bleeding and multiple organ failure.

## Results

The patient presented severe mtDNA depletion (residual mtDNA levels were 2% in liver and 23% in muscle) and molecular studies detected a homozygous mutation c.186+2T>C in *MPV17*, a variant already reported in a heterozygous state with poor prognosis in a singleton [4]. This mutation is located at the invariant splice donor site and is predicted to abolish the splicing donor site of exon 3 (<http://www.cbs.dtu.dk/services/NetGene2> and <http://www.fruitfly.org>). The c.186+2T>C was also detected in the proband's elder sister who had presented at birth with neonatal hypoglycemia, failure to thrive and hepatic insufficiency, later developed seizures and hypotonia, and died at 10 months. The mutation was heterozygous in the parents who were from nearby villages in south Brazil.

## Discussion/Conclusion

To date a total of 32 patients have been reported with *MPV17* mutations. Our study expands the ethnic background of *MPV17*-mutated patients and will be important for an accurate genetic counseling and a prenatal diagnosis to the affected family. MtDNA depletion should be looked for in neonates with progressive cholestasis and neurological deterioration.

## References

- [1] A. Suomalainen, P. Isohanni, Mitochondrial DNA depletion syndromes - many genes, common mechanisms, *Neuromuscul Disord* 20 (2010) 429-437.
- [2] A.W. El-Hattab, F. Scaglia, W.J. Craigen, and L.C. Wong, *MPV17-Related Hepatocerebral Mitochondrial DNA Depletion Syndrome*, In: Pagon RA, Bird TD, Dolan CR, Stephens K, Adam MP (Eds.), *GeneReviews™*, Seattle (2012).
- [3] A. Rötig, J. Poulton, Genetic causes of mitochondrial DNA depletion in humans, *Biochim. Biophys. Acta* 1792 (2009) 1103-1108.
- [4] A.W. El-Hattab, F.Y. Li, E. Schmitt, S. Zhang, W.J. Craigen, L.C. Wong, *MPV17-associated hepatocerebral mitochondrial DNA depletion syndrome: New patients and novel mutations*, *Mol. Genet. Metab.* 99 (2010) 300-308.