



Imported African histoplasmosis by *Histoplasma capsulatum* var. *duboisii* in an HIV-2 infected patient

C. Toscano¹, J. Batista¹, R. Carvalho², C.E.Espírito-Santo², R. Marcos³, R. Sabino⁴, C. Veríssimo⁴, I. Viana³, T. Marques¹

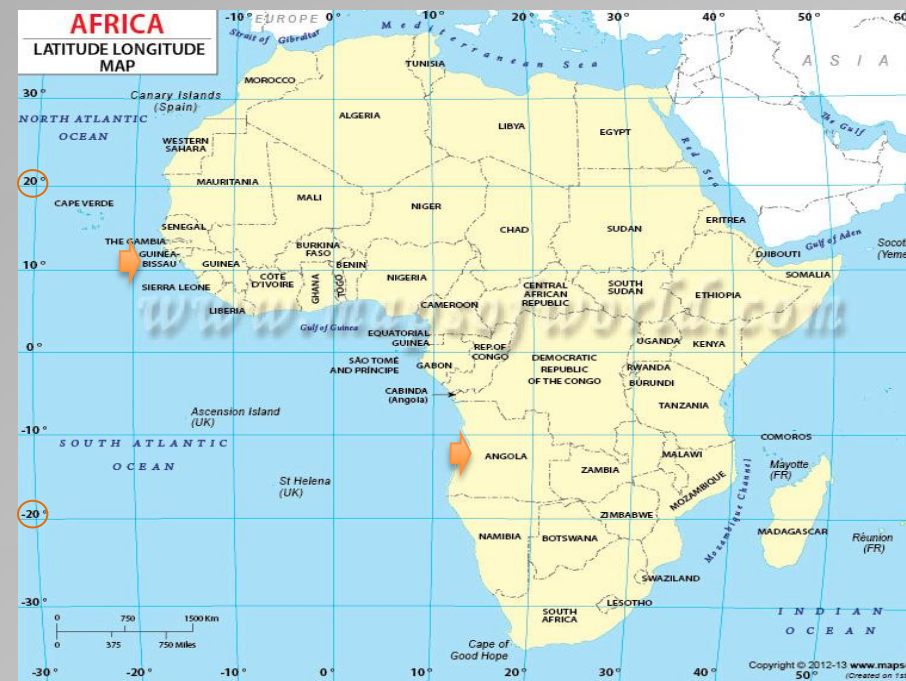¹Laboratório de Microbiologia Clínica e Biologia Molecular, Hospital Egas Moniz/CHLO; Lisboa, Portugal

²Serviço de Doenças Infecciosas e Medicina Tropical, Hospital Egas Moniz/CHLO; Lisboa, Portugal

³Serviço de Dermatologia, Hospital Egas Moniz/CHLO; Lisboa, Portugal

⁴Laboratório de Micologia, Instituto Nacional de Saúde Dr. Ricardo Jorge; Lisboa, Portugal

Objectives



African histoplasmosis caused by the fungus *Histoplasma capsulatum* var. *duboisii* is a rare endemic mycosis occurring in western and central regions of sub-Saharan Africa. For unknown reasons, although HIV infection and *H. capsulatum* var. *duboisii* coexist in Africa, this coinfection remains rare. In Europe, diagnosed cases of African histoplasmosis are all imported.

We describe a case of African histoplasmosis on a Portuguese war veteran co-infected with HIV-2 who fought in Guiné-Bissau in 1963-65 and Angola 1972.

Methods

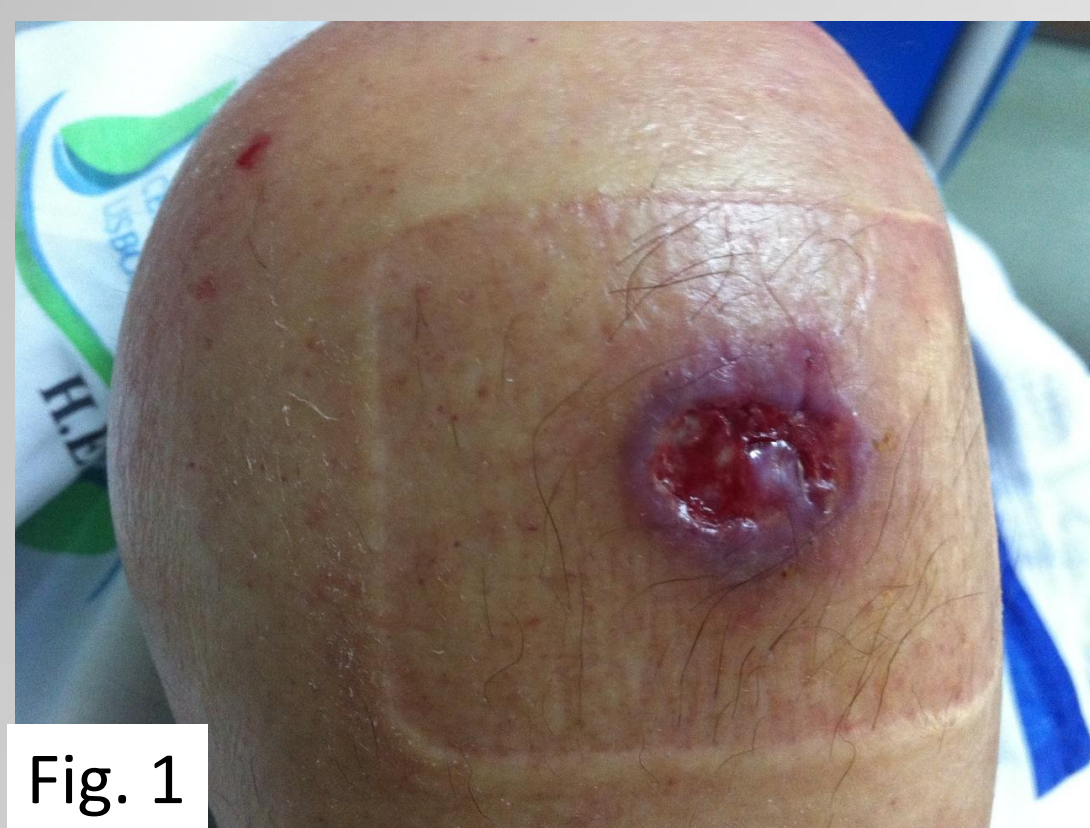

Fig. 1

We report a case of a 76-year-old man, diagnosed with HIV-2 infection in the previous year (under combined antiretroviral therapy) presenting an ulcerated skin lesion on the right thigh, just above the knee (Fig. 1) that proved to be caused by *Histoplasma capsulatum* var. *duboisii*.

He was diagnosed pulmonary tuberculosis the year before and was finishing one year treatment. The solitary skin lesion begun as a small non-pruriginous eritematous papule, evolving in 6 months to a painless 3-4cm ulcer with raised borders surrounded by a hyperpigmented halo. There were no adenopathies or bone lesions. Respiratory samples and blood cultures were systematically negative for *Histoplasma capsulatum*.

He was initially treated with IV liposomal Amphotericin-B (4mg/Kg/d) for one month, followed by oral Itraconazol (400mg/d) with a favourable clinical outcome (complete resolution of skin lesion by day 20 of Itraconazol treatment).

Results

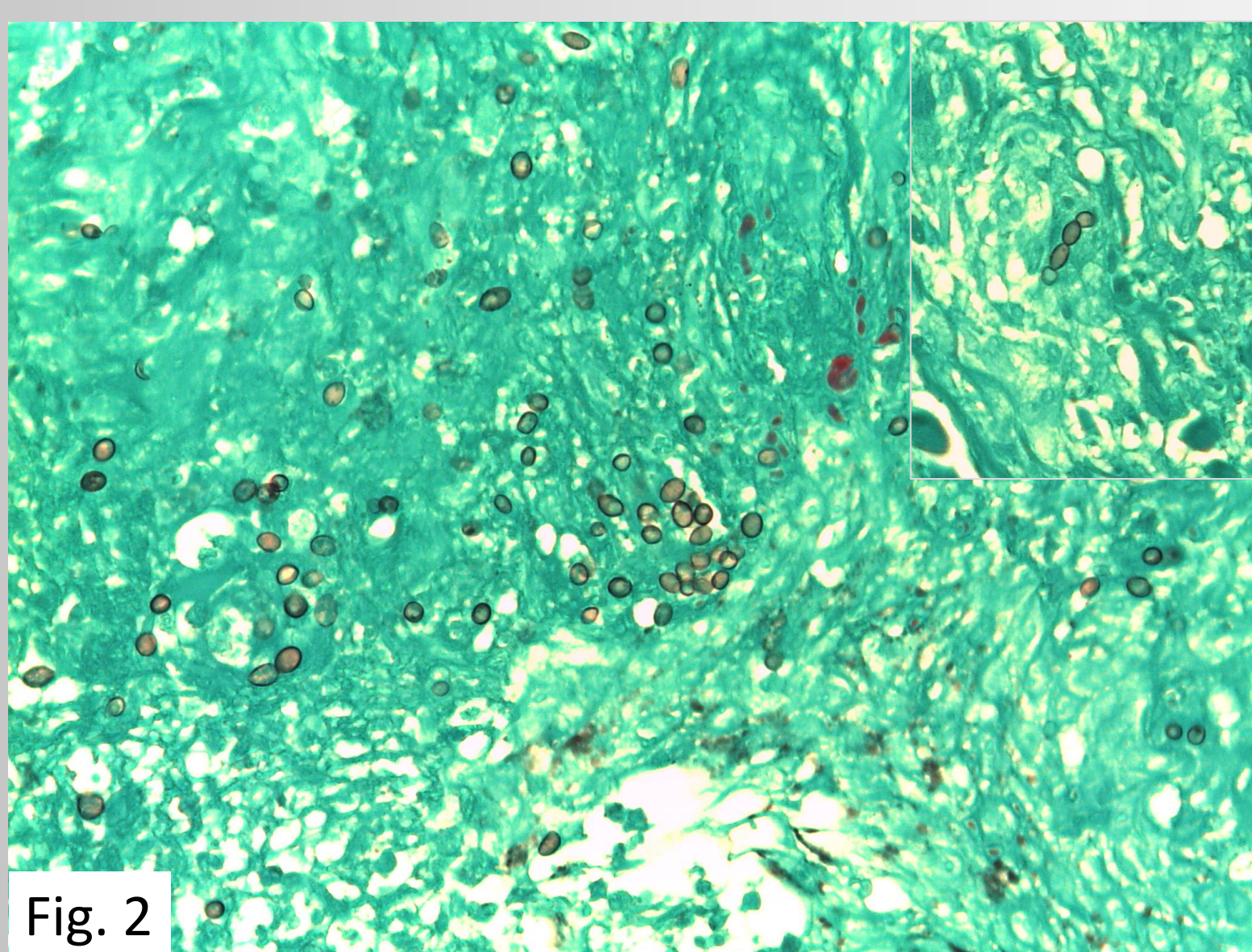


Fig. 2

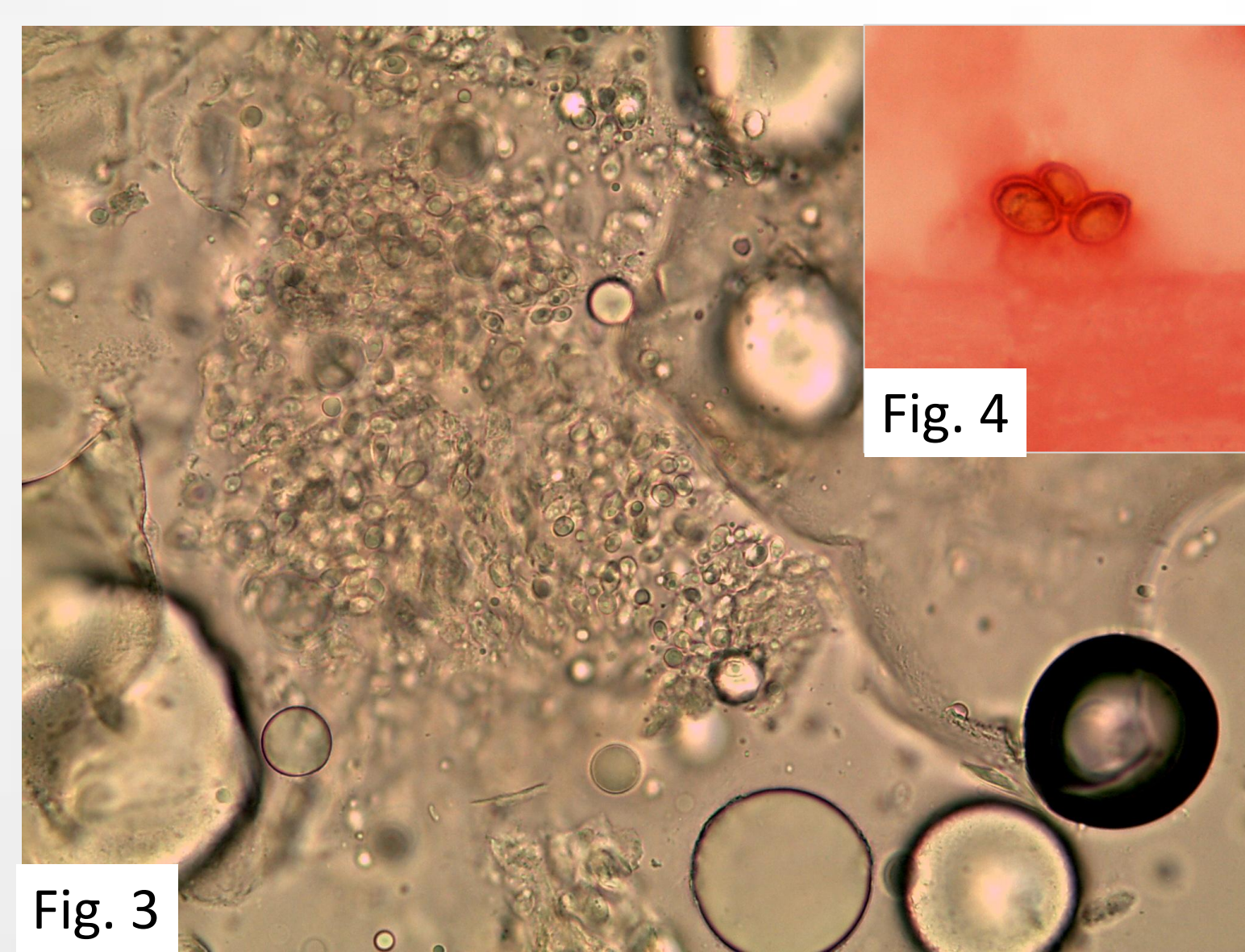


Fig. 3

Fig. 4




Fig. 5

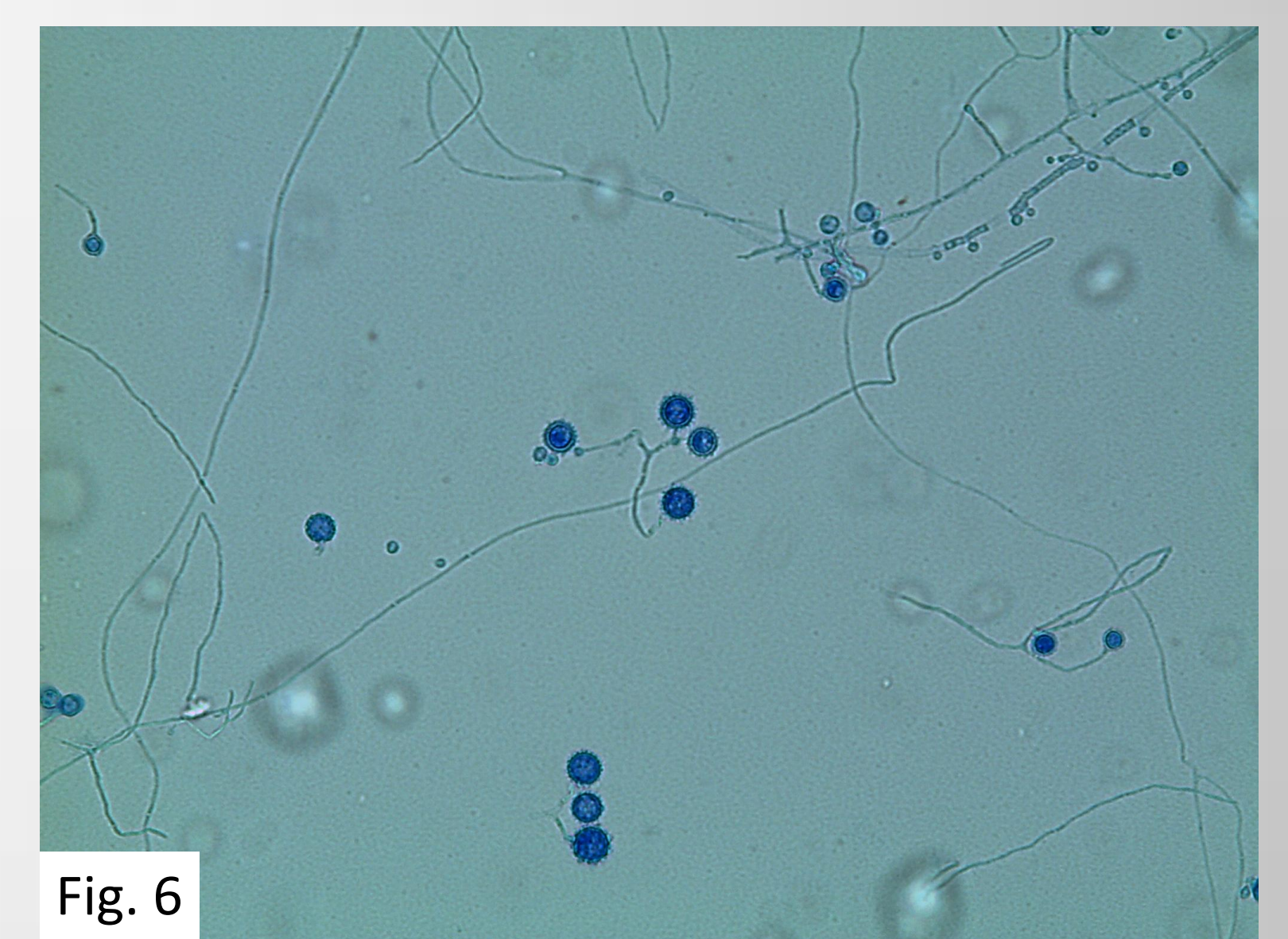


Fig. 6

Histopathology of skin biopsy revealed a superficial ulceration with underlying granulomatous infiltrate with many giant cells, where numerous round mononucleated yeasts measuring 7-8µm, sometimes in chains, were evident and highlighted in Grocott stain (Fig. 2, 40x objective).

Skin biopsy was observed on a wet mount with KOH and revealed numerous round yeasts (Fig. 3, 40x objective) that were also seen on Gram stain (Fig. 4: 100x objective).

Culture of skin biopsy on two Sabouraud dextrose agar (with and without cicloheximide) showed growth of a filamentous fungus compatible with *Histoplasma capsulatum* (Fig. 5, Sabouraud dextrose culture medium), with large thick-walled spherical macroconidia with finger-like projections (tuberculate conidia) arising from short conidiophores, and small oval microconidia arising on short stalks from undifferentiated hyphae (Fig. 6, Lactofenol blue, 40x objective). Reversion to the yeast phase has not been succeeded yet.

Identification was further confirmed by sequencing of genomic DNA fragments using the universal fungal primers ITS1 and ITS4. The sequences obtained were compared with sequences deposited in the GenBank and the result was: *Histoplasma capsulatum* var. *duboisii* (99% homology). The obtained consensus sequence was deposited in GenBank with the accession number KF228448.

Conclusion

With banalization of business or leisure trips, endemic mycosis are becoming frequently diagnosed in countries outside their natural geographic endemic areas and only a high index of suspicion makes the diagnosis possible. Apart from trips, nowadays in Portugal 4% of the resident population is immigrant, mostly from Brasil (25.5%) but also from Angola and Guiné-Bissau (9.2%), being the former an endemic country of American histoplasmosis and the later of both American and African histoplasmosis.

We consider histoplasmosis a probable underdiagnosed disease that should be suspected mainly in immunodeficient HIV positive individuals with a past history of travel or residence in an endemic area.

References:

- Chandenier J., 1995. *Histoplasma capsulatum* var. *duboisii*: liens avec le Sida à propos de cas congolais récents. *Cahiers d'études et de recherches francophones / Santé*, 5(4), pp.227-234. Available at: http://www.jle.com/fr/revues/sante_pub/san/e-docs/00/04/1E/D4/article.phtml.
- Gugnani, H.C. & Muotoe-Okafor, F., 1997. African histoplasmosis: a review. *Revista Iberoamericana de micología*, 14(4), pp.155-9. Available at: <http://www.ncbi.nlm.nih.gov/pubmed/15538817>.
- Loulergue, P. et al., 2007. Literature Review and Case Histories of Histoplasma Infections in HIV-infected Patients. *Emerging Infectious Diseases*, 13(11).
- Manfredi, R. et al., 1994. Histoplasmosis capsulati and duboisii in Europe: the impact of the HIV pandemic, travel and immigration. *European journal of epidemiology*, 10(6), pp.675-81. Available at: <http://www.ncbi.nlm.nih.gov/pubmed/7672046>.
- Minta, D.K. et al., 2005. Histoplasmosis africaine à *Histoplasma capsulatum* var. *duboisii*. À propos d'un cas au Mali. *Journal de Médecine*, 15, pp.195-199.
- Mounguengui, D. et al., 2012. Histoplasmosis: première observation au Gabon. *Médecine et Santé Tropicales*, 22, pp.82-83.
- Panackal, A. et al., 2002. Fungal infections among returning travelers. *Clinical infectious diseases*: an official publication of the Infectious Diseases Society of America, 35(9), pp.1088-95. Available at: <http://www.ncbi.nlm.nih.gov/pubmed/12384843>.
- Wheat, L.J. et al., 2007. Clinical practice guidelines for the management of patients with histoplasmosis: 2007 update by the Infectious Diseases Society of America. *Clinical infectious diseases*: an official publication of the Infectious Diseases Society of America, 45(7), pp.807-25. Available at: <http://www.ncbi.nlm.nih.gov/pubmed/17806045>.