

2014

Treatment of pagetoid reticulosis with intensity modulated radiation therapy

Charles Mount

Washington University School of Medicine in St. Louis

Daniel Ferraro

Washington University School of Medicine in St. Louis

Alejandro Gru

Washington University School of Medicine in St. Louis

Matthew Bradbury

Washington University School of Medicine in St. Louis

Lynn Cornelius

Washington University School of Medicine in St. Louis

See next page for additional authors

Follow this and additional works at: http://digitalcommons.wustl.edu/open_access_pubs

Recommended Citation

Mount, Charles; Ferraro, Daniel; Gru, Alejandro; Bradbury, Matthew; Cornelius, Lynn; and Gay, Hiram, "Treatment of pagetoid reticulosis with intensity modulated radiation therapy." *Dermatology Online Journal*.20,10. . (2014).
http://digitalcommons.wustl.edu/open_access_pubs/5149

Authors

Charles Mount, Daniel Ferraro, Alejandro Gru, Matthew Bradbury, Lynn Cornelius, and Hiram Gay



Peer Reviewed

Title:

Treatment of pagetoid reticulosis with intensity modulated radiation therapy

Journal Issue:

[Dermatology Online Journal, 20\(10\)](#)

Author:

[Mount, Charles](#), Washington University in St. Louis
[Ferraro, Daniel](#), Washington University in St. Louis
[Gru, Alejandro](#), Washington University in St. Louis; The Ohio State University
[Bradbury, Matthew](#), Washington University in St. Louis
[Cornelius, Lynn](#), Washington University in St. Louis
[Gay, Hiram](#), Washington University in St. Louis

Publication Date:

2014

Permalink:

<http://escholarship.org/uc/item/67d7n40j>

Local Identifier:

doj_24251

Abstract:

Pagetoid reticulosis, also known as Woringer-Kolopp disease, is a rare variant of cutaneous T-cell lymphoma usually presenting as an isolated patch or plaque on the extremities. Immunohistochemical staining of T-cell markers can be variable, but as the name implies the epidermotropic lymphocytes consistently display a “pagetoid” appearance. The following case demonstrates clearance of this condition with intensity modulated radiation therapy, whereas most cases are managed with electron beam therapy if radiation therapy is implemented.

Copyright Information:



Copyright 2014 by the article author(s). This work is made available under the terms of the Creative Commons Attribution-NonCommercial-NoDerivs4.0 license, <http://creativecommons.org/licenses/by-nc-nd/4.0/>



Case Presentation

Treatment of pagetoid reticulosis with intensity modulated radiation therapy

Charles Mount MD¹, Daniel Ferraro MD PhD², Alejandro Gru MD^{1,3}, C. Matthew Bradbury MD PhD², Lynn Cornelius MD¹, Hiram Gay MD²

Dermatology Online Journal 20 (10): 4

¹Washington University in St Louis, Division of Dermatology

²Washington University in St Louis, Department of Radiation Oncology

³The Ohio State University, Division of Dermatopathology and Hematopathology

Correspondence:

Charles Mount MD
Washington University in St. Louis
charles.e.mount@gmail.com

Abstract

Pagetoid reticulosis, also known as Woringer-Kolopp disease, is a rare variant of cutaneous T-cell lymphoma usually presenting as an isolated patch or plaque on the extremities. Immunohistochemical staining of T-cell markers can be variable, but as the name implies the epidermotropic lymphocytes consistently display a “pagetoid” appearance. The following case demonstrates clearance of this condition with intensity modulated radiation therapy, whereas most cases are managed with electron beam therapy if radiation therapy is implemented.

Introduction

Pagetoid reticulosis is a well documented, but rare, localized form of mycosis fungoides. According to the World Health Organization-European Organization for Research and Treatment of Cancer cutaneous lymphoma classification it is also referred to as the localized Woringer-Kolopp disease. The more diffuse form referred to as Ketrion-Goodman disease is more appropriately categorized today as aggressive epidermotropic CD8-positive cytotoxic T-cell lymphoma, cutaneous gamma-delta-positive T-cell lymphoma, or tumor-stage mycosis fungoides [1]. Pagetoid reticulosis often presents as a solitary or localized erythematous patch and eventually a psoriasiform plaque, typically on the distal extremities. The significant epidermotropism of the lymphocytes seen on histology resembling that of Paget’s disease distinguish it from classic mycosis fungoides and explains the ‘pagetoid’ portion of its name.

Given its overall rare incidence and overlapping clinical features with other more common and benign entities, it may be overlooked. Its slow, indolent course may allow it to progress while the patient or their providers treat it as similarly appearing dermatoses such as psoriasis, eczema or contact dermatitis, bacterial or fungal infection, atrophic dermatofibroma, or porokeratosis of Mibelli. Pagetoid reticulosis may improve or at least stabilize with shared treatment modalities such as corticosteroids, retinoids, phototherapy, and surgery, which may further complicate and delay its diagnosis [2-6].

Case synopsis

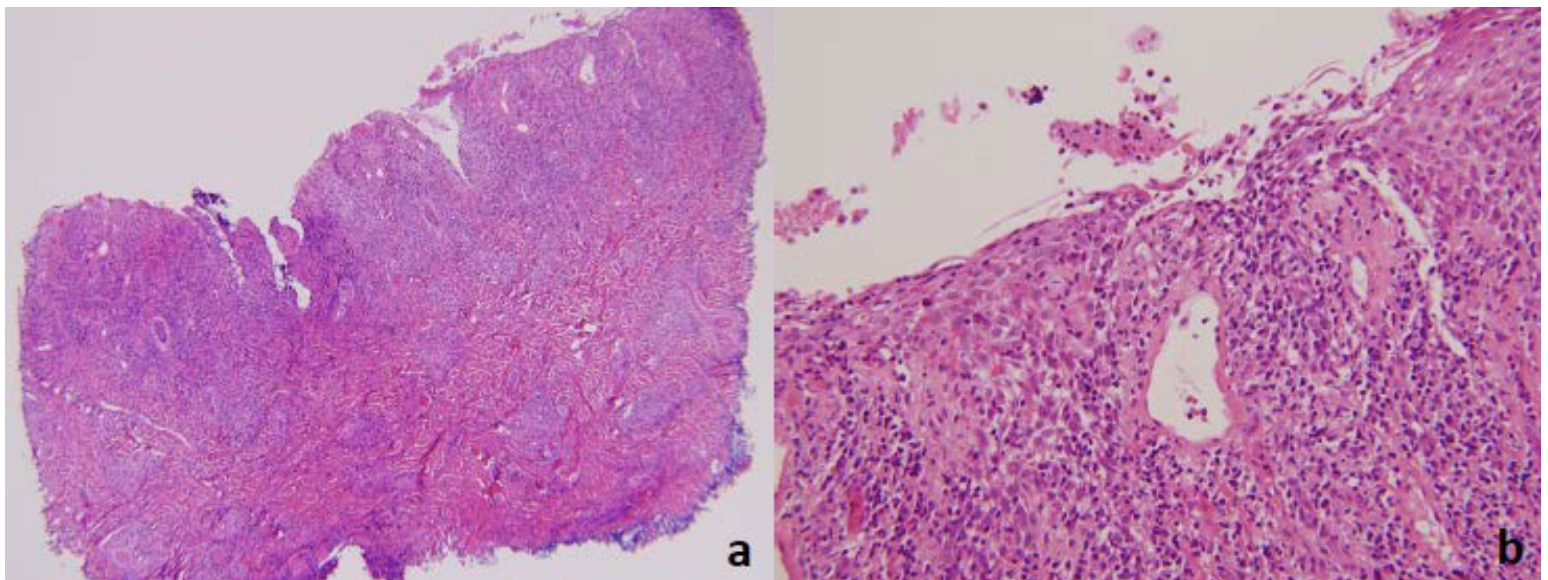
We report a case of an 89-year-old man, first referred to the dermatology service for the treatment of resistant plantar psoriasis. Over several months he cleared with topical psoralen with ultraviolet A phototherapy in addition to ultra potent topical steroids plus tar compounds. After recurring, his condition cleared again with narrow band ultraviolet B phototherapy. He eventually

developed an open ulceration (Figure 1a, b): Plantar surface. Figure 1b: Lateral surface) on the left plantar surface and biopsies were performed.

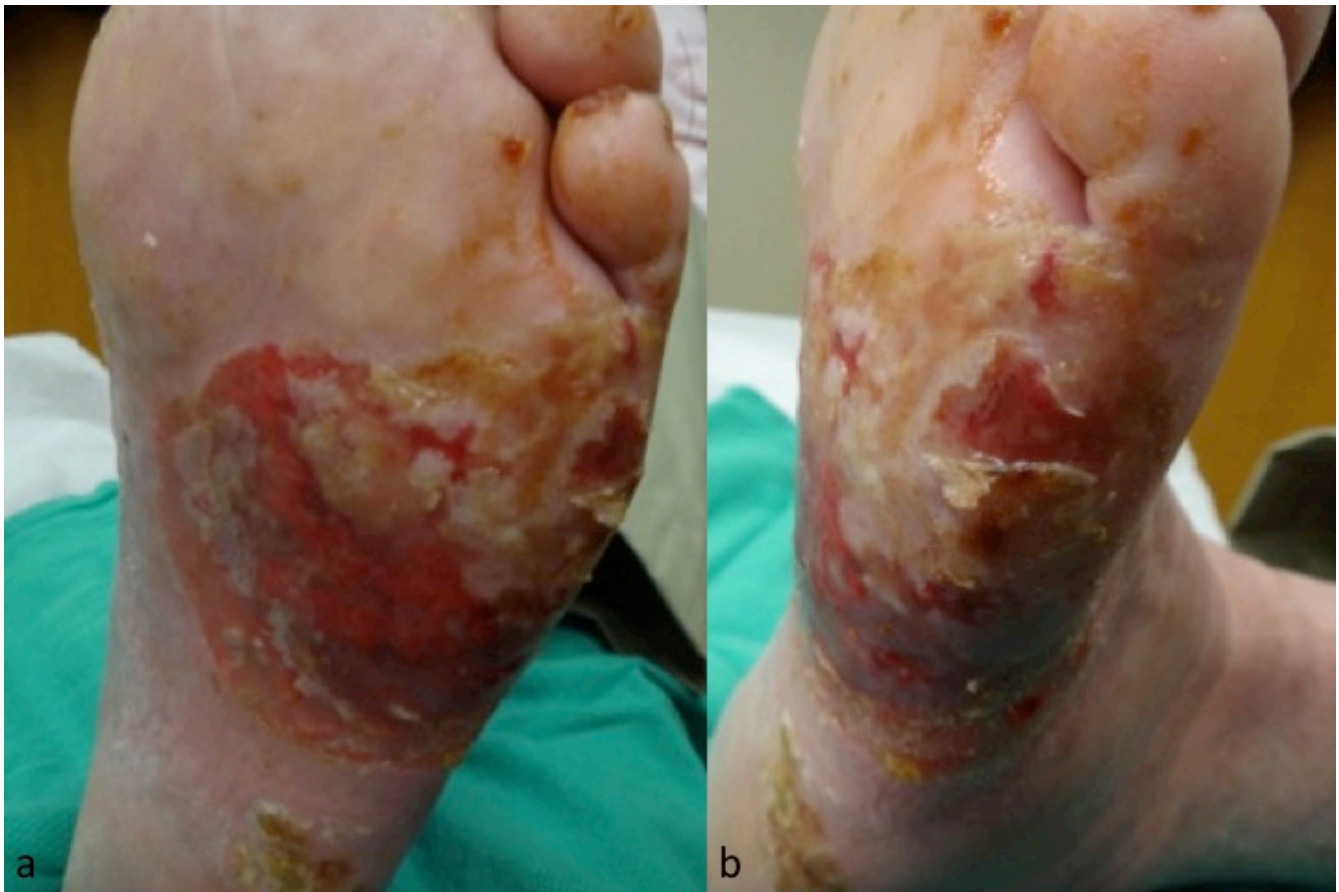

Figure 1 Parts A-B. Plantar and lateral surface views of the left foot showing the erythematous ulcerated plaque at the time of biopsy

Histology revealed an ulcerated epidermis with a dense lymphocytic infiltrate that obscured the dermoepidermal junction (Figure 2). The lymphocytic population showed a marked epidermotropism with numerous cells having perinuclear halo, irregular and cerebriform nuclei, and hyperchromatic chromatin. No Pautrier microabscesses were seen. The lymphocytic population also tagged the dermoepidermal junction. The same abnormal lymphoid population was present throughout the dermis with a background rich in eosinophils. Scattered large and atypical cells were also present but represented less than 10% of the neoplastic cells. The immunophenotype of the abnormal lymphoid population was CD4+ with aberrant loss of CD7 and partial CD30 expression particularly, among the large cells. Further molecular studies revealed a clonal T-cell receptor gene rearrangement by routine polymerase chain reaction analysis. His diagnosis was consistent with pagetoid reticulosis consistent with his long-standing, isolated plaque on the foot with the above histopathologic findings.



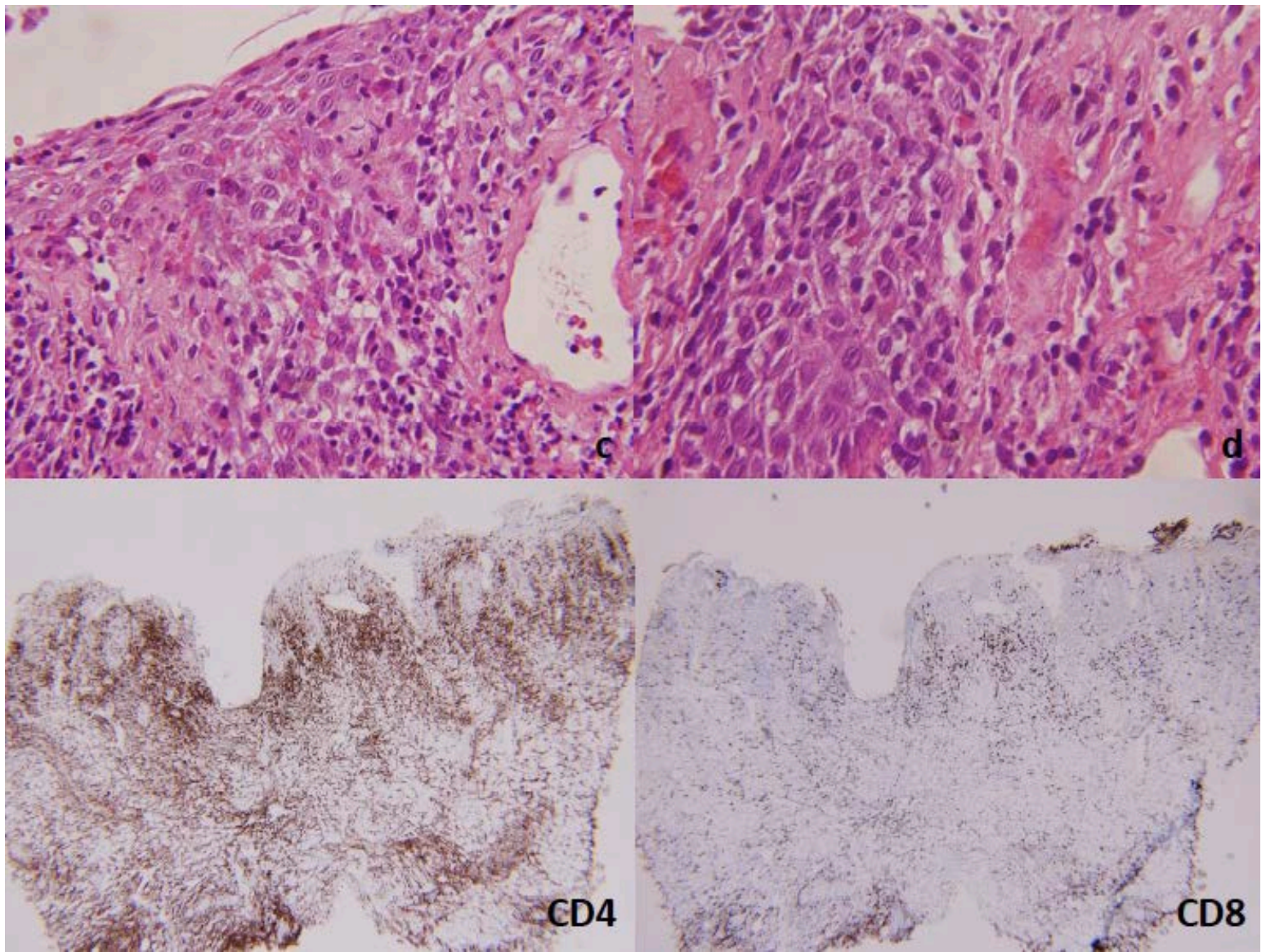


Figure 2 Part a-d. Histology specimen exhibiting a dense, atypical, lymphocytic epidermotropic infiltrate: Immunohistochemical staining revealing a CD4 predominant population of cells

He was then evaluated by the radiation oncology department for definitive radiation therapy. In prior reports, radiation therapy to a dose of 26-41 Gray, delivered either by en face electrons or opposed lateral photon beams have been reported with good long-term results [5,7]. In this case, the affected areas encompassed both the dorsal and plantar surface of the foot, which made electron therapy difficult owing to the need for multiple matched fields over curved profiles. Opposed lateral photon fields were also considered. However this would require delivering the dose to the entire foot, which could lead to increased risk for long-term radiation therapy sequelae of the deep tissues such as fibrosis.

To reduce the risk associated with unnecessary dose to the deep tissues, an intensity modulated radiation therapy plan was developed. A computed tomography simulation of the patient's affected foot was performed in an alpha cradle. A thermoplastic mesh boot surrounding a 1 cm of tissue-equivalent custom bolus was wrapped and taped around the foot (Figures 3a and 3b). A triangle cushion was placed under the patient's knee; the opposite leg was frogged out to avoid any intensity modulated radiation therapy beams going through the opposite foot. A clinical treatment volume was contoured on the computed tomography images encompassing the most superficial 3-5 mm of tissue. A 5 mm expansion of the clinical treatment volume was generated to create the planning treatment volume, which allowed for daily setup and positioning errors.

The patient was prescribed 40 Gray in 2 Gray fractions. During treatment, the patient had improvement in his symptoms from tumor response followed by increased discomfort and tenderness from radiation therapy-related moist desquamation. His skin reaction peaked approximately 1 week after therapy completed. No pauses or delays were necessary during his treatment schedule. During the recovery phase, a shoe insert was created with bolus material and a hole aligned with the patient's round patch of moist desquamation to decrease the pressure in this area. Erythema was less pronounced and the plaque had decreased in size by the

completion of his intensity modulated radiation therapy regimen (Figure 4a). Clearing was achieved and maintained at two and five months after completing treatment (Figures 4b-d).

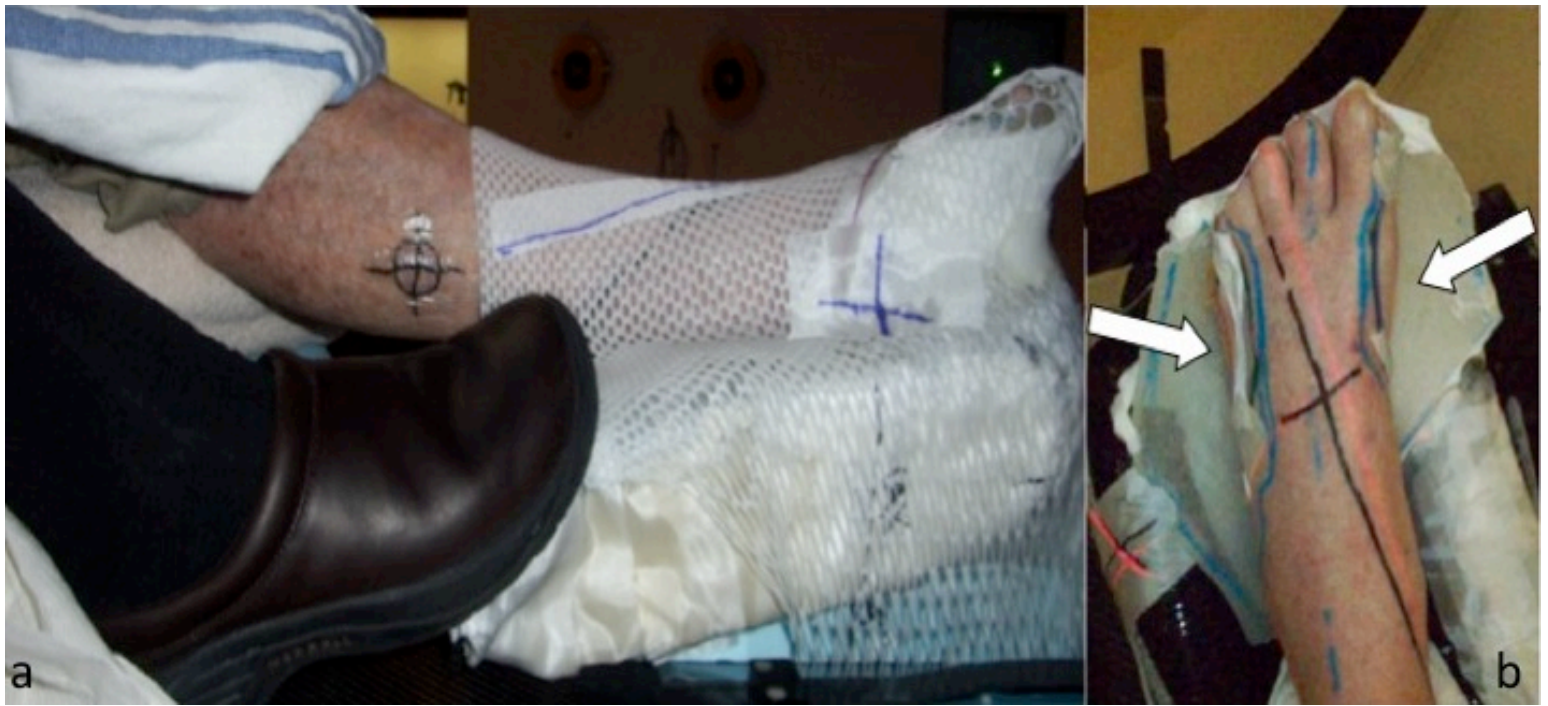

Figure 3 Parts a-b. The thermoplastic mesh boot surrounding a 1 cm tissue-equivalent custom bolus (arrows). The tissue-equivalent acts to absorb photons and protect normal tissue outside of the therapeutic field.

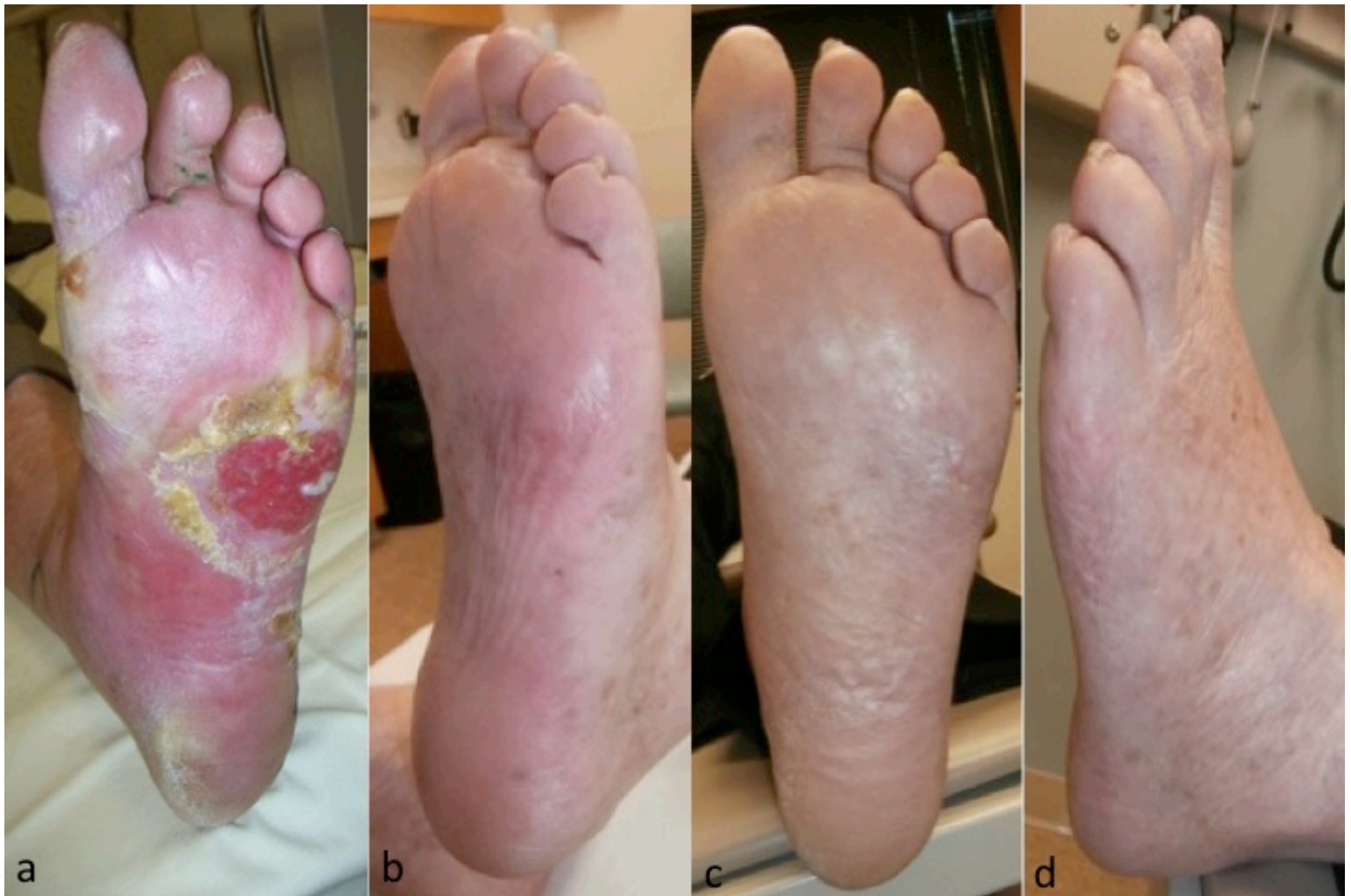

Figure 4 Parts a-d. Post-treatment clinical response at 0 months (a), 2 months (b), and 5 months (c and d)

Discussion

Pagetoid reticulosis represents a localized, exquisitely epidermotropic form of the mycosis fungoides responsive to localized radiation therapy [3,8]. The differential diagnosis of this entity includes infectious and inflammatory processes in addition to aggressive primary cutaneous lymphomas that often require intensive chemotherapeutic regimens and are usually associated with a poor outcome [1]. On exam, pagetoid reticulosis can appear very concerning, with tumors and ulceration. However, it is relatively indolent and responds to localized treatments. Pagetoid reticulosis may even resolve spontaneously before initiation of treatment [9]. The histopathologic and clinical distinction of pagetoid reticulosis from classic mycosis fungoides and other forms of cutaneous T-cell lymphoma remains important owing to the difference in disease course and prognosis. Systemic involvement and mortality related to pagetoid reticulosis have not been documented in this cutaneous T-cell lymphoma variant.

Pagetoid reticulosis presents with either a CD30 positive or negative immunophenotype in addition to CD3 and CD4 positive markers, but may also be CD8 positive/CD4 negative [2-3]. An even more rare CD4/CD8 double negative immunophenotype has also been reported, but is now considered to be in a different diagnostic category [3,5-7].

In prior reports, radiation therapy to a dose of 26-41 Gray, delivered either by en face electrons or opposed lateral photon beams, have been reported with good long-term results [8,10]. In this case, the affected areas encompassed both the dorsal and plantar surface of the foot, which made electron therapy difficult because of the need for multiple matched fields over curved profiles. Opposed lateral photon fields were also considered. However this would require delivering the dose to the entire foot, which could lead to increased risk for long-term radiation therapy sequelae of the deep tissues such as fibrosis.

Although the use of electron beam therapy in mycosis fungoides and pagetoid reticulosis is well established, the use of intensity modulated radiation therapy, which instead uses photons, is less reported. Intensity modulated radiation therapy has been used to treat a case of scalp mycosis fungoides prior to stem cell transplant and in a case of Natural Killer/T-cell lymphoma nasal type, but not specifically in the treatment of pagetoid reticulosis [10-11].

Intensity modulated radiation therapy is an external beam radiation therapy technique. Initially described nearly 20 years ago, advances in computing permitted it to rapidly become standard practice for many tumors. Intensity modulated radiation therapy involves customized, nonuniform assignment of intensities to small treatment beams directed toward a therapeutic target to meet specified dosimetric objectives. The iterative, computational adjustment of intensities of these individual beams results in highly conformal dose distributions and the opportunity for both better disease control and improved normal tissue sparing. The resulting treatment plans are frequently more conformal than standard three-dimensional radiation therapy techniques. Use of intensity modulated radiation therapy with tissue-equivalent custom bolus improved dose delivery to the tumor in our patient [12-13].

Our patient exhibited a complete response to intensity modulated radiation therapy. His long-standing disease cleared within a few months of treatment and he experienced mild, localized side effects. Whereas his ambulation was initially hindered owing to the ulcerated plaque on the lateral-plantar surfaces of his foot, he was walking without difficulty just several months later. By using this treatment modality he was spared frequent office visits for phototherapy and the potential systemic side effects from retinoids and chemotherapy.

Although pagetoid reticulosis may be fully or partially responsive to other mycosis fungoides treatment regimens, such as topical nitrogen mustard, topical retinoids, phototherapy, and even surgery [2-3], several case series and authors have documented a better treatment response to local radiation therapy [5-7]. This case demonstrates intensity modulated radiation therapy as an effective treatment modality with low risk of systemic side effects in addition to high compliance and equal, if not superior, medical outcomes to other previous documented treatment modalities.

Conclusion

Pagetoid reticulosis remains a rare entity that for reasons yet to be elucidated runs an indolent course with no reported cases ending in death. It does, however, have the ability to mimic other more common conditions affecting the extremities. Because it may partially respond to the treatments for such conditions it may go undiagnosed for long periods of time. It should be considered in cases of more common dermatoses that do not respond to standard therapies. The pagetoid appearance of the lymphocytes on histopathology sets it apart from other cutaneous T-cell lymphomas. The presence or absence of T-cell markers can be variable, although it is typically a CD4 predominant lesion. When lesions extend over multiple surfaces of a patient's anatomy a different approach than standard electron beam therapy may need to be considered. Intensity modulated radiation therapy has the advantage of being able to administer the desired dose using a treatment field over a contoured surface. This method of delivering electromagnetic energy proves to be a viable option in the treatment of pagetoid reticulosis and perhaps other cases and variants of localized cutaneous T-cell lymphomas.

References

1. Willemze R, Jaffe ES, Burg G, Cerroni L, Berti E, Swerdlow SH, Ralfkiaer E, Chimenti S, Diaz-Perez JL, Duncan LM, Grange F, Harris NL, Kempf W, Kerl H, Kurrer M, Knobler R, Pimpinelli N, Sander C, Santucci M, Sterry W, Vermeer MH, Wechsler J, Whittaker S, Meijer CJ. WHO-EORTC classification for cutaneous lymphomas. *Blood*. 2005;105(10):3768-85. [PMID: 15692063]
2. Martin SJ, Cohen PR, Cho-Vega JH, Tschen JA. CD8+ Pagetoid Reticulosis Presenting as a Solitary Foot Plaque in a Young Woman. *J Clin Aesthet Dermatol*. 2010;3(10):46-9. [PMID: 20967196]
3. Yao Y, Mark LA. Woringer-Kolopp disease mimicking foot dermatitis. *Cutis*. 2012;90(6):307-9, 316. [PMID: 23409481]
4. Lichte V, Ghoreschi K, Metzler G, Möhrle M, Geyer A, Röcken M, Schaller M. Pagetoid reticulosis (Woringer-Kolopp disease). *J Dtsch Dermatol Ges*. 2009;7(4):353-4. [PMID: 19054422]
5. Lee J, Viakhireva N, Cesca C, Lee P, Kohler S, Hoppe RT, Kim YH. Clinicopathologic features and treatment outcomes in Woringer-Kolopp disease. *J Am Acad Dermatol*. 2008;59(4):706-12. [PMID: 18550209]
6. Lee AD, Cohen PR. What is Woringer-Kolopp disease? *Skinmed*. 2013 Jan-Feb; 11(1):17-20. [PMID: 23540072]
7. Hsieh TT, Wang JY, Wu YH. Pagetoid reticulosis with a keloid-like appearance. *Dermatologica Sinica*. 2013;31(3):157-158. [No PMID]
8. Mercer SE, Vidal CI, Grummer SE, Strauchen JA, Gordon ML, Birge MB. Pagetoid reticulosis after radiotherapy of primary cutaneous anaplastic large-cell lymphoma. *Am J Dermatopathol*. 2010;32(1):79-82. [PMID: 19940753]
9. Mourtzinos N, Puri PK, Wang G, Liu ML. CD4/CD8 double negative pagetoid reticulosis: a case report and literature review. *J Cutan Pathol*. 2010;37(4):491-6. [PMID: 19614989]
10. Samant RS, Fox GW, Gerig LH, Montgomery LA, Allan DS. Total scalp radiation using image-guided IMRT for progressive cutaneous T cell lymphoma. *Br J Radiol*. 2009;82(978):e122-5. [PMID: 19451312]
11. Shen Q, Ma X, Hu W, Chen L, Huang J, Guo Y. Intensity-modulated radiotherapy versus three-dimensional conformal radiotherapy for stage I-II natural killer/T-cell lymphoma nasal type: dosimetric and clinical results. *Radiat Oncol*. 2013;8:152. [PMID: 23800149]
12. Teh BS, Woo SY, Butler EB. Intensity modulated radiation therapy (IMRT): a new promising technology in radiation oncology. *Oncologist*. 1999;4(6):433-42. [PMID: 10631687]
13. Chao KSC, Mohan R, Marinetti TD, Dong L. Intensity-Modulated Radiation Treatment Techniques and Clinical Applications. In: Halperin EC, Wazer DE, Perez CA, and Brady LW, eds. *Perez and Brady's Principles and Practice of Radiation Oncology*. 6th ed. Philadelphia, PA: Lippincott Williams and Wilkins; 2013.