

2016

# A brushfire in the eye

Mehnaz Khan  
*Cole Eye Institute*

P. Kumar Rao  
*Washington University School of Medicine in St. Louis*

Rajesh C. Rao  
*University of Michigan-Ann Arbor*

Follow this and additional works at: [http://digitalcommons.wustl.edu/open\\_access\\_pubs](http://digitalcommons.wustl.edu/open_access_pubs)

---

## Recommended Citation

Khan, Mehnaz; Rao, P. Kumar; and Rao, Rajesh C., "A brushfire in the eye." *BMJ*.353, i3075. (2016).  
[http://digitalcommons.wustl.edu/open\\_access\\_pubs/5112](http://digitalcommons.wustl.edu/open_access_pubs/5112)

This Open Access Publication is brought to you for free and open access by Digital Commons@Becker. It has been accepted for inclusion in Open Access Publications by an authorized administrator of Digital Commons@Becker. For more information, please contact [engeszer@wustl.edu](mailto:engeszer@wustl.edu).



# ENDGAMES

## CASE REVIEW

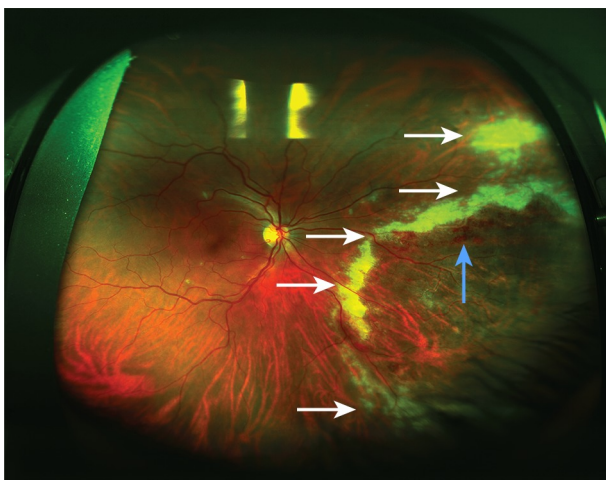
### A brushfire in the eye

Mehnaz Khan *vitreoretinal fellow*<sup>1</sup>, P Kumar Rao *professor*<sup>2</sup>, Rajesh C Rao *assistant professor*<sup>3 4</sup>

<sup>1</sup>Cole Eye Institute, Cleveland Clinic, Cleveland, Ohio, USA; <sup>2</sup>Department of Ophthalmology and Visual Sciences, Washington University School of Medicine, St Louis, MO, USA; <sup>3</sup>Department of Ophthalmology and Visual Sciences, WK Kellogg Eye Center, University of Michigan, Ann Arbor, MI 48105, USA; <sup>4</sup>Department of Pathology, University of Michigan

A 44 year old man with untreated HIV infection was referred to the department of ophthalmology for routine screening of ocular disease. He reported non-compliance with highly active antiretroviral therapy (HAART) consisting of efavirenz, tenofovir, and emtricitabine, and his CD4 count was below  $50 \times 10^6$  cells/L. He had no ocular problems at the time of presentation to his general practitioner.

His visual acuity was normal. Examination of the anterior structures of both eyes was unremarkable. Examination of the right eye identified a white annular edge of haemorrhagic retinitis in a brushfire pattern (fig 1). The fundus of the left eye looked normal.



**Fig 1** Fundus photograph of the right eye on presentation showing a white, annular leading edge of retinitis (white arrows) associated with haemorrhage (blue arrow) in a brushfire pattern.

### Questions

1. What are the differential diagnoses for retinitis?
2. What is the diagnosis?

3. What is the most common cause of blindness in this condition?

4. What are the available treatments and follow-up recommendations?

### Answers

1. **What are the differential diagnoses for retinitis?**

#### Short answer

Retinitis can be secondary to viral, bacterial, fungal, and parasitic infections; autoimmune conditions; and cancer.

#### Discussion

The differential diagnoses include infections—viral (eg, herpes simplex virus (HSV), herpes zoster virus (VZV), cytomegalovirus (CMV)), bacterial (eg, syphilis and tuberculosis), parasitic (eg, toxoplasmosis and *Toxocara canis*), and fungal (eg, candida) entities. Autoimmune diseases such as Behçet’s syndrome and cancers such as vitreoretinal lymphoma should also be considered. A complete medical history, as well as serological or intraocular fluid analysis (eg, polymerase chain reaction, fungal smear) can help narrow the diagnosis.

2. **What is the diagnosis?**

#### Short answer

Cytomegalovirus retinitis.

#### Discussion

Our case is a striking example of CMV retinitis with a “brushfire” pattern in an immunocompromised host. Although the diagnosis was largely based on clinical examination,

polymerase chain reaction of biopsied intraocular fluid confirmed the presence of CMV.

Occasionally described as a “pizza pie,” “cheese and ketchup,” or “brushfire” retinitis, CMV retinitis is the most common opportunistic ocular infection in HIV/AIDS and other severely immunocompromised states. CMV remains latent after primary infection but is reactivated when cell mediated immunity is severely impaired, as in HIV positive patients who are poorly compliant with HAART.<sup>1</sup> The reactivated CMV can disseminate throughout the body and seed any organ; the most common target in patients with HIV is the eyes.<sup>1</sup>

CMV retinitis can be broadly categorised into two forms: indolent and fulminant. The indolent form presents with granular opacities in the peripheral retina and occasional associated haemorrhages.<sup>2,3</sup> The fulminant form manifests as confluent areas of necrosis and prominent haemorrhages most commonly starting along the major retinal vascular arcades.<sup>2,3</sup> Few inflammatory cells are present in the anterior or posterior segments of the eye in both forms of the disease.

CMV retinitis is characterised by necrotic retinitis, which progresses over months from an acute to a chronic stage. Chronic inflammatory cells and both intranuclear and intracytoplasmic inclusion bodies are seen throughout the active margins of the lesions.<sup>4</sup> With time, the cytoarchitecture of the full thickness retina is destroyed, and this presents as atrophic retina.<sup>5</sup>

Patients with CMV retinitis may be asymptomatic or they may present with blurred or decreased vision, loss of peripheral or central vision, and multiple floaters.<sup>6</sup> Given that CMV retinitis can be asymptomatic, it is important for primary care and emergency physicians, infectious disease specialists, and ophthalmologists to be aware of CMV retinitis and to be vigilant, especially in patients with low CD4 counts, even in the absence of presenting symptoms. Clinicians who care for immunocompromised patients must therefore be able to recognise CMV retinitis, especially in areas where access to ophthalmology expertise is limited. One recent study showed that a four day task oriented training workshop was sufficient to train clinicians (non-ophthalmologists) working in HIV clinics to do binocular indirect ophthalmoscopy for the diagnosis of CMV retinitis.<sup>7</sup>

Although CMV retinitis is the most common ocular infection in immunocompromised patients, other causes must be considered. For example, cotton wool spots—infarctions of the nerve fibre layer of the retina—are common in HIV retinopathy but can be differentiated from early CMV retinitis by their smaller size, more superior location, and lack of progression.<sup>8,9</sup> Toxoplasmosis retinochoroiditis can also present with retinitis similar to CMV infection, but the accompanying retinal haemorrhage is usually less severe than that seen in untreated CMV retinitis.<sup>10</sup> Necrotising herpetic retinitis including acute retinal necrosis (ARN) and progressive outer retinal necrosis (PORN), which are linked to HSV and VZV, respectively, can also occur in immunocompromised patients. PORN is characterised by yellow-white infiltrates and often presents with little or no vitritis, and its treatment (eg, intravitreal ganciclovir or foscarnet) can be similar to that used for CMV retinitis. However PORN can affect the macular region early on in the disease process, whereas this region is often involved at a later point in CMV retinitis.<sup>11</sup> Overall, it is prudent to consider a broad differential diagnosis for retinitis in immunocompromised patients. If the clinical diagnosis remains uncertain, consider evaluation of intraocular fluid by biopsy or diagnostic vitrectomy

with CMV specific polymerase chain reaction and histological examination.<sup>12</sup>

### 3. What is the most common cause of blindness in this condition?

#### Short answer

CMV retinitis of the posterior pole.

#### Discussion

CMV infection can cause retinal necrosis, retinal detachment, cataract, and optic atrophy, which can all lead to visual acuity or visual field loss (or both).<sup>13</sup> The three most common causes of CMV associated blindness (less than 20/200 vision) are CMV retinitis of the macular or optic nerve (posterior), cataract, and retinal detachment, which account for ~55%, ~25%, and ~15% of cases, respectively.<sup>14</sup>

Because the macula is responsible for the detection of fine details (vision better than 20/200) and the optic nerve transmits all visual information from the retina to the brain, it is not surprising that CMV retinitis involving these structures can cause blindness. In some cases, CMV retinitis affects the peripheral retina first, and in this situation the risk of blindness can be decreased by starting treatment before the macula or optic nerve is affected.<sup>14</sup> Cataract often occurs after immune recovery ( $>100 \times 10^6$  cells/L), and because it is less common when CD4 cell counts are low it is thought to have an inflammatory component.<sup>14</sup> In addition to cataract, immune recovery can be associated with symptoms of posterior uveitis, such as cystoid macular oedema, vitritis, and epiretinal membrane formation, which can also cause vision loss, although they are not such common causes of vision loss as retinitis of the macular or optic nerve, cataract, and retinal detachment.<sup>14</sup>

Although retinal detachment is only the third most common cause of CMV related blindness, it is an ominous risk factor: it portends blindness to a greater degree than involvement of the macula or optic nerve and cataract.<sup>14</sup> Retinal detachment is usually caused by retinal holes at the junction of the affected atrophic retina and the normal retina. This is precipitated by traction of the vitreous on the underlying retina.<sup>15</sup> The reported incidence of retinal detachment in patients with CMV retinitis is 33-50% per eye per year.<sup>16-18</sup> One retrospective study found that adherence to HAART in patients with HIV and a diagnosis of CMV retinitis statistically significantly reduces the risk of progression to retinal detachment.<sup>19</sup> This is probably because the immune response reduces CMV replication, which may suppress retinitis activity and prevent progression of the retinal lesions. This is consistent with other studies showing that larger lesion size is a known risk factor for development of retinal detachment.<sup>16,18</sup>

Since the introduction of HAART, the incidence of CMV retinitis has plummeted in developed countries. However, data from the Longitudinal Study of the Ocular Complications of AIDS (LSOCA) show that even though CMV retinitis related ocular complications and overall mortality have decreased, patients with this condition still experience CMV related vision loss such as retinal detachment and cataract, as well as death at five year follow-up.<sup>14,20</sup>

4.

## What are the available treatments and follow-up recommendations?

### Short answer

Intravenous ganciclovir, the oral prodrug valganciclovir, intravenous foscarnet, intravenous cidofovir, intravitreal injections of ganciclovir or foscarnet, or the ganciclovir intraocular implant (not currently available).

### Discussion

The treatment of CMV retinitis includes systemic or local (intravitreal) administration of the anti-CMV drugs listed above. Studies demonstrating the efficacy of these drugs were largely performed before the introduction of HAART.<sup>21-22</sup> The overall finding from these studies is that intraocular localised therapy with the ganciclovir implant controls retinitis better than systemic ganciclovir alone, but that systemic treatment prevents dissemination (spread to second eye in unocular disease or visceral dissemination) better than intraocular implant therapy alone.<sup>23-25</sup>

LSOCA showed that even with the introduction of HAART, anti-CMV systemic drugs decrease the risk of mortality and visceral dissemination and, in unilateral ocular disease, decrease the risk of dissemination to the other eye.<sup>25</sup> Overall, the study authors recommended instituting systemic treatment in patients with newly diagnosed CMV retinitis regardless of whether concomitant intraocular (direct injection into the vitreous) therapy is given, and that treatment should be continued at least until the CD4 count has returned to  $\geq 100 \times 10^6$  cells/L cells for six months or more.<sup>25-26</sup>

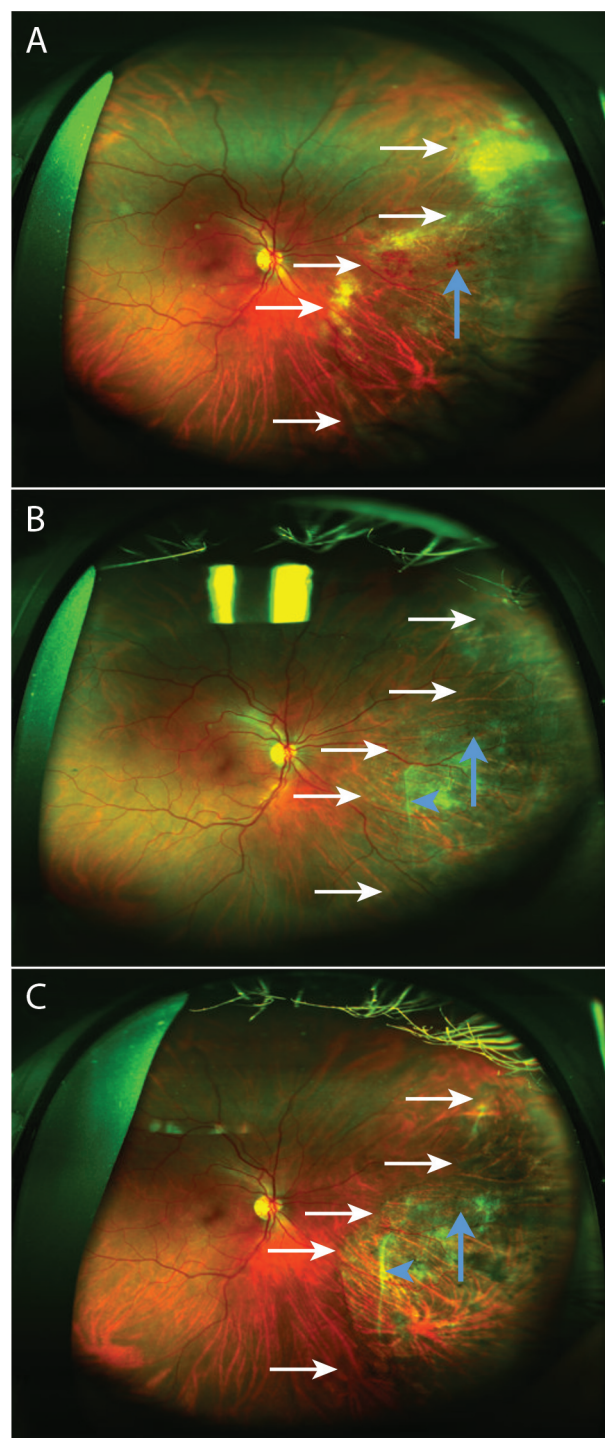
Before HAART was introduced, 41.9%, 26.3%, and 14.7% of patients with baseline CD4 counts of  $0-50 \times 10^6$  cells/L,  $51-100 \times 10^6$  cells/L, and  $101-250 \times 10^6$  cells/L, respectively, developed CMV retinitis over about two years.<sup>27</sup> Although HAART has reduced the incidence of CMV retinitis by about 75%,<sup>14-28</sup> it is still one of the most common opportunistic infections in patients with AIDS. With the introduction of HAART, the rate of progression to retinitis has decreased from 3 per patient year to 0.10 per patient year. For the subset of patients with CD4 cells  $\geq 100 \times 10^6$  cells/L progression has decrease further to 0.06 per patient year (CD4 count  $199-299 \times 10^6$  cells/L) and 0.02 per patient year (CD4 count  $\geq 200 \times 10^6$  cells/L). Thus the rate of progression to retinitis is not zero, and patients with CD4 counts  $\leq 100 \times 10^6$  cells/L can relapse. Indeed, LSOCA investigators recommend dilated ophthalmic examination every three months in patients with a history of CMV retinitis and a CD4 count of  $\leq 100 \times 10^6$  cells/L even when systemic anti-CMV therapy has been discontinued.<sup>20-28</sup>

CMV retinitis can cause blindness so requires urgent treatment, with referral to ophthalmology and infectious disease consultants. Hospital admission should be considered if compliance remains uncertain.

### Patient outcome

After diagnosis, the patient was started on HAART and oral valganciclovir. In addition to regular follow-up for his retina care, he regularly visited an infectious disease specialist. Oral valganciclovir was stopped nearly a year after his initial visit when he achieved a CD4 count  $\geq 100 \times 10^6$  cells/L, which was sustained during the follow-up period (two years after his first ophthalmic examination). During this time, the CMV retinitis evolved from a haemorrhagic form to an inactive retinal scar. The haemorrhages gradually resolved over two years, a

subretinal band formed, and a demarcation line (the boundary between viable and scarred necrotic retina) appeared (fig 2). His retinitis has not recurred.



**Fig 2** Fundus photographs of the right eye during two years of treatment. The right eye was examined after initiation of highly active antiretroviral therapy and oral ganciclovir. The retinitis (white arrows) and haemorrhages (blue arrows) resolved over one week (A), six weeks (B), and at two years (C). A subretinal band formed at six weeks (B; black arrowhead), and persisted at two years (C, blue arrowhead). At two years (C), a demarcation line (white arrows: boundary between viable and scarred, necrotic retina) formed in the place of the leading edge of the previous retinitis (A and B; white arrows)

Competing interests: We have read and understood BMJ policy on declaration of interests and declare the following interests: None.



Provenance and peer review: Not commissioned; externally peer reviewed.

Patient consent obtained.

- 1 Gallant JE, Moore RD, Richman DD, Keruly J, Chaisson RE. The Zidovudine Epidemiology Study Group. Incidence and natural history of cytomegalovirus disease in patients with advanced human immunodeficiency virus disease treated with zidovudine. *J Infect Dis* 1992;166:1223-7. doi:10.1093/infdis/166.6.1223 pmid:1358986.
- 2 Holland GN, Vaudaux JD, Jeng SM, et al. UCLA CMV Retinitis Study Group. Characteristics of untreated AIDS-related cytomegalovirus retinitis. I. Findings before the era of highly active antiretroviral therapy (1988 to 1994). *Am J Ophthalmol* 2008;145:5-11. doi:10.1016/j.ajo.2007.09.040 pmid:18154750.
- 3 Holland GN, Vaudaux JD, Shiramizu KM, et al. Southern California HIV/Eye Consortium. Characteristics of untreated AIDS-related cytomegalovirus retinitis. II. Findings in the era of highly active antiretroviral therapy (1997 to 2000). *Am J Ophthalmol* 2008;145:12-22. doi:10.1016/j.ajo.2007.09.040 pmid:18154751.
- 4 D'Amico DJ, Talamo JH, Felsenstein D, Hirsch MS, Albert DM, Schooley RT. Ophthalmoscopic and histologic findings in cytomegalovirus retinitis treated with BW-B759U. *Arch Ophthalmol* 1986;104:1788-93. doi:10.1001/archoph.1986.01050240062041 pmid:3024605.
- 5 Pepose JS, Hilborne LH, Cancilla PA, Foos RY. Concurrent herpes simplex and cytomegalovirus retinitis and encephalitis in the acquired immune deficiency syndrome (AIDS). *Ophthalmology* 1984;91:1669-77. doi:10.1016/S0161-6420(84)34108-2 pmid:6097855.
- 6 Friedberg DN. Cytomegalovirus retinitis: diagnosis and status of systemic therapy. *J Acquir Immune Defic Syndr Hum Retroviral* 1997;14(Suppl 1):S1-6. doi:10.1097/00042560-199700001-00002 pmid:9058611.
- 7 Maningding E, Tun N, Chan KN, et al. CMV retinitis diagnosis by non-ophthalmologists: learning curve over a 4-day training workshop. *J Acquir Immune Defic Syndr* 2015;69:e115-7. doi:10.1097/QAI.0000000000000629 pmid:25844697.
- 8 Freeman WR, Lerner CW, Mines JA, et al. A prospective study of the ophthalmologic findings in the acquired immune deficiency syndrome. *Am J Ophthalmol* 1984;97:133-42. doi:10.1016/S0002-9394(14)76082-9 pmid:6320647.
- 9 Holland GN, Pepose JS, Pettit TH, Gottlieb MS, Yee RD, Foos RY. Acquired immune deficiency syndrome. Ocular manifestations. *Ophthalmology* 1983;90:859-73. doi:10.1016/S0161-6420(83)80009-8 pmid:6314219.
- 10 Schmitz K, Fabricius EM, Brommer H, Emminger C. [Prevalence, morphology and therapy of toxoplasmosis chorioretinitis in AIDS]. *Fortschr Ophthalmol* 1991;88:698-704. pmid:1794794.
- 11 Pavesio CE, Mitchell SM, Barton K, Schwartz SD, Towler HM, Lightman S. Progressive outer retinal necrosis (PORN) in AIDS patients: a different appearance of varicella-zoster retinitis. *Eye (Lond)* 1995;9:271-6. doi:10.1038/eye.1995.53 pmid:7556731.
- 12 Crosson JN, Laird PW, Grossniklaus HE, Hendrick AM. Toxoplasma chorioretinitis diagnosed by histopathology in a patient with AIDS. *Retin Cases Brief Rep* 2015;9:162-3. doi:10.1097/ICB.0000000000000126 pmid:25621872.
- 13 Butler NJ, Thorne JE. Current status of HIV infection and ocular disease. *Curr Opin Ophthalmol* 2012;23:517-22. doi:10.1097/ICU.0b013e328358ba85 pmid:23047168.
- 14 Thorne JE, Jabs DA, Kempen JH, Holbrook JT, Nichols C, Meinert CL. Studies of Ocular Complications of AIDS Research Group. Causes of visual acuity loss among patients with AIDS and cytomegalovirus retinitis in the era of highly active antiretroviral therapy. *Ophthalmology* 2006;113:1441-5. doi:10.1016/j.ophtha.2006.03.022 pmid:16781775.
- 15 Chuang EL, Davis JL. Management of retinal detachment associated with CMV retinitis in AIDS patients. *Eye (Lond)* 1992;6:28-34. doi:10.1038/eye.1992.4 pmid:1330757.
- 16 Freeman WR, Friedberg DN, Berry C, et al. Risk factors for development of rhegmatogenous retinal detachment in patients with cytomegalovirus retinitis. *Am J Ophthalmol* 1993;116:713-20. doi:10.1016/S0002-9394(14)73471-3 pmid:8250074.
- 17 The Studies of Ocular Complications of AIDS (SOCA) Research Group in Collaboration with the AIDS Clinical Trials Group (ACTG). Rhegmatogenous retinal detachment in patients with cytomegalovirus retinitis: the Foscarnet-Ganciclovir Cytomegalovirus Retinitis Trial. *Am J Ophthalmol* 1997;124:61-70. doi:10.1016/S0002-9394(14)71645-9 pmid:9222234.
- 18 Jabs DA, Enger C, Haller J, de Bustros S. Retinal detachments in patients with cytomegalovirus retinitis. *Arch Ophthalmol* 1991;109:794-9. doi:10.1001/archoph.1991.01080060058024 pmid:1645952.
- 19 Kempen JH, Jabs DA, Dunn JP, West SK, Tonascia J. Retinal detachment risk in cytomegalovirus retinitis related to the acquired immunodeficiency syndrome. *Arch Ophthalmol* 2001;119:33-40. pmid:11146724.
- 20 Jabs DA, Ahuja A, Van Natta M, Lyon A, Srivastava S, Gangaputra S. Studies of the Ocular Complications of AIDS Research Group. Course of cytomegalovirus retinitis in the era of highly active antiretroviral therapy: five-year outcomes. *Ophthalmology* 2010;117:2152-61.e1, 2. doi:10.1016/j.ophtha.2010.03.031 pmid:20673591.
- 21 Cochereau I, Diraison MC, Mousalatti H, et al. [High-dose intravitreal ganciclovir in CMV retinitis]. *J Fr Ophthalmol* 2000;23:123-6. pmid:10705113.
- 22 Stewart MW. Optimal management of cytomegalovirus retinitis in patients with AIDS. *Clin Ophthalmol* 2010;4:285-99. doi:10.2147/OPTH.S6700 pmid:20463796.
- 23 Martin DF, Kuppermann BD, Wolitz RA, Palestine AG, Li H, Robinson CA. Roche Ganciclovir Study Group. Oral ganciclovir for patients with cytomegalovirus retinitis treated with a ganciclovir implant. *N Engl J Med* 1999;340:1063-70. doi:10.1056/NEJM199904083401402 pmid:10194235.
- 24 Musch DC, Martin DF, Gordon JF, Davis MD, Kuppermann BD. The Ganciclovir Implant Study Group. Treatment of cytomegalovirus retinitis with a sustained-release ganciclovir implant. *N Engl J Med* 1997;337:83-90. doi:10.1056/NEJM199707103370203 pmid:9211677.
- 25 Jabs DA, Ahuja A, Van Natta M, Dunn JP, Yeh S. Studies of the Ocular Complications of AIDS Research Group. Comparison of treatment regimens for cytomegalovirus retinitis in patients with AIDS in the era of highly active antiretroviral therapy. *Ophthalmology* 2013;120:1262-70. doi:10.1016/j.ophtha.2012.11.023 pmid:23419804.
- 26 Jabs DA. Cytomegalovirus retinitis and the acquired immunodeficiency syndrome—bench to bedside: LXVII Edward Jackson memorial lecture. *Am J Ophthalmol* 2011;151:198-216.e1, e1. doi:10.1016/j.ajo.2010.10.018 pmid:21168815.
- 27 Pertel P, Hirschtick R, Phair J, Chmiel J, Poggensee L, Murphy R. Risk of developing cytomegalovirus retinitis in persons infected with the human immunodeficiency virus. *J Acquir Immune Defic Syndr* 1992;5:1069-74. pmid:1357151.
- 28 Jabs DA, Van Natta ML, Thorne JE, et al. Studies of Ocular Complications of AIDS Research Group. Course of cytomegalovirus retinitis in the era of highly active antiretroviral therapy: 1. Retinitis progression. *Ophthalmology* 2004;111:2224-31. doi:10.1016/j.ophtha.2004.05.031 pmid:15582078.

Published by the BMJ Publishing Group Limited. For permission to use (where not already granted under a licence) please go to <http://group.bmj.com/group/rights-licensing/permissions>