

Washington University School of Medicine Digital Commons@Becker

Open Access Publications

2015

Combined epiretinal and internal limiting membrane peeling facilitated by high dilution indocyanine green negative staining

Mark M. Kaehr

Washington University School of Medicine

Rajendra S. Apte

Washington University School of Medicine

Follow this and additional works at: http://digitalcommons.wustl.edu/open_access_pubs

Recommended Citation

Kaehr, Mark M. and Apte, Rajendra S., "Combined epiretinal and internal limiting membrane peeling facilitated by high dilution indocyanine green negative staining." *Journal of Ophthalmic and Vision Research*.10,4. . (2015).
http://digitalcommons.wustl.edu/open_access_pubs/4862

This Open Access Publication is brought to you for free and open access by Digital Commons@Becker. It has been accepted for inclusion in Open Access Publications by an authorized administrator of Digital Commons@Becker. For more information, please contact engeszer@wustl.edu.

Surgical Technique

Combined Epiretinal and Internal Limiting Membrane Peeling Facilitated by High Dilution Indocyanine Green Negative Staining

Mark M. Kaehr, MD; Rajendra S. Apte, MD, PhD

Department of Ophthalmology and Visual Sciences, Washington University School of Medicine, St. Louis, MO, USA

Abstract

We describe the utilization of indocyanine green (ICG) dye to facilitate combined/en bloc removal of epiretinal membranes (ERM) along with internal limiting membranes (ILM). The method utilizes a highly diluted preparation of ICG in dextrose water solvent (D5W). Elimination of fluid air exchange step facilitating staining in the fluid phase and low intensity lighting help minimize potential ICG toxicity. The technique demonstrates how ICG facilitates negative staining of ERMs and how ILM peeling concomitantly can allow complete and efficient ERM removal minimizing surgical time and the necessity for dual or sequential staining.

Keywords: Indocyanine Green; Epiretinal Membrane; Membrane Peel; Chromodissection

J Ophthalmic Vis Res 2015; 10 (4): 495-497.

INTRODUCTION

Epiretinal membranes (ERM) represent a cellular proliferation on the inner retinal surface. Population studies have revealed the prevalence of the condition to be as high as 11% in elderly patients,^[1] and perioperative evaluations have demonstrated improved visual function and visual symptoms following membrane peels.^[2] As such, ERMs represent a common and important yet correctable source of visual morbidity.

Despite the lack of randomized controlled trial data, there is some evidence indicating that internal limiting

membrane (ILM) peeling may be beneficial in reducing the recurrence of epiretinal membranes.^[3] Benefits to ILM peeling have been suggested in other disease processes frequently presenting concomitantly with ERM such as macular hole and diabetic macular edema.^[4,5]

Although indocyanine green (ICG) readily stains the ILM, it only faintly stains ERMs. Herein, we describe a negative staining technique using highly diluted ICG to facilitate demarcation and removal of epiretinal membranes concomitant with internal limiting membrane peel.

SURGICAL TECHNIQUE

Preoperatively, informed consent is obtained. In the operating suite, the eye is prepped and draped in the usual fashion. A 3-port, 23 gauge vitrectomy is first performed utilizing a one-step trocar/cannula system with wide-angled BIOM viewing system. After core vitrectomy, care is taken to ensure the posterior

Correspondence to:

Rajendra S. Apte, MD, PhD. Washington University School of Medicine, 660 South Euclid Venue, Box 8096, St. Louis, MO 63110, USA.

E-mail: apte@vision.wustl.edu

Received: 03-08-2015

Accepted: 01-09-2015

Video Available on: www.jovr.org

Access this article online

Quick Response Code:



Website:
www.jovr.org

DOI:
10.4103/2008-322X.176898

This is an open access article distributed under the terms of the Creative Commons Attribution-NonCommercial-ShareAlike 3.0 License, which allows others to remix, tweak, and build upon the work non-commercially, as long as the author is credited and the new creations are licensed under the identical terms.

For reprints contact: reprints@medknow.com

How to cite this article: Kaehr MM, Apte RS. Combined epiretinal and internal limiting membrane peeling facilitated by high dilution indocyanine green negative staining. *J Ophthalmic Vis Res* 2015;10:495-7.

hyaloid is lifted, and a complete vitrectomy has been performed.

Once the vitrectomy is complete, ICG is applied. The light pipe setting is reduced to approximately 25% of normal illumination to minimize the risk of phototoxicity. The ICG is mixed as per the bottle instructions with sterile water. Subsequently, the ICG solution is then diluted in a 1:24 ratio with dextrose 5% in water (D5W). The added dextrose solution allows the 'relatively heavier' ICG solution to gently gravitate to the macula and stain the ILM without the need for an air-fluid exchange. Use of valved cannulas further facilitates this step. The solution is applied using a 23 gauge blunt cannula. Once ICG covers the epimacular surface, it is allowed to sit for 30 seconds. While the ICG is resting on the retinal surface, care is taken to avoid removing the cannula or rotating the globe so that the ICG stays in place undisturbed. After the 30 second time period, the vitrector is reintroduced and used to aspirate any residual ICG. The aspiration process is continued for several seconds after all visible ICG has been removed to ensure that indiscernible traces of the dye have been thoroughly cleared.

Subsequent inspection of the retinal surface reveals a pattern of ILM staining surrounding the area of epiretinal membrane which is negative stained [Figure 1]. Next, a macular contact lens is placed and 23 gauge disposable forceps are used to initiate an ILM flap outside of the ERM using a pinch and peel technique [Figure 2]. This flap is subsequently enlarged to the appropriate diameter for a complete peel. Once a large enough flap is constructed, the flap is then advanced toward the ERM [Figure 3]. This effectively allows the removal of the ILM and ERM en bloc [Figure 4]. This technique bypasses the need for sequential or dual staining as well as the number of contact sites required between the tip of the forceps and the retinal surface.

Following the peel, the periphery is inspected with scleral depression. A partial air fluid exchange is performed, and sutureless closure of the scleral wounds is achieved [Video 1].

DISCUSSION

Epiretinal membranes are a common ocular finding^[1] and a correctable source of visual morbidity.^[2] ILM peeling has been shown to possibly decrease the rate of epiretinal membrane recurrence^[3] and has also been shown to be beneficial in epiretinal membranes presenting with concomitant pathologies such as diabetic macular edema and macular hole.^[4,5]

ICG has previously been shown to facilitate peeling of the ILM and ERM either individually or together.^[6] However, concerns have been raised over the potential toxicity of ICG.^[7] By utilizing the technique described herein, we have not encountered any case of toxicity. Since ICG mixed with D5W can easily stain the ILM

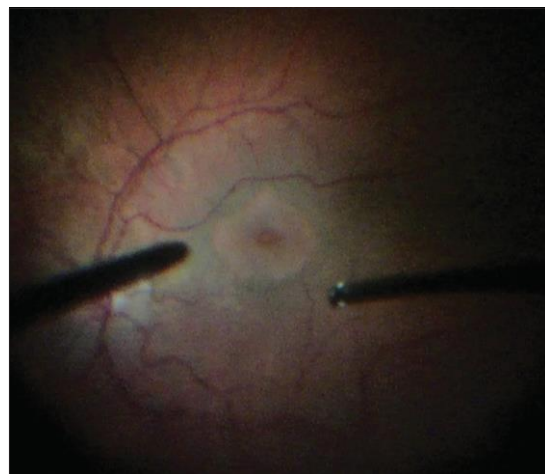


Figure 1. ICG staining of ILM and negative staining of the ERM.

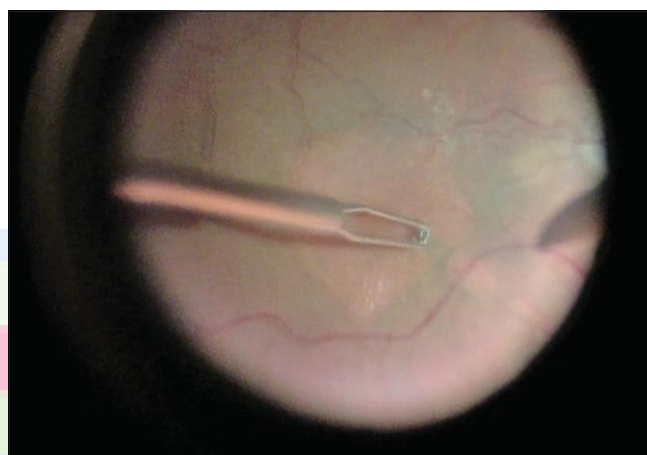


Figure 2. Initiation of an ILM flap outside of the ERM using a pinch and peel technique.

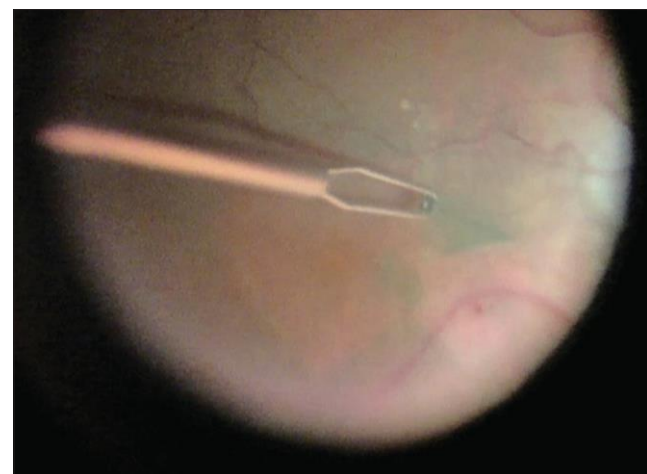


Figure 3. Advancement of the flap towards the ERM.

in a fluid filled eye, there is no need for an air fluid exchange that could lead to a higher concentration of dye at the retinal surface. Additionally, decreasing the light intensity of the endoprobe during staining and

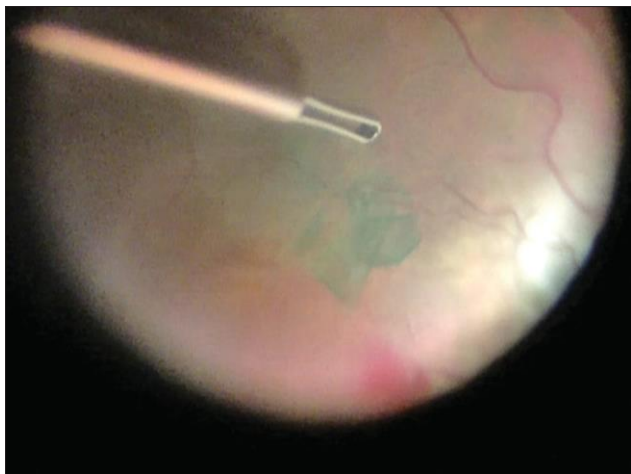


Figure 4. Completion of en bloc removal of both the ILM and ERM.

meticulous aspiration of the dye after staining further enhance the safety of this technique.

The use of ICG for staining the ILM and negative staining of epiretinal membranes has been described previously.^[8] However, in that study, the ERM and ILM were removed separately. Herein, we present a technique for planned en bloc removal of the ERM and ILM. This technique carries several advantages. Firstly, utilizing negative staining obviates the need for multiple staining agents or repeat staining for the ERM and ILM separately. Additionally, the en bloc technique decreases overall operative time by removing the ILM concomitantly with the ERM. Furthermore, the en bloc technique helps ensure that the entirety of the epiretinal membrane has been removed.

In summary, ICG negative staining safely facilitates combined peeling of ERM and ILM allowing complete

and efficient surgical treatment of this common retinal pathology.

Financial Support and Sponsorship

Nil.

Conflicts of Interest

There are no conflicts of interest.

REFERENCES

1. Mitchell P, Smith W, Chey T, Wang JJ, Chang A. Prevalence and associations of epiretinal membranes. The Blue Mountains Eye Study, Australia. *Ophthalmology* 1997;104:1033-1040.
2. Ghazi-Nouri SM, Tranos PG, Rubin GS, Adams ZC, Charteris DG. Visual function and quality of life following vitrectomy and epiretinal membrane peel surgery. *Br J Ophthalmol* 2006;90:559-562.
3. Kwok AK, Lai TY, Yuen KS. Epiretinal membrane surgery with or without internal limiting membrane peeling. *Clin Experiment Ophthalmol* 2005;33:379-385.
4. Stolba U, Binder S, Gruber D, Krebs I, Aggermann T, Neumaier B. Vitrectomy for persistent diffuse diabetic macular edema. *Am J Ophthalmol* 2005;140:295-301.
5. Ando F, Sasano K, Ohba N, Hirose H, Yasui O. Anatomic and visual outcomes after indocyanine green-assisted peeling of the retinal internal limiting membrane in idiopathic macular hole surgery. *Am J Ophthalmol* 2004;137:609-614.
6. Da Mata AP, Burk SE, Riemann CD, Rosa RH Jr., Snyder ME, Petersen MR, et al. Indocyanine green-assisted peeling of the retinal internal limiting membrane during vitrectomy surgery for macular hole repair. *Ophthalmology* 2001;108:1187-1192.
7. Engelbrecht NE, Freeman J, Sternberg P Jr., Aaberg TM Sr., Aaberg TM Jr., Martin DF, et al. Retinal pigment epithelial changes after macular hole surgery with indocyanine green-assisted internal limiting membrane peeling. *Am J Ophthalmol* 2002;133:89-94.
8. Foster RE, Petersen MR, Da Mata AP, Burk SE, Rosa RH Jr., Riemann CD. Negative indocyanine green staining of epiretinal membranes. *Retina* 2002;22:106-108.