

Washington University School of Medicine Digital Commons@Becker

Open Access Publications

2001

Laparoscopic repair of diaphragmatic defect by total intracorporeal suturing: Clinical and technical considerations

Jamil Rehman

Washington University School of Medicine in St. Louis

Jaime Landman

Washington University School of Medicine in St. Louis

Kurt Kerbl

Washington University School of Medicine in St. Louis

Ralph V. Clayman

Washington University School of Medicine in St. Louis

Follow this and additional works at: http://digitalcommons.wustl.edu/open_access_pubs

Recommended Citation

Rehman, Jamil; Landman, Jaime; Kerbl, Kurt; and Clayman, Ralph V., "Laparoscopic repair of diaphragmatic defect by total intracorporeal suturing: Clinical and technical considerations." *Journal of the Society of Laparoendoscopic Surgeons*.5,3. 287-291. (2001).

http://digitalcommons.wustl.edu/open_access_pubs/3379

This Open Access Publication is brought to you for free and open access by Digital Commons@Becker. It has been accepted for inclusion in Open Access Publications by an authorized administrator of Digital Commons@Becker. For more information, please contact engeszer@wustl.edu.

Laparoscopic Repair of Diaphragmatic Defect By Total Intracorporeal Suturing: Clinical and Technical Considerations

Jamil Rehman, MD, Jaime Landman, MD, Kurt Kerbl, MD, Ralph V. Clayman, MD

ABSTRACT

Objective: The use of laparoscopy in urology is increasing. Tumor of the kidney or adrenal gland and, in some cases, metastatic disease can involve the diaphragm. We describe the application of laparoscopic suturing techniques in the case of diaphragmatic involvement with a renal tumor.

Methods: After resection of the tumor and a small area of the diaphragm, a chest tube was placed under laparoscopic guidance. The tube was kept clamped until the end of the procedure. Decreasing intraabdominal pneumoperitoneum pressure made suturing easier with less tension on the edges of the diaphragmatic incision. Nonabsorbable interrupted horizontal mattress sutures were placed to close the diaphragmatic defect.

Results: The repair was uneventful; no intraoperative complications occurred. Extubation was done at the end of the procedure in the operating room. The chest tube was removed on postoperative day 2, and the patient was discharged on postoperative day 3.

Conclusions: Laparoscopic repair of the diaphragm should be commensurate with traditional open surgical principles. In this regard, it is essential that surgeons interested in performing "advanced" laparoscopic oncologic surgery become facile in laparoscopic suturing.

Key Words: Diaphragm resection, Diaphragm repair, Intracorporeal suturing, Laparoscopic nephrectomy.

INTRODUCTION

Tumors of the kidney and adrenal gland rarely involve the diaphragm; however, when this does occur, en bloc resection including partial excision of the diaphragm is needed. In the current environment, laparoscopic surgery has come to play a larger role in the removal of renal and adrenal tumors. To date, only 1 urological case has involved repair of a laparoscopic diaphragmatic injury (Kavoussi LR, personal communication), and no reports exist of intended resection of part of the diaphragm using laparoscopic techniques.

The initial investigation evaluating the role of minimally invasive surgery via thoracoscopy in the management of diaphragm injuries has been reported by Jackson and Ferreira.¹ Adamthwaite^{2,3} was the first to recommend laparoscopy for dealing with traumatic injuries of the diaphragm. Since then, several authors have advocated the use of laparoscopy⁴⁻¹³ or thoracoscopy¹⁴⁻¹⁸ for the diagnosis and repair of diaphragmatic defects or injuries. With broadening and honing of laparoscopic skills, acute incarcerated diaphragmatic hernias have now also been repaired¹⁹ laparoscopically. According to the pediatric surgical literature,²⁰ laparoscopic diaphragmatic plication is now accepted treatment for congenital diaphragmatic eventration.

MATERIAL AND METHODS

Illustrative Case

A 57-year-old woman was seen because of painless hematuria. A CT scan showed a 3.9 x 3-cm mass involving the upper and midportion of the right kidney and extending medially to the area of the main renal vein (**Figure 1**). The right kidney (8 cm) was markedly smaller than the left (11.6 cm), and a renal scan showed only 34% function coming from the right side. Significant in her past medical history was total abdominal hysterectomy and bilateral salpingo-oophorectomy followed by chemotherapy for ovarian cancer in 1991 (Stage 2 C). In 1992, she had a second look procedure followed by intraperitoneal P-32 (prophylactic). In 1993, she had a recurrence in Morison's pouch, which was treated with chemotherapy. She had another recurrence in Morison's

Department of Surgery, Division of Urology, Washington University School of Medicine, St. Louis, Missouri, USA (all authors).

Department of Radiology (Mallinckrodt Institute of Radiology), Washington University School of Medicine, St. Louis, Missouri, USA (Dr Clayman).

Address reprint requests to: Ralph V. Clayman, MD, Professor of Urology and Radiology, Washington University Medical Center, Division of Urologic Surgery, 4960 Children's Place, St. Louis, MO 63110, USA. Telephone: (314) 454-8775, Fax: (314) 454-5396, E-mail: claymanr@compuserve.com

© 2001 by JSL, *Journal of the Society of Laparoendoscopic Surgeons*. Published by the Society of Laparoendoscopic Surgeons, Inc.

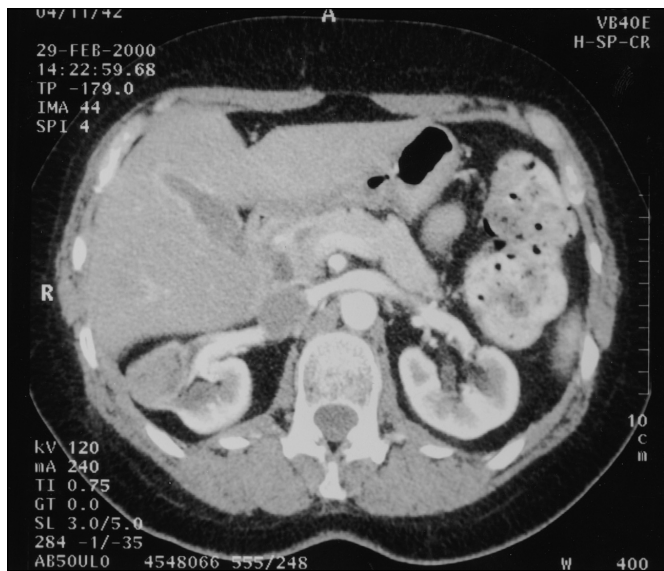

Figure 1. CT scan showing the tumor involving the diaphragm.

pouch in 1994, which was treated with high-dose chemotherapy followed by bone marrow stem cell transplantation. She also received 3-D radiotherapy (5940 cGy over 6 weeks) to Morison's pouch. In 1999, the patient was evaluated for hematuria, and a right renal mass was discovered consistent with a renal cell carcinoma. Metastatic evaluation at this time was negative. Her serum creatinine ranged from 1.3-1.5 mg/dL. Her only other health problem was a history of asthma.

Surgical Technique

After general endotracheal anesthesia, a nasogastric tube and Foley catheter were placed. A Veress needle pneumoperitoneum was achieved via a 12-mm incision off of the iliac crest. With the patient in a lateral decubitus position, 3 ports were placed: a 12-mm port off the iliac crest in the midclavicular line, a 12-mm port approximately 4 cm above the umbilicus in the pararectus line, and a 12-mm port subcostal in the midclavicular line. Dense adhesions were encountered; an extensive adhesiolysis was performed. In particular, the liver edge was adherent to Gerota's fascia, likely a result of the patient's prior radiation therapy.

The line of Toldt was incised, as was the hepatic triangular ligament. The colon was mobilized medially, and a Kocher maneuver was done on the duodenum. The renal

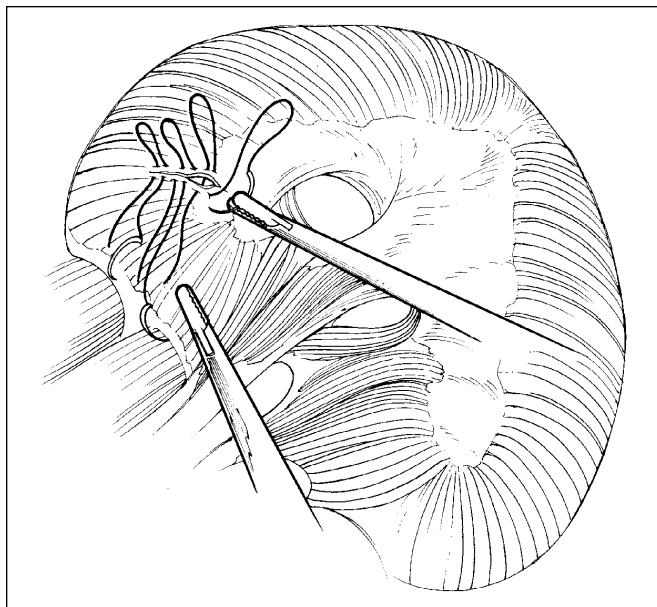


Figure 2. Surgical technique of laparoscopic closure of diaphragm.

hilum was dissected; the artery was secured with 5 clips, and cut. The renal vein was then carefully dissected and secured with the Endo-GIA stapler. The specimen appeared to be adherent to the diaphragm, and no clear plane of dissection existed. As such, the involved portion of the posterior diaphragm was resected along with the tumor. A chest tube (20 F) was placed at what appeared to be the 6th intercostal space, under laparoscopic guidance; this was affixed to the skin and kept clamped until the end of the procedure. The diaphragm was repaired with interrupted 0 silk sutures: 2 simple and 3 horizontal mattress sutures; the sutures were tied intracorporeally with the knots on the abdominal side of the diaphragm (**Figure 2**). During this portion of the procedure, the pneumoperitoneum was reduced to 10 mm Hg to facilitate reapproximation of the edges of the diaphragm. The tail of the previously placed suture was used as a handle to aid accurate placement of the next suture. After complete mobilization of the specimen, the ureter was taken between pairs of clips and was then placed in an Endo-Catch (United States Surgical, Corp., Norwalk, CT). The lowermost incision was extended to approximately 7 cm, and the specimen was removed intact. The intraabdominal pressure was reduced to 5 mm Hg, and hemostasis was obtained. The 12-mm port sites were closed with the

aid of the Carter-Thomson device (Inlet Medical, Inc., Prairie Eden, MN) under laparoscopic visualization. No intraoperative complications occurred. The patient was extubated in the operating room.

Postoperative Course

The chest tube was removed on postoperative day 2. A regular diet was instituted on postoperative day 2. The patient was discharged on postoperative day 3. The pathology showed poorly differentiated adenocarcinoma with sheets of necrosis. The tumor involved the renal cortex and renal medulla and distorted the renal pelvis, but no perirenal fat was involved. All resection margins were clear. The tumor was felt to represent metastatic ovarian cancer.

DISCUSSION

Laparoscopic surgery offers the advantages of minimally invasive access for treating a wide range of renal diseases. As laparoscopic skills and experience increase, more difficult and larger renal tumors are being approached. For the upper pole complex renal mass, the laparoscopic approach offers several obvious benefits over a standard thoraco-abdominal incision.^{21,22} However, for these tumors, the surgeon needs to be able to effectively reconstruct the diaphragm.

Once the diaphragm has been opened, rhythmic contractions of the diaphragm may cause further diastasis; in addition, once an opening in the diaphragm occurs, a natural tendency exists for the intraabdominal contents to migrate through the opening. Also, the pressure of the pneumoperitoneum can result in a tension pneumothorax, making ventilation of the patient more difficult. Lastly, upon closure of the diaphragm, as much as a 100 cm H₂O pleuroperitoneal pressure gradient (during deep inspiration) may occur, which may pull apart a diaphragmatic repair and thereby force intraabdominal contents into the chest.²³

Accordingly, during laparoscopic repair of a diaphragmatic injury, it is helpful to keep the pneumoperitoneum pressure at 10 mm Hg. This facilitates ventilation of the patient and the creation of a tension-free closure. Immediately prior to the repair, the surgeon needs to decide whether to place a chest tube. If the opening in the diaphragm is small, the surgeon may elect to not place a chest tube. In this circumstance, a 24 F red rubber catheter can be placed through 1 of the ports and

passed across the final diaphragmatic mattress suture into the chest. Air and fluid are then withdrawn under suction. With the lungs held in full inspiration, the catheter is extracted while the final mattress suture is tied. In this case, a postoperative chest radiograph is obtained; tube thoracostomy may be necessary if a > 20% residual pneumothorax exists. On the other hand, if a chest tube is to be placed, then the 30-degree laparoscopic lens is helpful, because it can be passed through the opening in the diaphragm and the chest tube can be placed under endoscopic guidance, properly positioned, secured to the skin, and clamped.

The diaphragmatic defect is usually closed using interrupted figure-of-eight or horizontal mattress sutures of 2-0 nonabsorbable suture material (eg, polypropylene or silk).²⁴⁻²⁷ Teflon pledgets are occasionally used when the diaphragm is attenuated or if the closure is tenuous. Other techniques include placing 2 rows of nonabsorbable sutures²⁸ or using absorbable materials placed in an interrupted or continuous technique.²⁹ Some authors recommend a 2-layer closure for defects greater than 2 cm. The inner layer is composed of an interlocking horizontal mattress (nonabsorbable) that everts the edges. This is then reinforced with a running 3-0 polypropylene or similar type of nonabsorbable suture. Endoscopic approximation of the diaphragmatic defect edges has also been performed using a hernia stapler.^{16,30} The purpose is to attain a firm closure while being careful not to injure the phrenic nerve (**Table 1**).²⁹

Intracorporeal suturing is cumbersome and by far the rate-limiting factor in reconstructive laparoscopic surgery.³¹⁻³³ A profound interest has developed, therefore, in the improvement of instrumentation to facilitate laparoscopic suturing and tissue apposition. Several new instruments have been designed for laparoscopic reconstructive surgery. The Endo Stitch semiautomated suturing device (United States Surgical Corp., Norwalk, CT) and the suture-assist device (Ethicon Endo-Surgery, Cincinnati, OH) have been developed to address these issues.³² Ethicon has introduced another device called suture-assist, which also makes intracorporeal suturing easier. However, both of these aids involve straight rather than curved needles, which may limit their application. Another aid, the absorbable Lapra-Ty clip (Ethicon Endo-Surgery, Cincinnati, OH) allows fixation of a suture without requiring a knot to be tied, thus speeding laparoscopic suturing; however, this clip is approved only for use on absorbable suture material. Because of these lim-

Table 1.
Principles/Techniques Recommended.

Stage	Recommendation
Preplanning	A double-lumen endotracheal tube allows optimum ventilation and exposure if a large portion of the diaphragm needs to be resected. Patients, undergoing laparoscopy for large upper pole renal or large adrenal cancers should have their chest prepared and draped and the necessary instruments and chest tubes available. A 30-degree laparoscope is extremely useful in visualizing the subdiaphragmatic area on both the right and left sides of the abdomen, and facilitates visualization of the superior portions of the spleen and liver.
Chest tube placement	If a chest tube is required, it needs to be placed prior to undertaking closure of the diaphragm. For small defects, the chest tube can be eliminated, and the chest cavity can be evacuated via a transdiaphragmatic 24F catheter, prior to tying the last diaphragmatic suture.
Laparoscopic Access for Diaphragm Repair	A decrease in abdominal pressure to 10 mm Hg may facilitate suturing and ventilation of the patient. Initially, a stay suture can be placed at the lateral edge of the incision to help pull the diaphragm towards the operator. The tail of the previously placed suture is used as a handle to provide traction, thereby permitting careful suture placement.
Suture for diaphragmatic repair	2-0, nonabsorbable suture is the consensus.
Suturing techniques of the diaphragm	Figure-of-eight or horizontal mattress. No tension should be allowed on the line of closure. If it appears that closure will result in some tension, then pledgets are placed to prevent tearing of the diaphragmatic muscle. If the defect is very large a 2-layer closure is done. The inner layer is an interlocking horizontal mattress that evens the edges. This is reinforced with a running 3-0 suture. Larger defects require placement of a PTFE patch, which is affixed with 2-0 nonabsorbable sutures.

itations and due to the high cost of these disposable products, laparoscopic surgeons interested in expanding into other more difficult procedures need to be skilled in intracorporeal free-hand laparoscopic suturing and knot tying.

When the defect is too large to reapproximate primarily, then it can be closed by placement of allogenic material (eg, polytetrafluoroethylene (PTFE), fluorinated polyester (FP), and a Gore-Tex graft or polypropylene mesh). PTFE is the most commonly used material in pediatric and adult surgery due to concern over the possible erosion of any mesh material into adjacent structures, such as the esophagus.¹¹

References:

- Jackson AM, Ferreira AA. Thoracoscopy as an aid to the diagnosis of diaphragmatic injury in penetrating wounds of the left lower chest: a preliminary report. *Injury*. 1976;7:213-217.
- Adamthwaite DN. Traumatic diaphragmatic hernia: a new indication for laparoscopy. *Br J Surg*. 1984;71:315.
- Adamthwaite DN. Penetrating injuries of the diaphragm. *Injury*. 1982;14:151-158.
- Layman TS, Barker DE, Burns RP. Laparoscopic evaluation of the diaphragm in penetrating injury to the lower thorax. *J Tenn Med Assoc*. 1992;85:471-474.
- Marks JM, Ramey RL, Baringer DC, Aszodi A, Ponsky JL. Laparoscopic repair of a diaphragmatic laceration. *Surg Laparosc Endosc*. 1995;5:415-418.
- Orita M, Okino M, Yamashita K, Morita N, Esato K. Laparoscopic repair of a diaphragmatic hernia through the foramen of Morgagni. *Surg Endosc*. 1997;11:668-670.
- Ortega AE, Tang E, Froes ET, Asensio JA, Katkhouda N, Demetriades D. Laparoscopic evaluation of penetrating thoracoabdominal traumatic injuries. *Surg Endosc*. 1996;10:19-22.
- Martin I, O'Rourke N, Gotley D, Smithers M. Laparoscopy in the management of diaphragmatic rupture due to blunt trauma. *Aust N Z J Surg*. 1998;68:584-586.

9. Lindsey I, Woods SD, Nottle PD. Laparoscopic management of blunt diaphragmatic injury. *Aust N Z J Surg.* 1997;67:619-621.
10. Kawahara N, Zantut LF, Poggetti RS, Fontes B, Bernini C, Birolini D. Laparoscopic treatment of gastric and diaphragmatic injury produced by thoracoabdominal stab wound. *J Trauma.* 1998;45:613-614.
11. Slim K, Bousquet J, Chipponi J. Laparoscopic repair of missed blunt diaphragmatic rupture using a prosthesis. *Surg Endosc.* 1998;12:1358-1360.
12. Torresini G, Sozio L, Crisci R, Amicucci G. Laparoscopic repair of diaphragmatic iatrogenic hernia. *Endoscopy.* 2000;32:52.
13. Pross M, Manger T, Mirow L, Wolff S, Lippert H. Laparoscopic management of a late-diagnosed major diaphragmatic rupture. *J Laparoendosc Adv Surg Tech A.* 2000;10:111-114.
14. Koehler RH, Smith RS. Thoracoscopic repair of missed diaphragmatic injury in penetrating trauma: case report [see comments]. *J Trauma.* 1994;36:424-427.
15. Spann JC, Nwariaku FE, Wait M. Evaluation of video-assisted thoracoscopic surgery in the diagnosis of diaphragmatic injuries. *Am J Surg.* 1995;170:628-630; discussion 630-631.
16. Kurata K, Kubota K, Oosawa H, Eda N, Ishihara T. Thoracoscopic repair of traumatic diaphragmatic rupture. A case report. *Surg Endosc.* 1996;10:850-851.
17. Mouroux J, Padovani B, Poirier NC, et al. Technique for the repair of diaphragmatic eventration. *Ann Thorac Surg.* 1996;62:905-907.
18. Guy TS, Montany PF. Thoracoscopic diaphragmatic plication. *Surg Laparosc Endosc.* 1998;8:319-321.
19. Ugazzi M, Chiriboga A. Laparoscopic treatment of incarcerated posttraumatic diaphragmatic hernia. *J Laparoendosc Surg.* 1996;6 Suppl 1:S83-S88.
20. Kizilcan F, Tanyel FC, Hicsonmez A, Buyukpamukcu N. The long-term results of diaphragmatic plication. *J Pediatr Surg.* 1993;28:42-44.
21. Clark RH, Hardin WD, Jr, Hirschl RB, et al. Current surgical management of congenital diaphragmatic hernia: a report from the Congenital Diaphragmatic Hernia Study Group. *J Pediatr Surg.* 1998;33:1004-1009.
22. Wilson JM, Lund DP, Lillehei CW, Vacanti JP. Congenital diaphragmatic hernia—a tale of two cities: the Boston experience. *J Pediatr Surg.* 1997;32:401-405.
23. Bautz PC, Knottenbelt JC. Diaphragmatic injury—a source of hazard in laparoscopy. *Injury.* 1994;25:401-402.
24. Brandt ML, Luks FI, Spigland NA, DiLorenzo M, Laberge JM, Ouimet A. Diaphragmatic injury in children. *J Trauma.* 1992;32:298-301.
25. Guth AA, Pachter HL, Kim U. Pitfalls in the diagnosis of blunt diaphragmatic injury. *Am J Surg.* 1995;170:5-9.
26. Holzberger P, Konigsrainer A, Tauscher T, Muller L, Thoni H. Indirect traumatic diaphragmatic rupture [in German]. *Wien Klin Wochenschr.* 1991;103:284-287.
27. Lee WC, Chen RJ, Fang JF, et al. Rupture of the diaphragm after blunt trauma. *Eur J Surg.* 1994;160:479-483.
28. van Vugt AB, Schoots FJ. Acute diaphragmatic rupture due to blunt trauma: a retrospective analysis. *J Trauma.* 1989;29:683-686.
29. Rosati C. Acute traumatic injury of the diaphragm. *Chest Surg Clin N Am.* 1998;8:371-379.
30. Bortul M, Calligaris L, Gheller P. Laparoscopic repair of a Morgagni-Larrey hernia. *J Laparoendosc Adv Surg Tech A.* 1998;8:309-313.
31. Moore RG, Averch TD, Schulam PG, Adams JB II, Chen RN, Kavoussi LR. Laparoscopic pyeloplasty: experience with the initial 30 cases. *J Urol.* 1997;157:459-462.
32. Adams JB, Schulam PG, Moore RG, Partin AW, Kavoussi LR. New laparoscopic suturing device: initial clinical experience. *Urology.* 1995;46:242-245.
33. Eden CG, Coptcoat MJ. Assessment of alternative tissue approximation techniques for laparoscopy. *Br J Urol.* 1996;78:234-242.