

Washington University School of Medicine Digital Commons@Becker

Open Access Publications

2005

Determination of cell viability after laparoscopic tissue stapling in a porcine model

Ramakrishna Venkatesh

Washington University School of Medicine in St. Louis

Jamil Rehman

SUNY Stony Brook

Jaime Landman

Washington University School of Medicine in St. Louis

David Lee

University of California - Irvine

Maged E. Ragab

Washington University School of Medicine in St. Louis

See next page for additional authors

Follow this and additional works at: http://digitalcommons.wustl.edu/open_access_pubs

Recommended Citation

Venkatesh, Ramakrishna; Rehman, Jamil; Landman, Jaime; Lee, David; Ragab, Maged E.; Sundaram, Chandru P.; Humphrey, Peter A.; and Clayman, Ralph V., "Determination of cell viability after laparoscopic tissue stapling in a porcine model." *Journal of Endourology*.19,6. 744-747. (2005).
http://digitalcommons.wustl.edu/open_access_pubs/3121

This Open Access Publication is brought to you for free and open access by Digital Commons@Becker. It has been accepted for inclusion in Open Access Publications by an authorized administrator of Digital Commons@Becker. For more information, please contact engeszer@wustl.edu.

Authors

Ramakrishna Venkatesh, Jamil Rehman, Jaime Landman, David Lee, Maged E. Ragab, Chandru P. Sundaram, Peter A. Humphrey, and Ralph V. Clayman

Determination of Cell Viability after Laparoscopic Tissue Stapling in a Porcine Model

RAMAKRISHNA VENKATESH, M.D.,¹ JAMIL REHMAN, M.D.,² JAIME LANDMAN, M.D.,¹
DAVID LEE, M.D.,³ MAGED E. RAGAB, M.D.,¹ CHANDRU P. SUNDARAM, M.D.,⁴
PETER A. HUMPHREY, M.D.,⁵ and RALPH V. CLAYMAN, M.D.³

ABSTRACT

Background and Purpose: Surgical stapling devices are often used to secure the distal ureter along with a cuff of bladder during laparoscopic nephroureterectomy. As the viability of cells within the stapled tissue would be important in patients with upper urinary-tract transitional-cell carcinoma, we determined the viability of cells within the lines of various commercially available staplers in a porcine model.

Materials and Methods: Four laparoscopic stapling devices were used: two vascular and two tissue designs (US Surgical, Norwalk, CT, and Ethicon, Cincinnati, OH). The devices were deployed across a portion of the bladder, much as they would be during a nephroureterectomy to create a bladder cuff while excising the distal ureter. The animals were sacrificed 6 weeks later, and the stapled sites were harvested for histopathologic examination by an experienced genitourinary pathologist (PH).

Results: Grossly, there were no visible staples at harvest of the stapled bladder and the ureterovesical junction, with a completely healed bladder being seen in all four animals. On histologic examination with hematoxylin and eosin staining, there were distinctly viable cells within the staple lines of the ureterovesical junction and the bladder wall, similar to the unstapled control tissue. There were viable cells in all samples of tissues stapled by either vascular or tissue staplers.

Conclusions: Deployment of both vascular and tissue staplers resulted in viable cells within the staple lines at the ureterovesical junction and bladder wall in this porcine model. There is a potential risk of tumor recurrence at the stapled site in patients who have the ureter and bladder cuff secured with these devices during laparoscopic nephroureterectomy for upper-tract transitional-cell carcinoma. Despite this concern, to date, over a period of 13 years, clinical experience has not revealed a single case of tumor recurrence within the stapled cuff of bladder. Careful endoscopic evaluation of the stapled bladder-cuff site after laparoscopic nephroureterectomy should minimize the potential for local tumor recurrence.

INTRODUCTION

LAPAROSCOPIC NEPHROURETERECTOMY performed with or without the aid of a hand-assist device has become a standard of treatment for transitional-cell carcinoma (TCC) of the upper urinary tract. During laparoscopic nephroureterectomy, removal of the kidney is similar to the well-established and rather straightforward technique of radical or total nephrec-

tomy for renal-cell carcinoma or benign kidney disease. However, myriad methods have been designed for removal of the distal ureter with a cuff of bladder. Currently, we employ the Washington University technique of stapling the distal ureter and bladder cuff with subsequent cystoscopic unroofing of the ipsilateral ureter with fulguration of the local tissue to the level of the staple line; this invariably follows the nephrectomy portion of the procedure.¹

¹Department of Surgery, Division of Urologic Surgery, Washington University School of Medicine, St. Louis, Missouri.

²Department of Urology, School of Medicine, SUNY-Stony Brook Health Sciences Center, Stony Brook, New York.

³Department of Urology, University of California-Irvine, Orange, California.

⁴Department of Urology, Indiana University School of Medicine, Indianapolis, Indiana.

⁵Department of Pathology, Washington University School of Medicine.

The question has been asked whether the cells within the staple line remain viable such that a local recurrence within the stapled cuff of bladder could occur. To answer this question, we determined the viability of the cells within the tissues secured by the stapler using a porcine model.

MATERIALS AND METHODS

Four commonly used laparoscopic tissue and vascular staplers made by two manufacturers (US Surgical, Norwalk, CT, and Ethicon, Cincinnati, OH) were evaluated. In four domestic pigs, the kidney and the ureter were mobilized laparoscopically, and the distal ureter and bladder cuff were transected with one of the stapling devices.

Under general anesthesia, the pigs were placed in the flank position in a 30° Trendelenburg position, and pneumoperitoneum was achieved with a Veress needle via an infraumbilical incision. A 12-mm umbilical trocar was placed, and two additional 12-mm laparoscopic trocars were inserted under laparoscopic vision lateral to the rectus muscle above and below the level of the umbilicus to allow renal and ureteral mobilization. The renal hilum was dissected, and the renal vessels were secured with vascular clips and divided. The ureter was dissected down to the bladder. The ipsilateral ureterovesical junction and the surrounding bladder was dissected and mobilized. The ureterovesical junction with the surrounding cuff of bladder was stapled with one of the devices. The bladder was also stapled at three additional sites: across the dome and across the left and the right lateral walls. The stapler places six rows of staples and simultaneously incises the tissue between the third and fourth rows. As such, for each application of a vascular or tissue stapler, there were two specimens, each with three rows of staples. The stapled line for the Ethicon vascular or tissue stapler was 35 mm and that for the US Surgical vascular or tissue stapler was 32.5 mm. Each single metal vascular staple, both Ethicon and US Surgical, when it is open has a 3-mm base and 2.5 mm of leg length and on firing has a 3-mm base and a leg length of 1 mm. A single metal tissue staple (Ethicon or US Surgical) has a 3-mm base and a leg length of 3.5 mm and on firing has a 3-mm base and a leg length of 1.5 mm. The kidney and the ureter were retrieved through an extended incision at the umbilical trocar site. The bladder was filled with saline solution through the Foley catheter and visually assessed laparoscopically for any leakage at the stapled sites.

Six weeks later, the animals underwent laparotomy and harvesting of the stapled ureterovesical junction and the bladder wall sites. Also, normal full-thickness bladder wall was harvested as a control. The specimens were preserved in 10% Formalin solution for histopathologic examination following hematoxylin and eosin (H&E) staining.

The harvested tissues with the staples *in situ* were sectioned using a unique Exakt cutting-grinding technique (Exakt Tech, Oklahoma City, OK) that employs a diamond-embedded cutting band to cut biomaterials embedded in tissues without structural distortion of the interface between the biomaterial and the tissue. The technique preserved the staples and the tissues within the staple lines for histologic staining and examination to evaluate the viability of the cells. The Formalin-preserved

tissue specimen was dehydrated with alcohol and infiltrated with a methylmethacrylate polymer embedding medium. The tissue block was phased and mounted on a slide, and the surface was ground using the Exakt cutting-grinding machine to obtain 200- to 250- μm sections. Further grinding was performed to achieve 5- to 15- μm tissue sections. The slide-mounted sections were polished and appropriately stained prior to microscopic evaluation by an experienced urologic pathologist (PH).

RESULTS

All procedures were completed laparoscopically. There were no complications secondary to stapling, such as urinary extravasation, stone formation, or abscess formation. At the time of tissue harvest, there were no exposed staples, as there had been complete epithelialization. On histologic examination, all tissue types, including the urothelium, ureteral and bladder smooth muscle-cell bundles, and stromal cells, were identified within and around the staples with minimal distortion of the tissues (Fig. 1) and were found to be normal. There were distinctly viable cells within the staple lines of the ureterovesical junction and the bladder wall (Fig. 2). Viable cells were noted in all the tissue samples stapled with either the vascular or the tissue staplers. The cells within the staple lines showed mainly normal nuclear and cytologic patterns similar to the control bladder-wall tissue. The staples were embedded in the bladder and the ureteral wall with viable cells within the closed loop of the staple and between individual staples. There was minimal fibrosis around the titanium staples (Fig. 3) with only an occasional foreign-body giant-cell reaction. There was no difference in the histologic appearance of the tissues within the staple lines of either the vascular or the tissue staplers.

DISCUSSION

Upper-tract TCC has historically been treated with nephroureterectomy because of the high incidence of ipsilateral multifocal disease and distal recurrence (up to 30%) and the low

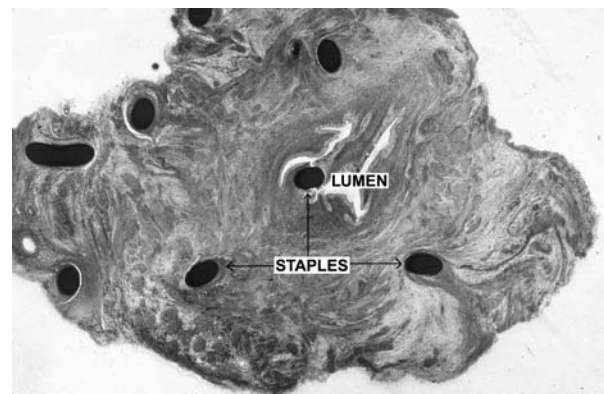


FIG. 1. Cross-section of ureter showing embedded metal staples *in situ* within wall with minimal distortion of adjacent muscle and urothelial and connective tissues. (H & E stain)

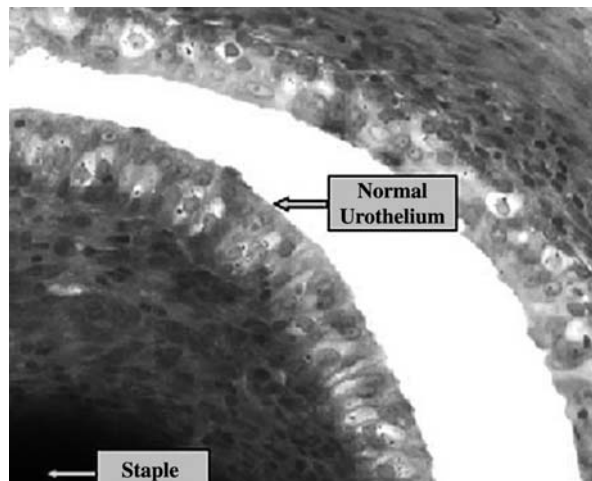


FIG. 2. Urothelium with viable cells adjacent to staple within ureter 6 weeks after stapling. (H & E stain)

incidence of contralateral disease (2%). When nephroureterectomy is performed by the traditional open technique, this procedure demands either two incisions or a single long abdominal incision. Advances in laparoscopic instrumentation such as surgical stapling devices have provided a minimally invasive approach for the treatment of upper-tract TCC. Oncologically, meticulous handling of the distal ureter and bladder cuff is critical during nephroureterectomy for upper-tract tumors to prevent spillage of the tumor cells or sparing of distal-ureteral tissues, which can result in bladder or retroperitoneal recurrence. Transperitoneal laparoscopic nephroureterectomy with the aid of a stapling device provides safe and secure closure of the bladder cuff with no local spillage. The versatility and speed of the available reticulating and articulating stapling devices helps in precise placement of the stapler across the ureterovesical junction in the narrow pelvic space.

The first laparoscopic nephroureterectomy was performed by Clayman and colleagues, who described the pre-nephrectomy technique of stapling the distal ureterovesical junction preceded by unroofing of the intramural ureter by a transurethral approach to the level of the intramural ureter.² Because of an extravesical recurrence, this approach was later modified such that the nephrectomy was performed first, followed by stapling the cuff of bladder; at the end of the procedure, cystoscopy was performed, and any remnant of the ureteral orifice or tunnel was unroofed until the staple line was identified. The unroofed portion of the ureteral tunnel was then electrocoagulated with a rollerball electrode.

An alternative technique of total laparoscopic nephroureterectomy is to perform flexible cystoscopy to map the bladder endoscopically prior to the laparoscopic procedure and use a Bugbee electrode to cauterize the intramural portion of the ureter and the ureteral orifice. Cauterization of the intramural ureter destroys the urothelium of the distal end of the ureter. It also facilitates identification of the distal limits of ureteral dissection during the laparoscopic procedure before stapling of the bladder cuff. Of note, an earlier porcine study showed that titanium staples exposed to urine do not suffer encrustation or stone formation.³ Similarly, the clinical application of stapling devices to secure

and close the bladder cuff during laparoscopic nephroureterectomy has been shown not to result in stone formation on the staple line at long-term follow-up.¹ More recently, the use of titanium staples with the Endo-GIA stapler to provide secure closure of the renal pelvis during upper-tract laparoscopic reconstructive surgery was reported, with no evidence of stone formation during a median follow-up of 27 months.⁴ Similarly, Landman and colleagues have reported on their experience with standard and hand-assisted laparoscopic nephroureterectomy in 27 patients with TCC in whom distal-ureteral control was achieved with staplers, and there was no evidence of increased bladder tumor recurrence and no retroperitoneal recurrences at the stapled site with a mean follow-up of 27.4 and 9.6 months for hand-assist and standard groups, respectively.⁵

To our knowledge, the viability of cells within the stapled tissue line has not been assessed previously. The concern was raised that if these cells were viable and if a portion of the ureter was incorporated into the stapled bladder cuff (which is commonly the case), tumor might recur. In this study, we have clearly shown that these cells are indeed viable, and accordingly, there is the potential for tumor recurrence within the stapled site in the bladder. Also, as TCC is considered a field-change disease, any ureteral or bladder urothelium outside the staple lines has the potential to develop tumor. Having stated this, it should also be stressed that in our clinical experience at Washington University, there has been no tumor recurrence at the stapled site in patients who have undergone laparoscopic nephroureterectomy for upper-tract TCC.⁵ This has similarly been the experience of Yoshino and coworkers from Japan⁶ and other individuals who have likewise stapled the bladder cuff during nephroureterectomy. On the basis of the above information, we believe that although stapling of the distal ureteral and bladder cuff has been safe and effective, if the TCC is known to extend to the lower ureter, an alternative strategy (i.e., formal incisional resection and sutured closure) should be employed for management of the distal ureter and bladder cuff.

CONCLUSIONS

In this porcine model, there were viable cells within all the staple lines at the vesicoureteral junction and bladder wall that

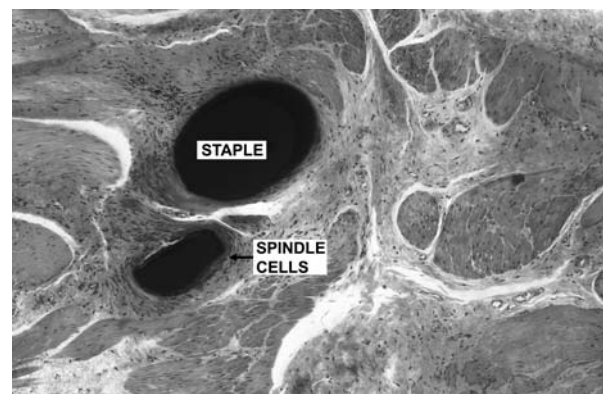


FIG. 3. Embedded staples in ureter with minimal fibrotic reaction showing spindle cells around staples. (H & E stain)

had been closed with any of the laparoscopic tissue or vascular stapling devices. Although clinically, distal-ureteral stapling has been successful, there may be a risk of tumor recurrence at the stapled site. Endoscopic bladder mapping before laparoscopy and careful cystoscopic evaluation of the site of the stapled bladder cuff after laparoscopic nephroureterectomy should minimize the potential for local tumor recurrence. As such, while we continue to use this method when dealing with TCC affecting the kidney or proximal ureter, we believe an alternative management strategy for the distal ureteral cuff should be employed when the tumor is known to extend to the distal ureter.

REFERENCES

1. Shalhav AL, Dunn MD, Portis AJ, Elbahanasy AM, McDougall EM, Clayman RV. Laparoscopic nephroureterectomy for upper tract transitional cell cancer: The Washington University experience. *J Urol* 2000;163:1100.
2. Clayman RV, Kavoussi LR, Figenschau RS, et al. Laparoscopic nephroureterectomy: Initial case report. *J Laparoendosc Surg* 1991; 1:343.
3. Maxwell KL, McDougall EM, Shalhav AL, et al. Laparoscopic ureteroureterostomy using vascular closure staples in a porcine model. *J Endourol* 1998;12:265.
4. Grubb RL, Sundaram CP, Yan Y, Chen C, McDougall EM, Clayman RV. Use of titanium staples during upper tract laparoscopic reconstructive surgery: Initial experience. *J Urol* 2002;168:1366.
5. Landman J, Lev R, Bhayani S, et al. Comparison of hand-assisted and standard laparoscopic radical nephroureterectomy for the management of localized transitional cell carcinoma. *J Urol* 2002;167: 2387.
6. Yoshino Y, Ono Y, Hattori R, Gotoh M, Kamihira O, Ohshima S. Retroperitoneoscopic nephroureterectomy for transitional cell carcinoma of the renal pelvis and ureter: Nagoya experience. *Urology* 2003;51:533.

Address reprint requests to:

Ralph V. Clayman, M.D.

Dept. of Urology

University of California, Irvine

101 The City Drive, Building 55

Room 304, Rt. 81

Orange, CA 92868-5395

E-mail: rclayman@uci.edu