

Washington University School of Medicine Digital Commons@Becker

Open Access Publications

2005

Comparison of running and interrupted vesicourethral anastomoses in a porcine model

David Lieber

Washington University School of Medicine in St. Louis

Veronique Tran

Washington University School of Medicine in St. Louis

Jay Belani

Washington University School of Medicine in St. Louis

Caroline Ames

Washington University School of Medicine in St. Louis

Kevin Morissey

Washington University School of Medicine in St. Louis

See next page for additional authors

Follow this and additional works at: http://digitalcommons.wustl.edu/open_access_pubs

Recommended Citation

Lieber, David; Tran, Veronique; Belani, Jay; Ames, Caroline; Morissey, Kevin; Yan, Yan; Humphrey, Peter; Venkatesh, Ramakrishna; and Landman, Jaime, "Comparison of running and interrupted vesicourethral anastomoses in a porcine model." *Journal of Endourology*.19,9. 1109-1113. (2005).

http://digitalcommons.wustl.edu/open_access_pubs/3120

This Open Access Publication is brought to you for free and open access by Digital Commons@Becker. It has been accepted for inclusion in Open Access Publications by an authorized administrator of Digital Commons@Becker. For more information, please contact engeszer@wustl.edu.

Authors

David Lieber, Veronique Tran, Jay Belani, Caroline Ames, Kevin Morrissey, Yan Yan, Peter Humphrey, Ramakrishna Venkatesh, and Jaime Landman

Comparison of Running and Interrupted Vesicourethral Anastomoses in a Porcine Model

DAVID LIEBER, M.D.,¹ VERONIQUE TRAN, M.D.,¹ JAY BELANI, M.D.,¹ CAROLINE AMES, M.D.,¹
KEVIN MORISSEY, M.D.,¹ YAN YAN, M.D.,¹ PETER HUMPHREY, M.D.,²
RAMAKRISHNA VENKATESH, M.D.,¹ and JAIME LANDMAN, M.D.^{1,3}

ABSTRACT

Purpose: To compare running and interrupted suturing techniques for porcine vesicourethral anastomosis with regard to procedure time, histopathologic effects, and leakage.

Materials and Methods: Twelve domestic pigs were randomized to a running (N = 6) or an interrupted (N = 6) vesicourethral anastomosis with polyglycolic acid sutures. In each case, the bladder was drained for 7 days. A cystogram was performed immediately after completion of each anastomosis and on postoperative days 7 and 30. Animals were sacrificed on postoperative day 30, and the area of the anastomosis was excised *en bloc* for histopathologic evaluation.

Results: All procedures were completed laparoscopically. The mean operative time for continuous and interrupted suturing were 27.5 and 36.8 minutes, respectively ($P = 0.3324$). A significant learning curve was noted for both anastomoses, with operative times decreasing with experience in both groups. There was no difference in anastomotic leakage. Histopathology examination revealed more muscle-layer fibrosis in the interrupted-suture group than in the continuous-suture group, with a mean score of 2.17 and 1.67, respectively ($P = 0.0325$).

Conclusions: Both continuous and interrupted vesicourethral anastomoses are feasible. In this *in-vivo* porcine comparison, there was no difference with respect to procedure time or anastomotic leakage. However, histopathologic grading demonstrated greater muscle fibrosis in the interrupted-suture group.

INTRODUCTION

LAPAROSCOPIC RADICAL PROSTATECTOMY was introduced by Shuessler and colleagues in 1997.¹ The technique was refined and gained acceptance after modifications were introduced by Guillonnet and Vallancien.^{2,3} Subsequently, other groups have continued to modify the technique, including introduction of an extraperitoneal technique.⁴

One of the most technically challenging components of laparoscopic radical prostatectomy remains the vesicourethral anastomosis. The initial description of this technique was an interrupted anastomosis (IA).^{1,5} However, others have described application of a continuous anastomosis (CA).⁶⁻⁹ Previous authors in other surgical specialties have focused on the issue of IA versus CA for tracheal,¹⁰ esophageal,¹¹ fallopian tube,¹² in-

testinal,¹³⁻¹⁵ and vascular¹⁶⁻²¹ anastomoses. None of these studies has established the superiority of one technique, making the individual surgeon's preference paramount. We compared the two techniques in an *in-vivo* porcine model with regard to procedure time, anastomotic leakage, and histopathologic effects.

MATERIALS AND METHODS

Permission for experiments was gained from the Department of Comparative Medicine at Washington University. Twelve domestic pigs (50–70 kg) were randomized to either an IA or a CA. A single surgeon (DL) with equal clinical experience with both interrupted and continuous vesicourethral anastomoses performed all procedures.

¹Division of Urology and ²Department of Pathology, Washington University School of Medicine, St. Louis, Missouri.

³Present address: Department of Urology, Columbia University School of Medicine, New York, New York.

Each animal fasted for 12 hours prior to the procedure, and ceftiofur sodium (5.0 mg/kg) was administered intramuscularly every 12 hours beginning preoperatively and continuing postoperatively for 24 hours. Telazol 0.45 mg/kg, xylazine 0.45 mg/kg, and ketamine 0.45 mg/kg were administered intramuscularly prior to intubation. After general intubated anesthesia was induced with 2% to 3% isoflurane, the pig was placed in a dorsal lithotomy position. Under aseptic conditions, cystoscopy was performed to place an 18F Foley catheter. Pneumoperitoneum was then established through a Veress needle placed at the umbilicus. Once the intra-abdominal pressure reached 15 mm Hg, the Veress needle was removed, and a 12-mm laparoscopic trocar was deployed. The pig was then placed in the Trendelenburg position. Two additional 12-mm working trocars were placed 8 to 10 cm lateral to the umbilicus under direct vision.

The bladder neck was identified and mobilized, and the vesicourethral junction was divided sharply. The vesicourethral anastomosis was performed utilizing 2-O Vicryl suture on an SH needle. The single-knot method for the running anastomosis described by Van Velthoven and colleagues was employed.⁷ Two 2-O Vicryl sutures were tied together extracorporeally to form a 6-inch double-armed suture. The remaining knots were instrument tied intracorporally. The sutures were passed outside in through the bladder neck at the 5:30- and 6:30-o'clock positions. The next needle passes were through the corresponding positions on the urethra from the inside out. Each suture was run on its corresponding side during the anastomosis, making sure to prevent the suture from crossing the midline. The anastomosis was completed over an 18F Foley catheter and tied at the 12-o'clock position after the anastomosis was judged to be secure and watertight.

The IA was performed utilizing a 2-O Vicryl suture with an SH needle. The posterior bladder neck was secured with two interrupted sutures through the 5:30- and 7:30-o'clock positions with the knot tied within the bladder lumen. Additional inter-

rupted sutures were performed as the anastomosis was completed over an 18F Foley catheter, with the remaining interrupted sutures being secured on the outside of the anastomosis.

After completion of the anastomosis, the Foley catheter balloon was inflated to 5 mL. Each trocar site was closed with 2-O Vicryl suture, and a 40 cm H₂O cystogram was performed by allowing 250 mL of contrast medium (iothalamate meglumine 60%; Conray; Mallinckrodt, St. Louis) to flow by gravity into the bladder. The bladder was then drained to completion via a 18F foley catheter by gravity for 5 minutes, with the contents collected and measured and the amount recorded. A repeat cystogram was performed in the same manner 1 week and 1 month after surgery. In addition to measuring postcystogram residuals to assess anastomotic leakage, fluoroscopy was used to grade leakage during the cystogram on a scale from 0 to 3 (0 none, 1 minimal, 2 moderate, and 3 severe). Postoperatively, the bladder was decompressed for 7 days with a Foley catheter. The animals were euthanized 1 month postoperatively, and the anastomotic site was excised *en bloc*. The tissues were fixed in 10% Formalin and then sectioned and stained with hematoxylin and eosin. All slides were analyzed by an experienced pathologist (PH), who was blinded to the gross findings as well as to the experimental group being evaluated. Each anastomotic site was analyzed and scored independently.

Histopathology parameters were graded using a previously described system.²² Light microscopy was utilized to assess for several factors, each based on a score of 0 to 3 (0 normal, 1 slight changes, 2 moderate changes, and 3 severe changes). Inflammatory reaction was graded for mural inflammation, lamina propria inflammation, edema, and perianastomotic fat inflammation. The fibrotic reaction of the anastomotic site was measured by muscle-layer fibrosis, lamina propria fibrosis, granulation tissue, perianastomotic fat fibrosis, and the presence of myofibroblasts. In addition, the following categories were analyzed: focal foreign-body reaction, squamous metaplasia, mucinous metaplasia, hemosiderin deposits, perianasto-

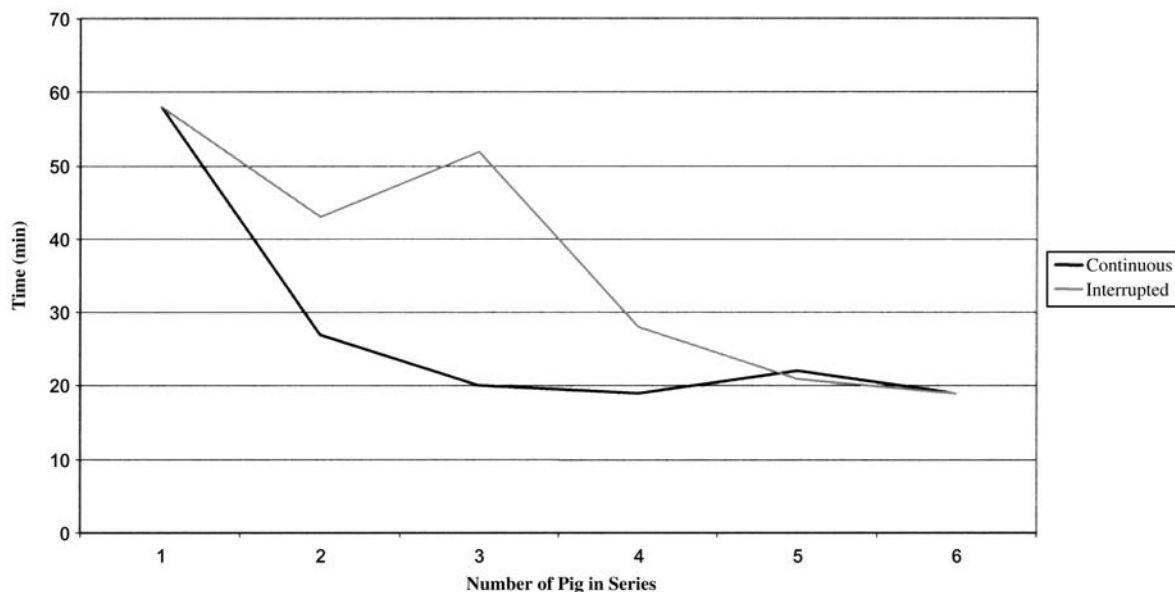


FIG. 1. Time required for vesicourethral IA and CA.

TABLE 1. COMPARISON OF HISTOPATHOLOGIC FINDINGS

	<i>Continuous mean (range)</i>	<i>Interrupted mean (range)</i>	<i>P value</i>
Inflammatory reaction of anastomoses			
Mural inflammation	1 (0–2)	1.166667 (0–2)	0.2273
Lamina propria inflammation	1.166667 (1–2)	1 (0–2)	0.2727
Edema	1.166667 (0–2)	1 (1)	0.0909
Perianastomotic fat inflammation	0.166667 (0–1)	0.333333 (0–1)	0.4091
Fibrotic reaction			
Muscle-layer fibrosis	1.67 (1–2)	2.17 (1–3)	0.0325
Lamina propria fibrosis	0.67 (0–1)	1 (1)	0.2273
Granulation tissue	0.67 (0–1)	1 (1)	0.2273
Peri-anastomotic fat fibrosis	0.5 (0–1)	0.67 (0–1)	0.3788
Focal foreign-body reaction	1.5 (1–2)	1.5 (0–3)	0.1082
Squamous metaplasia	0 (0)	0 (0)	
Mucinous metaplasia	0.83 (0–2)	0.83 (0–2)	0.1299
Hemosiderin deposits	0 (0)	0 (0)	
Perianastomotic hemorrhage	0.17 (0–1)	0 (0)	0.5000
Presence of necrotic debris	0 (0)	0 (0)	
Percentage of defect covered with urothelium	100 (100)	76.7 (10–100)	0.1757
Percentage of defect covered with smooth muscle	75 (0–100)	37.5 (0–100)	0.2221
Description of muscle layer			
Thickness	0.67 (0–2)	0.5 (0–20)	0.2273
Muscle fascicles	2 (1–3)	3 (3)	0.0974
Number of sutures present on light microscopy	1.33 (1–2)	1.67 (0–3)	0.0065

motric hemorrhage, and the presence of necrotic debris. The percent of the anastomotic site that was covered with urothelium and smooth muscle was also documented.

Statistical analysis was performed utilizing Fisher’s exact test to compare the frequency distribution of categorical variables and the non-parametric Wilcoxon test to compare continuous variables.

RESULTS

Procedure times for IA and CA are presented in Figure 1. There were no statistical differences. However, there was a sig-

nificant learning curve for both types of anastomoses. Procedure times for CA and IA decreased from 58 minutes to 19 minutes with a mean operative time of 27.5 and 36.8 minutes, respectively. A mean number of 7.3 and 5.5 sutures were passed for the CA and IA groups, respectively ($P = 0.0037$).

The postoperative cystogram volumes for CA and IA were 238 mL (range 180–270 mL) and 256 mL (range 240–275 mL) ($P = 0.3717$). On the day of surgery, the mean fluoroscopic leakage grade was 1.5 (range 0–2) for the CA group and 0.17 (range 0–1) for the IA group ($P = 0.2727$). The volumes for cystograms performed on postoperative day 7 for CA and IA were 254 mL (range 180–320 mL) and 266 mL (range 208–370 mL), respectively ($P = 0.9353$). The volumes for cystograms

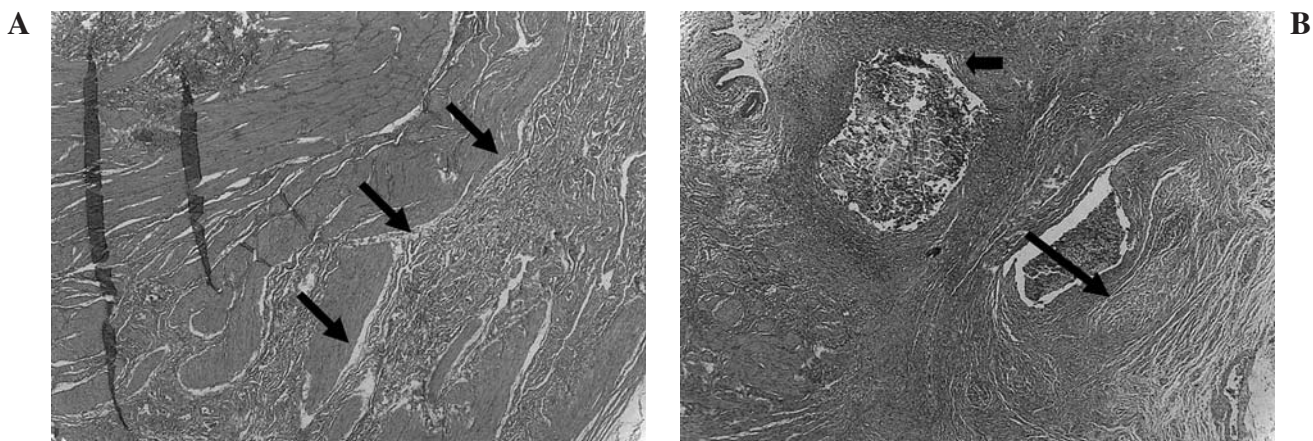


FIG. 2. Muscle-layer fibrosis. (A) Continuous anastomosis. Arrow indicate areas of fibrosis. (B) Interrupted anastomosis. Long arrow indicates area of fibrosis. Suture material is present (short arrow).

performed on postoperative day 30 for CA and IA were 266 mL (range 230–330 mL) and 292 mL (range 240–350 mL), respectively ($P = 0.2281$). Neither cohort demonstrated anastomotic leakage on fluoroscopic examination at day 7 or day 30.

Histopathology data are presented in Table 1. There was no statistical difference in the grades of focal foreign-body reaction, squamous metaplasia, mucinous metaplasia, hemosiderin deposits, perianastomotic hemorrhage, or the presence of suture material. The inflammatory reaction of the anastomosis and the amount of urothelium and muscle present at the anastomosis also revealed no statistical difference. However, evaluation of the muscle layer revealed a higher degree of fibrosis in the IA than the CA cohort, with a mean score of 2.17 and 1.67, respectively ($P = 0.0325$). The fibrosis was localized in the urethra in the area where the suture was passed. Figure 2 demonstrates muscle fibrosis in each group, as well as suture material in the IA tissue.

DISCUSSION

Laparoscopic radical prostatectomy is a challenging procedure that offers patients the advantages of decreased blood loss and faster convalescence.²³ One of the most challenging components of the procedure has been the vesicourethral anastomosis. While both CA and IA have been applied successfully, to our knowledge, no data have been published comparing the two techniques.

In this porcine study, we compared IA and CA and demonstrated no difference with respect to procedure time or anastomotic leakage. In both cohorts, there was a dramatic learning curve, with anastomotic times decreasing substantially in both groups, from approximately 60 minutes to 20 minutes in only six cases. The steep learning curve suggests that nonclinical *in-vivo* or *in-vitro* training may be of great value to surgeons who wish to attempt laparoscopic radical prostatectomy.

The difference in the number of sutures needed to complete the anastomosis was statistically significant ($P = 0.0037$), with a mean of 7.3 and 5.5 for the CA and IA groups, respectively. The clinical significance of this difference is unclear, but apparently the greater number of sutures had no bearing on the anastomotic times or leakage rates, as the differences were not significant.

Histopathology results were for the most part similar in the two groups except for a statistically significant higher incidence of muscle-layer fibrosis with IA ($P = 0.0325$). One possible reason for the greater incidence of muscle fibrosis is the amount of suture material present to cause a reaction as it dissolves. While it is intuitive that a running suture would have a greater amount of material at the anastomotic site, it is feasible that the knots used in the IA result in a larger volume of suture in the region of the anastomosis and therefore a greater tissue reaction. Additionally, it is feasible that the more intense fibrosis noted in the IA cohort is the result of tissue ischemia within the knots. Data in this regard are not available.

The clinical relevance of the greater degree of fibrosis remains undetermined. To date, there does not appear to be a high rate of bladder-neck contracture with laparoscopic radical prostatectomy when either the IA or the CA technique is employed. However, long-term data are not yet available, and the

results of our study suggest that an IA may eventually yield a higher rate of contracture.

CONCLUSIONS

Both IA and CA are feasible. In this *in-vivo* porcine model, there was no difference in anastomotic time or anastomotic leakage rate. The IA resulted in greater muscle-layer fibrosis, but the long-term significance of this finding remains to be determined.

REFERENCES

- Schuessler WW, Schulam PG, Clayman RV, et al. Laparoscopic radical prostatectomy: Initial short-term experience. *Urology* 1997;50:854.
- Guillonnet B, Cathelineau X, Barret E, et al. Prostatectomie radicale coelioscopique: Première évaluation après 28 interventions. *Presse Med* 1998;27:1570.
- Guillonnet B, Cathelineau X, Barret E, Rozet F, Vallancien G. Laparoscopic radical prostatectomy: Technical and early oncological assessment of 40 operations. *Eur Urol* 1999;36:14.
- Raboy A, Ferzli G, Albert P. Initial experience with endoscopic radical retropubic prostatectomy. *Urology* 1997;50:849.
- Guillonnet B, Vallancien G. Laparoscopic radical prostatectomy: Initial experience and preliminary assessment after 65 operations. *Prostate* 1999;39:71.
- Hoznek A, Salomon L, Rabii R, et al. Vesicourethral anastomosis during laparoscopic radical prostatectomy: The running suture method. *J Endourol* 2000;14:749.
- Van Velthoven R, Ahlering T, Peltier A, et al. Technique for laparoscopic running urethrovesical anastomosis: The single knot method. *Urology* 2003;61:699.
- Nadu A, Olsson LE, Abbou CC. Simple model for training in the laparoscopic vesicourethral running anastomosis. *J Endourol* 2003;17:481.
- Menon M, Tewari A, Peabody J, et al. Vattikuti Institute prostatectomy: Technique. *J Urol* 2003;169:2289.
- Behrend M, Kluge E, Schuttler W, Klempnauer J. A comparison of interrupted and continuous sutures for tracheal anastomoses in sheep. *Eur J Surg* 2002;16:101.
- Bardini R, Bonavina L, Asolati M, et al. Single-layered cervical esophageal anastomoses: A prospective study of two suturing techniques. *Ann Thorac Surg* 1994;58:1087.
- Hurwitz A, Amir G, Yagel S, et al. A single continuous suture as a possible alternative to the interrupted suture for tubal anastomosis. *Int J Fertil* 1990;35:125.
- Burch JM, Francoise RJ, Moore EE, et al. Single-layer continuous versus two-layer interrupted intestinal anastomosis: A prospective randomized trial. *Ann Surg* 2000;231:832.
- Deen KI, Smart PJ. Prospective evaluation of sutured, continuous, and interrupted single layer colonic anastomoses. *Eur J Surg* 1995;161:751.
- Jonsson T, Hogstrom H, Zederfeldt B. Effect of interrupted and continuous suturing on intestinal wound margin strength in rats. *Eur Surg Res* 1993;25:169.
- Chen YX, Chen LE, Seaber AV, Urbaniak JR. Comparison of continuous and interrupted suture techniques in microvascular anastomosis. *J Hand Surg Am* 2001;26:530.
- Guity A, Young PH, Fischer VW. In search of the "perfect" anastomosis. *Microsurgery* 1990;11:5.

18. Laskar M, Cornu E, Leman A, et al. [Vascular anastomoses of small caliber vessels: Comparison between continuous or interrupted sutures] (Fre) Presse Med 1988;17:1152.
19. Mao K, Tang MY, South JR. A comparison of continuous with interrupted sutures in microvascular anastomosis. Microsurgery 1985;6:141.
20. Joos KM, Blair WF, Maynard JR. A comparison of continuous and interrupted microarteriorrhaphy. Microsurgery 1985;6:141.
21. Firsching R, Terhaag PD, Muller W, Frowein RA. Continuous- and interrupted-suture technique in microsurgical end-to-end anastomosis. Microsurgery 1984;5:80.
22. Andreoni CR, Hsueh-Kung L, Olweny E, et al. Comprehensive evaluation of ureteral healing after electrosurgical endopyelotomy in a porcine model: Original report and review of the literature. J Urol 2004;171:859.
23. Bhayani SB, Pavlovich CP, Hsu TS, et al. Prospective comparison of short-term convalescence: Laparoscopic radical prostatectomy versus open radical retropubic prostatectomy. Urology 2003;61:612.

Address reprint requests to:
Jaime Landman, M.D.
161 Ft. Washington Ave.
Room 1111
New York, NY 10023

E-mail: landmanj@yahoo.com