

2004

Laparoscopic sacrocolpopexy for the correction of vaginal vault prolapse

Chandru P. Sundaram

Indiana University - Purdue University Indianapolis

Ramakrishna Venkatesh

Washington University School of Medicine in St. Louis

Jaime Landman

Washington University School of Medicine in St. Louis

Carl G. Klutke

Washington University School of Medicine in St. Louis

Follow this and additional works at: http://digitalcommons.wustl.edu/open_access_pubs

Recommended Citation

Sundaram, Chandru P.; Venkatesh, Ramakrishna; Landman, Jaime; and Klutke, Carl G., "Laparoscopic sacrocolpopexy for the correction of vaginal vault prolapse." *Journal of Endourology*.18,7. 620-623. (2004).
http://digitalcommons.wustl.edu/open_access_pubs/3160

Techniques in Endourology

Laparoscopic Sacrocolpopexy for the Correction of Vaginal Vault Prolapse*

CHANDRU P. SUNDARAM, M.D.,¹ RAMAKRISHNA VENKATESH, M.D.,² JAIME LANDMAN, M.D.,²
and CARL G. KLUTKE, M.D.²

ABSTRACT

Background and Purpose: Laparoscopic sacrocolpopexy offers a minimally invasive approach to correcting vaginal vault prolapse. We describe our operative technique and review our experience.

Patients and Methods: A retrospective study of 10 patients who underwent laparoscopic sacrocolpopexy between February 2000 and June 2002 for posthysterectomy vaginal vault prolapse was performed. Data collected included operative time, complications, hospital stay, and postoperative morbidity.

Results: One patient underwent primary laparoscopic repair of an intraoperative bladder injury. Conversion from a laparoscopic to an open procedure was required in one patient because of dense bowel adhesions in the pelvis. The mean analgesic (morphine sulfate equivalent) requirement was 7.3 mg (range 5–21 mg). With a mean follow-up of 16 months (range 5–32 months), prolapse recurred in one patient.

Conclusion: In the short term, laparoscopic sacrocolpopexy appears to be an effective approach for the treatment of vaginal vault prolapse with minimal postoperative pain and morbidity.

INTRODUCTION

VAGINAL VAULT PROLAPSE is descent of the apex of the vagina below the introitus, turning the vagina inside out. Vaginal vault prolapse is uncommon in the United States, occurring in only 900 to 1200 women annually, and is estimated to develop in 0.2% to 1% of women who have undergone hysterectomy.¹ The goals of correcting vault prolapse are relief of symptoms, restoration of normal vaginal anatomic relations, and preservation of coital function. Abdominal sacrocolpopexy, by suspending a mesh hammock between the prolapsed vaginal vault and sacrum, provides durable support to the vagina that has prolapsed after hysterectomy.^{2–4}

The laparoscopic approach to sacrocolpopexy for vaginal vault prolapse is a relatively new procedure, carried out in very few specialized centers across the country. We demonstrate our technique for this procedure and review the outcome.

TECHNIQUE

The laparoscopic sacrocolpopexy was performed with the intent of applying the principles of open sacrocolpopexy. Laparoscopic techniques and instruments were adapted to duplicate open surgery. Our procedures were performed by an experienced laparoscopic surgeon (CPS) assisted by an experienced open surgeon (CGK). The equipment used is listed in Table 1.

Patient preparation

The patient is placed in the dorsal lithotomy position, and the vagina and the abdomen are prepared and draped in a sterile fashion. The vagina, including the apex, is thoroughly prepared with povidone-iodine solution. The bladder is drained with a Foley catheter. Preoperatively, intravenous cefazolin and gentamicin are administered.

¹Department of Urology, Indiana University School of Medicine, Indianapolis, Indiana.

²Department of Surgery, Division of Urologic Surgery, Washington University School of Medicine, St. Louis, Missouri.

*The technique described here is illustrated on the enclosed CD-ROM. Videoclips available online at www.liebertpub.com/end/video/.

TABLE 1. INSTRUMENTS FOR LAPAROSCOPIC SACROCOLPOPEXY

Trocars, two 12 mm, three 5 mm
30° laparoscope
Harmonic Scalpel (Ethicon Endosurgery, Cincinnati, OH)
5-mm grasping forceps
Suction irrigator
Bowel retractor (fan shaped)
Ethicon drivers (non-self-righting), two
Gore-Tex mesh (W.L. Gore and Associates, Flagstaff, AZ)
2-0 Ethibond suture on CT-1 needle (Ethicon, Inc., Somerville, NJ)
Endostitch device with 2-0 polyglactin suture (US Surgical, Norwalk, CT)
Protack helical tacker (US Surgical) with clips
Endoscissors
Sponge-holding forceps

Approach

After the pneumoperitoneum is established with a Veress needle, the trocars are introduced in a fan-shaped or inverted-U configuration (Fig. 1). We use five trocars: two 12-mm trocars and three 5-mm trocars. A 30° laparoscope is introduced through the umbilical 12-mm trocar. The trocars on the left are used by the surgeon, who stands on the left of the patient, fac-

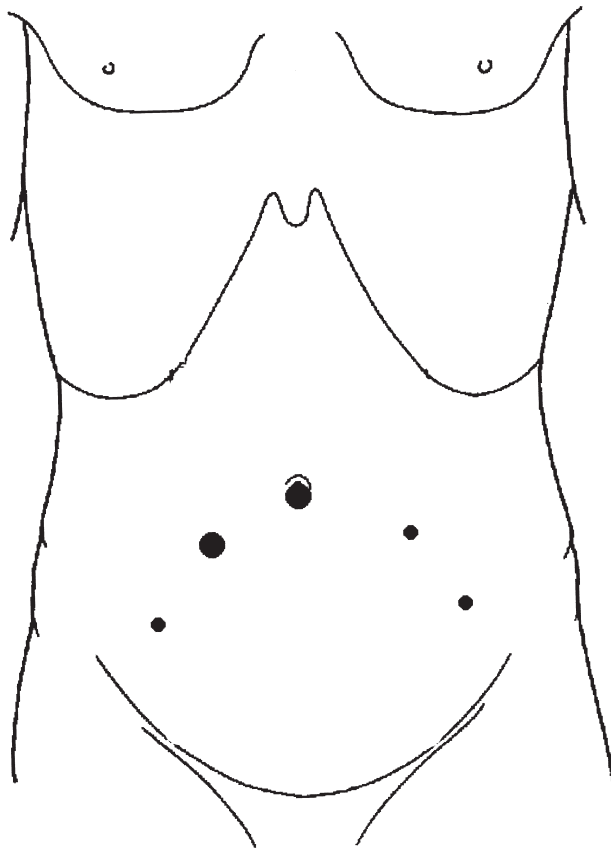


FIG. 1. Trocar positions. Large dot: 10/12 mm; small dot: 5 mm.

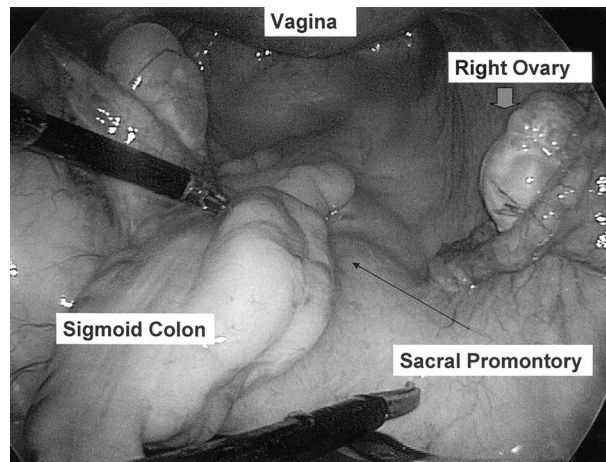


FIG. 2. Pelvic anatomy with patient in Trendelenburg position and sigmoid colon retracted to left.

ing the patient's right leg, while the assistant utilizes the trocars on the right. The patient is placed in a steep Trendelenburg position to help move the bowel out of the pelvis. The sigmoid colon is retracted superiorly and to the left with a fan retractor to facilitate exposure of the anterior sacral surface (Fig. 2). A sponge stick in the vagina is used by an assistant to push the vaginal vault to facilitate vaginal dissection.

Presacral dissection

The peritoneum over the sacral promontory is incised in the midline to the right of the sigmoid mesocolon using ultrasonic shears (Fig. 3). The prominent sacral promontory is identified, and the presacral fascia is exposed for fixation of the Gore-Tex patch (W.L. Gore and Associates, Flagstaff, AZ). Care is taken not to shear the presacral veins by excessive blunt dissection. During the surgeon's early experience, prior placement of external ureteral catheters can facilitate identification of the

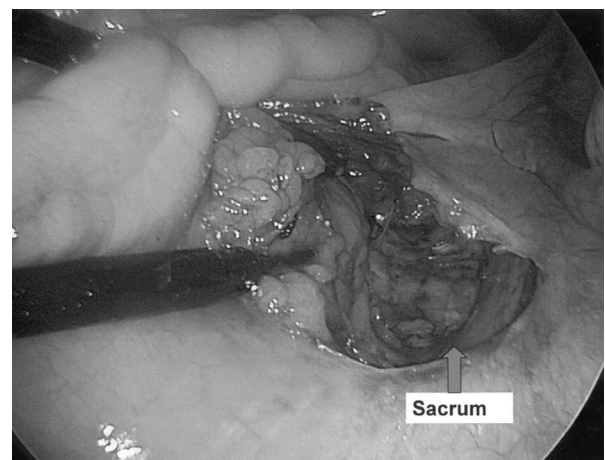


FIG. 3. Incision of peritoneum overlying sacrum exposes presacral fascia.

ureters. Rolled gauze is placed in the presacral region to keep this area dry until fixation of the Gore-Tex patch is performed (Fig. 4).

Vaginal vault dissection

The apex of the vagina is identified and elevated using a lubricated intravaginal sponge stick, and the overlying peritoneum is incised transversely. The peritoneal surface is dissected off the vaginal apex while simultaneously mobilizing the bladder anteriorly and the rectum posteriorly. The vault apex is exposed about 3 cm anteriorly and posteriorly. An appropriate length of Gore-Tex patch is taken, usually 2×8 cm, one end of which is fixed to the vault of the vagina with interrupted 2-0 Ethibond suture on a CT1 needle (Ethicon, Somerville, NJ). We now use polypropylene mesh.

Culdoplasty

Culdoplasty is performed by closing the cul-de-sac linearly (Halban's method) with 2-0 Vicryl sutures by opposing the remnants of the uterosacral ligaments using an Endostitch device (US Surgical, Norwalk, CT). Alternatively, the closure of the cul-de-sac can be achieved with a 2-0 polyglactin pursestring suture using the Moschowitz technique. Care is taken not to injure the ureters during this procedure. Constriction of the colon must also be avoided.

Patch fixation to sacrum

The Gore-Tex patch is affixed to the presacral fascia and periosteum using a laparoscopic 5-mm Protack helical tacker (US Surgical), making sure there is no tension on the patch (Fig. 5). The excess patch is excised. The patch is retroperitonealized by bringing the peritoneal edges back together over the sacrum using 2-0 polyglactin sutures on an Endostitch device (Fig. 6).

Postoperative care

Postoperatively, the patient is given three doses of antibiotics intravenously, and an oral antibiotic is prescribed for 1 week.

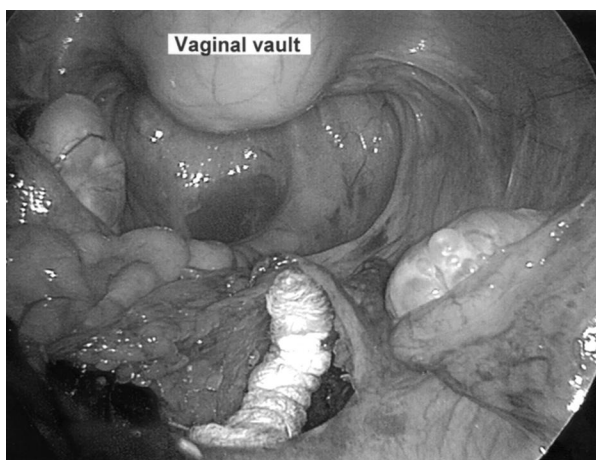


FIG. 4. Rolled gauze overlying presacral fascia. Sponge stick inserted through vagina helps identify vaginal vault.

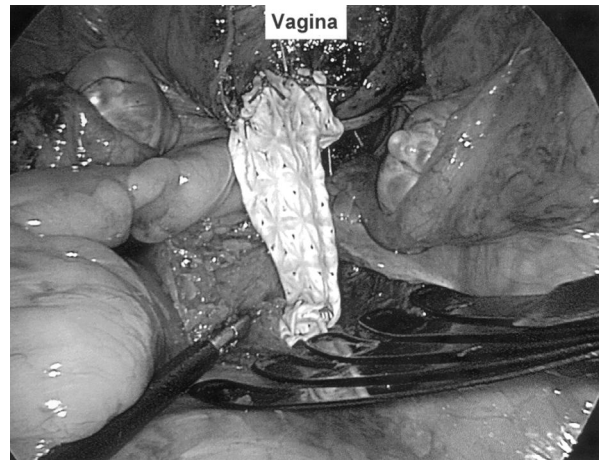


FIG. 5. Gore-Tex patch is sutured to vaginal vault and fixed to sacrum with helical tacker.

The Foley catheter is removed on the first postoperative day, after which most patients are discharged from the hospital. The patient is advised to refrain from strenuous activity and heavy lifting for 6 weeks.

RESULTS

In our series, the mean patient age was 61 years (range 43–83 years), and the average body mass index was 29 (range 22–34). The mean operative time was 196 minutes (range 170–265 minutes), and the average blood loss was 65 mL (range 20–125 mL). One patient underwent primary laparoscopic repair of an intraoperative bladder injury. One of the six patients with associated preoperative urinary symptoms got worse after surgery, requiring a TVT sling procedure for stress urinary incontinence. The average hospital stay was 2 days (range 1.5–3 days), and the mean postoperative analgesic requirement (mor-

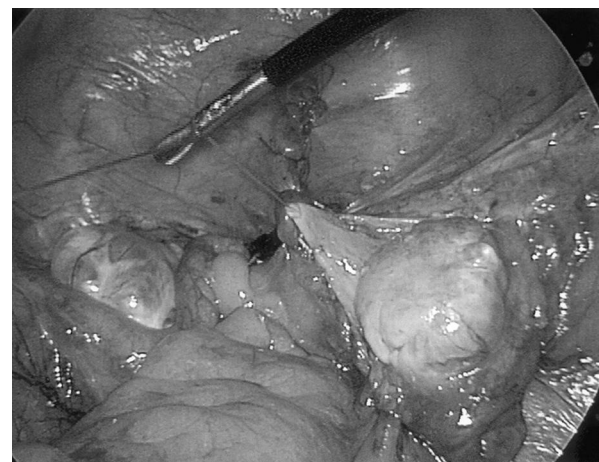


FIG. 6. Gore-Tex patch has been peritonealized with continuous 2-0 polyglactin suture using Endostitch device. Lapra-Ty clip is visible at one end of suture line.

phine sulfate equivalent) was 7.3 mg (range 5–21 mg). The average time of return to normal activity was 1.5 weeks (range 0.5–6 weeks). With a mean follow-up of 16 months (range 5–32 months), there was recurrence of prolapse in one patient that was repaired laparoscopically.

ROLE IN UROLOGIC PRACTICE

Laparoscopic sacrocolpopexy offers a new approach to vaginal vault prolapse, providing a good view of the anterior and posterior pelvic compartments to correct the problem with minimal morbidity. The open procedure requires a midline abdominal incision, abdominal packing, and bowel manipulation and has the potential for morbidity such as infection, wound separation or dehiscence, and ileus or bowel obstruction.⁵ On the other hand, reported failures necessitating repeat operation with a long-term follow-up are few.^{6,7} Addison and coworkers⁶ observed 3 recurrences in 250 patients treated with abdominal sacrocolpopexy over a 20-year period, and Livengood and associates⁷ reported only 1 failure following 143 procedures. Nezhat and colleagues² and Dorsey and Cundiff⁸ reported the first cases of laparoscopic sacrocolpopexy in 1994. A synthetic material such as Gore-Tex was used for fixation of the vaginal vault to the sacral promontory. Y-shaped mesh for anterior and posterior fixation to the vaginal apex has been used.

Cosson et al from France⁹ reported on their experience with 77 patients who underwent laparoscopic sacral colpopexy. Subtotal laparoscopic hysterectomy and laparoscopic Burch colposuspension was performed in 60 and 74 patients, respectively. There were one rectal and two bladder injuries. Only five of these patients had prior hysterectomy. Open conversion was performed in six patients. Their mean follow-up was nearly 1 year, with three patients requiring reoperation: one for a third-degree cystocele and two for recurrent stress incontinence. Fedele and coauthors¹⁰ reported on their experience with 12 operations by the laparoscopic approach for posthysterectomy vaginal vault prolapse and reported no complications and no recurrence with a follow-up ranging from 9 to 28 months.

CONCLUSION

Laparoscopic sacrocolpopexy can be performed with minimal complications and morbidity. At least in the short term, the procedure appears to be an effective approach for the treatment of vaginal vault prolapse with minimal postoperative pain and morbidity.

REFERENCES

1. Dunton JD, Mikuta J. Posthysterectomy vaginal vault prolapse. *Postgrad Obstet Gynecol* 1988;8:1–6.
2. Nezhat CH, Nezhat C, Nezhat F. Laparoscopic sacral colpopexy for vaginal vault prolapse. *Obstet Gynecol* 1994;84:885–888.
3. Timmons MC, Addison WA, Cavenar MG. Abdominal sacral colpopexy in 163 women with posthysterectomy vaginal vault prolapse and enterocele. *J Reprod Med* 1992;37:323–327.
4. Arthur HG, Savage D. Uterine prolapse and prolapse of vaginal

vault treated by sacral hysterectomy. *J Obstet Gynaecol Br Emp* 1957;64:355–360.

5. Symmonds RE, Williams TJ, Lee RA, Webb MJ. Post-hysterectomy enterocele and vaginal vault prolapse. *Am J Obstet Gynecol* 1981;140:852–859.
6. Addison WA, Livengood CH, Parker RT. Posthysterectomy vaginal vault prolapse with emphasis on management by transabdominal sacral colpopexy. *Postgrad Obstet Gynecol* 1988;8:1–7.
7. Livengood CH, Addison WA. Failed abdominal sacral colpopexy: Observations and recommendations. *Obstet Gynecol* 1989;74:480–482.
8. Dorsey JH and Cundiff G. Laparoscopic procedures for incontinence and prolapse. *Curr Opin Obstet Gynecol* 1994;6:223.
9. Cosson M, Bogaert E, Narducci F, Querleu D, Crepin G. Laparoscopic sacral colpopexy: Short-term results and complications in 83 patients. *J Gynecol Obstet Biol Reprod (Paris)* 2000;8:746–750.
10. Fedele L, Garsia S, Bianchi S, Albiero A, Dorta M. A new laparoscopic procedure for the correction of vaginal vault prolapse. *J Urol* 1998;159:1179–1182.

Address reprint requests to:
Chandru P. Sundaram, M.D., FRCS
Dept. of Urology
University of Indiana School of Medicine
Indianapolis, IN 46202

E-mail: sundaram@iupui.edu

EDITORIAL COMMENT

Pelvic vault prolapse can be an extremely distressing problem for the small percentage of women who suffer this condition after hysterectomy. While there is a paucity of reports in the literature with regard to the laparoscopic approach to sacrocolpopexy, the open counterpart has certainly demonstrated excellent long-term success rates. I concur with the authors that the laparoscopic approach affords excellent access to the pelvis and magnification of the surgical site, which facilitates this minimally invasive approach to the surgical repair. Abdominal and pelvic adhesions secondary to the prior gynecologic surgery may be a limiting factor in the laparoscopic access for these patients. However, often, the pneumoperitoneum, in conjunction with articulating laparoscopic scissors or the Harmonic Shears, can facilitate adhesiolysis and access to the pelvis.

A variety of materials has been used to perform the sacrocolpopexy, and we have found Marlex mesh to be as successful as the Gore-Tex patch the authors describe. The key component of this surgical procedure is secure attachment of the chosen piece of material to the apex of the vaginal vault and then securing the cephalad aspect of the material to the presacral ligaments without any tension. This facilitates return of the vagina to its normal anatomic position.

One aspect of the surgical procedure that has limited the enthusiasm for the laparoscopic approach has been the challenge of intracorporeal suturing and knot tying. However, as the authors have demonstrated in the description of their technique, the use of the helical tacking device reduces the difficulty of securing the mesh to the sacral ligaments. We have also incorporated several time-saving tricks in our technique of performing the laparoscopic sacrocolpopexy. These allow laparoscopic

suturing of both the vaginal and the sacral ends of the mesh and include use of a pre-formed loop at the end of the suture and the incorporation of the Lapra-Ty suture clips to complete the securing of the continuous suturing of both ends of the mesh. The recent introduction of the robot-assisted laparoscopic approach has further enhanced our ability to perform sacrocolpopexy with a 50% reduction of our operative time.

It is essential that these patients be adequately assessed preoperatively for concomitant stress incontinence. Such incontinence can be addressed effectively at the same operative procedure. We have been incorporating the TVT procedure at the commencement of the operation to manage the stress incontinence and follow this with the laparoscopic sacrocolpopexy. It is important to perform the TVT procedure first, as the degree of elevation of the anterior vaginal vault as a result of the sacrocolpopexy may make access to the anterior vaginal wall difficult. Performing the TVT procedure initially facilitates this portion of the surgery and does not adversely affect the ability to complete the sacrocolpopexy. A formal posterior closure of the cul-de-sac can be performed in those patients with a significant

rectocele. Even in patients without evidence of an enterocele or posterior prolapse, we routinely use a purse-string suture to close the posterior cul-de-sac with a Moschcowitz technique. This maneuver alone will isolate the mesh material from the abdominal contents.

As the authors have demonstrated, laparoscopic sacrocolpopexy affords the patient with vaginal vault prolapse effective surgical management with minimal postoperative morbidity. While a randomized study comparing the open and laparoscopic approaches for sacrocolpopexy is unlikely to happen, I commend the authors on their report as an addition to the literature on this topic. I encourage them to continue accruing patients to their study population and to provide further long-term (5-year) follow-up with regard to this technique in the future.

Elspeth M. McDougall, M.D.
University of California—Irvine Medical Center
Orange, California