

Washington University School of Medicine Digital Commons@Becker

Open Access Publications

2012

Intestinal adenocarcinoma arising in urinary conduits

Genevieve C. Moyer
Saint Louis University

Robert L. Grubb III
Washington University School of Medicine in St. Louis

Frank E. Johnson
Saint Louis University

Follow this and additional works at: http://digitalcommons.wustl.edu/open_access_pubs

Recommended Citation

Moyer, Genevieve C.; Grubb, Robert L. III; and Johnson, Frank E., "Intestinal adenocarcinoma arising in urinary conduits." *Oncology Reports*.27,2. 371-375. (2012).
http://digitalcommons.wustl.edu/open_access_pubs/2100

This Open Access Publication is brought to you for free and open access by Digital Commons@Becker. It has been accepted for inclusion in Open Access Publications by an authorized administrator of Digital Commons@Becker. For more information, please contact engeszer@wustl.edu.

Intestinal adenocarcinoma arising in urinary conduits

GENEVIEVE C. MOYER¹, ROBERT L. GRUBB III^{2,3} and FRANK E. JOHNSON^{1,3}

¹Department of Surgery, Saint Louis University Medical Center, ²Washington University Medical Center and ³St. Louis Department of Veterans Affairs Medical Center, St. Louis, MO, USA

Received June 15, 2011; Accepted July 4, 2011

DOI: 10.3892/or.2011.1534

Abstract. It is estimated that >10,000 patients who undergo cystectomy for bladder cancer in the US each year receive a conventional ileal conduit and that >2,000 receive a continent urinary diversion. Case reports of primary intestinal adenocarcinomas in urinary conduits have been published recently, mainly in the urology literature. An epidemic of such cancers in this small, high-risk population seems to be emerging, particularly in conduits that utilize the colon. A case report and literature review was carried out. We describe a patient with a new primary adenocarcinoma arising in a colonic neobladder. We summarize prior literature describing intestinal adenocarcinomas that developed in an intestinal segment used for urinary diversion. Patients with urinary conduits of all types (particularly those utilizing colon rather than ileum) are at high risk of developing a second primary intestinal adenocarcinoma in the conduit. This population is likely to benefit from surveillance measures aimed at detecting such cancers. The primary form of therapy remains adequate surgical resection. General surgeons should be aware of such patients as they may be involved in the diagnosis of, and surgery for, the cancer in the conduit.

Introduction

In 2008, the World Health Organization projected that cancer would become the leading cause of death in the world (1). Carcinoma of the urinary bladder is the ninth most commonly diagnosed type of cancer in the world (2). Over 70,000 people in the US develop this cancer every year (3) and the incidence is projected to increase (4). Comparable data are reported from other wealthy nations (5). In the US and most other countries, tobacco abuse is the main known environmental risk factor for the development of bladder cancer (6-8). The incidence in smokers is estimated to be two to three times as great as the incidence in non-smokers. In countries where *S. haematobium*

is endemic, bladder infestation is the leading cause (2). In river basins draining the Himalayas (e.g., India, Pakistan, Myanmar, Vietnam), the groundwater contains high concentrations of arsenic, which is a major cause of bladder carcinoma (9). Additional known etiologic agents include exposure to certain aromatic amines such as those found in dyes and rubber, the chemotherapeutic agent cyclophosphamide, ionizing radiation, and various textiles and metals (7,10,11).

Colorectal carcinoma is the third most commonly diagnosed type of cancer in the world (1). Over 150,000 people in the US develop cancer of the colon or rectum every year (12). Adenomas arising in subjects without known polyposis syndromes are the most common precursor lesion. Hamartomas are also well-described precursor lesions, as in Peutz-Jehgers syndrome. Other known causes of colorectal cancer include hereditary polyposis syndromes, Li-Fraumeni syndrome, inflammatory bowel disease, and ionizing radiation (13,14). Charred food and diets high in red meat and low in fiber, fruits and vegetables have been implicated as causative environmental agents (15-17). There is some evidence that a human colonic bacterium promotes colonic tumorigenesis (18). Tobacco abuse, including secondhand smoke exposure, is also associated with colorectal carcinoma development (19), and the relationship appears to be dose-dependent (20).

Over 6,000 new cases of small intestinal cancer are diagnosed in the US annually (12). These include carcinoid, adenocarcinoma, lymphoma, and sarcoma/gastrointestinal stromal tumor. Cancer of the small intestine accounts for about 1-2% of all gastrointestinal cancers. Predisposing causes include familial polyposis syndromes, Peutz-Jehgers syndrome, Crohn's disease, hereditary non-polyposis colon cancer syndromes, and cystic fibrosis (21). Because of the rarity of these cancers, the role of environmental agents such as tobacco-derived carcinogens has not been fully explored (22).

About 75% of bladder cancers are low-grade and non-muscle-invasive. They are usually managed by cystoscopic resection. Radical cystectomy is the mainstay of treatment for muscle-invasive carcinoma (though partial cystectomy is occasionally utilized). After radical cystectomy, some form of urinary diversion is required. Direct implantation of the ureters into non-isolated intestinal segments, particularly colon, was employed quite frequently after it was first described in 1852 by Simon (23). Feris and Odel reported that patients with a uretero-sigmoidostomy often had intractable hyperchloremic metabolic acidosis and other metabolic complications so this procedure is now used infrequently (23). Uterosigmoidostomy was also found to lead to adenocarcinoma of the colon adjacent

Correspondence to: Dr Frank E. Johnson, Department of Surgery, Saint Louis University Hospital, 3635 Vista Ave. at Grand Blvd., St. Louis, MO 63110, USA
E-mail: frank.johnson1@va.gov

Key words: adenocarcinoma, urinary conduit, tobacco abuse

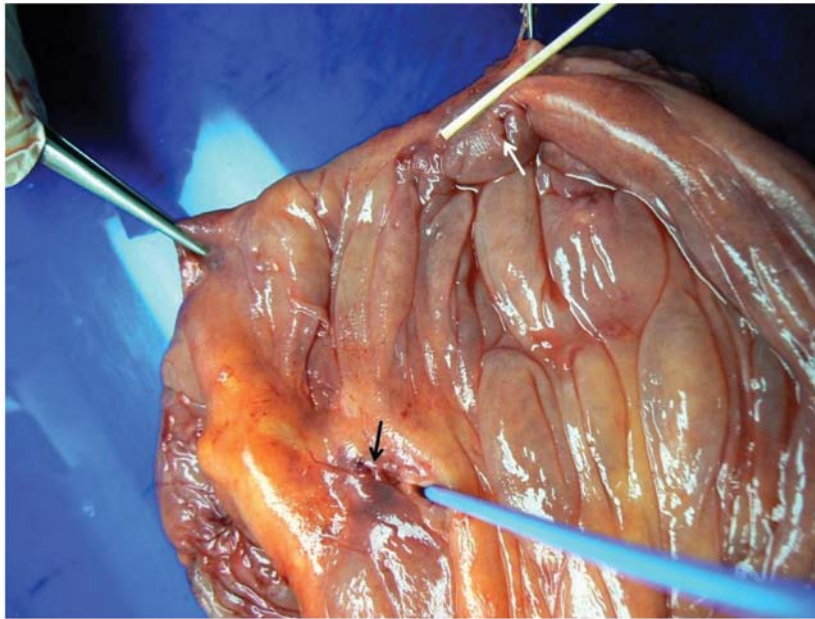


Figure 1. Photograph of the fresh specimen. The wooden pointer indicates the carcinoma (1 cm in diameter). It is adjacent to the lumen of the appendix (white arrow). There is a linear mucosal erosion (black arrow) caused by the blue ureteral stent.

to the location of ureteral implantation in an animal model (24). Austen and Kälble estimated that individuals between the ages of 25 and 30 with this form of diversion have a 477-fold increased lifetime risk of colon carcinoma and that patients between the ages of 55 and 60 years have an 8-fold increased lifetime risk (25).

Currently, urinary diversion into isolated bowel, typically ileum, is the most common method used after cystectomy (23,26). It was introduced by Bricker in the mid-twentieth century (27). Tizzoni and Foggi were the first to attempt creation of a neobladder in 1888 but the results were not satisfactory (23). During the 1970s, continent pouches were introduced again. In this procedure, a segment of bowel is isolated on a vascular pedicle, detubularized and reconfigured to create a spherical, low-pressure conduit. Ureters are implanted and the pouch is either connected to the native urethra (orthotopic neobladder) or a catheterizable stoma is created. Today, in young patients without major comorbid conditions, the orthotopic neobladder is the most commonly utilized form of urinary diversion and allows for a good quality of life (28,29).

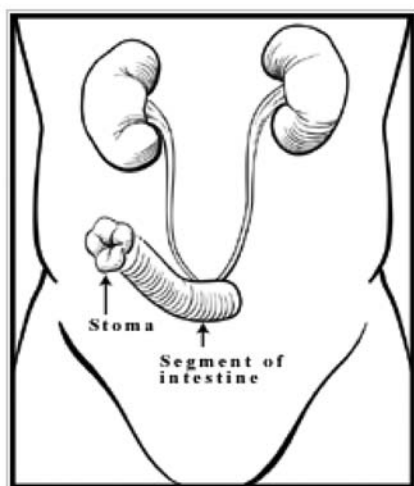
The pattern of carcinogenesis in patients with urinary diversions that maintain separation of urine and feces is different than that of patients with ureterosigmoidostomies. Cancers occurring after ureterosigmoidostomy are almost all colon adenocarcinomas; those in isolated intestinal segments used for urinary diversion are usually adenocarcinomas but sarcomas and transitional cell, squamous cell, and oat cell carcinomas also occur occasionally. The location of cancer developing in patients with ureterosigmoidostomy is practically always at the ureteroenteric anastomotic sites; those arising in isolated intestinal segments used for urinary diversion are located at the ureteroenteric anastomotic sites in ~58% of instances and elsewhere in the conduit in the remaining 42% (25).

Despite the risk of metabolic and other complications, the use of intestinal segments for urinary diversion is generally pref-

erable to other options (cutaneous ureterostomy, percutaneous nephrostomy, or tissue-engineered bladder) (29). However, it is now also clear that patients with ileal conduits and continent diversions of various types (e.g., continent conduits and orthotopic neobladders) are at risk for second primary cancers. About 13,000 individuals receive a cystectomy for bladder carcinoma in the US each year, and ~17% undergo continent diversion (28,29). Based on these statistics, we estimate that about 11,000 patients receive an ileal conduit and >2,000 receive a neobladder each year in the US. In the US, the colon is used for the neobladder in about half of those who receive continent diversion; the small intestine is used for the other half. Considering that the neobladder procedure has been regularly used for the past twenty years, perhaps 10,000 people in the US currently have a neobladder. The typical latency period for developing cancer in an intestinal segment used for urinary diversion is about two decades. Because the mean survival duration for patients who have received curative-intent treatment for bladder carcinoma continues to increase, the risk of developing cancer in a urinary conduit for each patient is also increasing. It seems likely that an epidemic of such cancers, particularly in those who continue to smoke, is emerging at present. We sought to alert general surgeons about this phenomenon as they are likely to be asked to provide surgical care for such patients more frequently in the future.

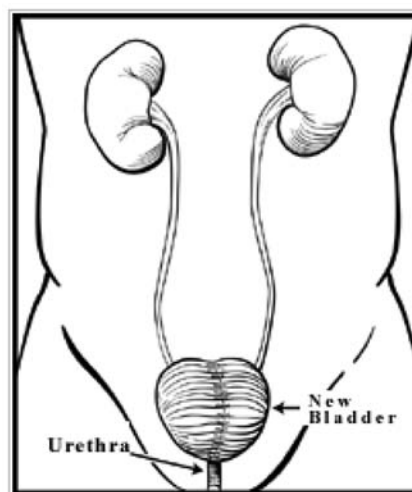
Materials and methods

We recently encountered a patient who developed a new primary adenocarcinoma in an orthotopic neobladder created at the time of radical cystectomy for transitional cell carcinoma of the bladder 22 years earlier. Two separate literature searches were performed using PubMed on January 17, 2010. To evaluate the prior literature on this topic, one search mimicked that used by Austen *et al* (25). The search criteria were 'urinary diversion' and



Ileal Conduit Urinary Diversion: A segment of the intestine directs urine through a stoma into an external collecting bag.

Figure 2. Conventional ileal diversion. A segment of the intestine directs urine through a stoma into an external collecting bag. Cleveland Clinic: Treatment and Procedures. Urinary Reconstruction and Diversion. http://my.clevelandclinic.org/services/urinary_reconstruction_and_diversion/hic_urinary_reconstruction_and_diversion.aspx



Neobladder to Urethra Diversion: Intestine is made into a reservoir and connected to the urethra

Figure 3. Neobladder. Intestine is made into a reservoir and connected to the urethra. Cleveland Clinic: Treatment and Procedures. Urinary Reconstruction and Diversion. http://my.clevelandclinic.org/services/urinary_reconstruction_and_diversion/hic_urinary_reconstruction_and_diversion.aspx

'carcinoma', using 'case reports' as a limitation. All languages were accepted. The second literature search, also using PubMed, was identical in all respects except that the search criteria were 'neobladder' and 'carcinoma' with 'case reports' as a limitation.

Results

Case report. In 1987, a 48-year-old male was diagnosed with muscle-invasive transitional cell carcinoma of the urinary bladder. He had smoked 1.5 packs of cigarettes per day for many years. He underwent a cystoprostatectomy and had an ileocolonic neobladder constructed to provide continent urinary diversion. He continued to smoke cigarettes and in 2008 he presented with symptomatic gallstone disease. Urology consultation was requested prior to cholecystectomy in order to determine whether further urologic procedures (revision of the neobladder, treatment of new primary urothelial tumors, etc.) might be indicated at the same operation. New-onset microscopic hematuria was detected and cystoscopy revealed two papillary tumors in the neobladder. One was invasive adenocarcinoma. Colonoscopy revealed no lesions in the colon remaining after the neobladder creation. He underwent open cholecystectomy, radical resection of the neobladder with regional lymphadenectomy, and implantation of ureters into a standard ileal conduit (Fig. 1). The operation was carried out by both surgeons and urologists. The prior radical cystectomy posed significant technical difficulties. Stents proved to be useful in avoiding damage to the ureters. Particular care was required to avoid injury to the obturator nerves, pelvic vessels, and the like, as much of the tissue overlying these structures had been resected at the time of the cystectomy. The pathology report indicated T1N0M0 colon adenocarcinoma. The second lesion seen at cystoscopy was an adenoma. The patient had no evidence of recurrence two years later.

There were 550 reports retrieved with our first computer-generated literature search. Sixty-six described cases of tumor development in patients with isolated intestinal urinary diversions created after cystectomy for bladder cancer (Fig. 2). There were 77 reports retrieved with the second search; 15 described cancers that developed in orthotopic neobladders (Fig. 3). Most were adenocarcinomas but transitional cell carcinoma, squamous cell carcinoma, small cell undifferentiated carcinoma, and mesenchymal cancers such as lymphomas and sarcomas were also reported.

Discussion

It has been known for several decades that aromatic amine exposure in an occupational setting and tobacco abuse account for the majority of cases of bladder cancer in most areas of the world (30). As the exposure to carcinogens arising from industrial sources has been decreasing in the US, the proportion of bladder cancers caused by tobacco abuse is increasing (31). Most experts conclude that the risk of cancer in isolated bowel segments used for urinary diversion after cystectomy is directly and causally related to the tobacco-derived urinary carcinogens bathing the epithelium, since most patients who abused tobacco before developing bladder carcinoma continue to smoke after cystectomy.

Since ureterosigmoidostomy is such a reliable model of colonic carcinogenesis, potential mechanisms have been investigated. One mechanism which could simultaneously explain tumor occurrence in both isolated and non-isolated gut segment urinary diversions involves inflammatory mediators (32). There are numerous reports implicating epidermal growth factor, various transforming growth factors and cytokines, and cyclooxygenase-2 in the process of carcinogenesis, particularly in chronically inflamed tissues such as these urinary conduits (25).

The causative role of tobacco abuse in carcinogenesis has been reviewed by Hecht (33). There are dozens of known carcinogens in cigarette smoke (34). They comprise various classes of agents and many are excreted in urine (35). Those agents believed to be most responsible for bladder carcinoma are 4-aminobiphenyl and other aromatic amines, although their relative potencies on a molar basis are not known. Whether tobacco-derived carcinogens are responsible for carcinoma of the small intestine is unknown at present since research on this topic is minimal (22). Hannan *et al* have provided a quantitative estimate of the risk of colorectal cancer in smokers (36). The relative importance of the various tobacco-derived carcinogens in carcinogenesis of the colon and rectum is uncertain. Many other ingested carcinogens derived from dietary sources are present in the colon. Resident bacterial, fungal, viral, and eukaryotic intestinal organisms, including protozoans (such as amoebas) and metazoans (such as tapeworms) produce an enormous number of metabolic products, most of which are not characterized. The causal relation between cigarette smoking and colorectal carcinogenesis has been well established recently (19,20). Tobacco-derived nitrosamines and heterocyclic amines are likely causative agents (33-39). The carcinogens responsible for carcinomas arising in intestinal segments used for urinary conduits are unknown but renal metabolism and urinary excretion of tobacco-derived chemicals is an important route of elimination of these substances. Because 4-aminobiphenyl and other small aromatic amines are present in urine and appear to be the dominant known chemicals responsible for bladder cancer in tobacco abusers, they may be presumed to cause cancer in intestinal urinary conduits as well.

According to the Centers for Disease Control and Prevention, approximately 45 million Americans smoke cigarettes and are unable to quit (40). A person who continues to smoke after resection of his/her bladder cancer is at risk of developing a primary adenocarcinoma in the diverted bowel segment. The long-term exposure of bowel mucosa to tobacco-derived and non-tobacco-derived fecal carcinogens prior to the cystectomy, followed by exposure to urine containing different carcinogens derived from cigarette smoke, in addition to the proinflammatory environment of the conduit, appears sufficient to explain the development of adenocarcinoma in patients with an orthotopic neobladder such as the patient described herein.

The risk of intestinal adenocarcinoma in a urinary conduit in patients with spina bifida or bladder exstrophy who receive a urinary diversion is appreciable (41). These patients presumably warrant periodic surveillance for this event, like patients after cystectomy for bladder carcinoma. The absolute risk of intestinal adenocarcinoma in a urinary conduit following cystectomy for bladder carcinoma is not known at present although there are many more such patients than spina bifida or bladder exstrophy patients. Sakano *et al* were apparently the first to report a patient who developed adenocarcinoma in an ileal conduit after cystectomy for bladder carcinoma (42). Albertini *et al* were apparently the first to describe an adenocarcinoma arising in the colonic mucosa of a continent urinary reservoir following cystectomy for bladder cancer (43). Reports have usually been in the urology literature and occasionally in gynecology (44) and general surgery (45) studies. The literature prior to 2004 has been summarized by Austen and Kälbe (25). Our literature search yielded four case reports of intestinal adenocarcinoma arising in

a urinary conduit created from an isolated segment of intestine since 2004 (46-49). It seems likely that the overall incidence of such second cancers is increasing.

In conclusion, as the results of treatment for bladder cancer are steadily improving, long-term survivors may develop other disorders requiring abdominal surgery, as in the case reported here. A general surgeon contemplating an elective abdominal operation for any reason in a patient who has had a prior cystectomy for bladder carcinoma should be alert to the potential need for an additional procedure involving the urinary system. We believe that urological consultation and appropriate diagnostic tests should be obtained. Purely urological disorders (ureter-enteric stricture, stones, etc.) may be discovered and warrant treatment at the same time. If an intestinal adenocarcinoma is found in the urinary conduit, resection may be curative. Collaboration between the general surgeon and the urologist can yield good results, as we have demonstrated.

References

1. Boyle P and Levin B (eds.): Introduction: needs and prospects for cancer control. World Cancer Report 2008. IARC Press, Lyon, pp11-13, 2008.
2. Ploeg M, Aben KKH and Kiemeny LA: The present and future burden of urinary bladder cancer in the world. World J Urol 27: 289-293, 2009.
3. Jacobs BL, Lee CT and Montie JE: Bladder cancer in 2010: how far have we come? CA Cancer J Clin 60: 244-272, 2010.
4. Smith BD, Smith GL, Hurria A, Hortobagyi GN and Buchholz TA: Future of cancer incidence in the United States: burdens upon an aging, changing nation. J Clin Oncol 27: 2758-2765, 2009.
5. Shah A, Rachet B, Mitry E, Cooper N, Brown CM and Coleman MP: Survival from bladder cancer in England and Wales up to 2001. Br J Cancer 99 (Suppl. 1): S86-S90, 2008.
6. Fraumeni JF Jr: Cigarette smoking and cancers of the urinary tract: geographic variation in the United States. J Natl Cancer Inst 41: 1205-1211, 1968.
7. Silverman DJ, Devesa SS, Moore LE and Rothman N: Bladder cancer. In: Cancer Epidemiology and Prevention. 3rd edition. Schottenfeld D and Fraumeni JF (eds.) Oxford University Press, New York, NY, pp1101-1127, 2006.
8. Stern MC, Lin J, Figueroa JD, *et al*: Polymorphisms in DNA repair genes, smoking, and bladder cancer risk: findings from the international consortium of bladder cancer. Cancer Res 69: 6857-6864, 2009.
9. Fendorf S, Michael HA and van Geen A: Spatial and temporal variations of groundwater arsenic in South and Southeast Asia. Science 328: 1123-1127, 2010.
10. Travis LB, Curtis RE, Glimelius B, *et al*: Bladder and kidney cancer following cyclophosphamide therapy for non-Hodgkin's lymphoma. J Natl Cancer Inst 87: 524-531, 1995.
11. Committee on the Biological Effects of Ionizing Radiation: Upton AC, Hartl DL, Boecker BB, *et al* and NAS (National Academy of Sciences): Health Risks of Exposure to Low Levels of Ionizing Radiation (BEIR V). Natl Acad Press, Washington, DC, 1990.
12. Jemal A, Siegel R, Xu J and Ward EM: Cancer Statistics, 2010. CA Cancer J Clin 60: 277-300, 2010.
13. Giovannucci C and Wu K: Cancers of the colon and rectum. In: Cancer Epidemiology and Prevention. 3rd edition. Schottenfeld D and Fraumeni JF (eds). Oxford University Press, New York, NY, pp809-829, 2006.
14. Winawer SH, Zauber AG, Ho MN, *et al*: Prevention of colorectal cancer by colonoscopic polypectomy. N Engl J Med 329: 1997-1981, 1993.
15. Potter JD and McMichael AJ: Diet and cancer of the colon and rectum: a case-control study. J Natl Cancer Inst 76: 557-569, 1986.
16. Adamson RH: Mutagens and carcinogens formed during cooking of foods and methods to minimize their formation. In: Cancer Prevention. De Vita VT Jr, Hellman S and Rosenberg SA (eds.) J.B. Lippincott, PA, pp1-7, 1990.
17. McKeown-Eyssen GE: Fiber intake in different populations and colon cancer risk. Prev Med 16: 532-539, 1987.

18. Wu S, Rhee KJ, Albesiano E, *et al*: A human colonic commensal promotes colon tumorigenesis via activation of T helper type 17 T cell responses. *Nat Med* 15: 1016-1022, 2009.
19. Peppone LJ, Reid ME, Moysich KB, *et al*: The effect of second-hand smoke exposure on the association between active cigarette smoking and colorectal cancer. *Cancer Causes Control* 21: 1247-1255, 2010.
20. Botteri E, Iodice S, Bagnardi V, Raimondi S, Lowenfels AB and Maisonneuve P: Smoking and colorectal cancer: a meta-analysis. *JAMA* 300: 2765-2778, 2008.
21. Beebe-Dimmer JL and Schottenfeld D: Cancers of the small intestine. In: *Cancer Epidemiology and Prevention*. 3rd edition. Schottenfeld D and Fraumeni JF (eds.) Oxford University Press, New York, NY, pp801-808, 2006.
22. Qubaiah O, Devesa SS, Platz CE, Huycke MM and Dores GM: Small intestinal cancer: a population-based study of incidence and survival patterns in the United States, 1992 to 2006. *Cancer Epidemiol Biomarkers Prev* 19: 1908-1918, 2010.
23. Pannek J and Senge T: History of urinary diversion. *Urol Int* 60: 1-10, 1998.
24. Crissey MM, Steele GD and Gittes RF: Rat model for carcinogenesis in ureterosigmoidostomy. *Science* 207: 1079-1080, 1980.
25. Austen M and Käble T: Secondary malignancies in different forms of urinary diversion using isolated gut. *J Urol* 172: 831-838, 2004.
26. Fisch M and Thüroff JW: Continent cutaneous diversion. *BJU Int* 102: 1314-1319, 2008.
27. Bricker EM: Bladder substitution after pelvic evisceration. *Surg Clin North Am* 30: 1511-1521, 1950.
28. Gore JL, Saigal CS, Hanley JM, Schonlau M and Litwin MS: Variations in reconstruction after radical cystectomy. *Cancer* 107: 729-737, 2006.
29. Gore JL, Yu HY, Setodji C, Hanley JM, Litwin MS, Saigal CS and the Urologic Diseases in America Project: Urinary diversion and morbidity after radical cystectomy for bladder cancer. *Cancer* 116: 331-339, 2010.
30. Ross RK, Jones PA and Yu MC: Bladder cancer epidemiology and pathogenesis. *Semin Oncol* 23: 536-545, 1996.
31. Strobe SA and Montie JE: The causal role of cigarette smoking in bladder cancer initiation and progression, and the role of urologists in smoking cessation. *J Urol* 180: 31-37, 2008.
32. Terzic J, Grivennikov S, Karin E and Karin M: Inflammation and colon cancer. *Gastroenterology* 138: 2101-2114, 2010.
33. Hecht SS: Etiology of cancer: tobacco. In: *Cancer*. 8th edition. De Vita VT, Lawrence TS and Rosenberg SA (eds.) Lippincott Williams & Williams, PA, 2008.
34. Hecht SS and Hoffmann D: Tobacco-specific nitrosamines, an important group of carcinogens in tobacco and tobacco smoke. *Carcinogenesis* 9: 875-884, 1988.
35. Carmella SG, Chen M, Han S, Briggs A, Jensen J, Hatsukami DK and Hecht SS: Effects of smoking cessation on eight urinary tobacco carcinogen and toxicant biomarkers. *Chem Res Toxicol* 22: 734-741, 2009.
36. Hannan LM, Jacobs EJ and Thun MJ: The association between cigarette smoking and risk of colorectal cancer in a large prospective cohort from the United States. *Cancer Epidemiol Biomarkers Prev* 18: 3362-3367, 2009.
37. Peppone LJ, Mahoney MC, Cummings KM, Michalek AM, Reid ME, Moysich KB and Hyland A: Colorectal cancer occurs earlier in those exposed to tobacco smoke: implications for screening. *J Cancer Res Oncol* 134: 743-751, 2008.
38. Ito N, Hasegawa R, Sano M, Tamano S, Esumi H, Takayama S and Sugimura T: A new colon and mammary carcinogen in cooked food, 2-amino-1-methyl-6-phenylimidazo[4,5-b]pyridine (PhIP). *Carcinogenesis* 12: 1503-1506, 1991.
39. Wu WK, Wong HP, Luo SW, *et al*: 4-(Methylnitrosamino)-1-(3-pyridyl)-1-butanone from cigarette smoke stimulates colon cancer growth via beta-adrenoreceptors. *Cancer Res* 65: 5272-5277, 2005.
40. Morbidity and Mortality Weekly Report: Centers for Disease Control and Prevention. Cigarette smoking among adults - United States, 2004. 54: 1121-1124, 2005. Online at: <http://www.cdc.gov/mmwr/preview/mmwrhtml/mm5444a2.htm>
41. Castell JB, Feu AO, Sfulcini CJ, Barredo GJM and Marvrich VH: Adenocarcinoma in ileal conduit after cystectomy for bladder exstrophy. *Actas Urol Esp* 32: 937-940, 2007.
42. Sakano S, Yoshihiro S, Joko K, Kawano H and Naito K: Adenocarcinoma developing in an ileal conduit. *J Urol* 153: 146-148, 1995.
43. Albertini JJ, Sujka SK, Helal MA, Seigne JD and Lockhart JL: Adenocarcinoma in a continent colonic urinary reservoir. *Urology* 51: 499-500, 1998.
44. Marchetti DL, Piver MS and Tsukada Y: Adenocarcinoma in an isolated sigmoid urinary conduit. *Obstet Gynecol* 63 (Suppl 3): S54-S56, 1984.
45. Lisle D, Cataldo P, Bibawi SE and Wood M: Colonic adenocarcinoma occurring in an Indiana pouch. *Dis Colon Rectum* 43: 864-867, 2000.
46. Ide H, Kikuchi E, Shinoda K, Mukai M and Murai M: Carcinoma *in situ* developing in an ileal neobladder. *Urology* 69: 576, 2007.
47. Berberian JP, Goeman L, Allory Y, Abbou CC and Solomon L: Adenocarcinoma of ileal neobladder 20 years after cystectomy. *Urology* 68: e9-e10, 2006.
48. Ryoichi S, Hiroyuki M, Nobuyuki N, Tomohiro U and Jang KC: Colonic adenocarcinoma in an Indiana pouch successfully treated by endoscopic mucosal resection. *Int J Urol* 14: 661-662, 2007.
49. Wielding S, Fineron P, Driscoll PJ and Anderson DN: Late malignant change in an ileal conduit. *Int J Urol* 15: 99-101, 2008.